

CORONARY EMBOLISM AND ANGINA IN MITRAL STENOSIS

BY

CELIA OAKLEY, RAUF YUSUF, AND ARTHUR HOLLMAN

From the Department of Medicine, Postgraduate Medical School of London, and Hammersmith Hospital

Received September 6, 1960

Coronary embolism has been considered a rare and often fatal mishap. The most frequently reported heart diseases causing coronary embolism have been syphilis and bacterial endocarditis (Shrader *et al.*, 1956), so that coronary embolism might be expected to be decreasing in frequency. Our experience suggests, however, that its occurrence is by no means rare in rheumatic heart disease.

The object of this paper is to report five patients with mitral stenosis who had coronary emboli and to comment on the significance of anginal pain and ischæmic heart disease in mitral valve disease. None of the five patients had bacterial endocarditis. Evidence is presented to support our belief that coronary embolism is neither uncommon nor usually fatal, that it may be unobtrusive rather than dramatic, diagnosed retrospectively as often as currently, and that it is the most important cause of angina in patients with mitral stenosis.

Since the first post-mortem description of coronary embolism was published by Virchow in 1856, 90 acceptable cases have been reported. Shrader *et al.* (1956) stated that coronary embolism was usually fatal, and quoted a mortality rate of 96 per cent in their review of 54 previously reported cases. Wenger and Bauer (1958) reviewed 61 such cases and described 15 more occurring at the Mount Sinai Hospital, New York, between 1929 and 1957 (an incidence at necropsy of 0.06 per cent). The commonest sources of embolism in 74 patients were fragments of vegetation in bacterial endocarditis in 47 (64%), aortic thrombus in 9 (12%) and intra-cardiac thrombus from the left ventricle after infarction or from the left atrium in mitral stenosis in 8 (11%). Three of these authors' cases of coronary embolism were found to be incidental to the cause of death at post-mortem examination, and all three were seen within a period of six months in 1957. In two of them, the source of the embolism was calcified left atrial mural thrombus, whereas in only one of the ten fatal cases seen during a 28-year period was left atrial thrombus due to mitral stenosis the source of the embolism. These authors suggest that coronary artery embolism with recovery may not be rare, and since their paper there have been reports of six other patients with coronary embolism incidental to the cause of death (Wigle, 1957; Kavanaugh *et al.*, 1958; and Case records of the Massachusetts General Hospital, 1958). Study of the earlier reports suggests that instances in which recovery took place might not have been recognized.

ANGINAL PAIN

Angina is well known to occur in heart disease that is not due to coronary artery atherosclerosis. It is most common in severe aortic stenosis in which generalized replacement fibrosis of the left ventricular muscle chiefly in the subendocardial region is the rule at necropsy. In aortic stenosis there are several causes of generalized myocardial ischæmia. The left ventricular stroke work may be as much as four times the normal; the oxygen demands of the hypertrophied muscle mass are increased; there is mechanical impedance to coronary flow by systolic compression of the vessels and partial covering of the ostia by the distorted aortic valve cusps; and finally there exists a relative inability to increase the cardiac output on effort. The amount of fibrosis is related to the severity

of the stenosis and the degree of left ventricular hypertrophy, and the presence of angina is a reliable clinical indication of severe aortic valve disease. Calcareous coronary emboli from the aortic valve sometimes occur but are not the usual cause of cardiac ischæmia in this disease.

Angina is not uncommon, however, in mitral stenosis also: "functional coronary insufficiency" has been invoked but is a much more tenuous concept than in aortic stenosis. In pure mitral stenosis the left ventricular stroke work is normal or reduced and there is no mechanical impedence to coronary flow. The oxygen supply to the left ventricle in mitral stenosis can become deficient only when the cardiac output is very greatly reduced. Coronary blood oxygen extraction may then be almost complete at rest, and when on effort the flow cannot be merely increased, ischæmia may result. This mechanism can account for angina only in those patients with mitral stenosis whose cardiac outputs are extremely low.

In contrast to aortic stenosis, microscopic myocardial fibrosis is minimal in mitral stenosis, while macroscopic fibrosis is focal, much less common, and much less extensive. When present, fibrosis in mitral stenosis is found almost exclusively in the posterior wall of the left ventricle (Wigle, 1957). Wood (1954) and Stuckey (1955) found that ischæmic changes in the cardiogram after effort in mitral stenosis were usually greatest in posterior leads, and it is therefore of interest that six out of eight infarcts in Wenger and Bauer's (1958) cases of coronary embolism were posterior.

CORRELATION OF ANGINA AND CORONARY EMBOLISM

It is surprising that no attempt has previously been made to relate the sequelæ of coronary embolism to the occurrence of ischæmic cardiac pain in mitral stenosis. Stuckey (1955) correlated cardiac pain with the severity of the mitral stenosis and the resultant low cardiac output. The average resting cardiac output in 15 of his 34 patients with mitral stenosis and angina was 3·7 litres per minute, but figures were not given for the cardiac output in the other 366 patients who had mitral stenosis without angina. A low output probably accounts for angina in a few instances, particularly when associated coronary atherosclerosis is present, but we were repeatedly struck by meeting young patients with incontrovertible angina with a normal cardiac output and with no more than passive pulmonary hypertension. Angina is rare in mitral regurgitation (for there were no instances in 40 patients in Stuckey's series), and possibly this is related to the infrequency of embolism from the left atrium in free mitral regurgitation.

When a young woman (C.H.) under our observation as an outpatient was admitted to hospital with classical coronary embolism, we decided to study the incidence, circumstances, and sequelæ of coronary embolism relevant to the incidence and ætiology of myocardial ischæmia in mitral stenosis.

THE PATIENTS STUDIED

Only patients with dominant mitral stenosis were studied. In the majority the stenosis was critical and thus required valvotomy. Hæmodynamic data were obtained in many, and most came to operation, when the surgeon confirmed the size of the valve and could assess the state of the left ventricle and note any scarring. Patients in whom mitral stenosis was complicated by important aortic valve disease were excluded.

There were 194 patients in the study; 152 (73%) of them were women and 42 (27%) were men, while 57 per cent of the women and 47 per cent of the men were over the age of 40 at the time of operation.

Diagnosis of Cardiac Ischæmia. Cardiac ischæmia was diagnosed if any of the following features were present: angina of effort or previous myocardial infarction; a positive cardiographic effort test in patients not having digitalis; cardiographic abnormalities that could not be attributed to ventricular hypertrophy, digitalis effects, or hypokalæmia; or the findings at operation or necropsy of disease of the coronary arteries or a myocardial scar.

CARDIAC INFARCTION

Five patients with mitral stenosis and coronary embolism resulting in cardiac infarction are described below.

Case 1. Mrs. C. H., aged 44, was seen in October 1957 with a history of increasing shortness of breath for two years. There was nothing to suggest paroxysmal arrhythmia, emboli, angina, or cardiac failure.

Examination. Sinus rhythm was present with signs of pure tight mitral stenosis. An X-ray showed enlargement of the left atrium and evidence of pulmonary venous hypertension. The cardiogram was normal apart from left atrial enlargement (Fig. 1). The patient was not taking digitalis. It was considered

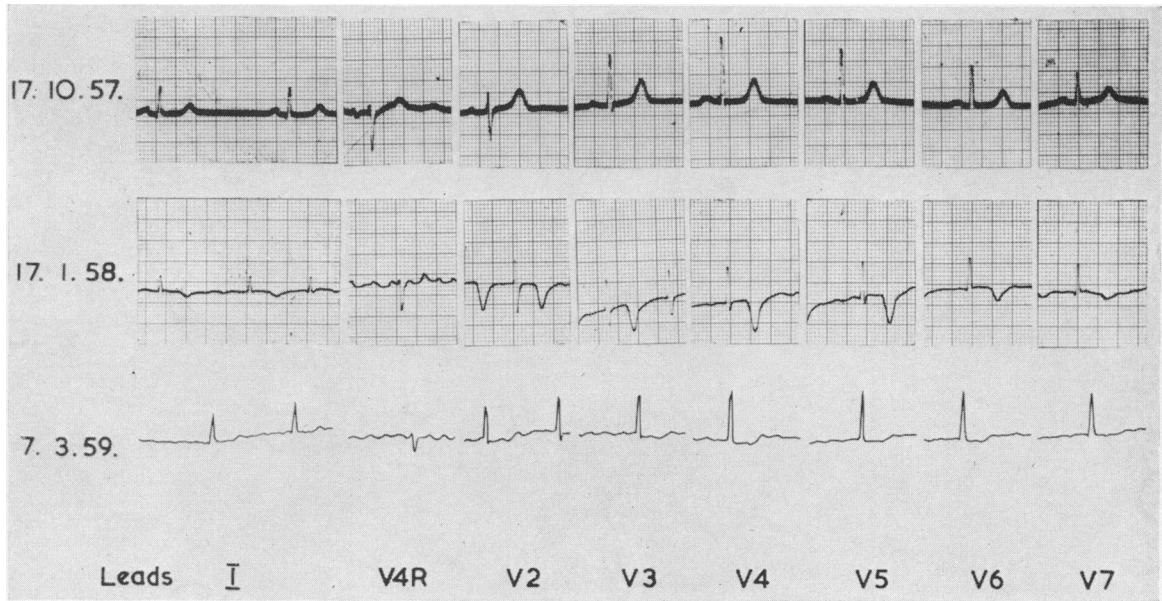


FIG. 1.—The cardiogram on 17/10/57 is normal except for left atrial P wave, shown only in lead II. That of 17/1/58, taken 16 days after the episode of chest pain, shows atrial fibrillation and evidence of anterior infarction. That of 7/3/59 shows no evidence of previous infarction, all the changes being attributable to digitalis. Case 1.

that she would need valvotomy and she was put on the waiting list for admission. In January, 1958, she was seized with sudden severe gripping chest pain which travelled from the right elbow to the shoulder blade and across the front of the chest. The pain persisted until morphine was given. The patient felt faint but did not lose consciousness nor did she notice any irregularity of her heart.

Twelve days later she was admitted to Hammersmith Hospital. Apart from atrial fibrillation there was no change in the physical signs or radiological appearances. The cardiogram confirmed the arrhythmia and showed deep symmetrical T-wave inversion in leads V2 to V7 without change in the QRS complexes. There was no family history of premature atherosclerosis, the serum cholesterol was 150 mg. per 100 ml. and the menopause had not occurred. Coronary embolism causing anterior infarction was diagnosed. She was treated with digitalis and anticoagulants and confined to bed. Mitral valvotomy was deferred until sound healing of the infarct could be assumed, phenindione being continued meanwhile.

At operation in November, 1958, by Mr. Kerr the mitral valve was split from 1.5 to 4 cm. in diameter by transventricular valvotomy. There was a fibrous scar 1½ cm. in diameter at the apex of the left ventricle, related to the anterior descending branch of the left coronary artery. An uneventful recovery was made, with freedom from dyspnoea and angina.

Comment. There is no doubt that cardiac infarction resulted from coronary embolism. By March, 1959, cardiographic stigmata of ischæmia had disappeared, the ST-T changes being attributable to digitalis effect alone. There is now no objective clue to suggest past infarction except this patient's own memory

of the incident. The passage of time may dim the memory and it is easy to imagine that many similar cases with milder chest pain could be missed entirely.

Case 2. Mrs. M. Y., aged 37, had been short of breath for three years. There had been no chest pain, palpitation, or suggestion of emboli. In January, 1957, she developed sudden severe pain down both arms, radiating later to the retrosternal area. The pain lasted 12 hours and the patient was later admitted to Bedford General Hospital under the care of Dr. Lewes. She was in sinus rhythm with signs of tight mitral stenosis, pulmonary hypertension, and tricuspid regurgitation. The cardiogram showed an rS pattern in leads V4 and V5, and QS in V6 with symmetrical T wave inversion (Fig. 2). One month after this incident

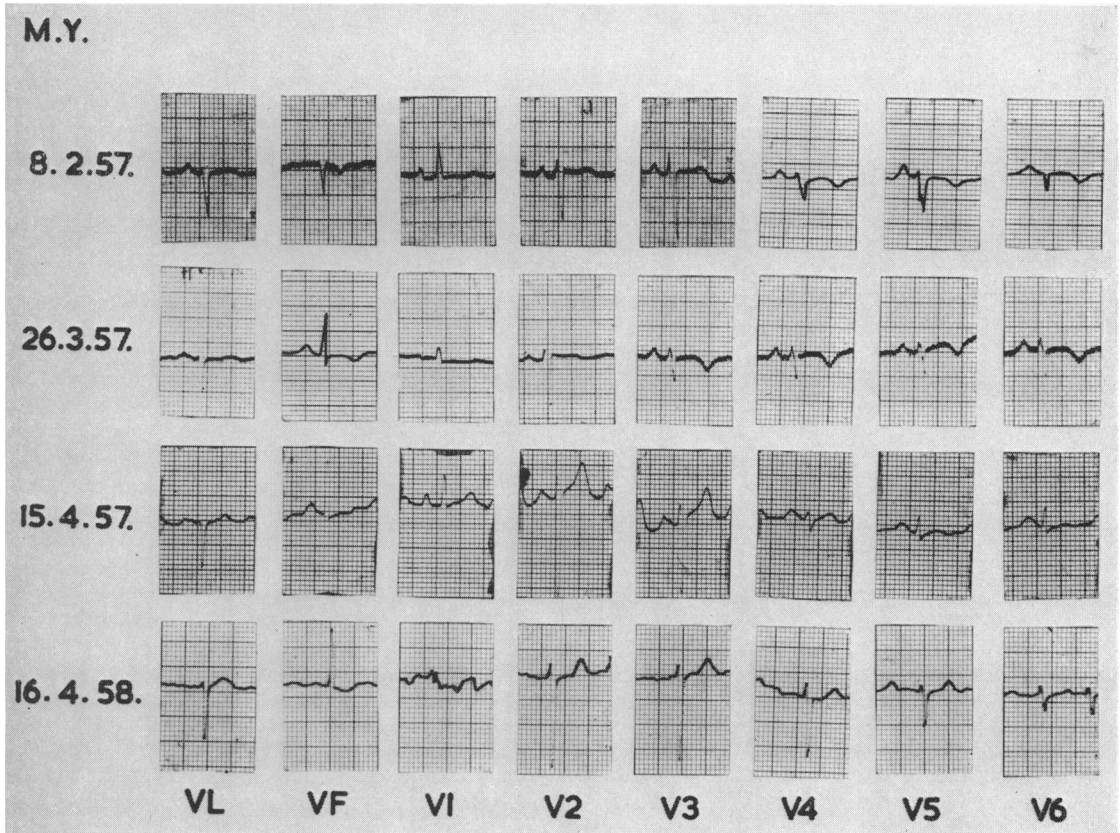


FIG. 2.—The cardiogram on 8/2/57, five weeks after the acute episode shows extensive anterior infarction. There is progressive recovery of T waves, and the record on 16/4/58 shows changes suggesting combined ventricular hypertrophy and concealed anterior infarction. Case 2.

she had a left popliteal embolus, and in April she was admitted to Hammersmith Hospital. The cardiographic changes had recovered, there now being a dominant R in V6 and V7 with flat T waves. She was severely incapacitated by fatigue and dyspnoea but had no angina. An effort test was negative. Digitalis was not being given.

Mitral valvotomy, deferred to allow time for healing of her infarct, was performed in September by Mr. Cleland. The valve opening was 1 cm. in diameter. The medial commissure only was split digitally to give an orifice of 3 cm. Atrial fibrillation developed after the operation; sinus rhythm was restored with quinidine, but readmission was necessary on three occasions subsequently because of relapse into fibrillation and persistent disability. The cardiogram six months later showed an rS pattern in all chest leads suggestive of combined ventricular hypertrophy and concealed cardiac infarction.

Necropsy. In October, 1958, a year after the operation the patient died suddenly at home. Necropsy showed re-stenosis of the mitral valve with an orifice of 1 cm: the medial commissure had re-fused. The left ventricle was greatly dilated, almost aneurysmal, the anterior wall and apex bearing an extensive old fibrous scar which largely replaced the heart muscle. The fibrosis extended to the interventricular septum. The coronary arteries were patent and normal, the embolus having presumably broken up and packed away into the smallest coronary branches. There was no pulmonary œdema. Both kidneys showed old infarcts.

Comment. Coronary embolism caused a large area of infarction and commencing left ventricular aneurysm in a 37-year-old woman who died suddenly with restenosis of the mitral valve 13 months after valvotomy and 21 months after the cardiac infarct. There was no coronary atherosclerosis and no macroscopic coronary arterial occlusion. The absence of macroscopic occlusion is often a feature after embolism to major vessels anywhere in the body, but not often compatible with thrombosis *in situ*. Evidence of other systemic emboli was found.

Case 3. Mrs. D. D., aged 33, first noticed shortness of breath in 1956 at the age of 30, but in March 1953, at the age of 27, signs of severe mitral valve disease with combined stenosis and regurgitation had been found. The cardiogram showed left atrial and left ventricular enlargement, confirmed on X-ray. There was no history of chest pain or embolism. By July the same year, much deterioration had taken place and the patient was admitted to hospital in gross heart failure with atrial fibrillation. She responded well to treatment and was discharged.

In November, 1953, there was sudden pain in the chest "like being clamped in a vice." This lasted about four hours, and resulted in admission to hospital. The patient was ashen and clammy, with a very small pulse volume and gross congestive heart failure. A cardiogram showed recent massive anterior infarction with QS waves in leads I and V1 to V4 followed by deep T inversion in leads T and V2 to V6. There was no improvement and death occurred 36 hours after admission.

Necropsy. The heart weighed 660 g. and there were 75 ml. of clear pericardial fluid. The visceral pericardium was slightly roughened over an area 7 cm. across on the anterior surface of the left ventricle between the septal region and the apex. The left atrium was greatly enlarged and contained antemortem thrombus. The left ventricle was dilated and 1.1 cm. thick. There was a recent red infarct of its anterior wall 7 cm. wide and extending up 7 cm. from the apex. The septum and the right ventricle were not involved. There was no mural thrombus. The coronary arteries were virtually free of atheroma and widely patent. Thrombus (probably embolic) 1.5 cm. long lay in the anterior descending branch of the left coronary artery, its proximal end being about 2.5 cm. from the aortic ostium. This clot was adherent to the wall and red, probably a few days old. The mitral orifice admitted three finger tips; the cusps were thickened and not calcified. No other emboli were found.

Comment. An unequivocal coronary embolism occurred as the sole embolus in a young woman with dominant mitral regurgitation, causing recurrence of congestive heart failure, which was irreversible.

Case 4. Mrs. L. S., aged 51, was admitted to hospital in 1945 on account of mitral stenosis with unstable rhythm and repeated paroxysms of atrial flutter or fibrillation. Between 1945 and 1953 she had a series of emboli including saddle and renal emboli, was seriously limited by dyspnoea, but did not have angina. There was no history of chest pain, syncope, or pulmonary œdema. On assessment in 1953 there were auscultatory signs of tight mitral stenosis without regurgitation. There was unexplained enlargement of the left ventricle. The blood pressure was 120/80 and there was a faint basal diastolic murmur. No signs of heart failure were present, but X-rays showed a grossly enlarged heart with cardio-thoracic ratio 70 per cent. The cardiogram showed atrial flutter, unusually deep Q waves with dominant R waves in V1 and V2, a dominant R without Q wave in V5 and T wave inversion throughout (Fig. 3). At cardiac catheterization the pulmonary trunk was not entered but the right ventricular systolic pressure was 63 mm. Hg, the cardiac output 3.5 litres a minute, and the estimated pulmonary vascular resistance, about 5 units.

Mitral valvotomy was performed in November, 1954, by Professor Pilcher. The pericardium was adherent anteriorly to the ventricles over an area about 4 cm. in diameter. The adhesions were partly separated and it was then seen that the underlying heart muscle was pale and fibrotic. The adherent area involved the contiguous parts of the two ventricles. The left atrium was enlarged. No thrombus was found. The mitral valve was spindle-shaped 1 cm. long, and calcified, but because of its rigidity the effective size could not materially be increased. There was no mitral regurgitation. An uneventful recovery followed the operation.

Comment. An old cardiac infarct was found at the time of mitral valvotomy in a 51-year-old woman. The left ventricular enlargement could be explained as a result of failure, with dilatation and ensuing hypertrophy following a major cardiac infarct which caused heart failure. As she had reached the age of risk

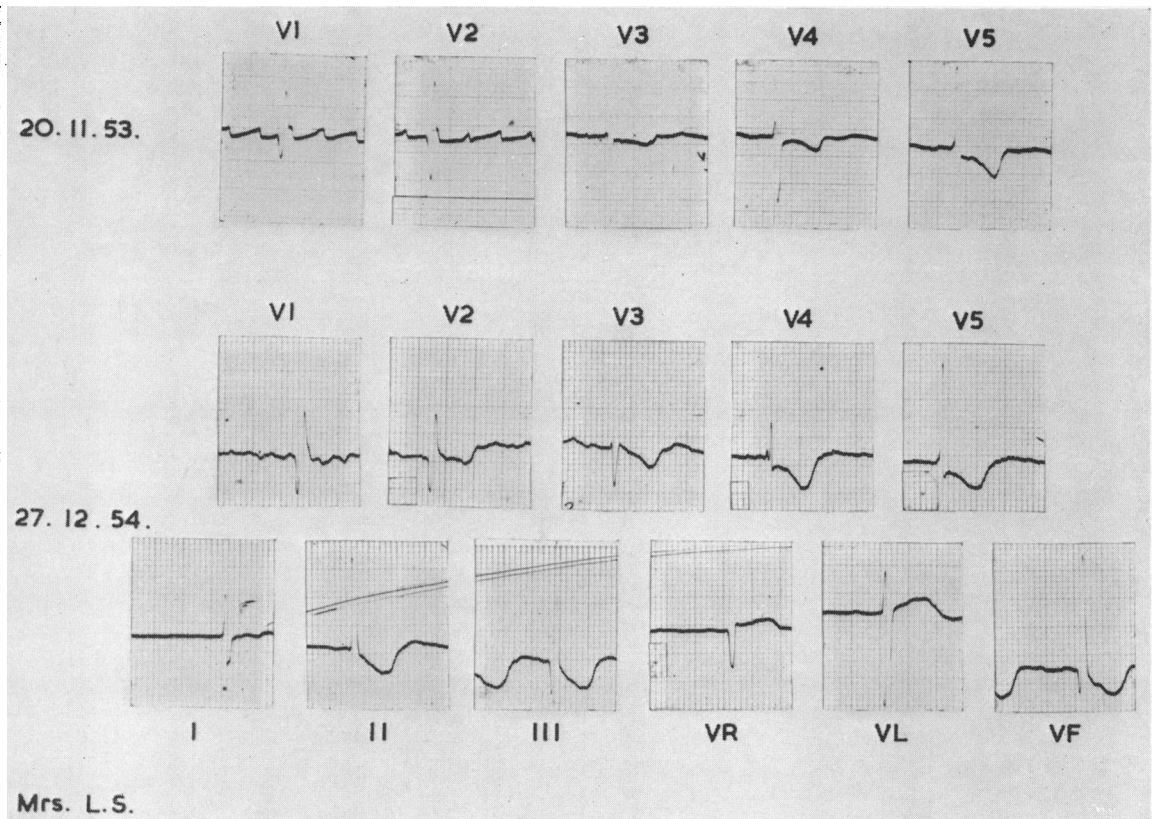


FIG. 3.—The cardiogram on 20/11/53 shows coarse atrial fibrillation and a deep Q wave in leads V1 and V2 with S-T depression and T wave inversion in V3, V4, and V5. On 27/12/54 the changes are more marked and suggest infarction of both ventricles. Case 4.

from atherosclerotic coronary occlusion, a diagnosis of embolic occlusion was no more than inferential. The unusual site of the infarct and the systemic emboli, however, supports the diagnosis of coronary embolism. The absence of cardiac pain may have been due to severe dyspnoea and heart failure.

Case 5. Miss B. B., aged 41, was first seen in 1948 with mitral stenosis and sinus rhythm. A standard lead cardiogram was normal. Seven years later she was admitted to hospital with very severe cramp-like retrosternal pain radiating to the left breast and arm, of several hours' duration. There was faintness and shock. The patient had noticed palpitations for three days previously and there was a history suggestive of paroxysmal arrhythmia but not of emboli, and she had not had angina. Examination showed signs of atrial fibrillation and mitral stenosis. The cardiogram (Fig. 4) showed recent anterior infarction with a QS wave in leads V4 and V5 and convex S-T segment elevation with commencing T wave inversion in leads V3 to V5. On treatment by bed rest and phenindione rhythm remained an unstable atrial flutter and three days later there was a left renal embolus; two days after this, and six days after stopping phenindione, a right brachial embolism occurred. At this time there were signs of pure tight mitral stenosis without mitral regurgitation or aortic valve disease and the blood pressure was 100/70. The clinical enlargement of the left ventricle could not be explained. The X-ray showed that the heart was larger than in 1948, this being due apparently to left ventricular enlargement. The left atrium was also enlarged. Mitral valvotomy was performed by Professor Pilcher in July, 1956. The valve was found to be 1 cm. in diameter, without regurgitation, and the orifice was enlarged to 3 cm. A localized bulge was seen in the lower part of the right ventricle which seemed to be displacing the left ventricle backwards. The surface over it was grey and resembled a scar 3-4 cm. in diameter which merged gradually into healthy muscle. There was very little

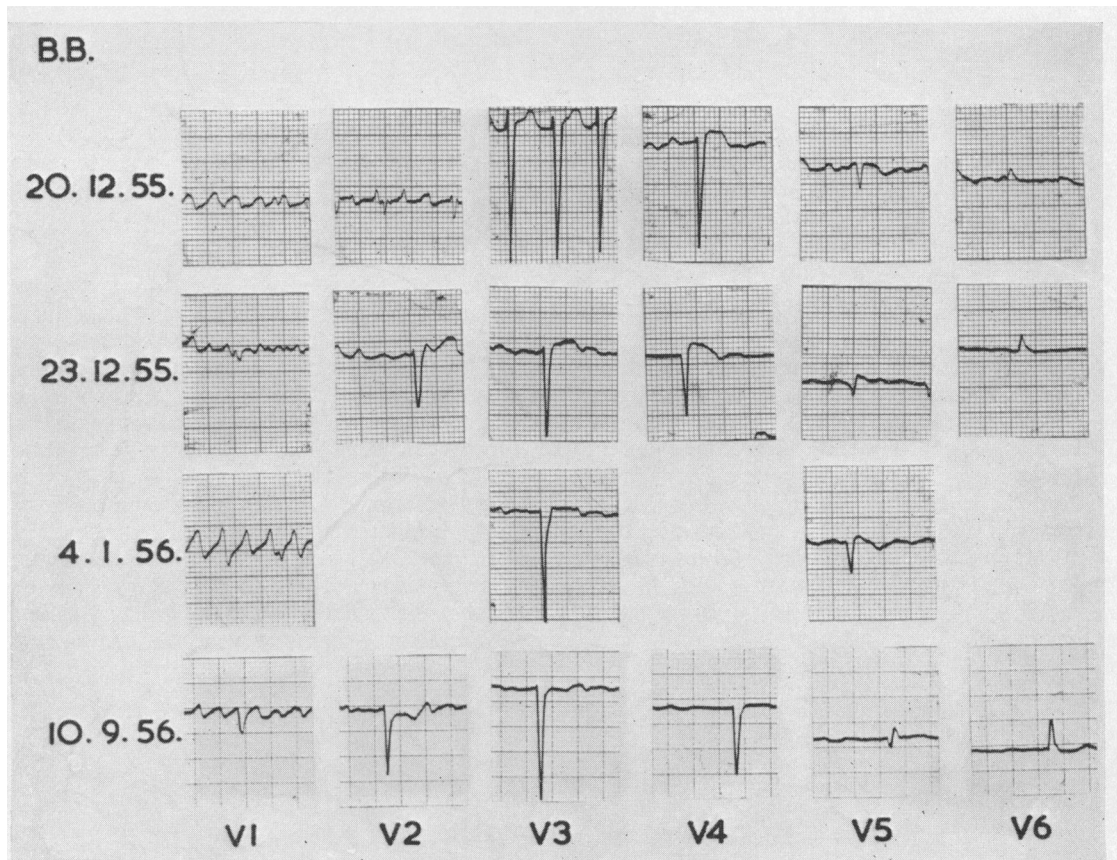


FIG. 4.—The cardiogram on 23/12/55 shows deep Q waves and S-T segment elevation in leads V4 and V5 due to infarction of the anterior wall of the right ventricle. There is unstable atrial flutter rhythm with 2:1 atrioventricular block, changing to coarse atrial fibrillation in the record of 23/12/55. Obvious stigmata of old infarction persist in the last record taken on 10/9/56. Case 5.

pulsation in the affected part. In the centre was a patch of fibrous tissue 1 cm. in diameter with strands extending from it blending into the surrounding part. The leg pulses were felt on return to the ward but a saddle embolus occurred six days after the operation necessitating mid-thigh amputation. Conversion to sinus rhythm was not attempted. The patient returned to Wales and has not been seen since.

Comment. An unequivocal coronary embolism with major infarction occurred in a patient with an unstable rhythm who had other emboli. Left ventricular enlargement followed and the infarcted area was subsequently seen at operation in an unusual site on the anterior wall of the right ventricle.

Coronary embolism causing minor infarction is easily diagnosed if seen during the acute incident, and also coronary embolism that has caused major infarction, even if there has been no acute episode, is readily recognized. But retrospective diagnosis of past coronary embolism causing minor infarction can only be speculative and this is probably the commonest type.

ANGINAL PAIN

Forty two patients (20%) suffered from angina of effort. Angina was commoner in the older patients, its incidence being 25 per cent in the patients over 40 compared with 16 per cent among patients below this age. This was to be expected as the accepted causes of ischaemic cardiac pain are more frequent in the older group of patients. These tended to have long-standing mitral valve disease, often had a high pulmonary vascular resistance, and were at some risk from coronary

atheroma. Older patients with mitral stenosis also have a higher incidence of systemic emboli (Bannister, 1960).

The higher incidence of angina in our series than in Wood's (1954) series (8.5% of 400 patients) is probably partly due to all our patients having critical stenosis whereas some of Wood's had mild or moderate stenosis, and possibly partly due to a higher average age in our patients. In contrast to Stuckey we found no consistent difference in character or duration between the anginal pain suffered by our patients with mitral stenosis, and the pain described by patients with occlusive coronary atherosclerosis. The following case reports illustrate the association of angina with mitral stenosis.

Case 6. Mrs. O. H., had developed heart failure during her first pregnancy when she was 27. After this she had minimal disability until, in 1957, at the age of 36, she suddenly developed dyspnoea, orthopnoea, and oedema of the ankles. She improved with digitalis and for the next two years had moderate shortness of breath, was easily tired, and suffered from bronchitis. There had been no systemic emboli but she developed classical angina of effort which was more disabling than her dyspnoea. At the age of 38 she had auricular fibrillation with signs of pure tight mitral stenosis, with tricuspid, but not mitral regurgitation, and no serious pulmonary hypertension. The blood pressure was never higher than 140/80 and there was no aortic valve disease, but the left ventricle was unquestionably enlarged. The cardiogram showed T wave inversion in leads V1 to V3 and S-T segment depression in leads V1 to V4 with possible left, but no right, ventricular enlargement. The effort test was strongly positive (Fig. 5) after exertion, less than that required to produce angina. An indicator dye dilution curve, obtained by injection into the pulmonary artery, was normal, excluding significant mitral regurgitation. It was thought that she had had a coronary embolus at the time of onset of atrial fibrillation and sudden decompensation two years previously, this being followed by angina and left ventricular enlargement.

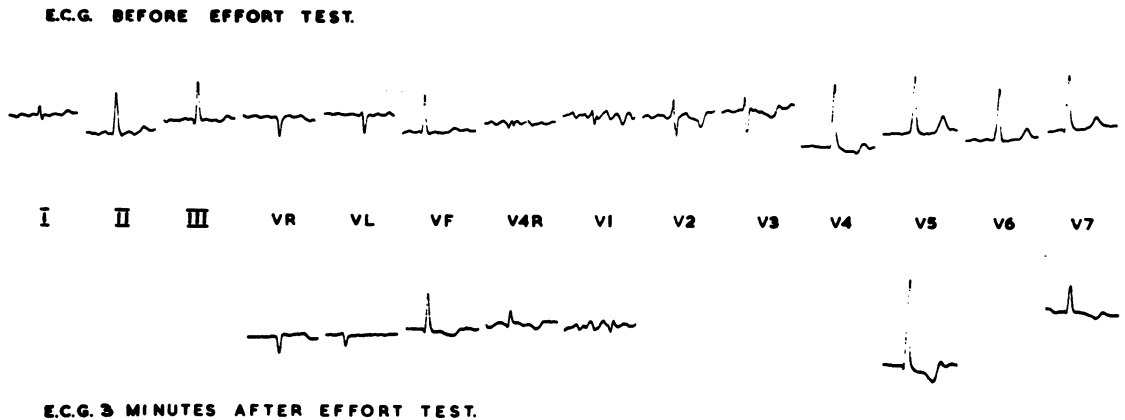


FIG. 5.—The resting cardiogram shows S-T segment depression confined to leads V2 to V4. After effort, S-T segment depression and early T wave inversion are seen in leads VF, V5 and V7. Case 6.

At mitral valvotomy by Mr. Sayed in September, 1959, moderate left ventricular enlargement was confirmed, and there was a scar 1 cm. in diameter at its apex. The mitral valve orifice was less than 1 cm. and was successfully split to 4 cm. without producing regurgitation. Recovery was uneventful.

Comment. In retrospect this patient probably suffered a cardiac infarction due to embolism. Angina, a cardiogram suggestive of localized ischæmia, a positive effort test, and left ventricular enlargement supported the diagnosis.

Case 7. Mrs. E. B., aged 41, underwent mitral valvotomy by Mr. Cleland in January, 1952, at the age of 35 years. Excellent relief of dyspnoea and bronchitis followed, and her cardiogram, which had shown a dominant R in leads V4R and V1, with T wave inversion in leads V1 to V3, became normal 10 months

after operation. The improvement lasted for five years after which, at the age of 39 years, typical angina of effort developed. The pain was always promptly relieved by trinitrine, but restricted her activity. A cardiogram now showed sagging depression of the S-T segment in leads II, III, VF, and V2 to V7, with flat T waves. Six months later she had developed permanent atrial fibrillation, and an effort test taken at that time was strongly positive (Fig. 6). The angina persisted for about 18 months and then gradually dis-

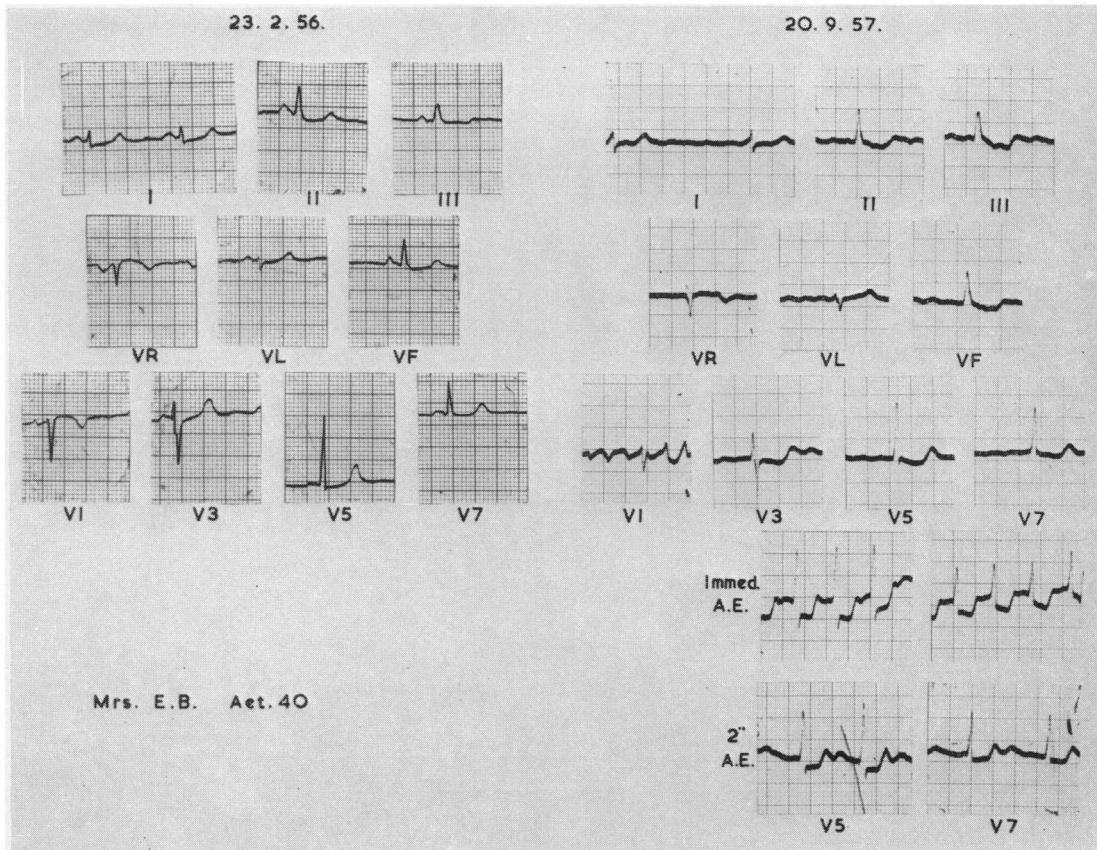


FIG. 6.—Case 7. The cardiogram on 23/2/56 shows sinus rhythm and slight S-T segment depression due to digitalis. On 20/9/57 there is atrial fibrillation with S-T-T wave changes attributable to digitalis, but a grossly positive effort test. (A.E.=effort test).

appeared; but she had become short of breath again. There was no history of emboli, no enlargement of the left ventricle, and no evidence of heart failure. The auscultatory signs suggested that the mitral valve had restenosed, although it was not as tight as before the first operation and there was no obvious rise in the pulmonary vascular resistance or recurrence of the previous cardiographic signs of right ventricular hypertrophy. A second mitral valvotomy was performed by Mr. Bentall in March, 1959, when the patient was 41 years old, and the mitral valve was split from $1\frac{1}{4}$ cm. to $3\frac{1}{2}$ cm. The left ventricle was of normal size and no scar was seen. She has again achieved excellent symptomatic and objective relief.

Comment. Angina of abrupt onset and cardiographic evidence of ischaemia was followed by atrial fibrillation. The angina disappeared spontaneously, although a second valvotomy was not performed until a year later. A diagnosis of coronary embolism here can only be speculative but the occurrence of angina could apparently not be related to a low cardiac output, nor was atherosclerosis a likely cause in a woman of 39 before the menopause.

Case 8. Mrs. A. T. had an abrupt onset of angina in November, 1955, and exertional pain gradually

became a greater disability than dyspnoea. There was no family history of ischæmic heart disease; she had not reached the menopause, was not thyrotoxic or anæmic, and had not had any emboli. The blood pressure was 115/75. There were clinical and cardiographic signs of left ventricular enlargement although the auscultatory signs indicated pure mitral stenosis with normal rhythm. The effort test was positive and the cardiac output was 10 litres a minute at rest, rising to 14 litres a minute after exercise. Valvotomy was advised and at operation by Mr. Bromley in January, 1956, the valve was 2 cm. in diameter. It was split to 3.5 cm. and after operation the dyspnoea was greatly relieved but angina persisted for two years before finally disappearing.

Comment. Angina was the chief complaint of this 43-year-old woman with a normal cardiac output and only moderate mitral stenosis. Whether it was due to coronary embolism or to premature coronary atherosclerosis cannot be proved. No note was made about the appearance of the left ventricle at operation. It is now routine practice to inspect the left ventricle, commenting on the size, the state of the myocardium, the presence of scars, and the appearance of the coronary arteries. However, it is possible to inspect only a portion of the exterior of the left ventricle at the time of operation, so by no means all infarcts are visible.

THE EFFORT TEST

Changes in the electrocardiogram provoked by exertion were investigated. Since digitalis effects may be exaggerated by effort and thus simulate changes caused by ischæmia (Leibow and Feil, 1941; Scherf and Schaffer, 1952) and since most of our patients were having digitalis, the effort test only had a limited value in detecting or confirming myocardial ischæmia. This test was performed on 54 patients, 41 of whom were taking digitalis. Positive effort tests were found in all of the 17 with angina, and in 7 of the 24 without angina. Thirteen patients were not taking digitalis: six of these had angina (four with positive effort tests), and only one of the seven without angina gave a positive result. Altogether 21 out of 23 patients with angina had positive tests and 8 out of 31 patients without angina had positive tests (Fig. 7).

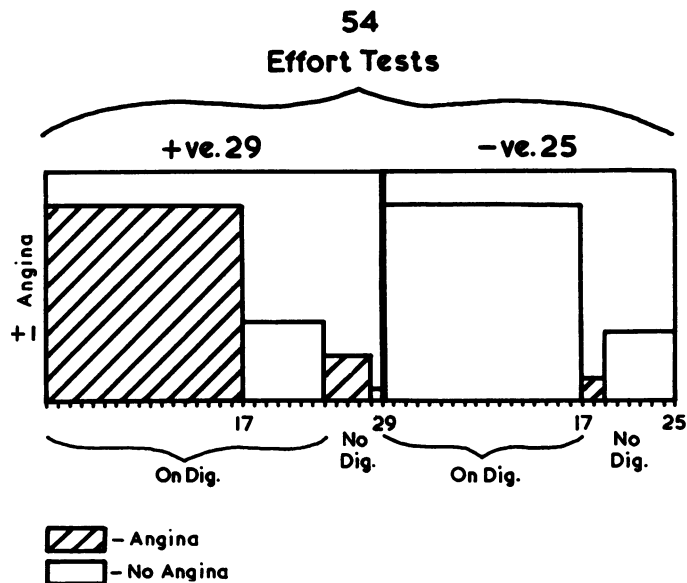


FIG. 7.—Relationship of results of cardiographic effort tests to anginal pain in 54 patients with critical mitral stenosis. Most patients with mitral stenosis and angina had positive effort tests, and most of those without angina had negative effort tests, whether or not they were taking digitalis. (Six patients with positive effort tests and no angina are discussed in the text.) (Dig.=digitalis.)

Only two of the last group of eight patients with positive tests but without angina were younger than 50 years of age. One, an Indian girl aged 26, who was not taking digitalis, had a strongly positive test (Fig. 8). She had critical mitral stenosis with tricuspid regurgitation and a cardiac

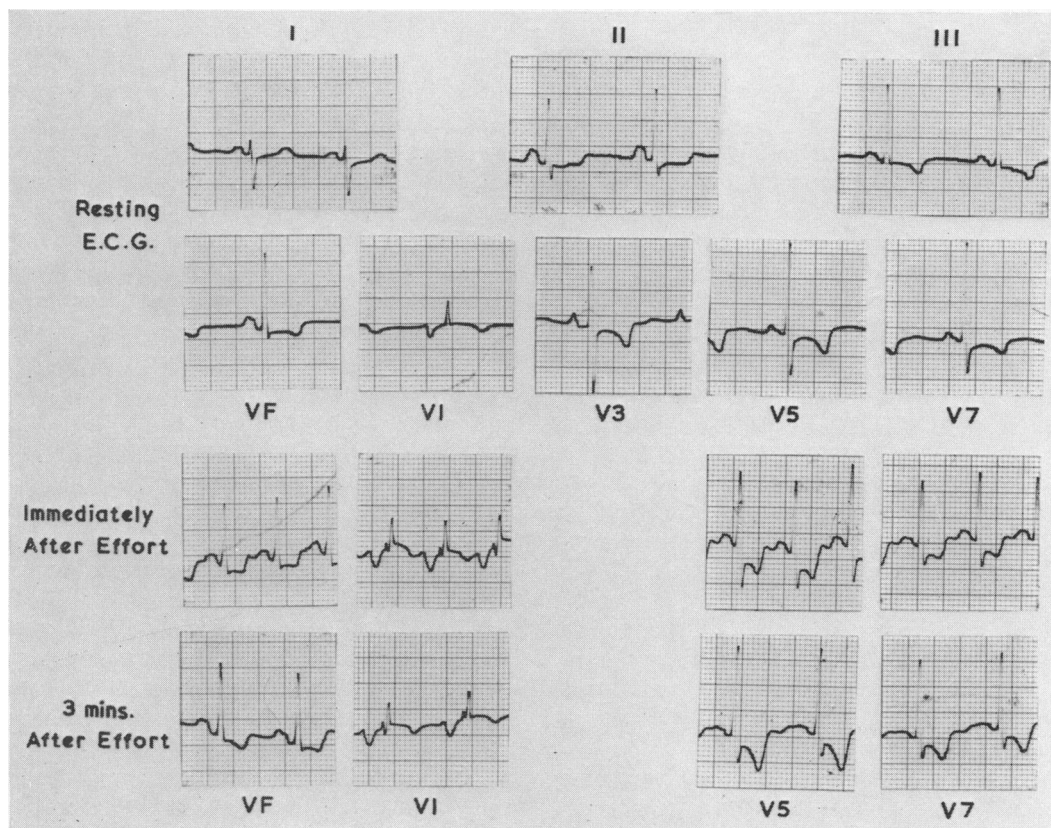


FIG. 8.—Case 8. Resting cardiogram and effort test in a woman of 26 years with critical mitral stenosis. The record at rest shows a dominant R wave in lead V1 with T wave inversion in all præcordial leads, and S-T segment depression in leads V3 to V7 due to right ventricular hypertrophy and possible anterior ischæmia. Left atrial enlargement is also seen. After effort there is gross S-T segment depression in leads VF, V1, V5, and V7 indicating a positive result.

output of only 2.3 litres a minute, but a normal pulmonary vascular resistance. There was no history of pulmonary or systemic emboli. It is not possible to say whether the positive test was due to a myocardial fault resulting from rheumatic myocarditis, to "functional coronary insufficiency," or to past coronary embolism. The other, a man of 30 years had unexplained slight left ventricular enlargement on clinical and cardiographic grounds, and a positive effort test. His cardiac output was normal clinically. There was no history of systemic embolism. Of the six patients aged over 50 years, four were women, two of whom had a resting cardiogram suggestive of ischæmia. All these older patients might have had coronary atherosclerosis to explain their positive effort tests.

A positive effort test thus seldom provided the only evidence of cardiac ischæmia, and a positive test was only considered valid if the patient was not taking digitalis, unless the S-T deviation on effort was gross (exceeding 2.5 mm.).

DISCUSSION

Three possible factors that might cause myocardial ischæmia in mitral stenosis were investigated: a low cardiac output, often but not always associated with a high pulmonary vascular resistance; occlusive coronary atheroma; and coronary occlusion due to embolism.

A Low Cardiac Output. The cardiac output tended to be lower in the patients with angina than in those without angina, averaging 2.7 litres a minute in patients with this symptom compared with 4.1 litres a minute in those without it. The output was 3.7 litres a minute in Stuckey's patients with angina. However, there was a wide scatter which rendered this difference insignificant, and in fact 44 per cent of the patients with angina had cardiac outputs exceeding 4.0 litres a minute compared with only 39 per cent of those without angina. The mean pulmonary vascular resistance in the patients with angina and in those without angina was similar, being 5.1 and 4.5 units respectively. We did not therefore consider a low cardiac output to be a cause of cardiac ischæmia.

Occlusive Coronary Atherosclerosis. This could have accounted for angina in some of the patients who were over 40 years old. Unlike aortic stenosis, mitral stenosis does not seem to confer any protection from coronary atherosclerosis. Scrutiny of the necropsy records of 50 cases of mitral stenosis aged over 40 at the time of death showed an incidence and severity of coronary atherosclerosis that did not differ from that found in a similar number of patients with other diseases, matched for age and sex. No more than four or five of our patients aged over 40 therefore would have been expected to have angina due to this cause. Since mitral stenosis mainly affects young women, coronary atherosclerosis could be expected to account for angina only in a very small proportion. Having found no correlation between angina, pulmonary vascular resistance, and cardiac output, the cause of angina was unexplained in most of our patients.

Coronary Occlusion due to Embolism. We have already commented upon the incidence of coronary embolism and have described four patients who survived infarction due to this. Not all had been seen during their acute illness, nor had they all suffered the classic severe pain of cardiac infarction, while the cardiogram did not always retain the stigmata of cardiac infarction. Patients with mitral stenosis often tell of "heart attacks" or "blackouts" which are variously and retrospectively attributed to paroxysmal arrhythmias, pulmonary or other embolism (except coronary), œdema, or "syncope".

A retrospective diagnosis of coronary embolism is clearly difficult. Embolism and bacterial endocarditis might be expected to figure more often in the histories of patients who have had coronary emboli. Systemic emboli are apt to occur in showers in mitral disease, and indeed 21 per cent of the patients with angina had suffered emboli to other sites, compared with 12 per cent of patients who did not get angina. Sixty-two per cent of those with angina had permanent atrial fibrillation compared with 50 per cent of those without angina.

The cardiograms of our patients with proven coronary emboli and classical cardiographic stigmata of infarction during their acute illness were sometimes no longer diagnostic of past infarction when viewed in isolation after as short an interval as a year later. Ventricular hypertrophy, atrial fibrillation, and digitalis effect tended to obscure the evidence of localized ischæmia. Goodwin (1958) found that in certain circumstances the cardiographic picture of anterior cardiac infarction may be indistinguishable from that of right ventricular hypertrophy, and that an rS pattern in V5 may conceal anterior cardiac infarction when there is right or combined ventricular hypertrophy. However, there were often hints such as considerable S-T segment depression or T wave inversion that was localized to a few unexpected leads such as the septal or posterior leads alone. These changes were very suspicious, particularly when they were grossly augmented by effort (Fig. 5).

Another sign that aroused suspicion was unexplained left ventricular enlargement. An infarct large enough to cause a period of left ventricular failure with increased residual cardiac blood volume stimulates myocardial hypertrophy. Left ventricular enlargement is well known in occlusive coronary artery disease with heart failure, and this response to dilatation might be greater when the remainder of the coronary vessels are healthy, as in mitral stenosis. We have several times seen

left ventricular hypertrophy, in the absence of an associated aortic lesion or systemic hypertension, in patients with pure mitral stenosis in whom a localized area of fibrosis in the left ventricle was seen at subsequent valvotomy (Cases 4, 5, and 6).

It is clearly difficult to prove coronary embolism retrospectively, but the later course of those few patients whom we have seen at the time of their acute incident at least proves that the sequelae may be angina, unexplained left ventricular enlargement, minor cardiographic changes easily missed or attributed to digitalis, a positive effort test, or a myocardial scar seen at operation.

We therefore suggest that anginal pain in mitral stenosis may not infrequently be due to unsuspected coronary embolism. Support for this belief has been received from Dr. David Lewes to whom we are indebted for Case 2. Dr. Lewes has since seen four other patients with mitral stenosis and coronary embolism. These cases are to be published shortly.

SUMMARY

The incidence of angina and the causes of myocardial ischæmia in mitral stenosis have been studied. Twenty per cent of 194 patients with pure mitral stenosis of critical degree were found to have angina. Coronary atherosclerosis, a high pulmonary vascular resistance, and low cardiac output with relatively fixed coronary blood flow accounted for angina in only a minority of our patients with this symptom. In the remainder, coronary artery obstruction appeared to be the probable cause. Four patients with non-fatal coronary embolism and one fatal case are described. Evidence has been produced to suggest that embolic rather than thrombotic coronary occlusion may be the commonest cause of ischæmic cardiac pain in mitral stenosis and that coronary embolism may be less rare than is commonly supposed.

We are grateful to the following Physicians for permission to publish the records of their patients: Dr. David Lewes for Case 2; Dr. Paul Wood for Case 3, and Dr. Hudson for the necropsy findings; Professor M. L. Rosenheim for Case 4; Dr. Howard Nicholson for Case 5; Dr. Kenneth Harris for the electrocardiograms of Cases 4 and 5; Dr. Jane Somerville kindly told us of Case 3 and arranged for us to inspect the records. We thank Dr. John Goodwin for permission to publish the other cases, for suggesting the investigation, and for much advice.

REFERENCES

- Bannister, R. G. (1960). *Lancet*, **2**, 329.
Case Records of the Massachusetts General Hospital (Case 44172). *New Engl. J. Med.*, **258**, 849.
— (1958). *New Engl. J. Med.*, **258**, 800.
Goodwin, J. F. (1958). *Brit. Heart J.*, **20**, 191.
Kavanaugh, G. J., Pruitt, R. D., and Edwards, J. E. (1958). *Proc. Staff Meet. Mayo Clin.*, **33**, 222.
Liebow, I. M., and Feil, H. (1941). *Amer. Heart J.*, **42**, 683.
Saphir, O. (1932). *Amer. Heart J.*, **8**, 312.
Scherf, D., and Schaffer, A. I. (1952). *Amer. Heart J.*, **43**, 927.
Shrader, E. L., Bawell, M. B., and Moragues, V. (1956). *Circulation*, **14**, 1159.
Stuckey, D. (1955). *Brit. Heart J.*, **17**, 397.
Virchow, R. (1856). *Virchow's Arch. path. Anat.*, **9**, 307.
Wenger, N. M., and Bauer, S. (1958). *Amer. J. Med.*, **25**, 549.
Wigle, E. D. (1957). *Brit. Heart J.*, **19**, 539.
Wood, P. (1954). *Brit. med. J.*, **1**, 1051.