

## EMBOLIC COMPLICATIONS OF CARDIOMYOPATHY

BY

J. E. COSNETT AND D. J. PUDIFIN

*From the Edendale Hospital, Pietermaritzburg, Natal, South Africa*

Received September 26, 1963

The cardiomyopathy that is common among the South African Bantu population has been described by diverse names, among which are "nutritional heart disease" and "cardiovascular collagenosis with parietal endocardial thrombosis". While its cause is obscure, pathologists are in agreement regarding its principal morbid anatomical features. Among the most striking of these is the endocardial thrombosis which is presumably responsible, by means of embolization, for infarction of other organs such as the lungs, spleen, kidneys, and brain. Evidence of such infarction is a common post-mortem finding, and this aspect of the morbid anatomy is well documented (Higginson, Gillanders, and Murray, 1952; Becker, Chatgidakis, and van Lingen, 1953; Higginson, Isaacson, and Simson, 1960). The clinical occurrence of visceral infarction in cardiomyopathy has not, however, been stressed. The object of this report is to show that the embolic complications may have clinically recognizable effects that may overshadow the primary cardiac disease.

### PATIENTS STUDIED

In a survey of heart disease among the Zulu patients at this hospital (Cosnett, 1962) it was found that cardiomyopathy was one of the four most common types of heart disease, and mention was made of the frequent occurrence of visceral infarction among these cases. From over 350 cases of cardiomyopathy that have occurred during the past four years we have selected a few to illustrate the clinical manifestations of embolism and infarction. These patients were all Zulu-speaking Bantu resident in Natal, who were admitted on one or more occasions to Edendale Hospital.

### CASE REPORTS

*Case 1.* A 20-year-old girl was first admitted to hospital in October 1959, nine days after the birth of her first child. The pregnancy had been normal. During the subsequent two and a half years she was admitted to hospital 11 times in congestive cardiac failure. The diagnosis of cardiomyopathy was made on the grounds of persistent heart failure with an enlarged, dilated heart, a loud third heart sound, and the absence of other cause for cardiac failure. The blood pressure and serum cholesterol were normal, and the Wassermann reaction was negative.

In the course of her eighth admission to hospital, in May 1961, she suddenly developed severe substernal and left-sided chest pain. The electrocardiogram showed a striking change in the pattern of the lateral chest leads which indicated the sudden development of an antero-lateral infarction (Fig. 1).

This patient showed all the features that we associate with cardiomyopathy of the post-partum type. In this race, sex, and age-group, it is difficult to explain the development of myocardial infarction on grounds other than those of coronary embolism.

*Case 2.* A 44-year-old man was admitted to hospital in congestive cardiac failure on 9 occasions during the five years preceding his death in May 1961. The diagnosis was cardiomyopathy, and the original cardiogram showed the pattern commonly found in this condition, the principal changes being low voltage with diffuse T-wave flattening or inversion. During his fourth admission the cardiogram showed, for the first time, the development of deep Q waves in the intermediate chest leads (V3 and V4), indicating an antero-

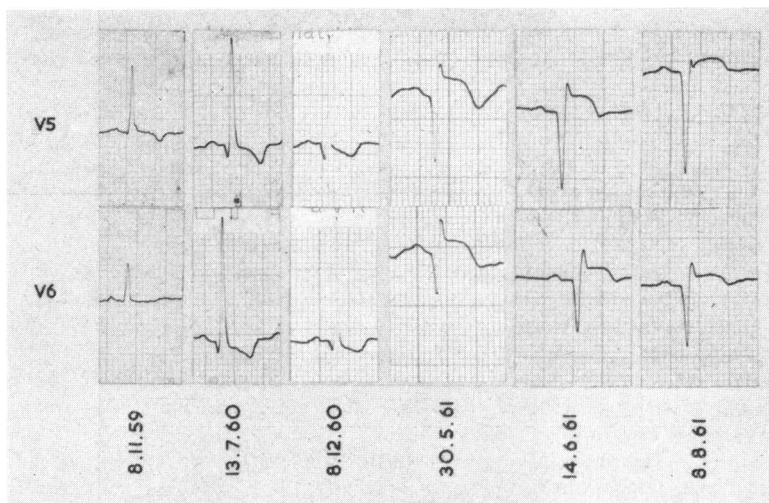


FIG. 1. The development of antero-lateral infarction in a woman aged 22 with cardiomyopathy (Case 1).

septal infarction. On his subsequent admission to hospital 8 months later, this pattern had extended to include all the anterior chest leads (V2 to V6), and the pattern of an extensive anterior infarction persisted until his death.

Necropsy confirmed the presence of an extensive myocardial infarct involving the apex of the heart and the interventricular septum. The interventricular branch of the left coronary artery was totally occluded by partially organized ante-mortem thrombus. Laminated ante-mortem thrombus was attached to the endocardial surface of the infarcted area and was present in the interstices of the trabeculae carneae remote from the infarct. The aorta and great vessels were free of atherosclerotic changes. There were multiple healed infarcts in both kidneys.

While it is possible that the coronary occlusion may have developed spontaneously, the absence of predisposing arterial disease, the clinical course and original freedom from coronary insufficiency, and the evidence of systemic infarction elsewhere suggests that this myocardial infarct originated from coronary embolism.

*Case 3.* A 40-year-old woman and her newborn baby were admitted to hospital in 1957. The mother was subsequently admitted to hospital on 4 occasions: each admission was for congestive cardiac failure of unknown cause and the presumptive diagnosis was cardiomyopathy. On her fourth admission she had developed left bundle-branch block. At her fifth admission, in 1961, she was very ill and died within three hours of arrival before a cardiogram was done. Her complaints at the time of her final admission were of cough, dyspnoea, and severe central chest pain. The Wassermann reaction was negative.

At necropsy all chambers of the heart were dilated and ante-mortem thrombus was present in the apex of the left ventricle. The interventricular branch of the left coronary artery was occluded by "partially organized ante-mortem thrombus". Sections of this artery showed the presence of "intimal thickening which did not have the characteristic features of atheroma". The kidneys showed recent and healed infarcts.

*Case 4.* This woman, 28 years of age, was first admitted to hospital in March 1960, three months after her seventh pregnancy, during which her health was normal. Between her first admission and her death a year later she was admitted in congestive cardiac failure 5 times, and spent about six months in hospital. The clinical diagnosis was cardiomyopathy. The cardiogram showed sinus rhythm and no evidence of myocardial infarction. Her last admission to hospital was punctuated by repeated episodes of abdominal pain, pain in one or both loins, and pleuritic chest pain associated with hæmoptysis. These episodes were accompanied by varying degrees of peripheral circulatory failure and shock.

At necropsy the heart showed the typical features of cardiomyopathy. There was gross dilatation of all

chambers and massive endocardial thrombus attached to the apices of both ventricles and the lateral wall of the left ventricle. Beneath this thrombus was some endocardial thickening and fibrosis. Multiple old and recent infarcts were present in both kidneys, the spleen, and both lungs. There was a large terminal pulmonary infarct.

The numerous setbacks which this patient suffered during her final illness were explained by multiple embolization of lungs and abdominal organs, the emboli originating from the endocardial thrombus.

*Case 5.* This woman, aged 32 years, had only one admission to hospital and this lasted over three months. Her 5-month-old baby had died shortly before her admission. Throughout her stay in hospital she was in severe intractable congestive cardiac failure and showed the clinical features of cardiomyopathy. Her progress was also punctuated by episodes of peripheral vascular failure with excessive sweating and hypotension. During her sixth week in hospital she developed pain and numbness in the left leg. The pedal pulses were not palpable and the leg subsequently became gangrenous below the knee. Anticoagulants had no beneficial effect, and above-knee amputation was performed. Her cardiac condition deteriorated and she died three weeks later. Permission for necropsy was refused.

Peripheral arterial occlusion might occur spontaneously in chronic heart failure, but the circumstances of this patient and our experience of cardiomyopathy led us to suggest that the vascular occlusion in this case was embolic in origin.

*Case 6.* This woman, aged about 45 years, died three weeks after her first admission to hospital. She had been ill at home for three months but came to hospital on account of severe left-sided chest pain with cough and hæmoptysis. On admission she was in congestive cardiac failure, but no cause was apparent. She suffered repeated episodes of dyspnoea, chest pain, and hæmoptysis, and developed bilateral pleural effusions: the effusion on the left was larger and was blood-stained. The clinical diagnosis was pulmonary embolism and cardiomyopathy. Her condition deteriorated rapidly and she died without having any signs of venous thrombosis in the legs.

At necropsy there was a large hæmorrhagic left pleural effusion. The heart was dilated and both ventricles and the right atrium contained adherent ante-mortem thrombus. Several pulmonary infarcts were present in both lungs. Infarcts were present in both kidneys and there was a large infarct in the spleen.

In this case the signs and symptoms of repeated pulmonary emboli overshadowed those of cardiomyopathy.

*Case 7.* This 34-year-old man was first admitted to hospital in June 1958, and was readmitted 5 times in congestive heart failure during the next three years. He consistently presented the clinical picture of cardiomyopathy, and the radiological and cardiographic evidence was in keeping with this diagnosis. During his fifth admission to hospital he suddenly developed weakness of the left side of the body, including the face, and left hemianæsthesia. These signs were thought to be caused by a vascular occlusion affecting the right cerebral hemisphere. These neurological signs improved rapidly. When he was readmitted to hospital six months later they were no longer present. During his final admission he was again in severe congestive cardiac failure and his deterioration was accentuated by several episodes of severe dyspnoea, abdominal pain, vomiting, and, on one occasion, he was reported to have passed blood in the stools.

One morning he was found to be mute and unresponsive with small pupils and weakness of the muscles supplied by the right third nerve. He died shortly afterwards without recovering consciousness. Though permission for necropsy was refused, we suspect that the repeated abdominal symptoms and the two neurological catastrophes were the result of recurrent embolization.

*Case 8.* This 21-year-old girl fell from her bed one night. Next morning she was found to be paralysed on the left side. Apart from the recent development of a cough she had been well previously. On admission to hospital she had a total hemiplegia on the left side with diminished appreciation of pinprick on that side. Her blood pressure was normal. There were no signs of congestive cardiac failure, but the heart was enlarged and there was a soft pansystolic murmur at the apex and a pronounced third heart sound was audible. The rhythm was regular and there were no signs to indicate bacterial endocarditis. Chest radiograph showed gross diffuse enlargement of the heart. The cerebrospinal fluid was normal and the Wassermann reaction negative.

After 6 weeks her neurological disability had improved and she was able to walk. Radiography showed considerable reduction in the size of the heart, and the previous auscultatory abnormalities disappeared. The clinical features and course of this patient were strongly suggestive of cardiomyopathy. This being so, the hemiplegia was probably the result of cerebral embolism. Reduction of the size of the heart and resolution of abnormal cardiac signs, with no treatment other than bed-rest, are not unusual in the earlier stages of cardiomyopathy.

## DISCUSSION

The occurrence of visceral infarction in cardiomyopathy in South Africa is, with the exception of cardiac failure, the most frequent complication of the disease. Hitherto this complication has been recognized and described mainly by pathologists. Becker *et al.* (1953) found infarction in 78 per cent of their cases, and in half of these more than one organ was affected. These authors state that "in the majority of these the cause was clearly embolic". Of the 12 cases studied by Higginson *et al.* (1952) 5 had evidence of peripheral emboli, and these authors list visceral infarction as one of the important pathological features of the condition. In a further survey of the pathology of "cryptogenic heart disease" Higginson *et al.* (1960) found intraluminal cardiac thrombi in 60 per cent and visceral infarction involving the lungs, kidneys, spleen, and brain in 35 per cent of their series of 80 cases. Intracardiac thrombosis and embolism are also features of the endomyocardial fibrosis of East Africa. Shaper and Wright (1963) have analysed its occurrence in necropsy material and compared this with its incidence in the South African cardiomyopathy. It appears that both thrombosis and embolism are more frequent in the latter condition, and the clinical occurrence of embolic phenomena in endomyocardial fibrosis is rare.

In our experience it is unusual not to find evidence of visceral infarction in a patient dying of cardiomyopathy. While this is well recognized pathologically the cases described above illustrate some more florid clinical effects of embolism and infarction. Unless one is aware of the possibility one might be tempted to seek a second diagnosis to explain the complication, or less correctly, to attribute the cardiac disorder to the infarction. Had Case 1, for instance, presented initially at a time corresponding to her eighth admission to hospital her cardiac disorder would probably have been ascribed to coronary thrombosis, however unlikely in this age-group, sex, and race. Similarly, repeated pulmonary embolism may mask the original cardiac disease and even produce clinical evidence of pulmonary hypertension.

Becker *et al.* (1953) reported that infarcts occurred in the lungs, kidney, spleen, and brain in that order of frequency. This statement accords with our pathological findings. Clinically, however, infarction of the spleen and kidneys is not easily recognizable. We suggest that infarction of abdominal organs provides an explanation of the episodes of abdominal pain and tenderness, hypotension, sweating, and peripheral vascular failure that have been observed in these cases, especially in the later stages. That embolism is not confined to the terminal phase of the disease is illustrated by Case 8, in which a presumed cerebral embolism was the first manifestation of cardiomyopathy.

It seems reasonable to infer that visceral infarction originates from emboli derived from the mural thrombus. Another possible explanation may be primary thrombosis conditioned by stasis or increased coagulability of the blood. That chronic cardiac failure is not the sole cause is illustrated by the fact that visceral infarction occurs more frequently in cardiomyopathy than in any other form of chronic cardiac disease. Primary arterial thrombosis is not likely to occur in the age-group in which cardiomyopathy prevails, and advanced atherosclerosis is exceptionally uncommon in this race and age-group. Of the arrhythmias that occur in association with cardiomyopathy atrial fibrillation is one of the least common.

Considering the great frequency of visceral infarction and the associated circumstances we feel that causes other than embolism from cardiac thrombus are never likely.

## SUMMARY

Evidence of visceral infarction is one of the common pathological findings in patients dying of cardiomyopathy in South Africa. Cases are described that illustrate that such infarction may become recognizable during the clinical course of the disease. In such cases the clinical effects of infarction of the myocardium, lungs, spleen, kidneys, or brain may overshadow the primary cardiac disease and confuse the diagnosis. It is suggested that the infarction is embolic in origin, emboli originating from mural thrombus in the chambers of the heart.

We thank Dr. D. Ranking, Medical Superintendent, for permission to publish.

#### REFERENCES

- Becker, B. J. P., Chatgidakis, C. B., and van Lingen, B. (1953). Cardiovascular collagenosis with parietal endocardial thrombosis. *Circulation*, **7**, 345.
- Cosnett, J. E. (1962). Heart disease in the Zulu: especially cardiomyopathy and cardiac infarction. *Brit. Heart J.*, **24**, 76.
- Higginson, J., Gillanders, A. D., and Murray, J. F. (1952). The heart in chronic malnutrition. *Brit. Heart J.*, **14**, 213.
- , Isaacson, C., and Simson, I. (1960). The pathology of cryptogenic heart disease. *Arch. Path.*, **70**, 497.
- Shaper, A. G., and Wright, D. H. (1963). Intracardiac thrombosis and embolism in endomyocardial fibrosis in Uganda. *Brit. Heart J.*, **25**, 502.