

GIANT BULLOUS CYSTS OF THE LUNG*

BY

P. R. ALLISON

Leeds

[For Plates see pages 181-186]

Emphysematous bullae of the lung may be single or multiple; they are usually of pathological interest rather than of clinical importance, except when they rupture into the pleura and cause a tension pneumothorax. They are an expression of underlying bronchial disease, either in the form of inflammation or scarring, whereby air passes during inspiration into the area of lung supplied by the bronchus or bronchiole more easily than it can escape during expiration. Over-inflation, occurs, with the formation of an air cyst, and it is possible that pleural adhesions may play a part; this point will be considered later. Observations on a very few patients led to the idea that these cysts might themselves give rise to symptoms apart from any disability for which their initial cause might be responsible.

DYSPNOEA CAUSED BY EXTENSIVE CYSTIC CHANGES IN THE LUNGS

If the cyst formation is extensive the patient may die of asphyxia because there is not enough normal lung tissue left to supply his respiratory needs. Much of the lung may be replaced by cysts and the rest is compressed by them. Such a patient has been observed by Dr. Hoyle and Mr. Barrett (personal communication).

Case I.—A man aged 39 years had complained of dyspnoea for many years. He had had periodic attacks of coughing but had never had any sputum. He was admitted to hospital and, on examination, was found to be short of breath at rest in bed and slightly cyanosed. He had signs of gross emphysema at both bases but no adventitious sounds. A radiograph of the chest showed that the lower halves of both lungs were almost replaced by air cysts, and iodized oil failed to enter these areas (Plate *1a*). He was under observation and various forms of treatment for some time. He had numerous attacks of paroxysmal tachycardia and Cheyne-Stokes respiration, and in one of these he died. A post-mortem examination showed an extremely emaciated patient with no abnormality apart from the thoracic viscera. A few pleural adhesions were present on the left but none on the right. Both lungs contained a number of cysts or bullae which were distended with air, and a number of smaller cysts distended with mucus (Plate *1b*). There were three principal cystic spaces, one in the right lower lobe, another in the right middle lobe, and a third in the left lower lobe. The one in the right middle lobe lay in front of the pericardium and might conceivably by its pressure have been responsible for the attacks of paroxysmal tachycardia.

*Based on a communication to the Association for the Study of Diseases of the Chest in January, 1947.

SYMPTOMS CAUSED BY DISTENSION OF INDIVIDUAL CYSTS

There are other ways in which air cysts may cause symptoms. They may become infected and need draining, they may cause dyspnoea by virtue of the tension within them, or they may cause pain. The way in which these things happen is a matter for speculation, but some hint of a possible explanation was given in the history of one of the patients.

Case 2.—The patient, who was a man, had had a cough with a little sputum for many years and had been supposed to have either chronic bronchitis or mild bronchiectasis. At rest he had no symptoms, but bending, digging, cycling, or running caused a catch in his breath, belching, and a feeling of fulness in the right base and axilla. This disability had started two years previously. One morning when he was getting out of bed he had felt a sudden but not very severe pain through the middle of the right side of his chest which had caused a fit of belching. The striking features of his complaint were the sudden onset, the recurrence of symptoms with increased respiratory effort, especially in a bending position, the relation to belching, which was probably a reflex vagal phenomenon, and the patient's accurate description of the nature of his trouble as being a collection of wind under tension in the right lower part of his chest which prevented his taking a deep breath.

The Hering-Breuer theory of the nervous control of respiration suggests that the limits of inspiration and expiration are regulated by the tension within the lung structure and that the afferent impulses reach the respiratory centre through the vagus nerves. Although the field of reception has been extended to the respiratory muscles themselves, it is still generally accepted that proprioceptive impulses from the lungs, through the vagi, play a part in regulating the depth of respiration. If the tension in the lungs is not uniform it is debatable whether the stimulus would arise from some mean tension, or if perhaps that part under the greatest tension would act as the governor. The approach to the disability now under review was based on an assumption that an isolated area of lung which was over-inflated could, through nervous influences, limit the depth of respiration and so cause dyspnoea on exertion. That it may cause a stitch-like pain seems likely from the histories of these patients. Other reflex effects, particularly belching, may be observed. If the cyst were so small that its effect was mainly a nervous limitation of respiration, treatment directed towards reducing its inflation might suffice, and it was on this basis that the second patient described in this paper was treated.

His history has already been given. No abnormality was detected on physical examination. There was, on the radiograph, an area of distended lung in the right costo-phrenic angle corresponding to the anterior axillary segment of the right lower lobe (Plate IIa). Iodized oil failed to enter this segment of lung, and an obstruction to the small bronchus was noted (Plates IIb and IIIa). Some congestion of the mucous membrane of the bronchi of the right lung was seen on bronchoscopic examination. A little mucopurulent secretion was present, and bacteriological examination of this gave a scanty growth of green and haemolytic streptococci. It was thought that the piston-like action of the diaphragm would play a large part in inflating this segment of lung and that a right phrenic crush might relieve his symptoms. This was done on May 22, 1943, with immediate and complete relief from

pain and dyspnoea. Screening showed that the right dome of the diaphragm was paralysed. The patient underwent his operation with the full knowledge that it was experimental. He was extremely pleased with the result, but, to eliminate the psychological element as far as possible, he was not told that the paralysis was temporary. He remained free from symptoms for just over four months. He reported back after five months because he had had a return of symptoms during the previous three weeks. His pain was felt a little higher in the axilla than before his operation, and belching was not so marked. The recovery of his diaphragm was confirmed by screen examination. The right phrenic nerve was avulsed in October, 1943, and he has remained well since.

If further observation confirms the impressions from this case an important paradox will have been established, for it seems that an operation which paralyzes part of the respiratory mechanism may increase respiratory function. It has not been possible to undertake detailed investigation of the hypothesis, but the following experience lends some support to it.

Case 3.—A man of 53 years, who had had a cough with thick yellow sputum for twenty years, complained that for two or three years he was becoming increasingly short of breath. Although he was always dyspnoeic with gentle walking, he had attacks when the dyspnoea was much worse and at these times he felt a pain in the right side of the neck coming down over the right shoulder. He had poor movement of the chest, scattered moist sounds throughout, and diminished air entry at both bases, particularly the right. He obviously had generalized bronchitis, but radiography showed that in addition he had bullous cysts at both bases (Plate III*b*). Bronchoscopic examination revealed congestion of the respiratory mucous membrane throughout and a moderate amount of muco-pus which was sterile on culture. The disease was so extensive and the condition of the patient so poor that excision of the cysts was not practicable. The attacks of dyspnoea, combined with pain in the right shoulder which was thought to be a referred pain along the phrenic nerve, suggested that a paralysis of this nerve might give symptomatic relief, as in the second patient.

He was placed on the operating table in the position for operation and his vital capacity measured. The best of three readings was 1,700 ml. Under a local anaesthetic the right phrenic nerve was crushed and the readings repeated, when the vital capacity was found to have risen to 2,300 ml. This was accompanied by a subjective improvement, for he felt that he could fill his chest more freely. His cough and sputum persisted, but his breathing improved and his pain disappeared. On a course of expiratory breathing exercises his vital capacity went up to 2,600 ml. The improvement lasted for six months, when the phrenic nerve recovered. Avulsion of the nerve again improved him, but soon afterwards he died at home from coronary thrombosis so that long observation was not possible.

Case 4.—The fourth patient was a woman of 35 years who for nine months had complained of a gripping pain low down in the axillary part of the left side of the chest and passing up in front as far as her throat. The pain came on in attacks, "took her breath away," and made her left arm go blue. She had a slight cough but no sputum. She herself described the condition as "wind round her heart." The only abnormality detected on physical examination was an area of hyper-resonance and diminished breath sounds at the left base. The postero-anterior film of her chest showed no gross abnormality, but on the left lateral view a bullous cyst was seen at the base; it was surrounded by some condensed lung tissue (Plate IV*a*). Iodized oil failed to enter the affected area but confirmed the compression of the surrounding lung (Plates IV*b* and V*a*). Her vital capacity in the sitting position as measured on a closed circuit spirometer was 2,400 ml. Bronchspirometry with

the patient recumbent and breathing through the double bronchoscope gave a total reading for vital capacity of 1,800 ml., of which the right lung accounted for 1,200 ml. and the left for 600 ml. The oxygen absorption per minute of the right lung was 130 ml., and that of the left 66 ml.; the tidal air volumes were 270 and 150 ml. respectively.

Left thoracotomy was performed and the cyst found to occupy practically the whole of the lower half of the pleural space. There was a dense band of adhesions stretching horizontally across it between the axillary part of the cyst and the posterior chest wall close to the spine (Plate Vb). Although the original intention had been to excise the cyst, this object was abandoned when the lower lobe was seen as a flat and airless structure stretched over the mediastinal side of the cyst, and a left lower lobectomy was performed. The patient recovered and remained free from symptoms.

A year later her vital capacity sitting was 2,300 ml., she could run to catch a bus without being short of breath, and she did all her own housework. It was hoped to do another bronchspirometry, but she was so well and so busy that she declined, and it was not felt legitimate to urge this.

This last operation turned out to have been unnecessarily drastic, but it did provide a specimen which was a useful clue to the aetiology (Plate VI, *a* and *b*). The lobe was inflated with formalin and cut after fixation. When a probe was passed towards the base of the lobe a small bronchus was seen to run in the medial wall of the cyst tangentially. In the lateral wall of this bronchus was a small tear opening into the cyst itself. A short distance below this the section of the lobe passed through and divided the bronchus. Inspection of this specimen makes it easy to see how inspiration can draw air into the cyst and expiration cause compression of the bronchus running along its wall to prevent escape of air.

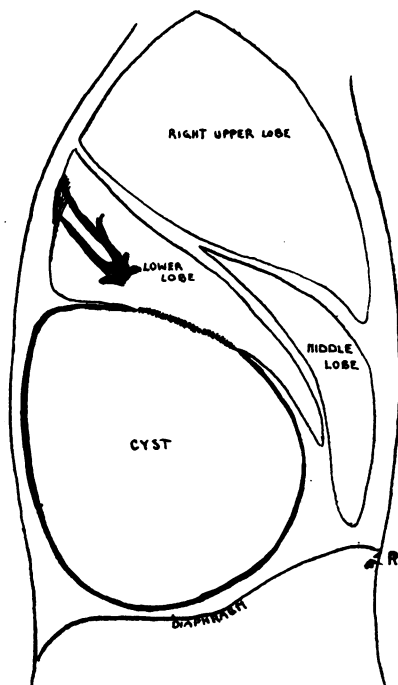
It seems that the rational treatment for a lesion such as was found in Case 4 would be to excise the greater part of the wall of the cyst and stitch up the leaking bronchus. This was done on the fifth patient.

Case 5.—A man of 42 years, a physical training instructor in the Army, had been unable to carry out his duties for five months because of a pain in the right side of the chest when he shouted. He had no cough and was not short of breath. Two years previously he had been in a military hospital for one week because of a "creaking feeling" in the right side of the chest when he inspired, and a year after this he had been off work with an influenza-like illness and cough from which he fully recovered. His radiographs taken in the Services are not available, but they showed a huge emphysematous cyst occupying the lower half of the right side of the chest. It seemed to be an isolated lesion and was therefore removed. When the right side of the chest was opened the cyst presented in the wound and occupied the whole of the lower half of the pleural cavity. It arose from the diaphragmatic aspect of the right lower lobe, to which it was closely adherent over an area about 5 cm. in diameter. It was also adherent to the middle lobe, diaphragm, posterior chest wall, and the rim of the basal part of the lower lobe. The posterior part of the lower lobe was bent upon itself by the pressure of the cyst below, so that the inferior margin, to which the cyst was adherent, was displaced upwards and firmly bound to the dorsal lobe by dense adhesions (see fig.). The depressed part of lung between was completely collapsed. When the adhesions were divided the lobe could be straightened out and this area inflated normally.

The cyst was removed by dividing its adhesions to the edges of the lobes and then cutting the cyst wall round its attachment to the diaphragmatic surface of the lower lobe. Normal saline solution was then poured into the pleura to submerge the lower lobe, and, as the anaesthetist applied positive pressure, the leak in the lung was located by the escape of bubbles. A mattress suture of fine catgut was inserted to enclose the hole in the bronchus, and when this was tied the escape of air ceased. The chest was closed with a temporary underwater drain, and the phrenic nerve was not paralysed. His recovery was uneventful, and two months later he was fit and free from symptoms. The excursion of his chest wall and diaphragm were normal and he could perform any exertion without discomfort.

It seems likely that emphysematous bullous cysts arise as a result of some over-exertion such as coughing, shouting, or digging, in the presence of an inflamed or ulcerated bronchus, so that rupture occurs at the weak point. For this reason it is not surprising to find them in association with bronchiectasis. In such circumstances the treatment is primarily that of bronchiectasis, but if lobectomy is being performed it is worth while to remove such a cyst at the same time, in order to improve the respiratory function after operation, as the following example suggests.

Case 6.—A man aged 31 years had had a cough with very little sputum since pneumonia at the age of 13 years. During the war he was engaged in very heavy work as a spring-smith and had become progressively more and more short of breath. He also complained of a tight feeling at the base of the chest on the right side. Examination showed that he



Operation sketch to show how the distension of a cyst in the presence of adhesions may distort the lung and kink bronchi. The margin of the basal lobe is displaced upwards and has become adherent to the dorsal lobe.

TABLE
BRONCHOSPIROMETRIC READINGS BEFORE AND AFTER EXCISION OF COLLAPSED RIGHT LOWER
AND MIDDLE LOBES AND BULLOUS CYST OF UPPER LOBE

	Before operation			After operation		
	Left lung	Right lung	Total	Left lung	Right lung	Total
O ₂ absorption in ml. per minute	180	50	230	150	160	310
Tidal air in ml.	170	150	320	120	170	290
Vital capacity in ml.	1,200	1,000	2,200	1,200	800	2,000

had complete collapse of the right lower and middle lobes—which were replaced by cystic bronchiectatic spaces—and a large emphysematous cyst of the upper lobe. Pre-operative bronchspirometry showed that the right lung was responsible for slightly more than one fifth of the total oxygen absorption (see Table).

At operation the collapsed lower and middle lobes were almost completely concealed by the cyst, which had arisen in the pectoral segment of the upper lobe and extended downwards and forwards over the middle lobe and then downwards and backwards over the lower. The cyst was therefore bent on itself to form what, on the surface, appeared as an interlobar fissure. The cyst, together with the lower and middle lobes, was removed and the right phrenic nerve crushed to prevent over-distension of the upper lobe. The patient recovered and was symptomatically much improved by his operation. Post-operative bronchspirometry showed that the right lung had taken on half the total respiratory function as measured by the oxygen uptake.

DISCUSSION

Numerous examples of emphysematous bullous cysts have been observed, both large and small, which caused no symptoms and therefore required no treatment. They may arise either by stenosis of a small bronchus or bronchiole and over-distension of the lobule of the lung supplied by this, or by ulceration of the wall of such a bronchus with the escape of air into the interstitial tissue of the lung. When the cyst is large such a distinction is unimportant. Their walls are lined partly by collagenous fibrous tissue and partly by cuboidal epithelium, which might occur with either method of formation. They can easily be mistaken for a localized pneumothorax. The distinction may be impossible on clinical or radiological grounds, but in general it may be said that if the air shows no tendency to absorb, and if it gives rise to persistent symptoms, the lesion is more likely to be a bullous cyst than a pneumothorax. An attempt at differential diagnosis should never be made with a pneumothorax needle; from the very nature of these cysts they must have a valvular bronchial communication, and if their wall is pierced with a needle a tension pneumothorax is almost inevitable. The leak from the bronchus is so small and so slow that the symptoms of tension pneumothorax are not likely to appear immediately. In four patients in the present series needling was performed at some stage, and in all a tension pneumothorax developed, the symptoms of which became acute one day, three days, four days, and a week later. The slowness of the leak, and its occurrence on forced expiration only, was confirmed by the operative findings in one patient where the cyst was removed and the leak located by submerging the lobe in saline solution.

It is unlikely that pleural adhesions play any part in the formation of cysts, for in the first patient referred to there were none on the right side. When the cyst has once started, however, they may determine the direction in which it enlarges and the effect this has on the surrounding lung. The unimpeded expansion of a cyst causes compression of the adjacent lung tissue, but adhesions may,

in addition, distort it and so kink the bronchi that obstructive emphysema or collapse occurs in other areas. It may be said that, whilst the formation of the cyst depends on changes in the bronchial wall, secondary effects reducing respiratory function may be produced by pleural adhesions.

SUMMARY

1. Bullous distension cysts of the lung are caused by inflammation with valve stenosis of a small bronchus, or by ulceration and perforation of the lateral wall. There is usually a previous history of acute or chronic respiratory illness. They may be single or multiple.

2. They probably grow very slowly, so that if the leak is into the interstitial tissue of the lung there is time for the air to become encysted rather than to produce generalized surgical emphysema.

3. They may produce dyspnoea, either by lung replacement and compression, as happens when the change is extensive, or, when the change is less severe, by nervous inhibition of the depth of respiration. In the latter case it is supposed that a focus of increased tension in the lung acts as a governor to the Hering-Breuer reflex.

4. In addition to dyspnoea they may cause pain or reflex vagal disturbances, or they may become infected.

5. Surgical treatment, where necessary, may be along three lines: phrenic nerve crush in the small basal lesion, and, if successful, later phrenic avulsion; excision of the cyst and suture of the bronchial opening where the cyst is large and causing compression collapse of neighbouring lung; excision and lobectomy when the cyst occurs either in or adjacent to a bronchiectatic lobe.