

THE REMOVAL OF A HYDATID CYST FROM THE WALL OF THE LEFT VENTRICLE*

BY

A. L. d'ABREU

From the Queen Elizabeth Hospital, Birmingham

(RECEIVED FOR PUBLICATION AUGUST 18, 1950)

On January 16, 1950, Dr. Jenkins, of Llandrindod Wells, sent me a patient, a woman aged 50, whose case proved most interesting.

CASE REPORT

Two years before, during the course of a successful cholecystectomy performed elsewhere for calculous disease, a large hydatid cyst of the spleen was seen, but, because of dense diaphragmatic adhesions, splenectomy was not done. Eighteen months later the patient had a small haemoptysis, and this led to a radiographic examination of the chest (Fig. 1). Because a cyst existed elsewhere and there had been haemoptysis, the radiographic appearances suggested a diagnosis of pulmonary hydatid cyst.

When admitted to the Queen Elizabeth Hospital she was a well-nourished woman of healthy appearance. She had an irritative cough which had produced small quantities of blood every week for the two previous months. The sputum examination failed to reveal tubercle bacilli or scolices. A large mass was palpable beneath the left costal margin and had the characteristic features of an enlarged spleen but without a palpable notch. She complained of persistent pain in the splenic area. The maximum cardiac impulse was in the mid-clavicular line in the fifth left interspace. The cardiac dullness was increased to the left of the sternum, and no other abnormal physical signs were detected in the chest. The pulse rate was 82, the cardiac rhythm was normal, the heart sounds were pure and without adventitious elements. The blood pressure was 140/90. The electrocardiogram (Fig. 3) showed an inverted T wave in standard lead I. The sinus rhythm was regular (94), P.R.=0.23 (long).

The intradermal Casoni test gave a moderate positive reaction. The blood picture revealed a secondary anaemia of minor degree with no increase in the eosinophil count.

Red blood cells	3,700,000
Haemoglobin	74%
Colour index	1.00
White blood cells	7,500

Differential Counts

N. polymorphonuclears	66.3%	4,972 per c.mm.
Eosinophils	1.7%	127 per c.mm.
Basophils	—	—
Lymphocytes	29.0%	2,125 per c.mm.
Monocytes	3.0%	225 per c.mm.
Unidentified cells	—	—

Stained films showed slight anisopoikilocytosis.

Platelets appeared normal.

* A communication to the Thoracic Society at its meeting in Bristol, July 14, 1950.

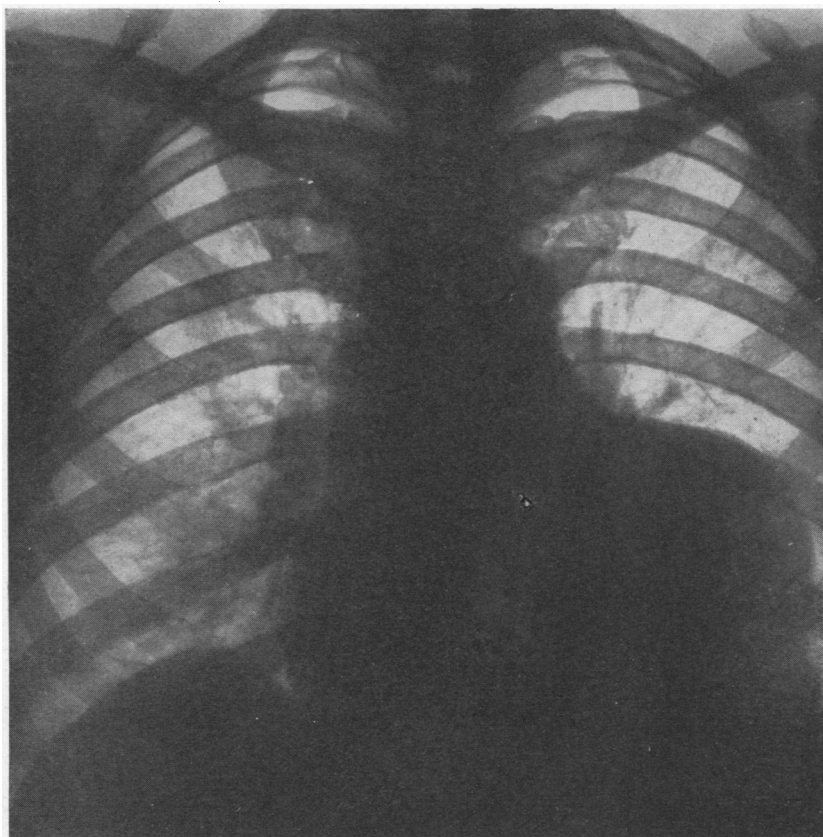


FIG. 1.—Postero-anterior radiograph showing outline of shadow continuous with cardiac border, and slight accentuation of vascular markings of the right lung.

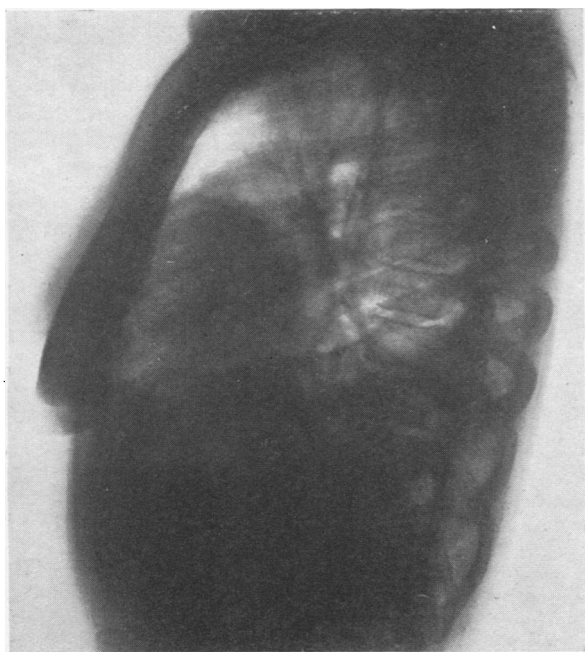

FIG. 2.—Lateral view (left).

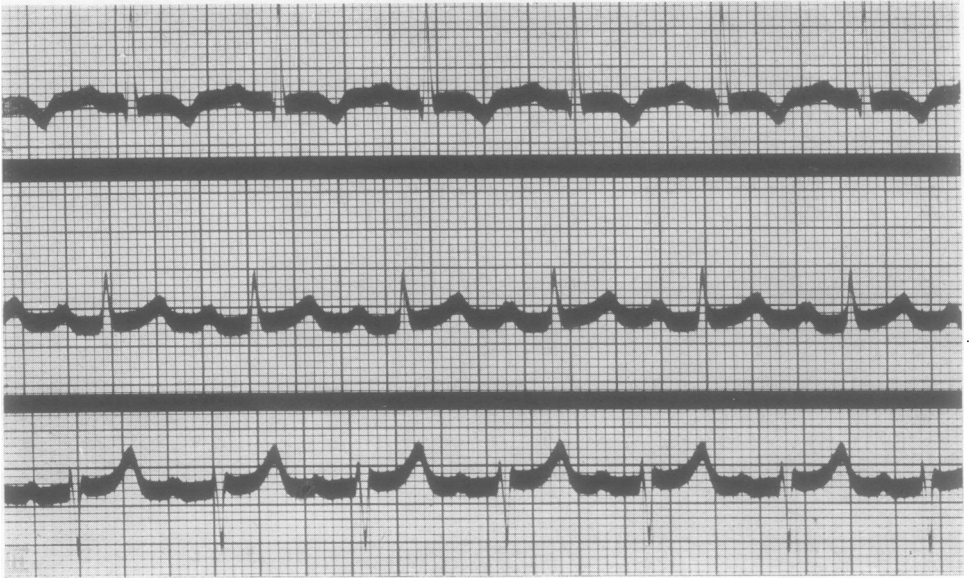

FIG. 3.—Electrocardiogram.

The sputum, which consisted largely of frothy mucus, contained red blood cells: but no tubercle bacilli and no scolices were found. Culture of the sputum gave a growth of *Streptococcus viridans*.

Radiological Features.—The postero-anterior view (Fig. 1) disclosed a large ovoid mass continuous with the left border of the cardiac outline. The vascular markings of the right lung were considered to be accentuated. The right dome of the diaphragm was elevated and aroused the possible suspicion that a cyst might be present in the right lobe of the liver.

By cardiac screening Dr. Harold Black demonstrated transmitted pulsation in the shadow which was continuous with the heart outline in all positions. The mass in the oblique and lateral views was situated mostly over the area of the left ventricle (Fig. 2). In spite of the radiological evidence that favoured a pericardial or cardiac cyst, the persistent haemoptysis remained a puzzle, and I was quite prepared to find that at operation the cyst would in fact prove to be pulmonary in origin.

The Pre-operative Plan.—This was a little disturbed by the patient's insistence that her continuous left upper abdominal pain would be relieved only by a splenectomy. It was felt, however, that the chief danger to life lay in the cardiac or pulmonary cyst. It was hoped that if the cyst proved to be pulmonary its eradication by Barrett's manoeuvre (Barrett, 1949) might be simple and satisfactory enough to permit a trans-diaphragmatic splenectomy to be done at the same operation, but the patient was warned that two operations would almost certainly be required. Against this background there also existed an uneasy feeling concerning the "hump" of the right diaphragmatic leaf. The horrifying sequelae to cardiac hydatid cysts described in the literature determined the order of priority of the surgical procedures.

Operation.—On January 20, 1950, under intratracheal anaesthesia (Dr. Murtagh) the left chest was opened through the bed of the resected sixth rib. An adhesion-free pleura enabled a rapid examination of the left lung to be made, and it seemed normal in all

respects. A large bulge in the pericardium posterior and to the left of the left phrenic nerves and vessels was obvious. This showed transmitted, but no expansile, pulsation, and a possible diagnosis of cardiac aneurysm was considered in spite of a history that lacked the features of any preceding attack of coronary thrombosis. Professor Melville Arnott, who was in the theatre, refused to accept the idea of an aneurysm; Dr. Paul Davidson suggested that it might be a myoma of the heart wall; all agreed to an exploration of the pericardium, which was opened widely in front of the left phrenic nerve. There was an excess of pericardial fluid, but no adhesions. In the wall of the left ventricle a glistening, pearly white area, the size of a florin, gave a similar appearance to that seen on the visceral pleura overlying a pulmonary hydatid cyst. The diagnosis was obvious and the need for excision of the cyst was clear.

The pericardial incision was enlarged sufficiently to enable a hand to be placed behind the heart if the need for this should arise. Moist saline packs were so placed that only the area of the ventricular wall containing the cyst remained exposed. The swelling in the heart wall reached to the auricular-ventricular groove, and the descending branch of the coronary artery in the interventricular groove was obscured by the tumour. Gauze wrung out in 10% formalin was then laid on the previously placed saline pads. The thickened epicardium over the cyst was incised carefully and the capsule exposed. Then, taking considerable care to avoid any risk of spill or contamination, a fine bore needle mounted on a syringe was inserted into the true cyst, which partially collapsed when it was half emptied, and, the needle being withdrawn, the small hole in the cyst was closed with a mosquito artery forceps. The incision in the adventitia was then enlarged by blunt dissection with small pledgets mounted on artery forceps and the semi-flaccid cyst removed intact without difficulty, as it separated readily from the wall of its false capsule (Fig. 4). When distended post-operatively the cyst measured 6 × 4 cm.

The capsule of the cyst and the pericardium were left widely open and the chest closed in layers without drainage, the lung being fully reinflated and all intrapleural air withdrawn from the pleural cavity.

Dr. A. L. Peeney recovered scolices from the fluid in the cyst which on histological examination showed a typical outer basophilic laminated cuticular membrane to which fragments of an inner nucleated germinative membrane adhered (Dr. Kenneth Walton).

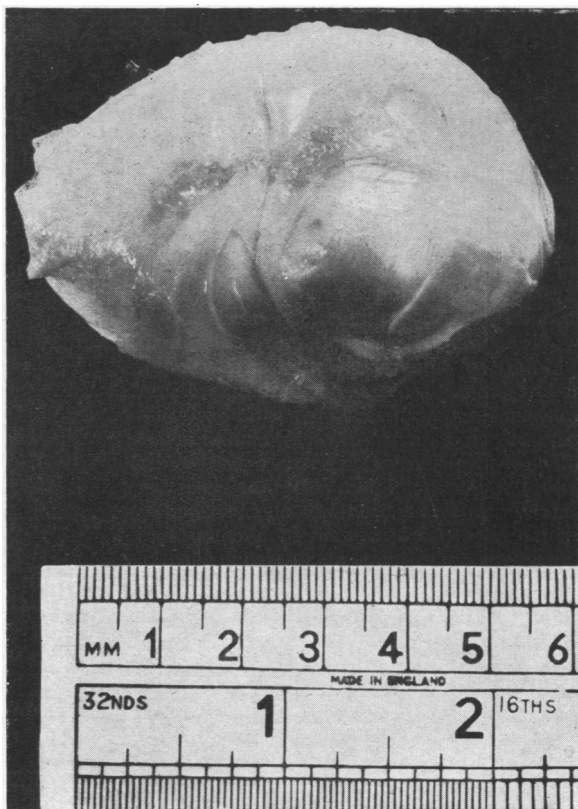


FIG. 4.—Photograph of the removed cardiac hydatid cyst.

Convalescence.—A blood transfusion of 1½ pints, started in the theatre, was continued in the ward to correct the pre-operative anaemia.

During the post-operative night the pulse was irregular, but resumed a normal rhythm the next morning, when the general condition was good. Periodically for a few days extra-systoles were noted. The chest was aspirated on three occasions, 25 oz. of blood-stained fluid being removed in all. The lungs remained aerated throughout the post-operative period and the patient was allowed up on the eighth day. The haemoptysis, which had been a constant pre-operative feature, ceased, and there has been no recurrence in the first post-operative months. The cause of this haemorrhage remains unexplained, and there is no radiological or clinical evidence to supplement a presumption that it may have been due to small blood clot emboli from the right ventricle, nor is there radiological evidence of small hydatid cysts in either or both lungs. If there has been any pulmonary hypertension I am at a loss to explain its aetiology or to offer any reasonable explanation for the disappearance of the haemoptysis.

Splenectomy.—The patient was readmitted to the Queen Elizabeth Hospital on May 3, 1950. Her general condition was good. An electrocardiogram showed a persistence of the T wave inversion. The Casoni reaction was still positive. Radiological examination showed a spherical swelling, much smaller than the original tumour, in the site of the removed cyst. The persistence of a peri-cyst presumably filled with fluid is not unexpected, as similar, though usually air-filled, spaces are common after the removal of hydatid cysts from the lung.

On May 5, 1950, the left chest was reopened. The left lung was adherent to the previous operative area in the pericardium, and no attempt was made to separate the area of fusion. The incision through the bed of the resected eighth left rib was carried on into the abdomen, the diaphragm split, and the spleen, containing a huge univesicular

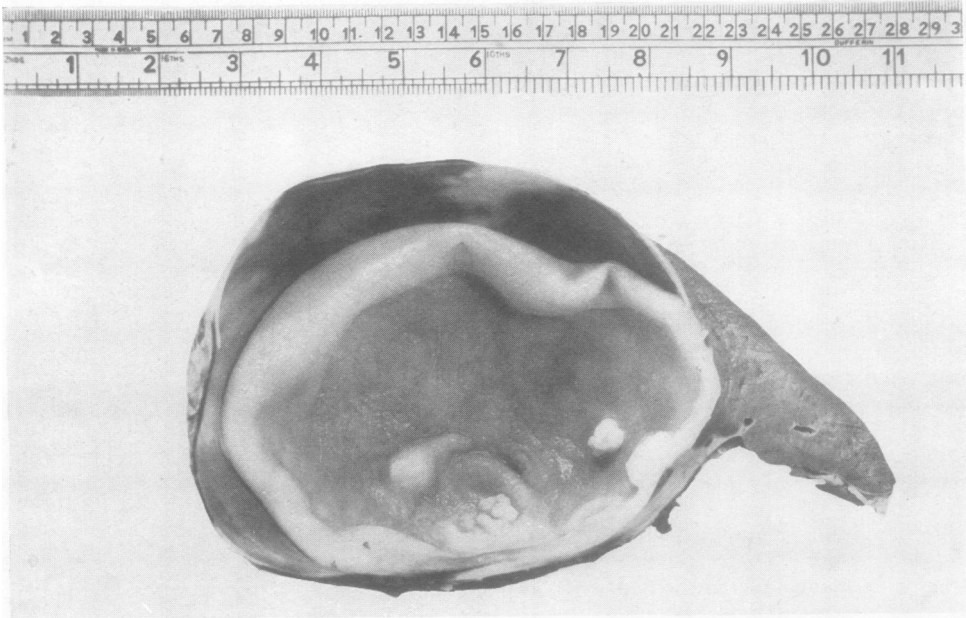

FIG. 5.—Specimen of removed spleen showing contained hydatid cyst.

cyst, was removed (Fig. 5). At the same time a full examination of the liver was made, but no cysts were present. The patient recovered uneventfully from this operation, was up on the sixth post-operative day, and remains in excellent health.

DISCUSSION

The Incidence of Cardiac Hydatid Cysts.—Many hydatid cysts of the heart have been described, and the most recent paper that I have been able to trace is that of Opokin and Kolju (1935), who collected 43 patients with cardiac or pericardial involvement. This clearly does not account for all the patients recorded and omits some Australian examples.

Not unexpectedly Australian surgeons provide much information, but I was pleased to read (Marten, 1921, quoting Thomas, 1894):

“I thought it might be of some interest to you if I reported a case of hydatid disease of the heart, not only because it is a case of great rarity even in this country (Australia) but . . .”

In the last decade of the nineteenth century Davies Thomas (quoted by Marten, 1921) collected 48 cardiac hydatids and stated that in 2,000 cases of echinococcal disease the heart and organs of circulation were invaded in 1.845%. Most of the recorded patients with heart hydatids died suddenly.

Anderson and Patterson (1924) described a fatal case in which post-mortem examination showed echinococcal cysts in the brain, spleen, kidney, and one in the left ventricle of the heart which had ruptured into the ventricular cavity. In summing up the clinical and pathological complications of cardiac hydatids they describe fibrillation, sudden death, paroxysmal attacks of dyspnoea and pain, rupture into the cardiac chambers and into the pericardium: such ruptures usually caused sudden death. Pulmonary hydatid embolisms were recorded by Rokitansky (1852), Stirling (1879), and others.

Dévé (1916) reported 10 patients in whom the original cyst had apparently ruptured more than once into the cardiac cavities. Degeneration and calcification of the cysts have been noted (Rokitansky, 1852; Goodhart, 1876; and others). From the confirmed accounts, in many of which accurate localizations of the cysts are not given, the right ventricular wall appears to be the commonest site. Calvert (1903) found that most accounts placed the cyst in the right ventricle, either beneath the endocardium or in the heart muscle. He said that, although rupture was the commonest cause of sudden death, this might occur with unruptured cysts. A specimen of such a cyst is in the museum of St. Bartholomew's Hospital, London. Goodhart (1876) in the pleasant language of his time described a “cured” cyst of the wall of the heart seen at necropsy in a young man of 20 who fell down dead in a stable in Portman Market:

“When the adherent pericardium was stripped from the wall of the left ventricle an abscess cavity was opened, from the wall of which hooklets were found.”

Most of the necropsy reports were made on subjects of sudden death, and I am pleased to have had the opportunity to perform a technically simple operation which I hope has decreased the risk of sudden death in the patient.

Surgical Treatment.—No description of the surgical removal of a cyst from the heart itself has been discovered in the literature. Opokin and Kolju (1935), reporting hydatid involvement of the heart or pericardium, recounted the successful removal of a cyst invading the pleura and pericardium. In the literature attempted cure by blind aspiration here, as elsewhere, seems to have been followed invariably by disastrous results. If the condition is diagnosed the logical treatment, in view of the great dangers of sudden heart failure and of hydatid embolism, is surgical removal, and the outcome in the patient reported is at least an encouragement for this course. At the time of writing the patient is well after her subsequent splenectomy, and this account is to present what I think may be the first successful removal of a hydatid cyst from the heart.

REFERENCES

- Anderson, A. V. M., and Patterson, S. W. (1924). Supplement to *Med. J. Aust.*, 1, 41.
Barrett, N. R. (1949). *Lancet*, 2, 234.
Calvert, J. (1903). *St Bart's Hosp. Rep.*, 29, 207.
Dévé, F. (1916). *C.R. Soc. Biol., Paris*, 79, 514.
Goodhart, J. F. (1876). *Trans. path. Soc., Lond.*, 27, 72.
Opokin, A., and Kolju, K. (1935). *Arch. klin. Chir.*, 181, 697.
Rokitansky, C. (1852). *Manual of Pathological Anatomy*, vol. 4, p. 208. London: Sydenham Society.
Stirling, R. (1879). *Aust. med. J.*, n.s., 394.
Thomas, D. (1894). Quoted by Marten, R. H., *Med. J. Aust.*, 1921, p. 287.