

## RHEUMATOID ARTHRITIS WITH LUNG LESIONS

BY

J. R. EDGE AND A. G. RICKARDS

*From High Carley Hospital, Ulverston, and the Royal Infirmary, Lancaster*

(RECEIVED FOR PUBLICATION JULY 19, 1957)

Since the original reports of Ellman (1947) and Ellman and Ball (1948) a further 52 cases of pulmonary involvement in rheumatoid arthritis have been described, making 56 in all. In 15 the rheumatoid lesions were associated with pneumoconiosis, but in the remaining 41 there was no evidence of previous exposure to dust. In only four of these cases was the diagnosis established by lung biopsy during life (Rubin, 1955; Ellman, 1956); it is the purpose of this paper to describe two cases of pulmonary disease in rheumatoid arthritis in which biopsy revealed chronic pneumonitis characterized by patchy fibrosis and intense infiltration with chronic inflammatory cells. Although these pathological appearances are not specific they bear a close resemblance to the pathological findings in previously reported cases of pulmonary involvement in rheumatoid disease and it appears not improbable that they represent an inflammatory reaction of rheumatoid type.

### CASE REPORTS

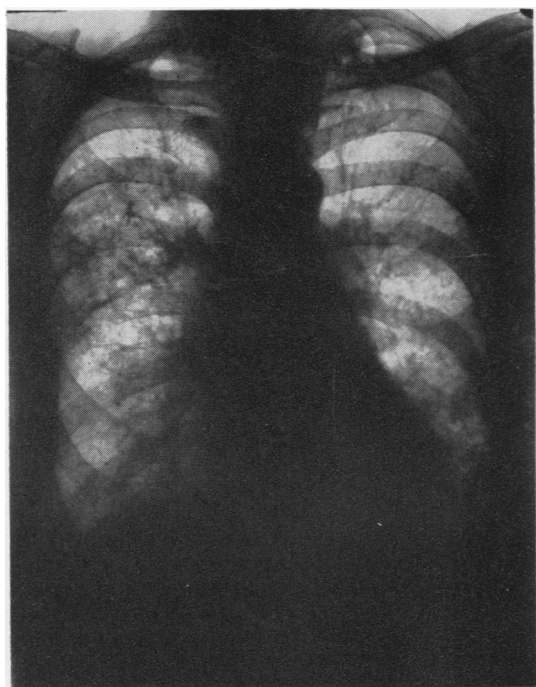
CASE 1.—A retired male clerk, aged 65 years, was admitted to hospital in March, 1957, for repair of an inguinal hernia. He complained of progressive painful swellings of the small joints of the hands and feet during the preceding 12 months, but denied respiratory symptoms. A left-sided empyema thoracis had been successfully treated by drainage 12 years previously. Physical examination showed finger clubbing, with ulnar deviation of the fingers of both hands and spindle-shaped deformities characteristic of rheumatoid arthritis; radiographs of the hands and feet revealed typical rheumatoid changes; no other joint was involved. Routine examination of the chest disclosed moist sounds at the bases of both lungs; and radiographs showed diffuse reticular and nodular shadowing throughout the right lung with confluent mottling in the mid-zone; similar changes were present in the lower half of the left lung (Fig. 1). Laboratory investigations showed an elevation of the erythrocyte sedimentation rate (E.S.R.) to 36 mm. in the first hour (Westergren), and a moderate degree of anaemia (Hb 68%, 10 g.). The serum protein level was 8.3 g. per 100 ml., with an increase in the gamma globulin fraction; L.E. cells were not found. A

differential agglutination (Rose-Waaler) test, done four weeks after starting "prednisone," showed a titre of 1:32. The blood urea was 25 mg. per 100 ml.

Lung biopsy from the axillary fringe of the right upper lobe was performed by Mr. Percy Jewsbury on April 15 by open surgical exploration, and sections of the lung were stained by haematoxylin and eosin and Mallory's trichrome methods. The essential histological change was diffuse fibrosis of non-specific character, and interspersed among the fibrotic areas were numerous collections of lymphocytes and plasma cells (Fig. 2); the alveolar ducts could be seen lined by simple cuboidal epithelium which contained many histiocytes surrounded by mucus (Fig. 3); there were no foci of epithelioid or giant cells, but the walls of occasional bronchioles showed hyperplasia of the muscle coat which in parts suggested focal leiomyomatous change. There was fairly heavy infiltration with carbon pigment throughout the whole area. The pleura showed dense hyaline fibrosis, although in parts it still showed active organization of its inner surface; the vessels showed no significant abnormality.

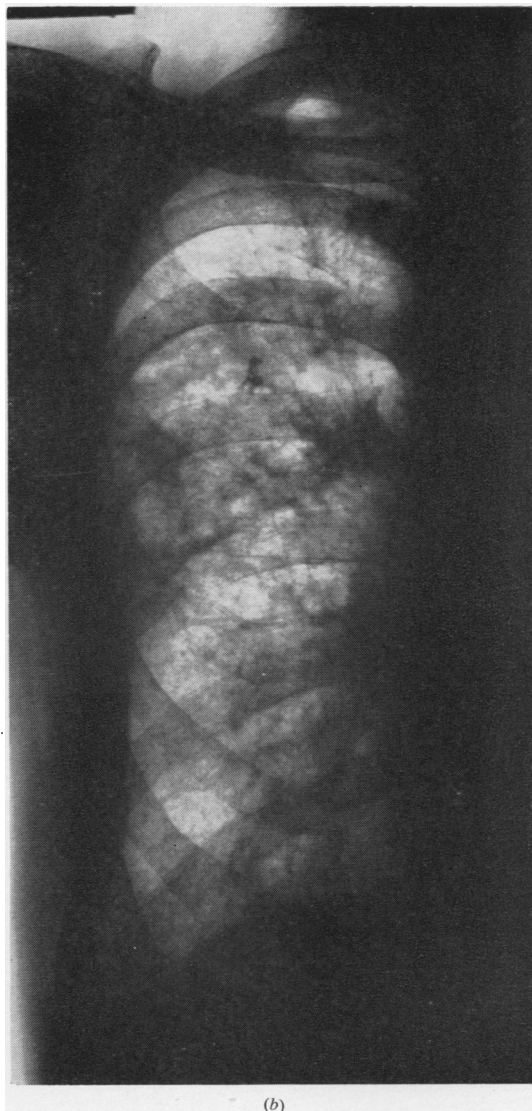Prednisone, 30 mg. daily, was started on April 28, 1957, and reduced after four days to 20 mg. daily. Within a few days all joint pain and stiffness were completely relieved, and the general condition was greatly improved. On June 4, 1957, the E.S.R. had dropped to 5 mm. in the first hour, though the increase in gamma globulin persisted. The chest radiograph remained unchanged. A striking feature was the almost complete disappearance of the finger clubbing, there being only very slight residual curvature of the nails without any congestion of the nail bed.

CASE 2.—A housewife, aged 52 years, first complained of exertional dyspnoea and cough in February, 1956, when a radiograph of the chest appeared normal. These symptoms steadily progressed so that by January, 1957, she was breathless on climbing one flight of stairs. At this time, she first noted pain in the small joints of the hands and feet, both knees and both ankles. She was admitted to High Carley Hospital in April, 1957. On physical examination she was in poor general condition with low fever; characteristic changes of rheumatoid arthritis were present in the hands and feet, and movement of both knees and ankles was limited. Finger clubbing was absent. On examination of the lungs there were scanty moist sounds at both bases, but otherwise



(a)

FIG. 1 (Case 1).—(a) Radiograph of lungs; (b) larger scale view of lower two-thirds of right lung.



(b)

nothing abnormal was found. A chest radiograph showed small scattered nodular shadows at the periphery at the lower half of each lung field (Fig. 4); and radiographs of the hands and feet showed diffuse osteoporosis but no characteristic rheumatoid change. The E.S.R. was elevated to 28 mm. in the first hour (Westergren), and the Rose-Waaler test was positive to a titre of 1 in 64. The serum protein level was 7 g. per 100 ml. (albumin 4.2 g., globulin 2.8 g.) with an increase in the gamma globulin fraction.

The maximum breathing capacity was 44 litres per min.

Lung biopsy from the left lower lobe was performed by Mr. Percy Jewsbury on May 8, 1957, by open surgical exploration. The lung felt nodular, and appeared unduly vascular. The tissue was stained by haematoxylin and eosin and by Mallory's trichrome stain. The essential histological change was diffuse fibrosis of non-specific character associated with a chronic inflammatory cell infiltration. The normal lung architecture was destroyed, being replaced by dense areas of collagenous fibrosis alternating with zones of more recent fibroblastic activity (Fig. 5); many abnormal bronchiolar elements were present (Fig. 6) within the lumina of which could be found plentiful histiocytes surrounded by mucus (Fig. 7). One of the most striking features was the dense accumulation of plasma cells and lymphocytes, the latter often being arranged in a true follicular pattern containing germ

cells and dividing lymphoblasts; there was slight thickening of the media in some of the smaller arterioles, but the appearances did not suggest a primary vascular disease. The general pathological features were very similar to those of Case 1, although the process in Case 2 appeared to be rather more acute.

In February and March a course of gold injections was given and was followed by some improvement in the joint symptoms, but was discontinued when the patient was admitted to hospital, as she developed a generalized rash with fever. Prednisolone, 30 mg. daily, was started on May 17, 1957, and reduced to 20 mg. after five days. Within a few days all joint

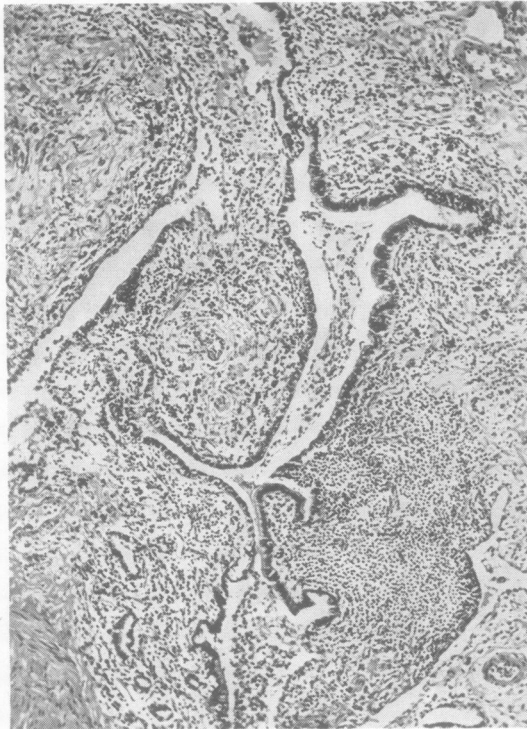


FIG. 2.—Diffuse fibrosis and round-cell infiltration in Case 1. Haematoxylin and eosin.  $\times 52$ .

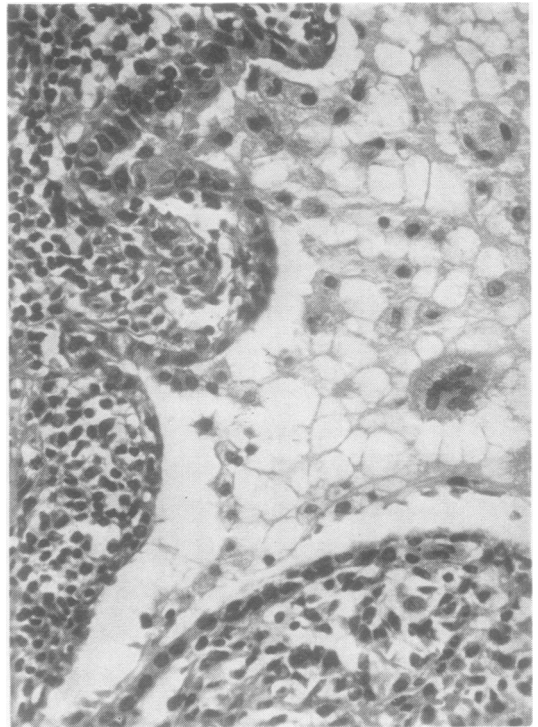


FIG. 3.—Cuboidal cell lining in dilated bronchiole with mucus and histiocytes in lumen in Case 1. Haematoxylin and eosin.  $\times 280$ .

pain had disappeared, full movement of the finger joints was restored and the general condition improved remarkably. At the same time, the temperature, which had been persistently raised up to 99.5° F. (37.5° C.), settled, and has remained normal since. On June 11, 1957, the E.S.R. had dropped to 15 mm. and the gamma globulin in the blood serum was no longer increased. A chest radiograph showed no significant change. Although the dyspnoea was much improved, there was no change in the maximum breathing capacity.

#### DISCUSSION

Including the present two cases, 43 cases of non-pneumoconiotic rheumatoid lung disease have now been described; in six of these the diagnosis was established by biopsy (Rubin, 1955; Ellman, 1956) and in a further 18 cases by necropsy (Ellman and Ball, 1948; Ellman, Cudkowicz, and Elwood, 1954; Ellman, 1947; Price and Skelton, 1956; Raven, Parkes Weber, and Price, 1948; Christie, 1954; Bevans, Nadell, Demartini, and Ragan, 1954; Katz and Auerbach, 1951; Skogrand, 1956; Yardumian and Kleinerman, 1949; Gruenwald, 1948; Bennett, Zeller and Bauer, 1940). In nine of these cases (Ellman and Ball, 1948; Ellman, 1947; Rubin, 1955; Katz and Auerbach, 1951; Yardumian and Kleinerman, 1949; Ellman, 1956)

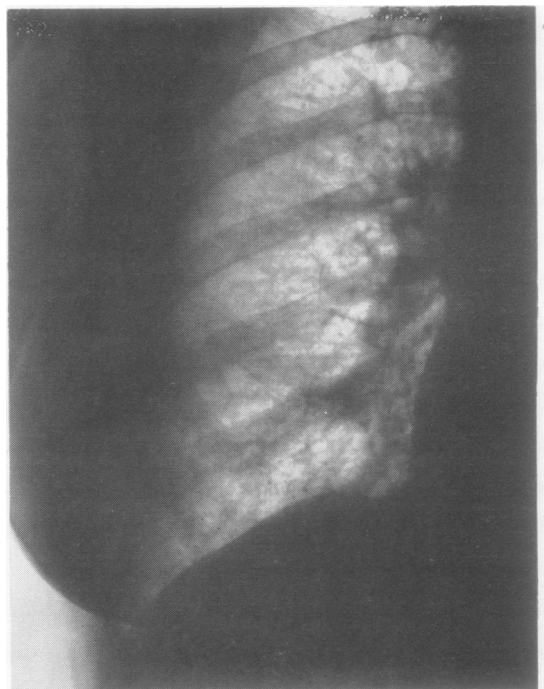


FIG. 4 (Case 2).—Radiograph showing lower two-thirds of right lung field.

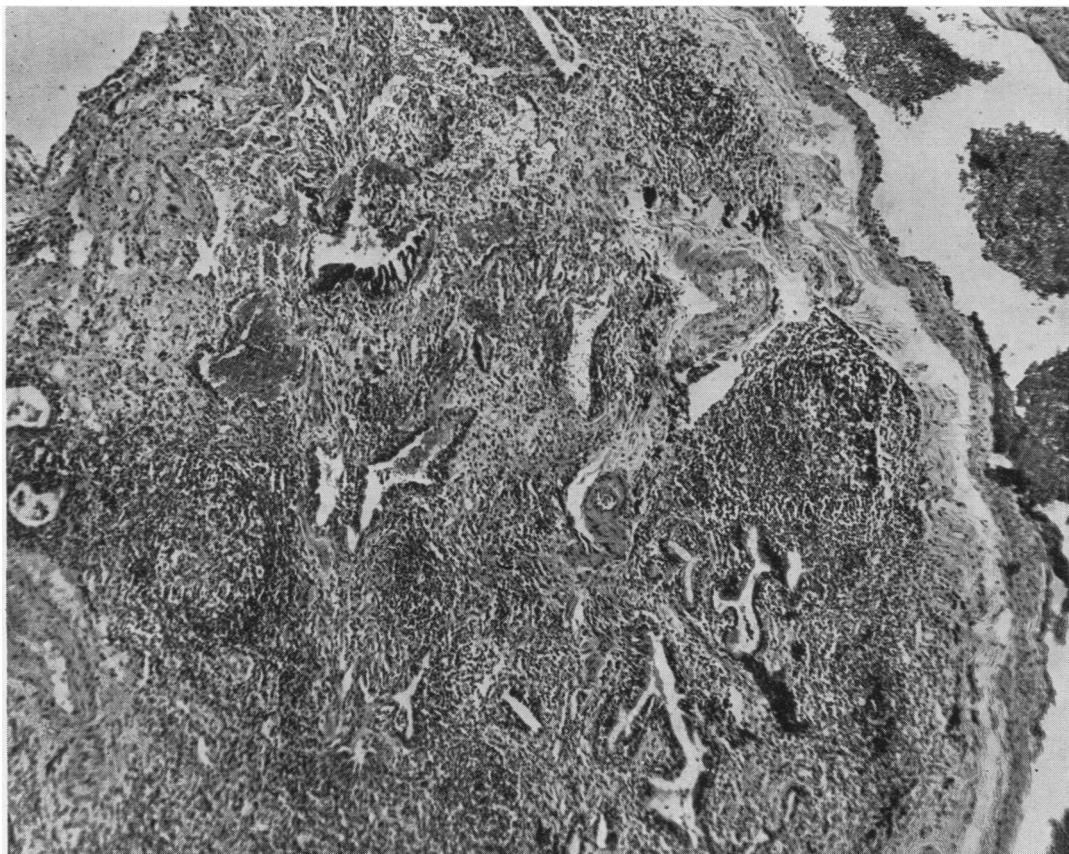


FIG. 5.—Gross fibrosis and round-cell infiltration in Case 2. Haematoxylin and eosin.  $\times 50$ .

the histological changes consisted of a non-specific fibrosing pneumonitis of the same general pattern as we have described in our two cases. In one case described by Price and Skelton (1956) the lesions appear to have been confined to the blood vessels, whilst the remaining 12 cases (Ellman and others, 1954; Raven and others, 1948; Christie, 1954; Bevans and others, 1954; Skogrand, 1956; Gruenwald, 1948; Bennett and others, 1940) have been characterized by the appearance of nodular necrobiotic foci of rheumatoid type, showing a close histological resemblance to the more commonly encountered subcutaneous lesions frequently seen in the region of the elbow joints of patients with rheumatoid arthritis.

Further cases of pulmonary involvement in rheumatoid disease in which the diagnosis has been based on clinical evidence only have been described by Ellman and Ball (1948), Middleton (1951), Schlesinger (1949), Ellman and Parkes Weber (1949), Leys and Swift (1949), Harris (1954),

Bloom and Rubin (1950), Rubin (1955), Ellman (1956), Spence (1955) and Stolte (1952).

If the lung lesion is characterized by rheumatoid necrobiosis, its interpretation is in no doubt, for the histological appearances are specific to rheumatoid disease. The pathological changes in the non-necrobiotic lesions, however, do not have the same degree of specificity and their interpretation is less certain, although there is some evidence to suggest that the pulmonary lesions are in fact of rheumatoid origin; for not only have all the cases so far described shown a broadly similar histological pattern, but the characteristic dense infiltrations with lymphocytes and plasma cells are reminiscent of the cellular reaction in the synovial tissues of affected joints.

The specific nature of the pulmonary lesions is suggested also by the high incidence of pneumonitis and pleurisy in patients with active rheumatoid arthritis. Hench and others (1948) reported an incidence of 73% of pleural adhesions in cases

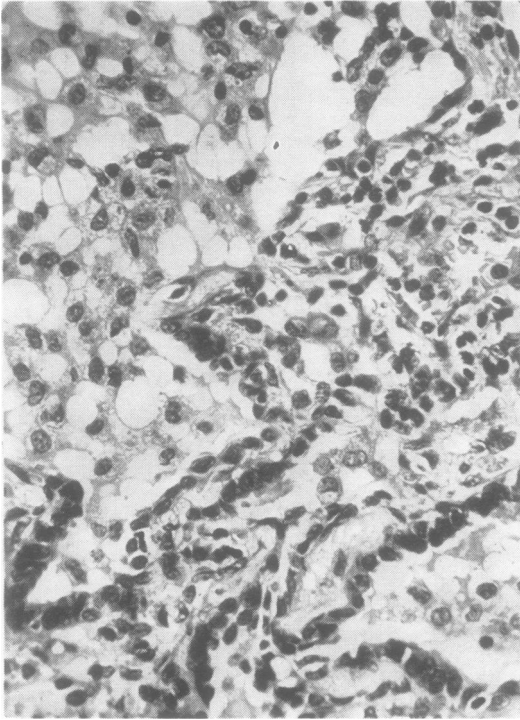


FIG. 6.—Disordered bronchiolar elements with surrounding histiocytic proliferation in Case 2. Haematoxylin and eosin.  $\times 280$ .

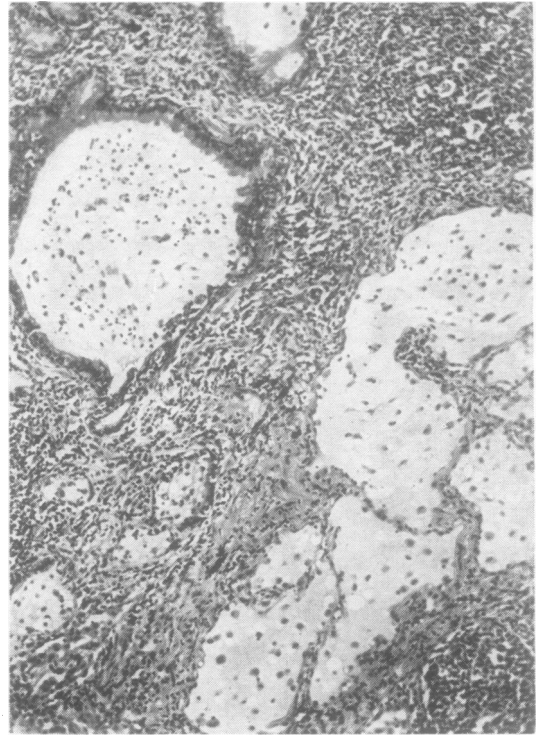


FIG. 7.—Mucus-distended bronchioles and ducts with dense round-cell infiltration in Case 2. Haematoxylin and eosin.  $\times 52$ .

in which full necropsy findings were available, and Schlesinger (1949) has testified to the frequent occurrence of pulmonary lesions during the course of rheumatoid disease in children. In an investigation of 90 cases of rheumatoid disease, Sinclair and Cruickshank (1956) found evidence of pleural adhesions in 61 cases as against 46 in a control series; they maintained that the incidence of unexplained adhesions and of pleural fibrosis showed a twofold increase over a control group, and considered that much of the pleurisy in patients with rheumatoid arthritis should be regarded as a systemic manifestation of the disease or as the result of lowered resistance to infection. Aronoff, Bywaters, and Fearnley (1955), while agreeing that the incidence of various pulmonary lesions appeared greater in rheumatoid disease than in a control series, considered that the lesions were non-specific; this opinion was based upon an analysis of 253 cases of rheumatoid arthritis. Christie (1954), in a careful pathological study of three cases of necrobiotic rheumatoid lung lesions, concluded that the proliferation of mononuclear cells, the localized areas of fibrinous pneumonia, the

focal scars and diffuse fibrosis of lungs and pleura represented true rheumatoid lung changes, and concluded that "rheumatoid inflammation is disseminated, focal, non-suppurative, persistent and prone to result in dense hyaline scars which may undergo secondary changes." He was also of opinion that the special characters of the pulmonary lesions were the consequences of such factors as the intensity, extent, duration, and localization of the action of the inflammatory process rather than of any unique attribute of the tissue reaction.

In spite of this evidence, it must be admitted that the non-necrobiotic forms of rheumatoid lung do not conform to any histological pattern which could be regarded as specific to rheumatoid disease, although the high incidence of pulmonary disease and the similarity of the lung lesions to those encountered elsewhere in rheumatoid arthritis suggest that in at least some cases the lung changes represent true rheumatoid inflammatory foci.

In the present two patients steroid treatment was followed by relief of joint and general symptoms, striking improvement in their general condition,

and subjectively much improved exercise tolerance; though, as might be expected from the nature of the lung changes, there was no alteration in the chest radiographs. In one patient there was a remarkable reversal of finger clubbing; as this change is not normally associated with rheumatoid arthritis it may be inferred that this regression was possibly due to the effect of hormone treatment on an active process in the lungs.

#### SUMMARY

Two patients with rheumatoid arthritis and lung lesions are described, and the literature of this association reviewed.

In each case lung biopsy showed a non-specific fibrosing pneumonitis. Treatment with "prednisone" was followed by striking improvement in symptoms, though there was no change in the chest radiographs.

Our thanks are due to Mr. Percy Jewsbury, who carried out the lung biopsies.

#### REFERENCES

- Aronoff, A., Bywaters, E. G. L., and Fearnley, G. R. (1955). *Brit. med. J.*, **2**, 228.
- Bennett, G. A., Zeller, J. W., and Bauer, W. (1940). *Arch. Path. (Chicago)*, **30**, 70.
- Bevans, M., Nadell, J., Demartini, F., and Ragan, C. (1954). *Amer. J. Med.*, **16**, 197.
- Bloom, J., and Rubin, J. H. (1950). *Canad. med. Ass. J.*, **63**, 355.
- Christie, G. S. (1954). *Aust. Ann. Med.*, **3**, 49.
- Ellman, P. (1947). *Proc. roy. Soc. Med.*, **40**, 332.
- (1956). *Postgrad. med. J.*, **32**, 370.
- and Ball, R. E. (1948). *Brit. med. J.*, **2**, 816.
- Cudkowicz, L., and Elwood, J. S. (1954). *J. clin. Path.*, **7**, 239.
- and Weber, F. Parkes (1949). *Brit. med. J.*, **1**, 304.
- Gruenwald, P. (1948). *Arch. Path. (Chicago)*, **46**, 59.
- Harris, L. H. (1954). *Lancet*, **2**, 119.
- Hench, P. S., *et al.* (1948). *Ann. intern. Med.*, **28**, 66.
- Katz, K. L., and Auerbach, O. (1951). *Dis. Chest*, **20**, 366.
- Leys, D. G., and Swift, P. N. (1949). *Brit. med. J.*, **1**, 434.
- Middleton, J. W. (1951). *Dis. Chest*, **19**, 473.
- Price, T. M. L., and Skelton, M. O. (1956). *Thorax*, **11**, 234.
- Raven, R. W., Weber, F. Parkes, and Price, L. W. (1948). *Ann. rheum. Dis.*, **7**, 63.
- Rubin, E. H. (1955). *Amer. J. Med.*, **19**, 569.
- Schlesinger, B. (1949). *Brit. med. J.*, **2**, 197.
- Sinclair, R. J. G., and Cruickshank, B. (1956). *Quart. J. Med.*, n.s. **25**, 313.
- Skogrand, A. (1956). *Acta rheum. scand.*, **2**, 17.
- Spence, M. P. (1955). *Arch. Mid. Hosp.*, **5**, 95.
- Stolte, J. B. (1952). *Ned. T. Geneesk.*, **96**, 1298.
- Yardumian, K., and Kleinerman, J. (1949). *Arch. intern. Med.*, **63**, 1.