

THE BRONCHIAL ARTERIES IN PULMONARY EMPHYSEMA*

BY

L. CUDKOWICZ† AND J. B. ARMSTRONG

From the Department of Medicine, Postgraduate Medical School of London

(RECEIVED FOR PUBLICATION JULY 4, 1951)

Occlusive lesions in the pulmonary arteries of emphysematous lungs have been recognized for some time (Loeschcke, 1928; Karsner, 1933; Kountz and Alexander, 1934; Brenner, 1935; Christie, 1944; Gilmour and Evans, 1946). The changes described varied from an obliterative arteritis to patches of atheroma. Loeschcke referred to the loss of pulmonary capillaries as the cause of the pallor of emphysematous lungs, and contended that *Kapillarschwund* preceded the development of the lung lesions. Gilmour and Evans suggested that a weakness of the media of the pulmonary arteries had predisposed to endarteritis obliterans. This they had observed in a case of primary pulmonary hypertension. Brenner, however, believed that increasing degrees of arteriosclerosis in the lungs of patients over 40 occurred irrespective of pulmonary disease.

Whereas lesions affecting the pulmonary arteries in pulmonary emphysema have been studied, the pathology of the bronchial arteries in this disease is more obscure. In the course of investigations of the bronchial arteries in a variety of pathological lung conditions, it became evident to us that in cases coming to necropsy with a clinical diagnosis of pulmonary emphysema, and in others in which necropsy revealed bullous emphysema of the lungs, lesions in the bronchial arteries could be demonstrated. It is the purpose of this paper to describe these findings in the bronchial arteries, to correlate them, as far as possible, with other pathological and clinical features, and to assess their relevance in relation to this group of respiratory disorders.

The bronchial arteries were first observed by Galen (1562), and were defined as "vasa nutritiva" of the lungs by Reisseisen and von Sömmering (1808). The studies of the normal anatomy of these vessels by Miller (1947) are of particular value. Several points from these anatomical studies are of importance for the discussion which is to follow.

The bronchial arteries arise from the descending aorta in variable numbers (Nakamura, 1924; Cauldwell, Sickert, Lininger, and Anson, 1948), and on reaching the hila of the lungs form an annulus which surrounds the main bronchi. From this structure arise the true bronchial arteries which follow the respective bronchial divisions to their terminations, without at any time in normal lungs forming precapillary anastomoses with the pulmonary arteries (Küttner, 1878; Berry, Brailsford, and Daly, 1931; Daly, 1935-6; Miller, 1947). In addition, they furnish branches to the visceral pleura (Küttner, 1878; Zuckerkandl, 1883; Daly, 1935-6) and the hilar lymph nodes (Fig. 1). Histological study indicates that, besides their normal function of supplying arterial blood to the bronchi and bronchioles, they are solely responsible for the blood supply of all intrapulmonary lymphatic structures (Miller, 1947), the pulmonary nerve fibres (Berry and others, 1931; Daly, 1935-6; Miller, 1947), the walls of the pulmonary arteries (vasa vasorum) (Berry, 1935; Miller, 1947), and to some extent the elastic framework supporting the alveoli (Daly, 1935-6). We believe that the connecting tissues supporting the air sacs derive their own bronchial arterioles from the interlobular septa (Cudkowicz and Armstrong, 1951). From these septa arterioles of at least 100 μ in diameter reach the alveolar supporting tissue via fibrovascular bundles which join the walls of the air sacs at right angles to the alveolar ducts. Thus bronchial arterioles appear as muscular arterioles near the alveolar walls, where they can be distinguished only by injection methods from pulmonary arterioles of similar calibre. This suggests, therefore, that the elastic supporting framework of the alveoli possesses an arterial blood supply which is independent of the pulmonary arteries and their capillary bed.

MATERIAL AND METHODS

The 18 cases which form the basis of this study were chosen from patients who showed in various forms the complex syndrome of pulmonary emphysema. Thirteen cases showed degrees of

* Some of the material in this study has been incorporated in a thesis by L. Cudkowicz accepted for the degree of M.D. by the University of London in December, 1950.

† In receipt of a grant from the Medical Research Council.

TABLE I
CLINICAL AND POST-MORTEM DIAGNOSIS

Case No.	Sex	Age	Clinical Diagnosis	Post-mortem Diagnosis
1	M	76	Hypertensive heart failure, chronic bronchitis and pulmonary emphysema	Bilateral ischaemic renal cortical atrophy. Left ventricular hypertrophy. Severe cystitis. Pulmonary emphysema
2	F	70	Carcinoma of the cervix; chronic urinary infection; chronic bronchitis and pulmonary emphysema	Carcinoma of cervix with pelvic spread. Pulmonary emphysema. Left basal bronchopneumonia
3	M	77	Chronic bronchitis and pulmonary emphysema; terminal congestive heart failure	Chronic bronchitis. Pulmonary emphysema. Patchy left basal bronchopneumonia. Old healed infarct of apex of left ventricle
4	F	76	Chronic bronchitis and pulmonary emphysema; right lower lobe consolidation	Old right apical tuberculosis. Right lower lobe infarction. Severe left pulmonary emphysema
5	M	64	Chronic bronchitis and pulmonary emphysema	Recent pericarditis. Bilateral patchy basal bronchopneumonia. Chronic bronchitis and emphysema
6	M	48	Severe pulmonary emphysema and recurrent bronchitis	Chronic bronchiolitis, patchy basal bronchopneumonia. Some alveolar fibrosis
7	M	49	Essential hypertension; terminal uraemia and melaena	Bilateral ischaemic renal cortical atrophy. Ulcer in small intestine. Moderate emphysema and some alveolar fibrosis
8	M	51	Chronic bronchitis and pulmonary emphysema	Chronic bronchitis. Pulmonary fibrosis. Cerebral congestion
9	M	54	Chronic bronchitis and pulmonary emphysema; coronary thrombosis	Infarction of anterior wall of left ventricle. Occlusion of left coronary artery. Chronic bronchitis and pulmonary fibrosis
10	M	60	Right apical carcinoma of bronchus, skeletal carcinomatosis; toxic peripheral neuritis	Small primary carcinoma at apex of right lung. Left emphysema. Demyelinating peripheral neuropathy. Multiple skeletal metastases
11	M	45	Pulmonary emphysema; myocardial infarction	Pulmonary emphysema. Right lower lobe bronchiectasis. Fibrosis of posterior wall of left ventricle
12	M	46	Right lower lobe pneumonia; urinary retention	Bilateral hydronephrosis. Emphysema of upper lobes. Right lower lobe consolidation. Left lower lobe bronchiectasis
13	M	69	Chronic bronchitis and pulmonary emphysema	Chronic bronchitis and pulmonary emphysema. Left lower lobe bronchiectasis. Purulent cystitis
14	M	38	Chronic bronchitis and pulmonary emphysema	Chronic bronchitis and pulmonary emphysema. Left lower lobe bronchiectasis. Cerebral anoxia
15	F	48	Aortic stenosis, congestive cardiac failure; chronic bronchitis	Calcareous aortic stenosis. Right and left ventricular enlargement. Chronic bronchitis, pulmonary fibrosis
16	M	51	Chronic bronchitis and emphysema; congestive cardiac failure	Pulmonary fibrosis and moderate marginal emphysema. Right ventricular enlargement
17	M	55	Chronic bronchitis, pulmonary emphysema; cor pulmonale and congestive cardiac failure	Alveolar fibrosis. Patchy left basal bronchopneumonia. Enlarged right ventricle. Congested liver and spleen

TABLE I—continued

Case No.	Sex	Age	Clinical Diagnosis	Post-mortem Diagnosis
18	M	38	Cor pulmonale; chronic bronchitis and pulmonary emphysema	Right basal cystic bronchiectasis. Pulmonary fibrosis. Very considerable right ventricular enlargement. Congestion of liver and spleen

dyspnoea which were clinically believed to be of the emphysema type and at necropsy revealed no extrapulmonary cause for this symptom. In five cases the dyspnoea was probably pulmonary and cardiac in origin, and at necropsy changes in the lungs and hearts of these patients were seen.

The clinical diagnosis and the post-mortem findings are given in Table I.

The methods used for the study of the bronchial circulation have already been described in a paper on the normal anatomy of the bronchial arteries (Cudkowicz and Armstrong, 1951). By means of a radio-opaque mass injected into the bronchial arteries via the aorta, as the mass was too coarse to penetrate arterioles of less than 60 μ in diameter, it was possible to examine the intrapulmonary distribution of these arteries radiologically, and the presence of bismuth granules in the lumina of the bronchial arteries permitted their easy histological recognition in ordinary lung sections. Often the method of removing the thoracic contents had to be slightly modified because dense pleural adhesions necessitated extrapleural mobilization of the lungs. Damage to the visceral pleura was thus avoided. The injection technique and the preparation of the histological material were the same as in the study of the normal lungs. In many instances the lesions in the bronchial arteries might have been the result of artifacts or of tangential cuts taken through the vessel walls. To eliminate uncertainty, serial cuts were taken of the same blocks until the changes could be properly assessed.

RESULTS

PATHOLOGICAL FINDINGS.—The changes in the bronchial arteries which were observed in the present cases fall under three headings.

(1) *Narrowing or Obliteration of Intrapulmonary Branches of Bronchial Arteries.*—A reduction in normal calibre was seen radiographically in 14 cases, and it appeared to affect the vessels even in their extrapulmonary course. On their entry into the lungs they frequently failed to form an annulus round the main bronchi, and their calibre became further reduced as they spread out. In

13 cases the bronchial arteries, following the bronchial divisions, ceased to be outlined by the contrast medium about 5 cm. beyond the lung hila, and failed to reach the periphery of the lungs. A characteristic "pigtail" pattern of the bronchial arteries in the proximity of the hila indicated some tortuosity proximal to the occlusion of their lumina. In one case (Table II, Case 6) their intrapulmonary distribution appeared to be normal, but their calibre was conspicuously reduced.

Serial sections of the bronchial arteries in their extra- and intra-pulmonary distribution revealed progressive reduction in the lumina as the result of medial hyperplasia and intimal proliferation of varying severity. This process of vascular narrowing, which led to actual occlusion in 17 cases, extended to all branches in their distribution to

the various lung structures, and appeared to be most severe in the arterioles at the periphery of the lungs. Medial hypertrophy often predominated in the peripheral arteries, and intimal thickening appeared to be more common in the more proximal branches.

(2) *Obliteration of the Visceral Pleural Arteries.*—The visceral pleural branches of the bronchial arteries were occluded in all our 18 cases, nor was the radiographical pattern of normal pleural branches visible. Histologically, these vessels showed the same medial and intimal changes as were seen in the other branches of the bronchial arteries. In 16 cases with dense pleural adhesions no extension of the visceral pleural arteries into the adhesions could be demonstrated. The rich pleural vascularity which was encountered in

TABLE II
SUMMARIES OF CLINICAL AND PATHOLOGICAL DATA OF CASES IN GROUPS 1-4

Case No.	Sex	Age	History of Dyspnoea in Years	Haemoglobin (g.%)	B.P.	E.C.G.	Past History of Heart Failure	Post-mortem Appearance of Lungs	Heart at Necropsy
<i>Group 1*</i>									
1	M	76	10		220/160	Left axis deviation	Nil. Terminal pulmonary oedema	Bullous emphysema of both lungs	455 g. Thick left ventricle
2	F	70	20		130/80	Normal	Nil	Bullous emphysema of upper lobes	275 g.
3	M	77	24		120/90	?Septal myocardial infarction	Terminal congestive failure	Very bulky lungs with bullae	320 ,,
4	F	76	17		140/90	Left axis deviation	Nil	Severe left bullous emphysema	305 ,,
5	M	64	20		120/85	Normal	„	Bulky and inflated lungs with marginal bullae	?
<i>Group 2†</i>									
6	M	48	13		150/200	Vertical heart	„	Normal in size	395 g.
7	M	49	3		190/115	Left ventricle plus	Terminal pulmonary oedema	Moderate enlargement with few bullae	805 g. Thick left ventricle
8	M	51	10		115/85	Right axis deviation	Nil	No enlargement	335 g.
9	M	54	12		135/80	„ „	„	„	370 ,,
10	M	60	5		160/60	Normal	„	Left lung moderately emphysematous	270 ,,
<i>Group 3‡</i>									
11	M	45	3		102/85	Right axis deviation	„	Moderate bilateral emphysema	365 ,,
12	M	46	5		145/90	Normal	„	Bilateral bullous emphysema	335 ,,
13	M	69	30		130/55	Vertical heart	„	„	290 ,,
14	M	58	35		150/85	Normal	„	Bullous at margins and widespread bullae in upper lobes	320 ,,
<i>Group 4§</i>									
15	F	48	20	15.0	140/65	Sinus tachycardia left ventricle plus	Congestive episodes	Left pulmonary oedema. No enlargement of right	790 g. Right and left ventricular enlargement
16	M	51	7	16.0	130/80	Right ventricle plus	„ „	No enlargement of lungs	470 g.
17	M	55	8	15.9	140/70	„ „ „	„ „	Upper lobes showed some marginal bullae	400 ,,
18	M	38	38	18.4	150/90	Right axis deviation; P waves 2 mm. high	„ „	No naked eye evidence of emphysema	840 g. Gross enlargement of right ventricle

* All five patients before death were dyspnoeic at rest, but not cyanosed. Finger and toe clubbing was absent. All had varying degrees of kyphosis. Bilateral vascular adhesions were seen in the pleural cavities.

† Case 6 had exertional dyspnoea and cyanosis at rest. The other cases were dyspnoeic at rest and developed cyanosis on exertion. In all some kyphosis was present, but clubbing of fingers and toes was absent. The arterial oxygen saturation in Cases 6, 8, and 9 was approximately 70%. The right ventricular pressure in Case 6, a few months before death, was 21/12 mm. Hg and terminally 66/22. Pleural avascular adhesions were present in Cases 6 and 10.

‡ Case 12 was dyspnoeic on exertion and the remaining patients had dyspnoea at rest. Cyanosis was not present. Finger and toe clubbing was absent. All had kyphosis. Extensive bilateral pleural vascular adhesions were seen in all four cases.

§ All four patients were dyspnoeic and cyanosed at rest. Kyphosis affected Cases 16 and 18. In all four cases marked toe and finger clubbing was present. The right ventricular pressure (four years before death) was measured in Case 18 and was found to be 46 mm. Hg (systolic).

13 cases was the result of extension of the parietal pleural arterioles and their capillaries through the adhesions to the underlying ischaemic visceral pleura. The latter vessels revascularized the obliterated visceral pleural arteries.

In two instances the adhesions were fibrous and avascular, and in three cases no adhesions were present in spite of the total obliteration of the visceral pleural arteries.

(3) *Anastomoses between Bronchial and Pulmonary Arteries in an Obliterated Peripheral Bronchial Arterial Circulation.*—In four instances there was radiological evidence of precapillary anastomoses in one lung lobe between pulmonary arteries and abnormally distributed and enlarged bronchial arteries (Fig. 5).

Serial sections taken from these lobes showed on histological examination that the pulmonary artery branches were occluded by organized thrombi and intimal thickening, and that the enlarged vasa vasorum in their adventitiae communicated with new channels within the thrombosed pulmonary artery lumina. The communications appeared to be more common at the periphery. Nearer the hilum the lumina of the pulmonary arteries were reduced by the same change and filled with bismuth granules (Figs. 13 and 14). Very large patent vasa vasorum, not in communication with the pulmonary arteries, lay in the adventitia.

In four cases anastomoses between the two circulations were observed radiographically in the lobes of both lungs, and grossly tortuous and enlarged bronchial arteries were seen to proceed along an aberrant intrapulmonary course. The histology of these lungs revealed extensive intimal proliferation and atheroma in the larger pulmonary artery trunks near the hila, with much reduced and bismuth-filled lumina. The vasa vasorum which could be identified at these levels were occluded. Nearer the periphery very large patent vasa vasorum appeared again in the adventitia of the pulmonary arteries, and seemed to be derived from tortuous bronchial arteries which led away from the larger bronchi they had previously followed. These vasa vasorum were in communication with the lumina of the peripheral pulmonary arteries.

The bronchial arterioles near structures in the lungs normally supplied by them were, with few exceptions, occluded by extensive medial and intimal changes.

CORRELATION OF BRONCHIAL ARTERY LESIONS WITH OTHER PATHOLOGICAL FINDINGS.—The sites of total loss of bronchial circulation corresponded

with the areas in the lung where structural changes were most severe. This avascularity was particularly arresting in the fibrosed interlobular septa, visceral pleura, and smaller bronchi. The peripheral alveoli, in more than half of the cases, showed rupture and collapse with attenuation of their epithelium. The bronchial vessels in their vicinity were occluded. In the remaining cases the peripheral alveoli showed considerable fibrosis of their supporting tissue, loss of capillaries, and collapse rather than rupture of the alveolar epithelium. The smaller bronchi in particular showed occluded bronchial arteries in their walls, with an increase of fibrous tissue between the atrophic muscle layers and submucosae. The cartilage and the glandular elements in many instances were fibrosed, and a characteristic metaplasia of the ciliated epithelium of the stratified type was observed.

All our 18 cases showed variable degrees of fibrosis of the visceral pleura with replacement of the elastic fibres by fibrous tissue. Scarring was particularly evident in the subserous layers. In 15 instances the pleural sacs were almost totally obliterated by dense adhesions which, in all but two cases, were intensely vascular. The vascularity was the result of extension of the parietal pleural arteries and their capillaries to the visceral pleura where, in 13 cases, recanalization of the obliterated visceral pleural arteries was effected. Patent visceral pleural arteries in the presence of adhesions were not seen.

In the four cases in which bronchopulmonary anastomoses were demonstrated in one lobe only, that lobe showed bronchiectasis. The walls of the bronchi revealed extensive fibrosis of the cartilage, muscle, and mucosa. The bronchial arteries in the walls of these bronchi were totally occluded by medial and intimal proliferation. The accompanying pulmonary arteries were thrombosed in these areas and showed some recanalization of their lumina by proliferating vasa vasorum, which were derived from aberrant enlarged bronchial arteries, accompanying the branches of the pulmonary arteries (Fig. 8). The fibrotic changes in the alveoli and bronchi, in addition to the thrombosis of the pulmonary arteries, make it unlikely that these lobes could retain any respiratory function, and they can only be regarded as areas in which a considerable systemic blood supply has established itself within the former pulmonary artery bed in order to provide an arterial circulation to the proliferating fibrous tissue.

In four instances in which anastomoses were seen in both lungs there was widespread alveolar

fibrosis and rupture, with atrophic changes in the smaller bronchi, and the walls of the major pulmonary artery trunks near the hila showed atheroma and intimal thickening. At that level occluded vasa vasorum could be identified in the adventitia of the pulmonary arteries, whose reduced lumina were filled with bismuth granules. The granules entered the peripheral branches of the pulmonary arteries through abnormally large patent vasa vasorum, in communication with their lumina. These large vasa vasorum were derived from aberrant bronchial arteries, and enabled retrograde filling of the pulmonary artery bed with the injection medium.

The bronchial arteries in their normal distribution in these lungs were obliterated.

CORRELATION OF BRONCHIAL ARTERY LESIONS WITH CLINICAL FEATURES.—On the basis of the present bronchial artery studies it proved possible to place our 18 cases into four distinct groups: Group 1 consisted of five cases with occluded bronchial arteries, absent precapillary anastomoses, and extensive vascular pleural adhesions. Group 2 consisted of five cases with narrowed or occluded bronchial arteries, absent anastomoses, and avascular or absent adhesions. Group 3 consisted of four cases with obliterated bronchial arteries, precapillary bronchopulmonary anastomoses in one lobe, and extensive vascular pleural adhesions. Group 4 consisted of four cases with occlusion of the normal bronchial arteries, widespread bilateral precapillary anastomoses of very large aberrant bronchial arteries with the peripheral branches of the pulmonary arteries and bilateral vascular pleural adhesions.

Other clinical and pathological data of the cases falling into these four groups are summarized in Table II, and show that there are some differences between them. Group 1 is a series of senile patients with long histories of exertional dyspnoea, who showed neither cyanosis, right heart enlargement, nor episodes of congestive cardiac failure. Kyphosis was present, but clubbing was absent. In Group 2 the patients, younger at the time of death than those of the previous group, had no enlargement of the right heart or congestive cardiac failure. One had cyanosis at rest, and three became cyanosed on exertion. All but one were dyspnoeic at rest. Clubbing was absent. The patients of Group 3 had the same signs and symptoms as the first group, but their age at the time of death was lower than the average age of the first group. The average age of the patients in Group 4 at the time of death was less than that of the previous three groups. They were cyanosed at rest as well

as dyspnoeic, and had repeated episodes of congestive failure. They all showed finger and toe clubbing, and in three there was clinical evidence of right heart enlargement. In two instances there was kyphosis and evidence of right ventricular preponderance on an electrocardiogram.

TYPICAL CASES

GROUP 1: CASE 3.—A man, aged 77, died after 24 years' history of dyspnoea at rest. He had a hyper-resonant, kyphotic chest, with distant breath sounds and expiratory rhonchi. The heart was not enlarged clinically and the sounds were normal. Blood pressure was 120/90 mm. Hg. There was no clubbing or cyanosis. At necropsy both lungs were bulky and had many large bullae along both lung margins. Multiple adhesions fixed the diaphragmatic surfaces and apices to the parietal pleura. Some of the bullae were free from adhesions. The heart weighed 320 g. The right ventricle was dilated but not hypertrophied, and an old infarct was seen at the left apex.

After injection of the bronchial arteries it was noticed that the pleural arteries remained uninjected at the periphery, but a few could still be seen at the hila.

Radiography of the injected lungs showed constriction of the bronchial arteries and failure of some of these to extend 5 cm. beyond the lung hila. A few fine "pigtailed" vessels emerged from the occluded major trunks and carried the contrast medium for another 2.5 cm. along the major bronchi. The periphery of the lungs, and the bullous areas in particular, were completely devoid of injected bronchial arteries (Fig. 1).

Serial sections of the large bronchi showed increasing degrees of intimal thickening and medial hypertrophy of the bronchial artery walls (Fig. 2) in the more peripheral sections. In the smaller bronchi this change led to total occlusions of the arterial lumina. The cells infiltrating the bronchial walls were predominantly lymphocytes. Squamous metaplasia of the mucosa, fibrosis with replacement of the muscle fibres, and glandular acini were also most commonly seen in the smaller bronchi. The alveoli at the periphery were thinned and collapsed, and the interlobular septa were fibrosed. The bronchial arterioles near these structures were occluded. The main bronchial arterial lesions, leading to the occlusion of their lumina, were most striking in the areas of severest emphysema, in the pleura, and in the walls of the small bronchi. The peripheral pleural arteries were all occluded and mostly recanalized if near adhesions. A section of a pleural artery near the hilus showed gross reduction of its lumen, and comparable changes were seen in systemic arteries elsewhere.

GROUP 2: CASE 8.—This man, aged 51, came to necropsy after 10 years of dyspnoea at rest and exertional cyanosis. He had considerable kyphosis and a hyper-resonant chest. The heart was not

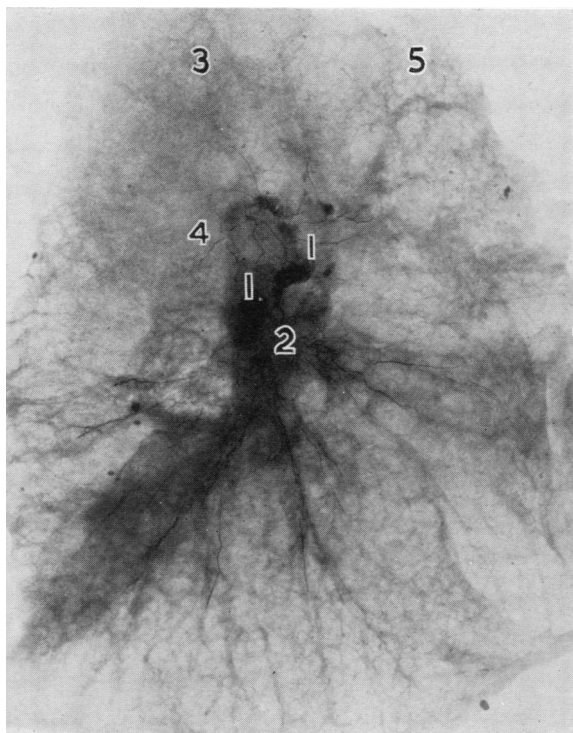


FIG. 1.—Case 3: lateral radiograph of left lung (left hilum faces x-ray tube). The bronchial arteries fail to reach the areas of emphysema at the periphery and their calibre is very constricted. One-fifth normal size; 1, hilar lymph nodes; 2, no proper annulus formation; 3, absent apical pleural branch; 4, "pig-tailing" of bronchial artery to apico-posterior bronchus; 5, bullae.

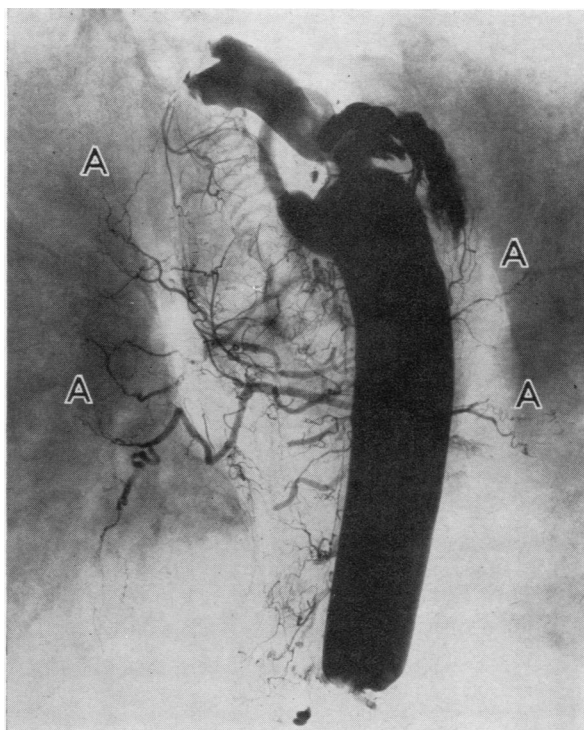


FIG. 3.—Case 8: radiograph of both lungs. The aorta and the bronchial arteries can be seen. The bronchial arteries (A) fail to penetrate beyond the hila. The appearance of "pig-tailing" is well marked. No extension of the bronchial arteries into the lungs beyond the hila took place.

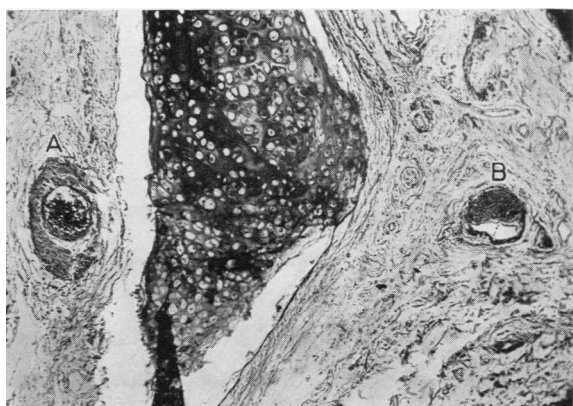


FIG. 2.—Case 3: Photomicrograph of the left main bronchus. The nutrient bronchial arteries in the bronchial wall show intimal proliferation and reduction in their lumina (A and B). H. and E. stain, $\times 40$.

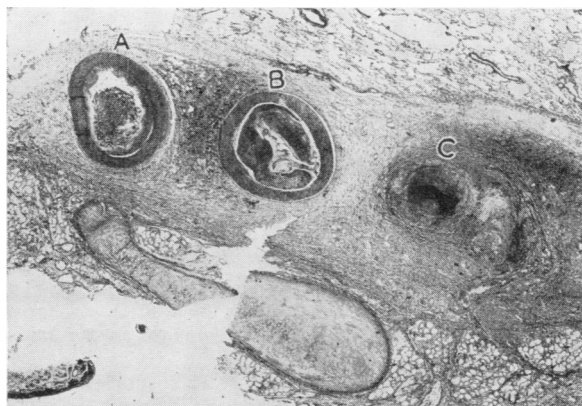


FIG. 4.—Case 8: photomicrograph of the wall of the right main bronchus. A tortuous bronchial artery—A, B, and C—appeared three times in this section and showed progressive occlusion of its lumen by intimal proliferation. The intima and media became finally replaced by fibrosis. H. and E., $\times 10$.

clinically enlarged and the sounds were normal. An electrocardiogram showed right axis deviation. The blood pressure was 115/85 mm. Hg, the haemoglobin 16.8 g.%, and the arterial oxygen saturation 66%. There was no clubbing of the fingers and toes. He died following an episode of extreme dyspnoea, cyanosis, and unconsciousness from which he could not be roused in spite of energetic therapy.

The lungs at necropsy were bulky, but no bullae were seen. Adhesions were absent. The heart was normal in size and showed no enlargement of the ventricular muscles. It weighed 335 g. The cerebral cortex was congested.

After the injection of the bronchial arteries the visceral pleural branches failed to fill. The radiographs of the injected lungs showed two fairly large bronchial arteries entering the hila and their sudden termination within 3 cm. of their course along the major bronchi. The centre and periphery of the lungs were devoid of bronchial arteries (Fig. 3).

Serial sections of the main bronchovascular bundles revealed dilatation of the bronchial arteries on entry into the lungs, and their subsequent occlusion within the walls of the major bronchi. The change in this case was primarily a proliferation of the intimal coat with replacement of the media by fibrosis (Fig. 4). The medium-sized bronchi showed thickening of the mucosa, degeneration of the glandular structures, fibrosis of the cartilage, and distorted, obliterated bronchial arteries in their walls. The same type of change was evident in the grossly thinned visceral pleura, which was not involved by adhesions. The visceral pleural arteries showed no recanalization. The alveolar walls appeared to be very thickened and fibrosed in the centre of the lungs, and at the periphery they were thinner and collapsed. Universal occlusion of the bronchial arterioles was seen in the fibrosed interlobular septa.

The absence of pleural adhesions or the presence of avascular adhesions in this group is of special significance.

GROUP 3: CASE 14.—This man, aged 58, died after a history of progressive breathlessness dating back to the first world war, in which he lost both legs. He had frequently to be admitted to hospital on account of an unproductive cough and dyspnoea at rest which persisted throughout the year. His work as a shoe-repairer became impossible one year before death because of the disabling breathlessness. During his final admission he was pale and orthopnoeic. The chest was rigid, hyper-resonant, and there was gross kyphoscoliosis. Air entry was absent at the bases, and rhonchi were audible in the mid-zones. A radiograph of the chest showed translucent lung fields. The heart shadow was not increased in size and contour, and the heart sounds were not abnormal. His vital capacity was 1.5 litres, the blood pressure 130/85 mm. Hg, the haemoglobin 14.4 g.%. An electrocardiogram showed no abnormalities. Finger and toe clubbing was absent.

At necropsy both upper lobes were very emphysematous owing to bullae, and the pleural sacs were obliterated. The heart weighed 320 g. and showed no abnormal changes.

After injection of the bronchial arteries the absence of filled pleural arteries was noticed. Radiography of the injected lungs revealed occlusion of the bronchial arteries 6.5 cm. from their emergence from the main annuli in all but the lower lobes. The bronchial arteries to the left lower lobe were tortuous and enlarged, and followed the pulmonary arteries to the periphery. Anastomoses between the two circulations took place at the periphery of the left lower lobe, causing the pulmonary artery pattern in that lobe to become outlined as well (Figs. 5 and 6). Bronchography showed bronchiectasis of the left lower lobe bronchi (Fig. 7). Microscopy of these lungs showed obliterative changes of the bronchial arteries in the walls of the smaller bronchi, near the air sac and in the pleura. There recanalization was in evidence in the visceral pleural arteries.

In random sections from the left lower lobe, occluded pulmonary arteries due to organized thrombosis or intimal proliferation were seen. Large vasa vasorum were visible in the adventitia (Fig. 8), and these communicated with new bismuth-filled channels in the pulmonary arteries near the periphery (Fig. 9). The accompanying bronchi were extremely fibrosed and infiltrated with macrophages and round cells. The epithelium of the mucosa was mostly squamous. The fibrosis was excessive in the tunica propria and replaced muscle and glandular acini. The cartilage was only recognizable in the larger bronchi. The surrounding lung tissue showed the same infiltration of cells and the alveoli were frequently unrecognizable on account of the widespread fibrosis. The overall impression gained was one of fibrous proliferation throughout that lobe, with occlusions of the pulmonary arteries and of the normal bronchial circulation. The recanalization of the pulmonary arteries by proliferating vasa vasorum suggested deviation of the peripheral bronchial flow into the pulmonary artery bed of that lobe, a process which would very well account for the radiographic findings after injection.

GROUP 4: CASE 18.—This patient was aged 38 at the time of death. Since birth he had been breathless and often cyanosed, and required repeated hospital admissions on account of cyanotic, congestive heart failure and severe dyspnoea. Cardiac catheterization four years before death revealed a right ventricular systolic pressure of 46 mm. Hg.

During his final admission he was orthopnoeic, grossly cyanosed, and frequently became unconscious. The jugular venous pulse was raised 8 cm. above the sternal angle, the liver was enlarged, and the ankles swollen. The apex beat was displaced 6 in. from the midline, but rhythm and heart sounds were normal. The blood pressure was 150/90 mm. Hg. The toes and fingers were grossly clubbed and the chest barrel-

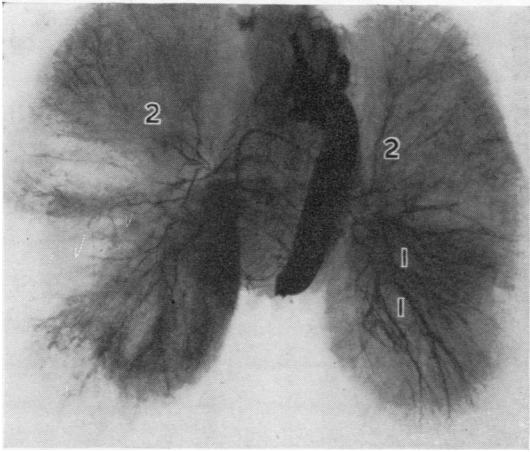


FIG. 5.—Case 14: radiograph of both lungs. The aberrant course of the bronchial arteries in the left lower lobe is shown: 1, anastomoses with the peripheral branches of the pulmonary arteries; 2, constricted bronchial arteries to both upper lobes.

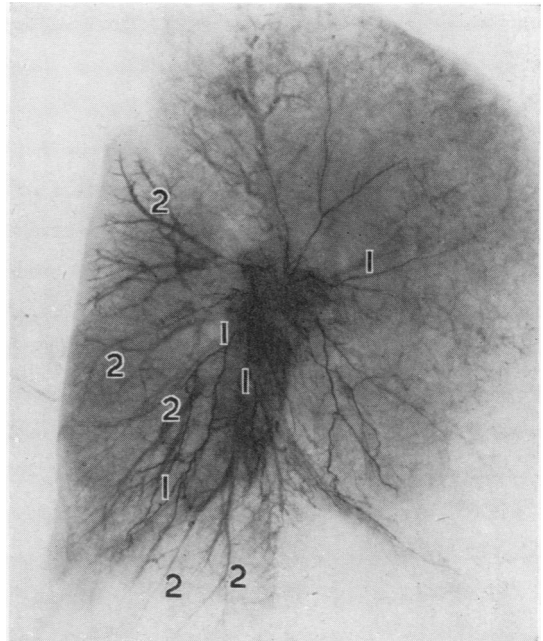


FIG. 6.—Case 14: lateral radiograph of left lung. The bronchial arteries (1) in the left lower lobe are tortuous and anastomose with the peripheral branches of the pulmonary arteries, which have also been outlined (2).

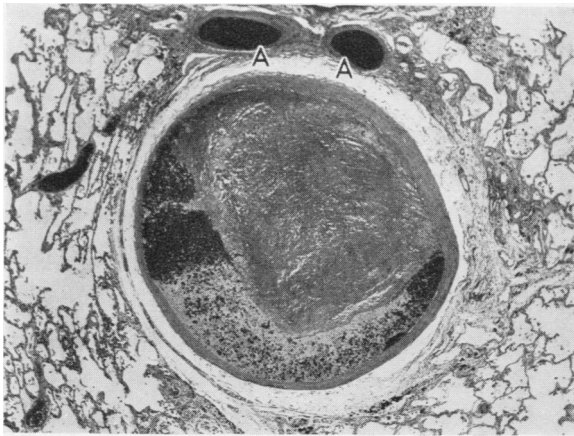


FIG. 8.—Case 14: photomicrograph of left pulmonary artery. The lumen of the artery is reduced by an organizing thrombus. The remaining lumen has become filled retrogradely by the injection medium. Large dilated vasa vasorum are visible in the adventitia (A). H. and E., $\times 20$.

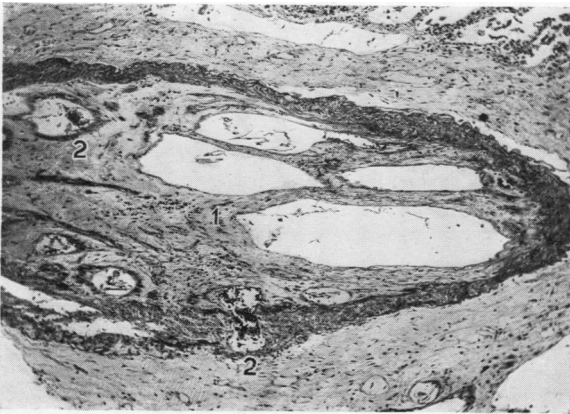


FIG. 9.—Case 14: photomicrograph of a left lower lobe pulmonary artery. The artery is thrombosed, but its lumen has become recanalized by proliferating vasa vasorum. (1) Thrombosed pulmonary artery, (2) bismuth-filled vasa vasorum. H. and E., $\times 40$.

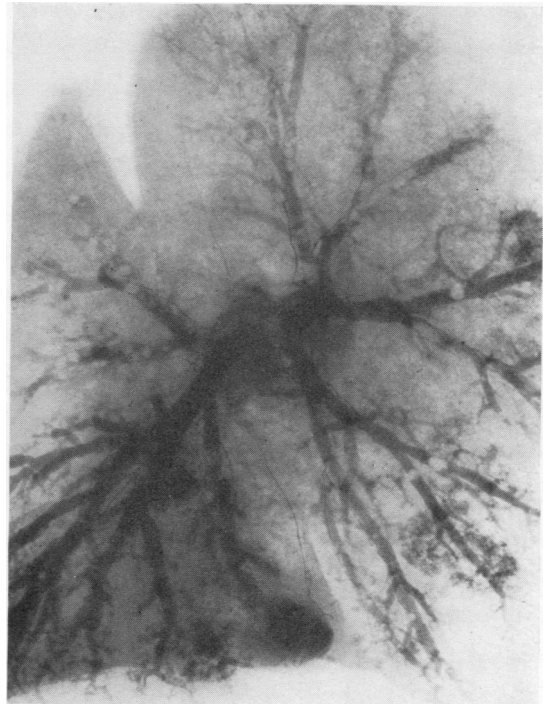


FIG. 7.—Case 14: bronchogram of left bronchial tree. The bronchi of the left lower lobe show fusiform dilatation.

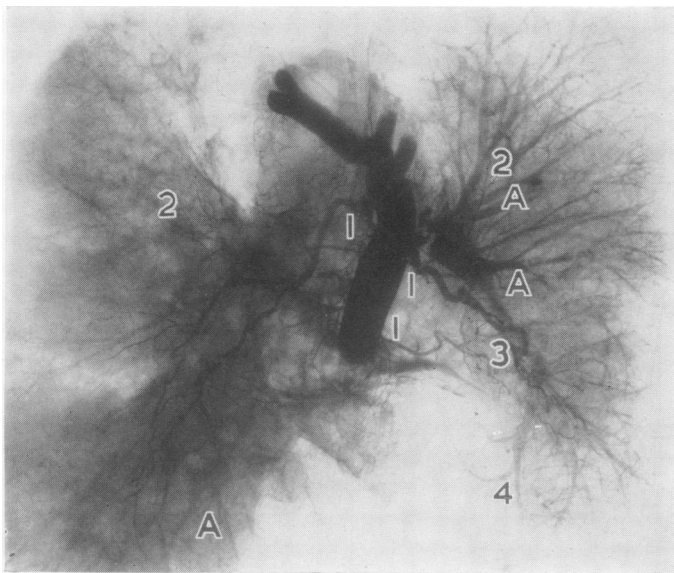


FIG. 10.

FIG. 10.—Case 18: radiograph of both lungs. 1. The bronchial arteries emerge from the aorta and are greatly enlarged. 2. Small bronchi entering the lungs follow an aberrant course. 3. Small bronchi only can be seen to extend to the upper lung fields on either side. 4. The largest bronchial arteries on the left communicate with the pulmonary artery in the left lower lobe. The left lower lobe pulmonary artery trunk is only faintly outlined contrasted with the peripheral pulmonary arteries (A) which have become filled retrogradely.

FIG. 11.—Case 18: photomicrograph of a pulmonary artery from the periphery of the left lower lobe. The wall of the vessel is normal, but a large vasa vasorum (A) communicates with lumen and conveyed the injection medium into the pulmonary vessel (B). H. and E., $\times 40$.

FIG. 12.—Case 18: photomicrograph of left main pulmonary artery trunk. The lumen of the artery is nearly occluded by intimal proliferation and a plaque of atheroma (A). Vasa vasorum cannot be seen in the adventitia. H. and E., $\times 25$.

FIG. 13.—Case 18: photomicrograph of the left main pulmonary artery near the hilum. The vasa vasorum (A) in its adventitia is occluded. The intima shows some proliferation. The lumen is filled with bismuth cream (B). $\times 45$.

FIG. 14.—Case 18: photomicrograph of a major bronchus. The bronchial arteries (A) in the wall of the bronchus are occluded. The accompanying pulmonary artery shows bismuth granules in its lumen (B). H. and E., $\times 36$.

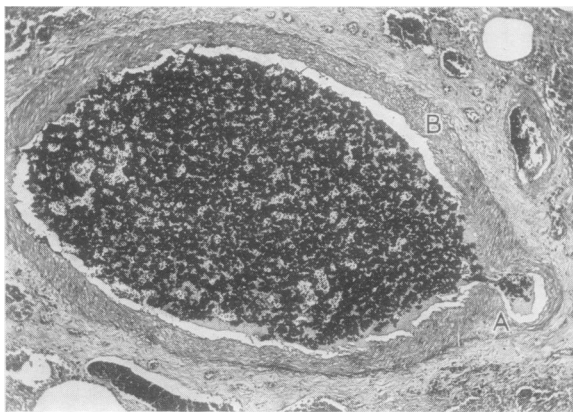


FIG. 11.

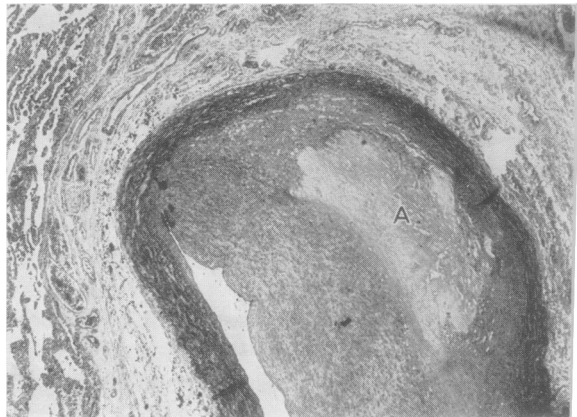


FIG. 12.

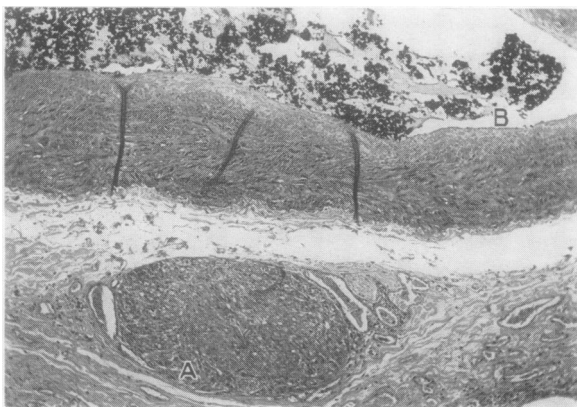


FIG. 13.

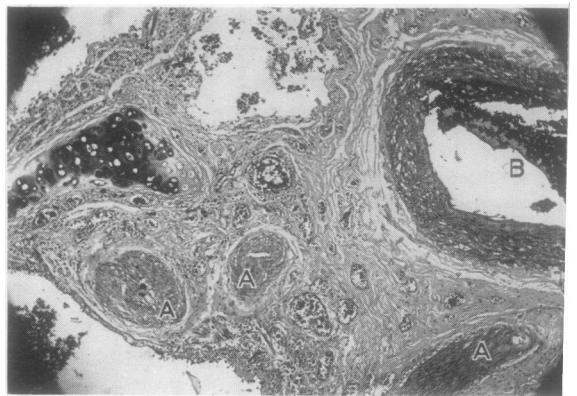


FIG. 14.

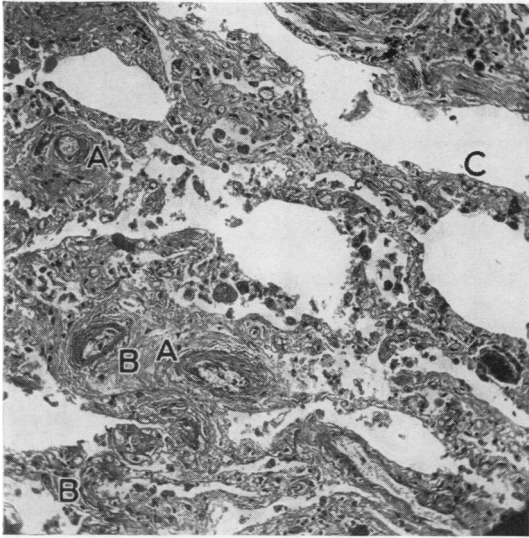


FIG. 15.—Case 18: photomicrograph of lung tissue. The bronchial arterioles in the septa between the alveoli show concentric thickening of the media and reduction in lumina (A). There is considerable increase in fibrous tissue between the alveoli (B) and some dilatation of the pulmonary capillaries (C). H. and E., $\times 100$.

shaped. A radiograph of the chest showed emphysematous lung fields with some basal "honeycombing" and enlargement of the right ventricle, and dilatation of the pulmonary arteries. An electrocardiogram indicated large P waves (over 2 mm. in height) and right axis deviation. The haemoglobin was 18.4 g.%, the arterial oxygen saturation 75%, the alkali reserve 64 vol. CO₂%, and the vital capacity was estimated at 2 litres.

At necropsy the body was grossly cyanosed, the chest barrel-shaped, and clubbing was very marked. The lungs were bulky, the pleural cavities obliterated by many adhesions, and the pulmonary arteries appeared to be very dilated.

The heart weighed 840 g. and showed considerable hypertrophy of the right ventricular muscle. The liver and spleen were congested.

The pleural arteries failed to fill after injection of the bronchial arteries.

Radiographs of the injected lungs showed two very large arteries entering the left hilum and one artery of more than 6 mm. in diameter coursing to the right hilum. The left and part of the right pulmonary artery beds were also outlined. The bronchial arteries divided at the hila and followed the radicles of the pulmonary arteries very closely to the periphery. Normally distributed bronchial arteries were absent (Fig. 10).

Histological examination showed precapillary anastomoses between the pulmonary and aberrant bronchial arteries at the periphery of both lungs (Fig. 11). There was severe intimal proliferation and atheroma of the walls of the proximal pulmonary

artery trunks (Fig. 12). At this level the vasa vasorum in the adventitia of the larger pulmonary arteries were also occluded (Fig. 13). The entry of the aberrant bronchial arteries, which accompanied the larger bronchi at first, occurred distal to the lesions in the pulmonary arteries. Although the lumina of the larger pulmonary arteries were severely reduced near the hila, they were fully patent at the periphery where the anastomoses took place and conveyed the injection medium retrogradely into the pulmonary artery beds.

The normal bronchial arteries in the walls of the bronchi (Fig. 14), pleura, and near the air sacs (Fig. 15) were severely occluded by medial hyperplasia. Revascularization was visible in the visceral pleural arteries. The bronchi were fibrosed, and the alveoli showed great thickening of their supporting structures, dilatation of the capillaries, and congestion of the alveolar spaces with red cells. The interlobular septa were fibrosed. There was no histological evidence of emphysema. The bronchi in the basal lobes were cystically dilated and had lost their epithelium. In the larger bronchi the epithelium had undergone squamous metaplasia (Fig. 16).

Thus bronchial arterial occlusion in the normal distribution, reduction in the lumen of the pulmonary artery near the hila, and considerable bilateral precapillary anastomoses at the periphery are features common to this fourth group.

DISCUSSION

There appear to be two principal changes in the bronchial arteries in pulmonary emphysema which might affect the lung function: (1) by occlusion, with consequent ischaemic changes in the bronchi and areas of lung supplied, and (2) by anastomoses with the pulmonary arteries, causing

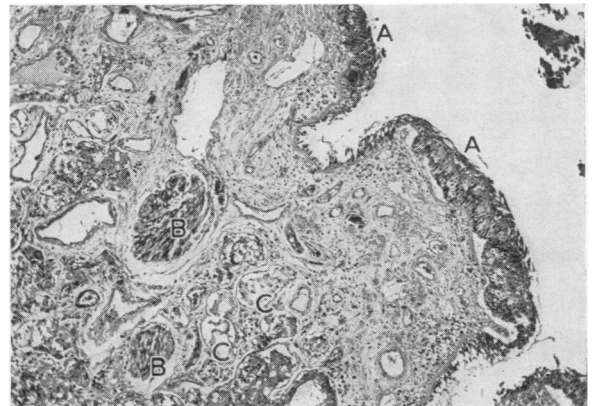


FIG. 16.—Case 18: photomicrograph of a large bronchus. A, Squamous metaplasia of the ciliated epithelium is associated with occlusion of the bronchial arteries in the wall of the bronchus (B). C, The glandular acini are greatly depleted. H. and E., $\times 45$.

altered haemodynamic effects. Of these two the second change is perhaps the simpler, and will be discussed first.

ORIGIN OF BRONCHOPULMONARY ANASTOMOSES.—Enlarged bronchial arteries have been found in certain types of congenital heart diseases, particularly with pulmonary stenosis or atresia, and they may constitute the only source of blood to the lungs (Taussig, 1947).

Virchow (1856) observed that occlusion of a pulmonary artery branch to one lobe did not lead to necrosis of that lobe, and he concluded that survival of the lobe depended on an intact compensating bronchial circulation. Ghoreyeb and Karsner (1913) and Karsner and Ash (1912), as a result of studies on the pathogenesis of pulmonary infarction, stipulated reduction in pulmonary blood flow as a prerequisite factor in the development of bronchopulmonary anastomoses and enlargement of the bronchial arteries. Liebow, Hales, and Lindskog (1949) demonstrated with a cast technique precapillary bronchopulmonary anastomoses in bronchiectasis, but their technique made subsequent histological examination of their specimens impossible and therefore failed to indicate the nature of these communications.

Our cases which fall into the third group showed bronchiectasis in one lung lobe, and the bronchopulmonary anastomoses seen in these lobes revealed thrombosis of the pulmonary arteries with proliferation of their vasa vasorum within their lumina. The vasa vasorum, which normally only supply the media of the pulmonary arteries, appear, therefore, to possess properties which can affect bronchopulmonary anastomoses in the presence of pulmonary artery occlusion. In the cases of Group 4 widespread bilateral bronchopulmonary communications were associated with large, tortuous bronchial arteries. Again, occlusive changes were seen in the pulmonary arteries, in this instance affecting the trunks near the hila. The bronchial arteries in their peripheral distribution were occluded; as this included the vasa vasorum to the main pulmonary artery trunks it may be that ischaemia of the media contributed to the lesions seen in the pulmonary arteries.

EFFECTS OF BRONCHOPULMONARY ANASTOMOSES.—These effects appear to be reflected on the general circulation as a whole and on the lungs in the areas normally supplied by the bronchial arteries.

HAEMODYNAMIC EFFECTS.—In the cases of our fourth group episodes of congestive cardiac failure

punctuated the clinical course of the illness and aggravated the respiratory symptoms. In this group alone cyanosis at rest and clubbing of the toes and fingers were present. In two cases there was electrocardiographic evidence of right ventricular preponderance, and at necropsy the right ventricles of all cases falling into this group were enlarged. In Case 18 the right ventricular pressure in systole, determined four years before death, was slightly raised. The haemodynamic result of bilateral bronchopulmonary anastomoses might, therefore, be reflected in the peripheral circulation as evidenced by cyanosis and clubbing, in the size of the right ventricle, and perhaps in the pulmonary artery pressure. Kountz, Alexander, and Prinzmetal (1936) emphasized that right ventricular enlargement is by no means constant in pulmonary emphysema. In a study of 17 cases, where the weight of each ventricle was separately determined, they found right ventricular enlargement in ten. Baldwin, Cournand, and Richards (1949) found elevated pulmonary artery pressures in a group with "cardiopulmonary insufficiency" in distinction to a group of patients with "pulmonary insufficiency" in whom the pressures were normal. Borden, Wilson, Ebert, and Wells (1950) have shown that pulmonary artery resistance, as measured by pulmonary artery pressure, bears no relationship to the ratio of the residual air to total lung volume, and that elevation of the pulmonary artery pressure, on the whole, does not permit deductions regarding the degree of lung impairment in pulmonary emphysema.

EFFECTS ON THE LUNGS.—Anastomoses of the type described were associated with the occlusion of the normal bronchial circulation and damage in the corresponding lung areas. The enlarged bronchial arteries which were seen in the cases of Group 4 conveyed their blood from the aorta to the peripheral branches of the pulmonary arteries, and failed to supply the bronchi and the other lung structures which normally depend on them. Thus a progressive increase in bronchopulmonary anastomoses suggests progressive ischaemic effects on the bronchi, pleura, and interlobular septa. With the establishment of permanent massive anastomoses the high pressure blood in the bronchial arteries flowing into the pulmonary circulation would appear to by-pass the peripheral bronchial artery tree, which, under these circumstances, could undergo regressive changes with attendant results on the dependent lung structures. This was seen in the lobes with bronchiectasis, and to a lesser extent in the cases where only simple bronchial artery occlusion was seen.

ORIGINS OF OCCLUSIVE LESIONS IN THE BRONCHIAL ARTERIES.—One possible origin of these has just been discussed. In most cases, however, there were no bilateral bronchopulmonary anastomoses, and the occlusive lesions must be otherwise accounted for. No satisfactory explanation for this is available. Brenner (1935) described increasing degrees of arteriosclerosis in the lungs of patients over 40, irrespective of pulmonary disease, and as he failed to distinguish clearly between the bronchial and pulmonary arteries it may well be that the changes he described were changes in the bronchial arteries due to age. The incrimination of chronic sepsis as a cause of the obliteration of the bronchial arteries, and of the atrophic lesions in the periphery of the lungs and bronchi, is not very satisfactory in view of the great proliferation of the bronchial arteries seen in chronic fibrocaceous tuberculosis and acute lung infections (Wood and Miller, 1938; Cudkowicz, 1952).

EFFECTS OF OCCLUSIVE LESIONS OF BRONCHIAL ARTERIES.—The anatomical changes seen in the lungs of our cases were very variable, and lung sizes ranged from normal to true bullous emphysema. The histology confirmed this in terms of the changes seen in the alveoli, which varied from distension and rupture to collapse and collagenous thickening of their walls. More constant was the loss of elastic tissue and the fibrosis in the interlobular septa, visceral pleura, and smaller bronchi. In nine of our cases the pulmonary lesions predominated at the periphery, and this corresponded with the occlusion of the peripheral bronchial circulation. In the remaining cases the pulmonary changes were uniformly severe throughout both lungs, and associated with almost total occlusion of the intrapulmonary branches of the bronchial arteries. The most mobile structures of the lung, normally very rich in elastic fibres, appeared thus to be bereft of their arterial blood supply, and the changes seen in them could be compatible with ischaemic fibrosis seen elsewhere.

The vascularity of the adhesions encountered in 13 of our cases might support pulmonary ischaemia as a contributing factor in this disease. The ability of pleural adhesions to convey a substantial collateral circulation to the lungs was empirically utilized by Barrett and Daley (1949) and experimentally confirmed by Cockett and Vass (1950). Kountz and Alexander (1934), in their review of 100 cases of pulmonary emphysema, noted varying degrees of obliteration of the pleural sacs in over 60% of their cases. •

The loss of pleural space and the absence of elastic tissue in the interlobular septa and supporting framework of the peripheral alveoli combine most probably in the pathogenesis of the bulky, inelastic bullous lung of the peripheral type of pulmonary emphysema. Christie (1944) considered peripheral enlargement of the lungs due to loss of elasticity and the expansion of the thoracic cage a result of absent diaphragmatic counterbalance and the elastic recoil of the expanded lung. The total capillary bed of the pulmonary arteries in these patients is somewhat reduced, but not sufficient to interfere with pulmonary blood flow (Christie, 1944; Borden and others, 1950; Cournand, 1950). The dyspnoea in the cases falling into Groups 1 and 3 of our present study is probably the result of a pathological pulmonary dead space and of impaired ventilation rather than of anoxia due to reduction in the total alveolar capillaries.

The cases falling into our second group had widespread fibrotic pulmonary lesions without many bullae. The severe dyspnoea and the fall in arterial oxygen saturation in these cases are probably the result of the increase in thickness of the alveolar membranes and the changes in the smaller bronchi. Functionally these patients would be considered to belong to the large group of cases of "pulmonary insufficiency" described by Baldwin and others (1949), but pathologically they could not really fit the anatomical concept of pulmonary emphysema. Although their respiratory symptoms differed somewhat from those found in our last group, the total obliteration of the intrapulmonary branches of the bronchial arteries in both groups was a surprising finding. The similarity of the lesions in the bronchi and air sacs of both groups has already been emphasized, and the impairment of ventilatory and alveolar function is very likely to be related to these lesions.

A collateral circulation to the lungs of the cases of the second group, derived from the parietal pleura, was absent in spite of the widespread occlusive changes in the bronchial arteries.

In the four cases of the fourth group episodes of congestive heart failure aggravated the respiratory symptoms. Although the pulmonary and bronchial arterial lesions in these cases resembled those of the second group, the essential difference emerged in the presence of extensive bilateral pericapillary bronchopulmonary anastomoses, and in the partial occlusion of the proximal pulmonary artery trunks.

CONCLUSION

In the light of the changes observed in the bronchial arteries the lesions in the lungs appear to vary according to the extent of the occlusion in the bronchial circulation. In the senile type of pulmonary emphysema the visceral pleura, the elastic structures in the lung periphery, and the smaller bronchi seem to have lost their arterial blood supply. In a younger group of patients who suffer clinically from pulmonary insufficiency and fail to show bullous emphysema after death, the pulmonary lesions are more universal and the bronchial circulation is almost totally occluded. Finally, in extreme instances of bronchopulmonary anastomoses, the bronchi and lung tissues show severe atrophy and fibrosis, while part of the pulmonary artery bed serves merely as a route for arterial blood to reach the proliferating collagen in the atrophic lung areas. Changes of this type probably throw a burden on both ventricles, and the expectation of life may become reduced as a result of the peripheral anoxia as a whole and the ischaemia of the lungs and heart in particular.

SUMMARY

The bronchial arteries were examined after death in 18 cases of chronic bronchitis and emphysema. Four distinct types of changes in the lungs were observed.

Obliteration of the intrapulmonary bronchial arteries and profuse pleural adhesion formation occurred in the senile type of atrophic emphysema. Obliterative changes in the bronchial arteries without pleural adhesions were seen in a younger group of patients. An intermediate group of patients showed obliteration of the intrapulmonary bronchial arteries, pleural adhesions, and, in addition, anastomoses between the bronchial and pulmonary arteries in one lung lobe only. In a final group, in which the haemodynamic changes of cor pulmonale were pronounced, there were profuse anastomoses between the vasa vasorum of the pulmonary arteries (which are derived from the bronchial arteries) and the pulmonary arteries them-

selves. This was associated with obliteration of the normal peripheral bronchial artery bed, and changes in the wall of the larger pulmonary artery trunks.

The significance of the changes in the bronchial arteries in chronic bronchitis and pulmonary emphysema has been discussed.

We are indebted to Professor J. McMichael and to Dr. C. V. Harrison for the provision of facilities in their respective departments, to Dr. J. Crofton for his interest, and to Dr. B. Lennox for his encouragement and constructive criticism. We wish to thank Miss M. S. McAdam for taking the many radiographs, Mr. E. V. Willmott, F.R.P.S., for the photomicrographs, Mr. K. Moreman, A.R.P.S., for printing the radiographs, and Mr. J. G. Griffin and his staff for the histological preparations.

REFERENCES

- Baldwin, E., Courmand, A., and Richards, D. W. (1949). *Medicine, Baltimore*, **28**, 201.
 Barrett, N. R., and Daley, R. (1949). *Brit. med. J.*, **1**, 699.
 Berry, J. L. (1935). *Quart. J. exp. Physiol.*, **24**, 305.
 — Brailsford, J. F., and Daly, I. de B. (1931). *Proc. roy. Soc. B.*, **109**, 214.
 Borden, C. W., Wilson, R. H., Ebert, R. V., and Wells, H. S. (1950). *Amer. J. Med.*, **8**, 701.
 Brenner, O. (1935). *Arch. intern. Med.*, **56**, 211, 457, 724, 976, 1189.
 Cauldwell, E. W., Sickert, R. G., Lininger, R. E., and Anson, B. J. (1948). *Surg. Gynec. Obstet.*, **88**, 395.
 Christie, R. V. (1944). *Brit. med. J.*, **1**, 105.
 Cockett, F. B., and Vass, C. C. N. (1950). *Brit. J. Surg.*, **38**, 97.
 Courmand, A. (1950). *Circulation, N.Y.*, **2**, 641.
 Cudkowicz, L. (1952). *Thorax*, **7**, 270.
 — and Armstrong, J. B. (1951). *Ibid.*, **6**, 343.
 Daly, I. de Burgh (1935-6). *Harvey Lect.*, p. 235.
 Galen, C. (1562). *Opera*, lib. 6, Cap. 3. Froben, Basel.
 Ghoreyeb, A., and Karsner, H. T. (1913). *J. exp. Med.*, **18**, 500.
 Gilmour, J. R., and Evans, W. (1946). *J. Path. Bact.*, **58**, 687.
 Karsner, H. T. (1933). "Sclerosis of the Pulmonary Arteries." In Cowdry, E. V., *Arteriosclerosis*, p. 457. New York.
 — and Ash, J. E. (1912). *J. med. Res.*, **27**, 205.
 Kaufmann, E. (1929). *Pathology for Students and Practitioners*, trans. S. P. Reimann, vol. 1, pp. 392-5. London.
 Kountz, W. B., and Alexander, H. L. (1934). *Medicine, Baltimore*, **13**, 251.
 — and Prinzmetal, M. (1936). *Amer. Heart J.*, **11**, 163.
 Küttner, C. (1878). *Virchows Arch.*, **73**, 476.
 Liebow, A. A., Hales, M. R., and Lindskog, G. E. (1949). *Amer. J. Path.*, **25**, 211.
 Loeschcke, H. (1928). Henke, F., and Lubarsch, O. *Handbuch der speziellen pathologischen Anatomie und Histologie*, vol. 3, pt. 1, pp. 599-700. Berlin.
 Miller, W. S. (1947). *The Lung*, 2nd ed. Springfield, Ill.
 Nakamura, N. (1924). *Anat. Anz.*, **58**, 508.
 Reisseisen, F. D., and Sömmering, S. T. von (1808). *Über den Bau der Lungen*. Berlin.
 Taussig, H. B. (1947). *Congenital Malformations of the Heart*, p. 464. New York.
 Virchow, R. (1856). *Gesammelte Abhandlungen zur wissenschaftlichen Medicin*, p. 285, exp. 20. Frankfurt.
 Wood, D. A., and Miller, M. (1938). *J. thorac. Surg.*, **7**, 649.
 Zuckerkandl, E. (1883). *S.B. Akad. Wiss. Wien.*, Abt. 3, **87**, 171.