

NERVE SUPPLY TO THE CRURA OF THE DIAPHRAGM

BY

J. LEIGH COLLIS, L. M. SATCHWELL, AND L. D. ABRAMS

From the Queen Elizabeth Hospital, Birmingham

(RECEIVED FOR PUBLICATION MARCH 28, 1953)

Anatomy to the surgeon is mainly of interest when it concerns parts that he ordinarily meets. In this respect the diaphragm has only attained an important place in the last 15 years. Before this the abdominal surgeon seldom saw it from below, while his thoracic counterpart was not particularly interested when his main attention was concentrated on the lung. The surgery of the oesophagus has brought these two fields together and has given a new importance to the detailed study of this structure.

Our attention was drawn to the importance of the nerve supply of the crura because of the possibility that the branch to the left half of the right crus might be interfered with during the repair of a hiatus hernia. In order to ascertain if this danger did exist we searched the literature, but no description of the nerve supply of these parts could be found. Much information was obtained about the nerve supply of the diaphragm as a whole, and it was noted that the main controversy had centred around whether or not the phrenic nerves were the sole motor innervation of its musculature. This is an important point which must be settled before confining attention to the phrenic nerve. There is a widely held view that failure to paralyse the diaphragm by a phrenic crush may sometimes be due to the nerve supply reaching the diaphragm by other routes, such as the intercostal nerves. This surgical opinion had much support from earlier anatomical authorities, but would seem to have been completely refuted by the work of Schlaepfer (1926), Jansen (1931), and Strauss (1933).

Working on a dog, Schlaepfer sectioned the left phrenic nerve, and after two years killed the animal. All the muscle of the left half of the diaphragm had atrophied and was replaced by fibrous tissue. The line of demarcation between the normal and atrophic areas was clear cut, and he made especial note that this was the case posteriorly. He concluded that the phrenic nerve provided the sole motor supply of the diaphragm. Jansen carried out similar degeneration experiments on

goats, and again found that no other nerve supply to the diaphragm existed. The interest in the work of Strauss arises from the fact that he confirmed that the above experiments applied to man. He examined diaphragms from patients who had been treated by phrenic evulsion, and demonstrated that without exception atrophy included the whole of the appropriate side. He also made careful dissections of the nerves and showed that they each divide into three branches, which he followed to the fine filaments only visible with a hand lens. He traced these nerves to the periphery of the diaphragm, and also dissected the intercostal nerves in relation to the attachment of this structure. In this way he proved to his own satisfaction that no branches of the intercostal nerves entered the diaphragm.

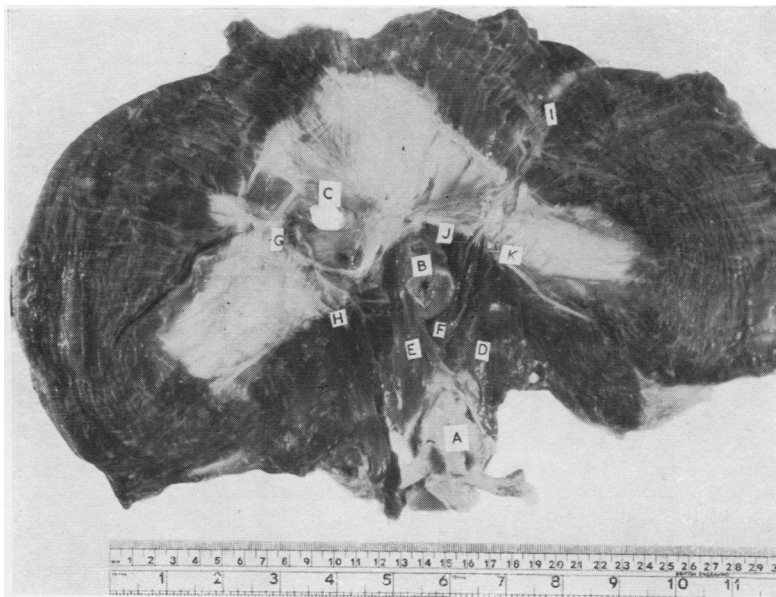
LOCAL SUPPLY OF THE CRURA

It seemed clear from the published work that the nerve supply to the crura could only come from the phrenic nerves, but it was also apparent that no information was available about how these nerves were distributed. It was, therefore, decided to carry out a series of dissections with the object of settling this point. Material was examined from 14 cadavera, and in each case a dissection was first made with the diaphragm *in situ*, followed by a more careful examination of the structure after its removal from the body.

ANATOMY

It was anticipated that as the fibres on both sides of the oesophageal orifice are spoken of as the right crus they would all be supplied by the right phrenic nerve, while the left crus would be supplied by the left phrenic nerve. Attention was especially directed to seeing if this was the case, and also to finding out how the nerve fibres from the right side reached the part of the right crus on the left side of the oesophagus. Reference to Fig. 1 will demonstrate that the supply of the fibres on the left side of the oesophagus might be achieved by branches passing in front of or behind

FIG. 1.—A view of the whole of the lower surface of the diaphragm after dissection to show the distribution of the posterior divisions of the phrenic nerves. The left phrenic nerve is seen appearing on the lower surface at I, while the right phrenic nerve appears at G. It will be found easier to follow their further course in Fig. 2.



the oesophagus. In either of these situations the nerve would be liable to damage in standard operations for hiatus hernia.

The findings were uniform in all the 14 specimens examined, with certain additional features in one case. The right phrenic nerve pierced the central tendon of the diaphragm on the lateral side of the inferior vena cava. Its posterior division passed downwards and medially under the central tendon to the right crus. It supplied all the crus to the right of the oesophagus, and also that part of the diaphragm attached to lumbo-costal arches. The left phrenic nerve pierced the diaphragm about 1 cm. to the left of the pericardium and 3 cm. in front of the central tendon. The posterior division ran backwards, downwards, and slightly medially under the central tendon, to be distributed to all the crural fibres to the left of the oesophagus, and also fibres of the diaphragm arising from the lumbo-costal arches. The crural fibres included the part of the right crus on the left side of the oesophagus and the left crus proper.

ADDITIONAL FINDINGS IN ONE CASE

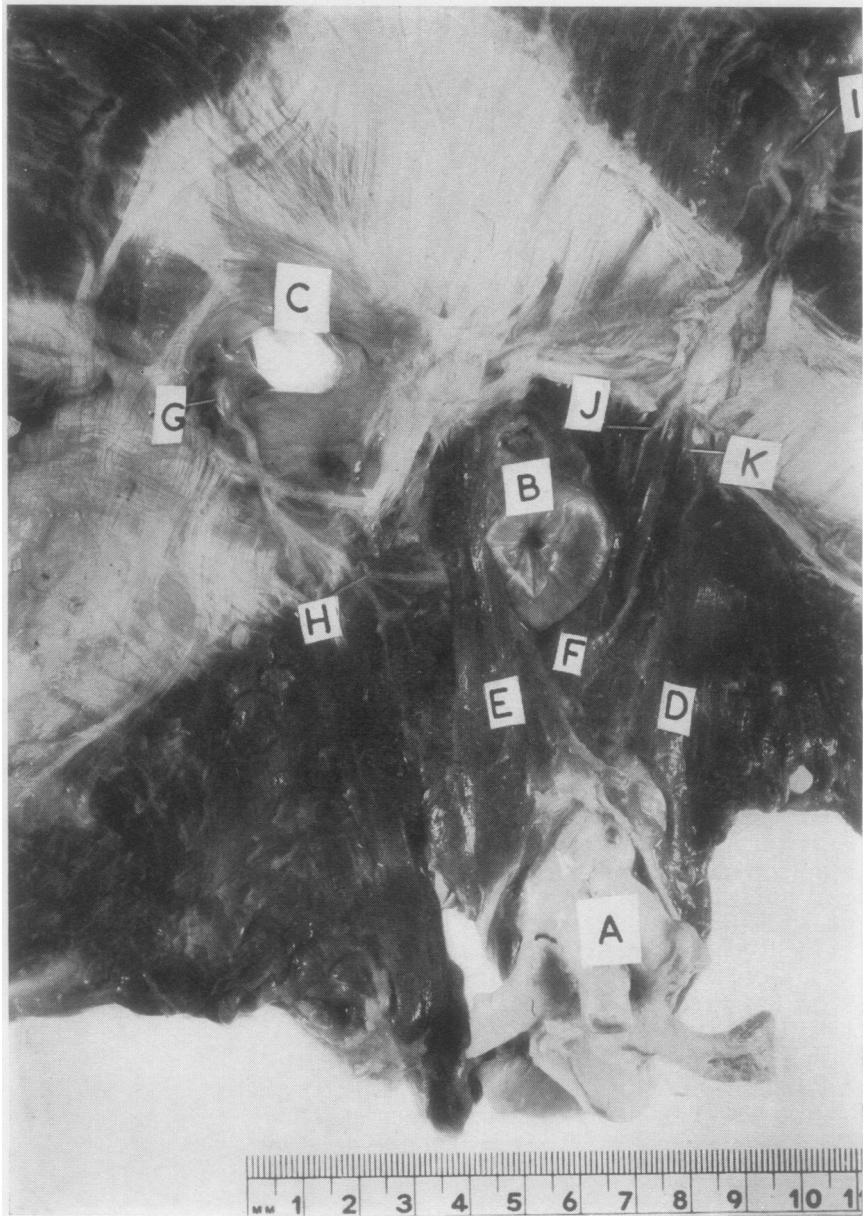
In 1907 Low described a muscle band which may arise from the left crus and pass over to the right. He pointed out that when it is present it does not take part directly in the formation of the oesophageal hiatus, but passes in the direction of the inferior vena cava. In one case a band of this type was found. On examining this

specimen it was clear that the direction of these fibres was contrary to the general habit of the fibres to pass from right to left, and that the case provided an instance of fibres from the left crus reaching the right side, which could be compared with the ordinary habit of fibres of the right crus reaching the left side. It was, therefore, of especial interest to find that the band of Low was innervated from the right phrenic nerve.

CONCLUSION

From the dissections it is clear that the muscle fibres arising from the right half of the central tendon are innervated by the right phrenic nerve, while those arising from the left half are supplied by the left phrenic nerve. This arrangement should really have been expected from the development of the diaphragm, and its appreciation leads on to the assumption that the fibres of the right crus, which are on the left of the oesophagus, are really part of the left side of the diaphragm. This muscle band has presumably gained secondary attachment to the tendon of the right crus, while in the same way the muscle of Low has migrated to the left side in gaining attachment with that crus.

Using the present terminology, the oesophagus, which is a mid-line structure, is surrounded by the two parts of a right-sided muscle, the right crus. This incongruity arose logically from the fact that the crura are always considered as originating



- (A) Aorta
- (B) Oesophagus
- (C) Hiatus for inferior vena cava
- (D) Left crus
- (E) Fibres of right crus on the right side of the oesophagus
- (F) Fibres of right crus on the left side of the oesophagus
- (G) Right phrenic nerve close to the point where it divides into three. It is shown appearing on the inferior surface of the diaphragm on the lateral margin of the inferior vena cava
- (H) The posterior division of the right phrenic nerve being distributed to fibres of the right crus on the right side of the oesophagus
- (I) The left phrenic nerve appearing on the under surface of the diaphragm
- (J) A part of the posterior division of the left phrenic nerve which is being distributed to the left half of the right crus on the left side of the oesophagus
- (K) A lateral division of the posterior branch of the left phrenic being distributed to the left crus and the posterior fibres of the diaphragm lateral to this

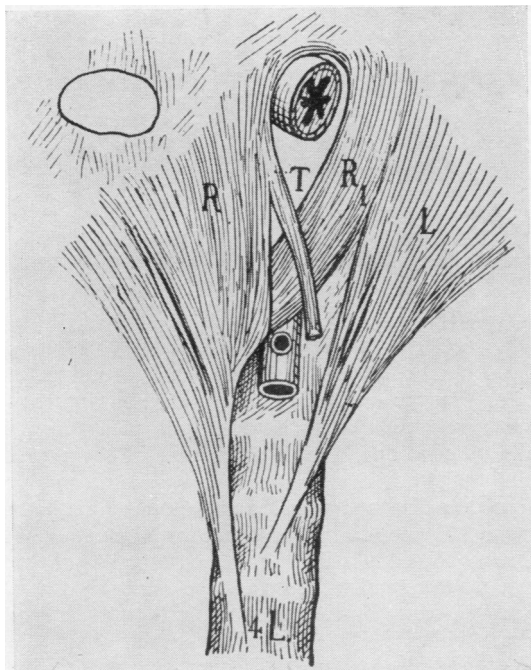


FIG. 3.—This diagram was published by Low in 1907 to show the distribution of the crural fibres. The two parts of the right crus are marked R and R1. The left crus is marked L. The muscle marked T passes over from the left crus to the area of the orifice of the inferior vena cava. One instance of the presence of this muscle was found in the 14 cadavera which we examined.

from the spine and being inserted into the central tendon. No suggestion is being made here that this terminology should be altered, but it is pointed out that the arrangements are easier to understand if the crura are thought of as arising from the central tendon. It is also suggested that if they had been described in this way no confusion would have arisen about their nerve supply.

FIG. 2.—This shows the under surface of the diaphragm in the region of the oesophageal hiatus. The posterior division of the right phrenic nerve can be seen passing to the part of the right crus to the right of the oesophagus and also to the muscle lateral to this. The left phrenic branch can be seen passing to the left half of the right crus and the left crus.

IMPLICATIONS

The implications from the above findings can be considered in two parts. First, with regard to the part of the posterior divisions of the phrenic nerves before they reach the crura, it will be seen that they are unlikely to be damaged by a surgical incision. They both travel backwards in close proximity to the attachment of the pericardium, and will be safe unless the incision cuts across this. On the right side additional protection is given by the inferior vena cava, and, provided the short part of the central tendon behind this is not cut, the nerve cannot be damaged. The second consideration is with regard to the actual supply of the right crus in the region of the oesophageal hiatus. As the nerves run down on either side of the oesophageal hiatus no damage will result from dissecting around the oesophagus, and this will still apply, however far the dissection is carried up to the central tendon or down between the two halves of the right crus. On the other hand, any incision across these muscle bands will divide the nerves, and when inserting stitches care should be taken not to place these too deeply for fear of picking up the nerves.

SUMMARY

The diaphragms of 14 cadavera have been examined.

The nerve supply to the left crus is wholly from the posterior division of the left phrenic nerve.

The left half of the right crus also receives its supply from the left phrenic nerve.

The right half of the right crus and the muscle of Low when it is present are supplied from the posterior division of the right phrenic nerve.

Certain surgical implications of the anatomy of these nerves are considered.

Our thanks are due to Mr. T. F. Dee, clinical photographer to the Queen Elizabeth Hospital, Birmingham, for the photographs reproduced here.

REFERENCES

- Jansen, J. (1931). *Z. Anat. EntwGesch.*, **96**, 624.
 Low, A. (1907). *J. Anat., Lond.*, **42**, 93.
 Schlaepfer, K. (1926). *Anat. Rec.*, **32**, 143.
 Strauss, L. H. (1933). *Z. ges. exp. Med.*, **86**, 244.