

## ABNORMAL TRANSRADIANCY OF ONE LUNG\*

BY

W. M. MACLEOD

*From the Brompton Hospital and the Thoracic Unit, St. Thomas's Hospital, London*

(RECEIVED FOR PUBLICATION AUGUST 4, 1953)

This paper describes a disease pattern with a distinctive clinico-radiological picture but of an undetermined pathology. The main features are quietening of the breath sounds and lessening of the radiographic lung markings with persistently greater transradiancy over one lung, the condition being distinguishable from simple unilateral obstructive emphysema by the small or normal size of the affected lung and the absence of evidence of bronchial obstruction. Bronchoscopy reveals no abnormality of the major bronchi, and bronchography shows the contrast oil flowing freely into an almost normal bronchial tree.

These observations are based on a study of nine well-developed cases. None of these showed

from 18 to 41 years; seven of them were men. In three the right lung was at fault. In the remaining six the left lung was diseased, and in two of those six the changes were confined to the lower lobe: two of the men were symptom free, the abnormality being an incidental finding of routine examination. The other seven persons attended hospital troubled by shortness of breath which varied from moderate annoyance on usual activities to severe distress with gentle exercise. The greatest embarrassment was noted by a woman in whom it had developed rapidly over six months. In the other patients the shortness of breath had developed slowly over several years, worsening from time to time in bouts of acute bronchitis. Sometimes wheezing was felt. Cough was not a prominent symptom, and sputum, if present, was mucoid or muco-purulent, not very copious, but increasing and thickening during acute infections.

On examination there was no clubbing, or significant abnormality outside the chest. In the chest, lessened movement, resonant percussion note, and quieter breath sounds were found on the affected side. In some instances rhonchi with prolonged expiratory wheezing were heard, but evenly over both lungs. In one case, where changes were most marked over the left lower lobe, they were accompanied by showers of fine inspiratory crepitations. This curious feature was also heard in two of four cases with evident preceding primary tuberculous infection which will be mentioned later in the paper.

### THE RADIOGRAPHIC EXAMINATION

The inspiratory postero-anterior radiograph shows increased translucency of the abnormal lung (Fig. 1). All pulmonary markings are less noticeable. The hilar shadow is smaller than on the opposite side, due in large part to the diminutive vascular shadows. This is well shown by tomography (Fig. 3). The mediastinum was central in three cases, but was displaced toward the affected side in the remaining six. This somewhat unexpected finding is significant. On expira-

TABLE I

SUMMARY OF CLINICAL FINDINGS IN NINE CASES OF ABNORMAL TRANSRADIANCY OF ONE LUNG

Case No.	Sex	Age (in Years) when First Seen	Principal Symptoms	Duration of Symptoms	Lung Affected
1	F	41	Slight dyspnoea on effort, recurrent bronchitis, severe progressive dyspnoea	2-3 yrs.	Left
2	F	25	Slight cough and bronchial catarrh	6 mths. 3 yrs.	"
3	M	32	Cough, mucoid sputum, occasional pinhead haemoptysis	"years"	Right
4	M	34	Slight shortness of breath, anxiety	10 yrs.	"
5	M	40	Slight cough and shortness of breath	20 "	Left
6	M	32	Slight shortness of breath, wheezing	2 "	"
7	M	35	Cough, moderate dyspnoea, recurrent bronchitis	3 "	Right
8	M	18	None (National Service examination)	—	Left
9	M	18	" " "	—	"

evidence of significant association with old primary tuberculous infection. I have purposely excluded from consideration several other less distinctive cases, though I believe that they are less extreme examples of this disease group. The nine patients showing characteristic changes were all adults, aged

\* Based on a communication to the Thoracic Society in February, 52.

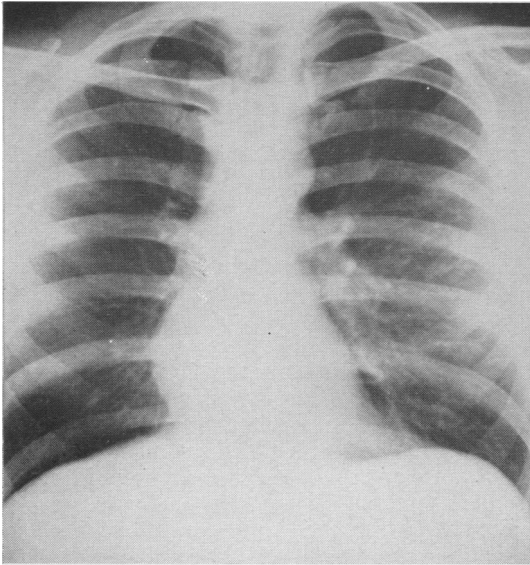


FIG. 1.—Postero-anterior view of Case 4 in inspiration. There is increased transradiancy of the right lung field; the mediastinum is displaced toward the same side.

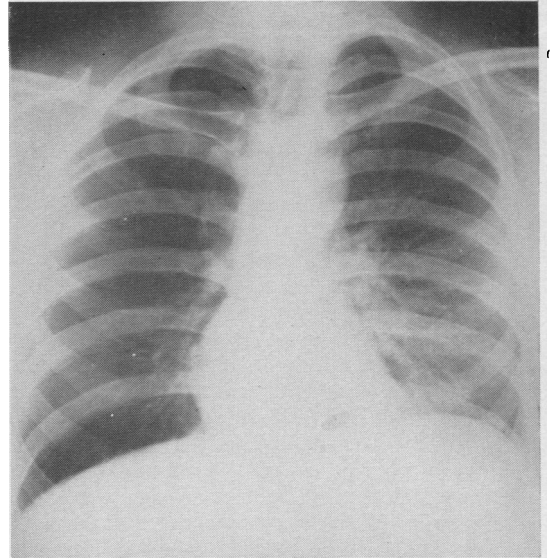


FIG. 2.—Same patient as in Fig. 1, radiograph taken in expiration.

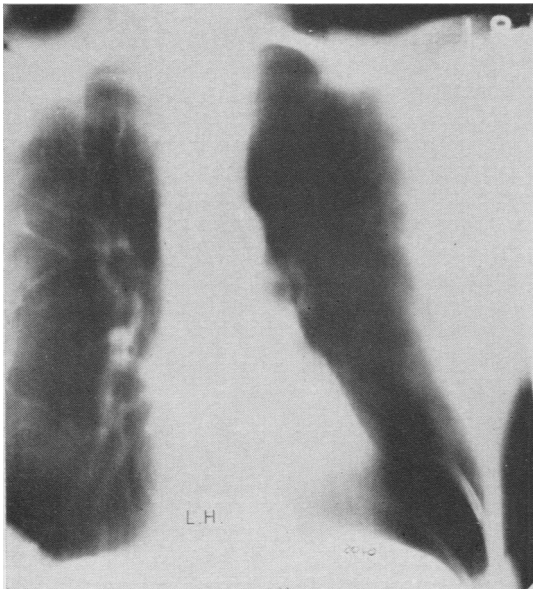

FIG. 3.—A representative tomographic section through the lung fields of a woman aged 41 years, with abnormal transradiancy of the left lung (Case 1). There is a small vascular pedicle and almost no detectable vascular markings on the left side.

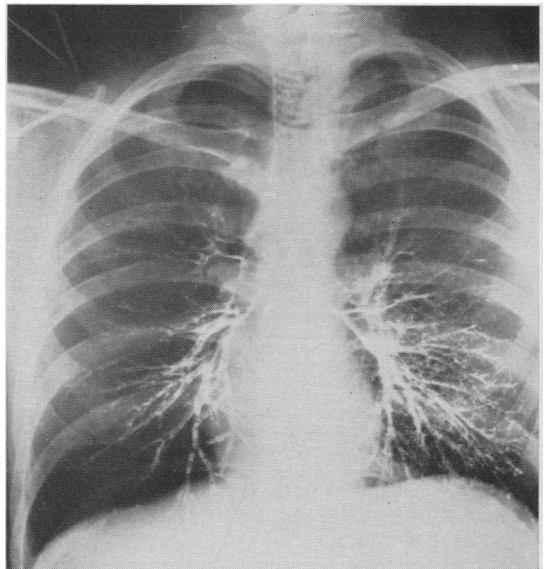


FIG. 4.—Bilateral bronchograms of Case 4. There is good filling of the abnormally transradiant right lung without bronchial distortion or displacement. Note the poor filling of the finer bronchi on this side.

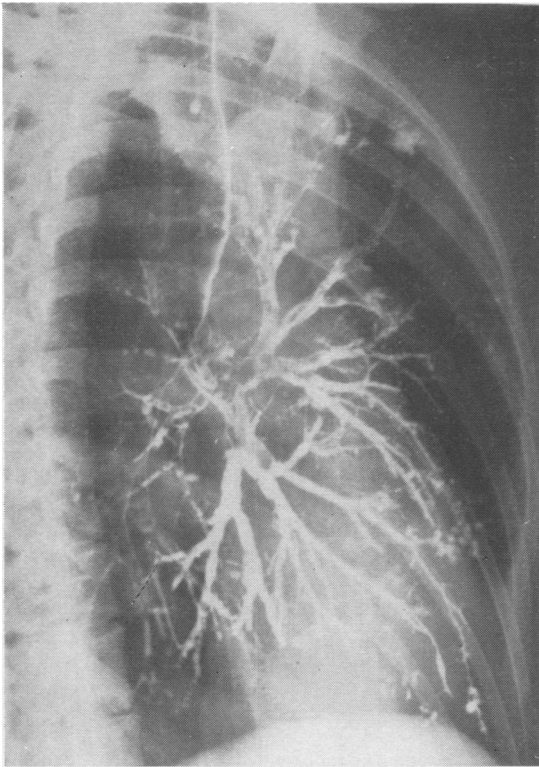


FIG. 5.—Oblique bronchographic view of the left lung of Case 1. There is slight dilatation and irregular calibre of the posterior basic bronchi. In contrast the anterior branches are thin and drawn out. There is scanty "alveolar" filling.

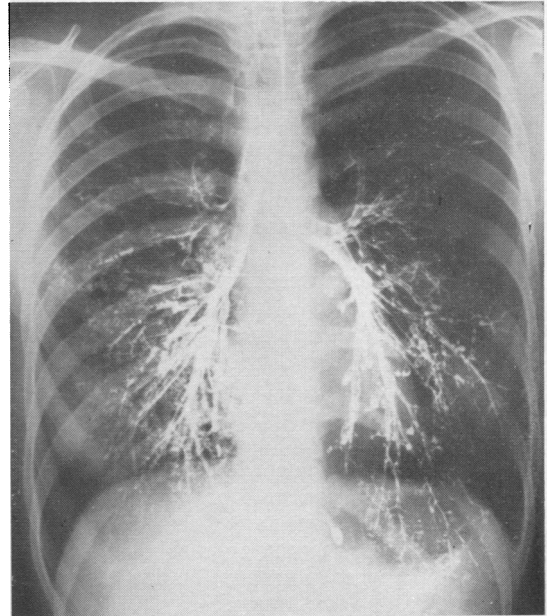


FIG. 6.—Bilateral bronchograms of Case 2. The left lung showed increased transradiancy. In addition to features shown in Fig. 5 there are several "cystic" loculi seen, especially in the left lower lobe.

tion, the difference in transradiancy between the two sides is increased, the normal side becoming more opaque (Fig. 2). The abnormal lung deflates only partially with the mediastinum moving to the centre or even over into the normal lung field. The rise in the diaphragm is also less on the diseased side. All these changes are well demonstrated by fluoroscopy.

On bronchography, the oil flows freely into the bronchi of the diseased lung (Fig. 4). This confirms the absence of any significant block in the major bronchi; and the wide fanning of the branches of the bronchial tree is very different from the picture seen in gross bullous emphysema where there is poor filling of the bullae and the healthier bronchi are deflected, sweeping round the emphysematous area. In the cases being described there is no noticeable bronchial displacement, and all the segmental bronchi are present and filled within the abnormal lung. The shadows of the bronchial lumina are normal or only slightly irregular in calibre (Fig. 5). In three of the cases, attached to the bronchi-like buds, are several loculi of oil (Fig. 6). Their significance is unknown. Another

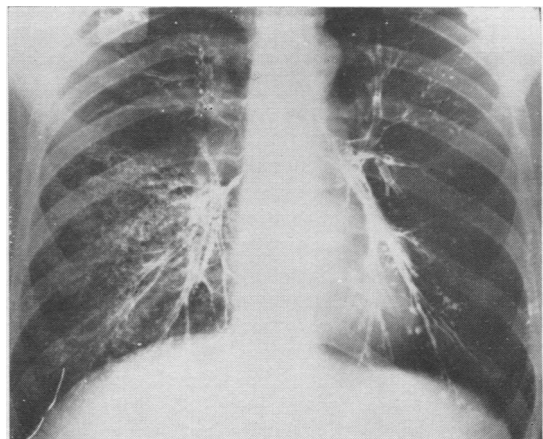


FIG. 7.—Bilateral bronchograms of a man aged 32 years (Case 6). The alveolar filling of the normal right lung is contrasted with its almost complete absence in the more transradiant left lung, in spite of reasonable filling of the bronchial tree.

interesting difference between the two lungs is the scanty or absent "alveolar filling" on the abnormal side. The bronchi of both lungs were outlined at one examination, and the poor filling of the finer bronchial radicles in the diseased lung was very noticeable (Fig. 7).

Bronchoscopy was performed in every case, and was absolutely normal. Several cases which showed narrowing of a major bronchus, though only of slight degree, were excluded from this series. In other respects they were similar to the nine cases described, and I believe that the stenosis was not a significant factor in the persistence of the abnormal changes.

When these cases were first seen a presumptive diagnosis of obstructive distension, secondary to a partial block of a major bronchus, was usually made. This was soon disproved by the investigations described. Gross bullous emphysema, the rare congenital cystic lung, and complete or partial pneumothorax were excluded by adequate radiography. Distension or emphysema, compensatory to a collapsed or diseased lobe, were excluded by bronchography. Elementary precautions and care will avoid confusion with anomalies of the chest wall and differences in penetration due to technical errors and faulty positioning.

#### DISCUSSION

The present series was studied only by clinical and radiological methods. No material has been available for morbid anatomical or histological examination. It is unavoidable, therefore, that information regarding the true nature of these cases must for the present be incomplete. Nevertheless, various processes that might have led to the development of this distinctive picture may usefully be reviewed. First let us consider the evidence in favour of a congenital developmental defect. Under the title of "Congenital Lobar Emphysema" Robertson and Stewart James (1951) describe lung changes in five young patients, aged from 2 weeks to 11 months. In each patient the disease was confined to one lobe, the right upper in three instances, and the left upper and the right middle in one each. The lobe was distended, compressing the remaining healthy lobes of the lung and pushing the mediastinum over to the other side with embarrassment of the normal lung. All lobes showed dilated alveoli with thinning and rupture of the alveolar walls, but gross bullous formation was not present. In three of the cases no lesion of the main bronchus was found, but in one case a large vein hooked round the right upper lobe bronchus and accompanied a narrowing of the bronchial lumen. In the remaining case, valve-like mucosal flaps were

present in the right upper lobe bronchus and were held responsible for the obstructive distension of the lobe. A similar mucosal flap was reported by Royes (1938) as an incidental necropsy finding in an adult with an emphysematous right middle lobe. Other cases of unilobar emphysema in infants and children have been reported by Leahy and Butsch (1949), Shaw (1952), Williams (1952), and Fischer, Potts, and Holinger (1952). Shaw noted that the bronchi of the affected lobes were abnormally flaccid and suggested that a localized chondromalacia of the bronchus results in expiratory bronchial collapse with obstructive emphysema distal to the block. Ferguson and Neuhauser (1944) had previously reported absent cartilaginous rings in the left main bronchus of two cases with emphysema of the whole lung. Fischer and others (1952) considered that the unusually low attachment to the left pulmonary artery of a persistent ductus arteriosus was the causative factor in two of their six cases. Only two of my cases showed changes predominant in one lobe. In both instances the left lower lobe was involved, and in neither was such gross distension as is reported in lobar emphysema of infants. It is probable that bronchoscopy and complete bronchography, with inspiratory, expiratory, and delayed contrast pictures, would detect the presence of a mucosal flap or significant weakness of the bronchial wall. These anomalies were not found in this series.

Congenital cystic disease of the lung, especially when it presents with multiple peripheral bronchial dilatations, would, if unilateral, show increased transradiancy of one lung. In adults this rare anomaly is difficult to distinguish from acquired bronchial disease (Sellers, 1938).

I have already commented on the small vascular shadows seen by radiography in these lungs. The pulmonary circulation adjusts itself to the oxygen uptake and in these examples the diminutive vessels are probably secondary to the poorly functioning lung. There is no evidence to support the suggestion that the lung changes follow a congenital hypoplasia or absence of one pulmonary artery or a developmental abnormality of the bronchial arteries (Madoff, Gaensler, and Strieder, 1952). An interesting case of unilateral emphysema in a boy of 6 is recorded by Swyer and James (1953). In their case radiographic studies, including angiography, suggested a hypoplasia of the right pulmonary artery, but this was in fact not demonstrable in the resected lung. There was, however, a widespread obliteration of the peripheral lung capillaries and the authors presumed a functional insufficiency of the right pulmonary artery secondary to the lung disease.

If we now turn to acquired disease processes there are several conditions which should be considered. There is an obvious similarity between this group and hypertrophic or vesicular emphysema. Laennec (1819, translated by Forbes, 1834) was fully aware that emphysema could develop solely or predominantly in one lung.

"Emphysema may affect both lungs at the same time, one only, or part of one or both. In the latter case, and indeed in any case, as long as there do not exist vesicles of considerable size on the surface of the lungs, it is easy to overlook the disease in the dead subject. . . ." Later he remarks: "When a single lung is affected, it becomes much more voluminous than the other—so much so, indeed, as sometimes to pass aside the heart and mediastinum, and to cause an evident enlargement of the bony walls of that side of the chest."

We may assume that Laennec found no major bronchial stenosis, but whether the open bronchi communicated freely with the emphysematous lung must remain unknown. Three of the nine cases in my series might well have been instances of unilateral vesicular emphysema, though the lungs are not so voluminous nor the changes so extreme as noted by Laennec at necropsy. For example, a woman of 41 years was admitted to St. Thomas's Hospital under the care of Dr. John Anderson. She gave a remarkably short history of only four months' progressive shortness of breath. She then suffered from an attack of acute bronchitis. This led to severe distress and she became bed-fast. She was admitted six months after the onset of her symptoms. She showed the characteristic features described above with evidence of bilateral bronchitis. On inspiration the mediastinum was central, but swinging away from the transradiant lung on expiration. Bronchography (Fig. 5) and bronchoscopy were characteristic of the group. The pleural pressures at the start of an induced pneumothorax were -12 cm. water on inspiration and +4 cm. water on expiration, being a clear indication of the diminished elastic recoil of the lung.

These features suggest that the disease in this instance is similar in nature to that seen in generalized emphysema, but that for obscure reasons it has developed predominantly in one lung. Whether such one-sided changes, together with the bilateral bronchitis, are a prelude to generalized lung disease with an equalizing increase in transradiancy of the more normal lung must be left to further observation.

Bilateral bronchial catarrh was found in five of the nine cases. Where a prolonged expiratory sound was present it appeared equally in the two lungs, though it was quieter and more difficult to

hear on the diseased side. However, the quality of the breath sounds is a very rough guide to the degree of bronchial obstruction. The poor "alveolar filling" seen on the more transradiant side at bronchography is suggestive of a significant difference in calibre of the terminal bronchi and bronchioles. It is well recognized that gross unilateral bronchial disease is commonly associated with emphysema. Such lungs, apart from the obvious differences in bronchial dilatation, may present clinically and radiologically in a similar manner to those under review.

An account of advanced unilateral emphysema in a man of 34 years is to be found in the case records of the Massachusetts General Hospital (1950). The patient was known to have had only one lung for over 19 years. He had a greatly distended left lung with displacement of the mediastinum to the right. The lung was examined after successful pneumonectomy and showed severe emphysema throughout. There were no giant bullae, the pulmonary artery and veins were relatively small, while the bronchial arteries were about four times normal diameter. Scattered through the lung were groups of epithelioid cells, and giant cells with tubercle formation. These changes were interpreted as sarcoidosis. The hilar nodes were also affected. Many of the foci were collagenous and in a healing phase. The relation between the two diseases is open to conjecture, but it is not impossible that the emphysema resulted from the extensive scarring of healed sarcoidosis. Little is known of the state of the lung years after resolution of sarcoid infiltration. In this case the evidence is far from complete, and in a disease which so frequently affects both sides knowledge of the remaining lung would be necessary before any more definite conclusions could be drawn.

In six of the cases studied, the mediastinum on inspiration was displaced into the hemithorax on the diseased side. This is very different from Laennec's observations and clearly requires a different explanation. It suggests that the lung was irreparably damaged during the growing period resulting in retarded growth, and that later it attempted unsuccessfully to fulfil its space-occupying function by distension of its dwarf-like lobes. The factors responsible for such damage are for the present unknown, but I will mention four cases similar in many respects to those described above which in addition show evidence of having in the past had a fairly severe primary tuberculous infection of the same lung. The story of A.Q. is typical. She was a woman of 31 years whose right lung showed increased transradiancy affecting mainly the middle and lower lobes. The anterior segment

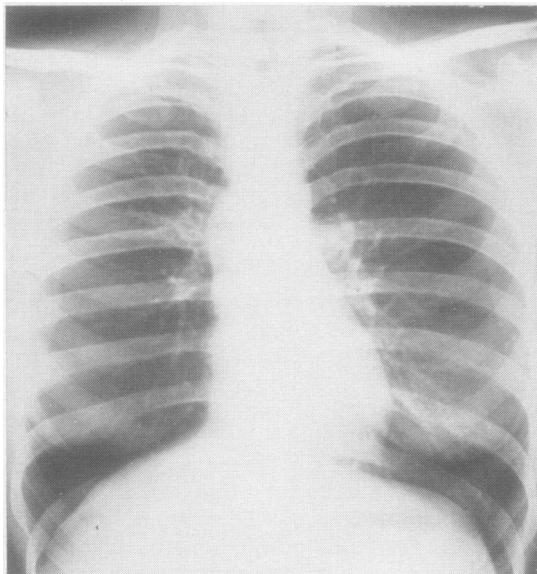


FIG. 8.—Abnormal transradiancy of the right lung associated with old primary tuberculosis. Postero-anterior view in a woman of 31 years. Emphysema of the lower and middle lobes with streaky shadowing upwards and outwards from the right hilum.

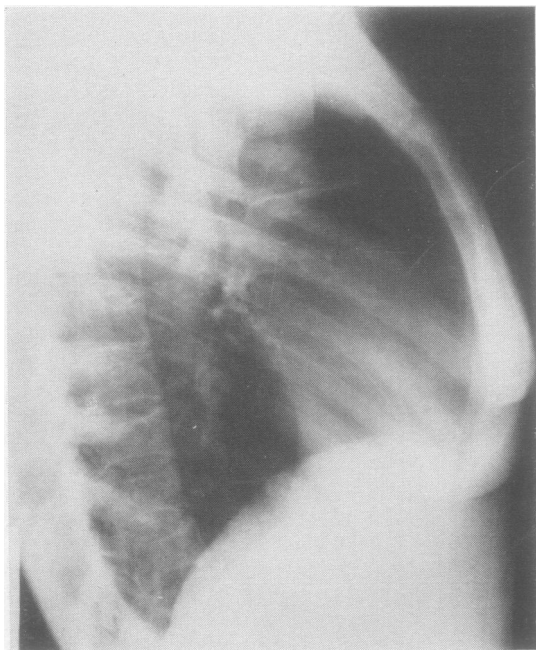


FIG. 9.—Lateral view of same patient as shown in Fig. 8. The collapse of the anterior segment is shown.

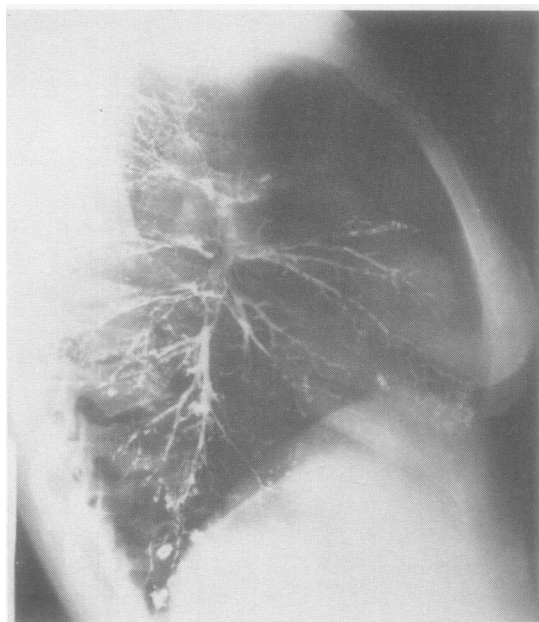


FIG. 10.—Right lateral bronchographic view of same case as in Figs. 8 and 9. The bronchial tree is normal except for the poorly filled anterior segment of the upper lobe.

is collapsed and there is calcification incorporated in the upper hilum (Figs. 8 and 9). This interpretation was confirmed by bronchography (Fig. 10) which also revealed an otherwise fully expanded bronchial tree. Bronchoscopy was normal. The extensive changes in the lower and middle lobes can hardly be attributed to compensatory distension of a collapsed anterior segment of the upper lobe; it is out of all proportion. It is more reasonable to postulate that at the time of the active primary infection, in addition to disease in the anterior segment, the lower and middle lobes were also involved or were damaged by distension due to partial bronchial obstruction by lymph-node pressure on the right main bronchus, and that, in spite of resolution of the disease or relief of the obstruction, the lower and middle lobes had sustained permanent damage.

It is very possible that there are other developmental and acquired disease processes which could produce an abnormally transradiant lung, but for the present, in the absence of morbid anatomical and histological studies, this disease group must remain a clinical and radiological syndrome awaiting further observation and fuller investigation.

#### SUMMARY

A disease pattern with a distinctive clinico-radiological picture is described. The main features are



lessening of the breath sounds and abnormal transradiancy of one lung. There is neither obstruction of the main bronchi nor gross bullous emphysema. The causation is unknown, but possible factors that might have led to this condition are reviewed.

I should like to express my thanks to the staff of the Thoracic Unit, St. Thomas's Hospital, and the physicians of the Brompton Hospital for allowing me to use the records of patients under their care. In particular I am greatly indebted to Dr. J. G. Scadding for his interest and help in the preparation of this report.

## REFERENCES

- Ferguson, C. F., and Neuhauser, E. B. D. (1944). *Amer. J. Roentgenol.*, **52**, 459.
- Fischer, H. W., Potts, W. J., and Holinger, P. H. (1952). *J. Pediat.*, **41**, 403.
- Laennec, R. T. H. (1819). *Traité de L'Auscultation Médiate*, 3rd ed., 1831. Chaudé, Paris. Trans. J. Forbes (1834). *A Treatise on the Diseases of the Chest*, 4th ed., pp. 143, 144.
- Leahy, L. J., and Butsch, W. L. (1949). *Arch. Surg., Chicago*, **59**, 466.
- Madoff, I. M., Gaensler, E. A., and Strieder, J. W. (1952). *New Engl. J. Med.*, **247**, 149.
- Massachusetts General Hospital Case Records (1950). *Ibid.*, **242**, 149.
- Robertson, R., and James, E. S. (1951). *Pediatrics*, **8**, 795.
- Royes, K. (1938). *Brit. med. J.*, **2**, 659.
- Sellors, T. H. (1938). *Tubercle*, **20**, 49.
- Shaw, R. R. (1952). *Pediatrics*, **9**, 220.
- Swyer, P. R., and James, G. C. W. (1953). *Thorax*, **8**, 133.
- Williams, M. H. (1952). *J. thorac. Surg.*, **24**, 522.