

## Congenital coronary artery aneurysms

R. Seabra-Gomes, Jane Somerville, D. N. Ross, R. Emanuel,  
D. J. Parker, and M. Wong

*From the National Heart Hospital and Cardiothoracic Institute, London*

*Two patients, aged 4 and 23 years, with congenital aneurysms of the coronary arteries are described. The pathology was different in each and required different surgical techniques involving obliteration of the aneurysm or establishing coronary flow with a saphenous vein graft. The clinical and radiological features are described.*

Aneurysms of the coronary arteries are rare, and it is only after the advent of coronary arteriography that they have been diagnosed in life. They may be due to atherosclerosis, necrotizing arteritis, mycotic emboli, syphilis, or trauma, and occasionally they are congenital. The prognosis appears to be poor and death can occur suddenly from rupture, peripheral coronary embolism, or bacterial endocarditis (Packard and Wechsler, 1929; Scott, 1948; Plachta and Speer, 1958; Daoud *et al.*, 1963; Sayegh, Adad, and Macleod, 1968; Konecke *et al.*, 1971; Ebert *et al.*, 1971). Recently surgical treatment has been successful. This report concerns two patients with congenital aneurysms of coronary arteries which were diagnosed by investigation and operated upon at the National Heart Hospital (D.N.R.).

### Case reports

#### Case 1

A Greek boy, aged 4 years, presented with dyspnoea for 6 months. His development was normal until the age of 3½ years when he was admitted to a hospital in Athens for an appendicectomy. Within a few days of operation he became breathless and ill. A heart murmur was detected and a provisional diagnosis of ventricular septal defect made. Antifailure treatment was instituted. Despite this he was noted to be tired and pale, breathless on exertion, and occasionally orthopnoeic.

On examination, the jugular venous pressure was raised after effort and the apex was displaced to the left. Pulmonary valve closure was loud and there was a short apical late systolic murmur. The second sound split normally. The electrocardiogram showed an old extensive anteroseptal infarction (Fig. 1). On the chest x-ray there was cardiomegaly with a curious bulge on the left heart border (Fig. 2). The clinical diagnosis was primary myocardial disease with a possible coronary

abnormality, and the significance of the curious shadow in the chest radiograph was not appreciated at this time. At cardiac catheterization the resting pulmonary artery pressure was 45/20 mmHg with a left ventricular end-diastolic pressure (pre A) between 5 to 10 mmHg and an A wave of 25 mmHg. There were neither shunts nor gradients. Left ventricular angiography revealed a localized dyskinctic area at the apex. Aortography showed aneurysms on the left and right coronary arteries which were better demonstrated by selective coronary arteriography using the Judkins technique with Puck films (Fig. 3). The aneurysm on the anterior descending coronary artery was irregular inside suggesting the possibility of clot.

It was assumed that the anterior myocardial infarction was probably due to a clot from an aneurysm in the left anterior descending coronary artery. As the right coronary artery was dominant it was considered that surgical treatment of the aneurysm was indicated before thrombosis occurred in the right coronary aneurysm, or there was further embolism.

At operation there was a large egg-shaped mass attached to the right coronary artery and another close to the root of the pulmonary artery displacing the left atrial appendage. There was a non-contractile area in the apex of the left ventricle. Cardiopulmonary bypass was established and the left coronary artery aneurysm, which involved the origin of the anterior descending, was opened and found to contain old layered and fresh clot which was shelled out to reveal a bleeding proximal coronary artery. A coronary cannula was inserted and perfused the heart retrogradely while the distal orifice was found in the sac. This was very stenotic and was oversewn. An end-to-side anastomosis was made between a saphenous vein graft and normal distal anterior descending artery which had a healthy wall. Proximally, the vein was anastomosed to the orifice of the anterior descending coronary artery in the aneurysm. The aneurysm in the right coronary artery was incised and had no clot in it. Both artery orifices were seen in the aneurysm and a length of saphenous vein was interposed to reconstitute the vessel end-to-end.

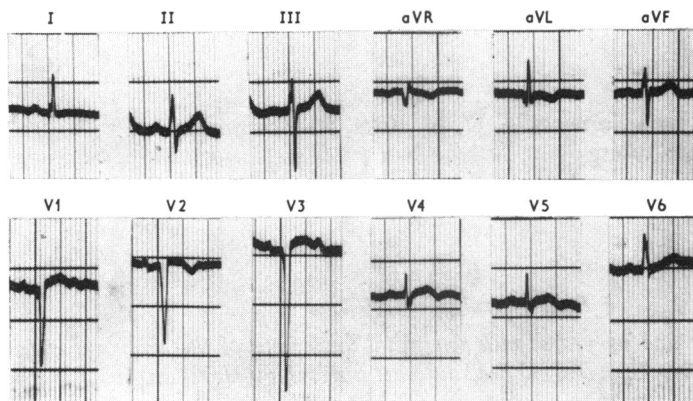


FIG. 1 *Preoperative electrocardiogram from Case 1 showing old anteroseptal myocardial infarction.*

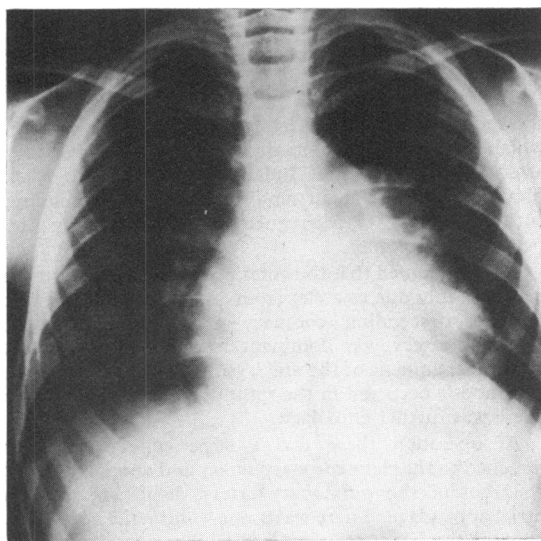


FIG. 2 *Penetrated chest radiograph of Case 1 at the age of 4 years. This shows cardiac enlargement and prominent bulge in the area of the left atrial appendage on the left heart border, which is caused by the aneurysm of the left anterior descending coronary artery.*

The heart came off bypass without difficulty; electromagnetic flowmeter measurements in the right graft showed a flow of 90 ml/min, and in the left 25 ml/min. After return to the recovery ward the cardiac rhythm was unstable with multifocal ventricular ectopics, partially controlled by lignocaine. Six hours after operation he developed a low cardiac output with ventricular

tachycardia. The chest was opened and it was noted that the area supplied by the right coronary artery was contracting poorly. The right coronary interposed graft was opened and it did not bleed. A temporary shunt was inserted into the proximal and distal right coronary arteries but the heart failed to improve. Consent for necropsy was not given.

### Case 2

A 23-year-old Malaysian girl was well and asymptomatic until 1969 when during routine examination a soft heart murmur was noticed after a complaint of chest pain on effort in the previous 6 months. She was catheterized at the University Hospital in Malaysia and a diagnosis of coronary artery fistula was made though no increase in oxygen saturation was detected in the right side of the heart.

On examination there was a palpable pulsation over the third left intercostal space and the apical impulse was displaced to the left. On auscultation the first sound was normal, followed by a systolic ejection click (0.07 sec), and the second sound was normally split (Fig. 4). A soft high-pitched continuous murmur was audible over the praecordium with maximum intensity at the left sternal edge. There was also an apical pansystolic murmur.

The electrocardiogram suggested anterior ischaemia (Fig. 5) and on the chest radiograph there was a localized bulge on the left lower cardiac border (Fig. 6). Reinvestigation confirmed normal resting left and right heart pressures, with no shunts detectable by careful multiple sampling. The left ventricular angiogram showed good ventricular contraction and two persistent opacities were seen to indent the anterior wall of the ventricle, filling presumably from the left coronary artery (Fig. 7). The left coronary injection showed an aneurysmal dilatation near the origin of the left anterior descending coronary artery which seemed to communicate with another aneurysmal sac. The right coronary artery was normal.

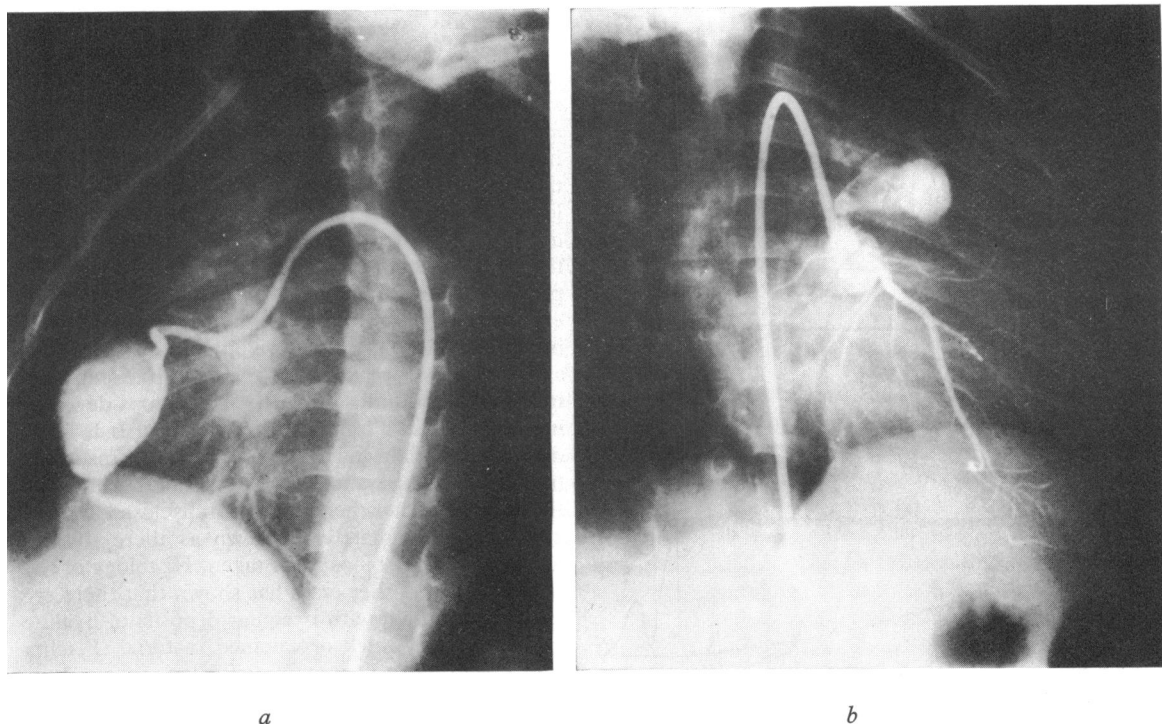


FIG. 3 Coronary arteriogram in Case 1. (a) Right coronary arteriogram in left anterior oblique projection showing a well-defined egg-shaped aneurysm, and normal terminal distribution of the right coronary artery. (b) Left coronary arteriogram in right anterior oblique projection showing a partially occluded aneurysm at the origin of the left anterior descending coronary artery.

No contrast was seen to enter either ventricle from the coronary injections.

At operation an easily identifiable aneurysm was obvious at the base of the pulmonary artery between it and the left atrial appendage in the position of the bifurcation of the main left coronary artery. On the anterolateral aspect of the heart a large intramyocardial bulge was felt. The right coronary artery was large with big branches running across the front of the right ventricle towards the apex. The circumflex coronary artery was a major vessel supplying all the posterior and lateral wall of the left ventricle. There was no identifiable left anterior descending coronary artery.

Using cardiopulmonary bypass, the left ventricle was decompressed, but both swellings remained filled. The aneurysm was opened transversely and a probe could be passed freely through the proximal orifice into the circumflex artery. There was a further orifice in the aneurysm distally and a probe passed down it entered the distal intramyocardial swelling. An incision was made over the distal swelling down through about 5 mm of myocardium before it was opened. It was thus buried and lying within the muscle of the anterior wall of the left ventricle. Careful probing did not reveal a communication with the ventricular cavity, or with the

venous system. The communication between this 'sinusoid' and the true aneurysm, and between the aneurysm and the main left coronary artery was restored with 'teflon' support. Coronary perfusion was restricted and there was no evidence of blood flow either into the blind sinusoidal sac or into the aneurysm, and the whole true aneurysm was obliterated over 'teflon'. The sinusoidal sac was then obliterated from below with multiple sutures over absorbable sponge and the myocardial incision was closed. The heart came off bypass without difficulty.

Convalescence was uneventful. The continuous murmur disappeared (Fig. 4) and the electrocardiogram showed persistent T wave inversion over the left chest which lessened but was still present six months later (Fig. 5). There were no electrocardiographic changes after effort and the chest radiograph was normal (Fig. 6). She was leading a physically active life without symptoms.

### Discussion

Congenital abnormalities of the coronary arteries may take different forms including absence, abnormal distribution, aneurysm formation, fistulous

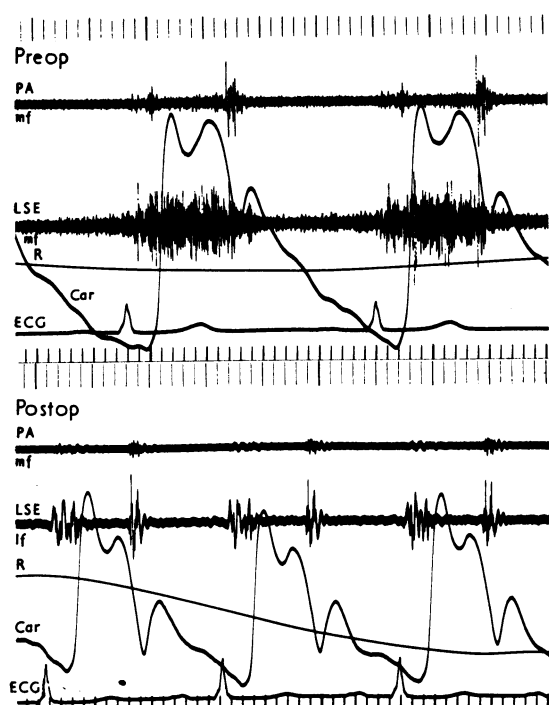


FIG. 4 Pre- and postoperative phonocardiograph in Case 2. Simultaneous recording of phonocardiogram (pulmonary area (PA) and left sternal edge (LSE)), with external carotid pulse tracing (Car), electrocardiogram (ECG), and respiratory tracing (R). Notice the systolic ejection click, 0.07 sec after  $S_1$ , and the continuous murmur at LSE disappearing postoperatively.

communication, unusual origin, and stenosis or occlusion (Hallman, Cooley, and Singer, 1966). The first reported case of coronary artery aneurysm in 1812 by Bougon (Jarcho, 1969) seemed to be acquired. True congenital aneurysms are rare. In young patients it is assumed that the basic abnormality in the coronary artery is a congenital one, but it is conjecture to state whether the aneurysm was present at birth or developed later. The strange dilated sinusoid found with the aneurysm in Case 2, and the youth of Case 1 strongly suggest that both had genuine congenital abnormalities. Congenital aneurysms are often associated with fistulous communications. This was certainly not so in Case 1 and though the soft continuous murmur in Case 2 strongly suggested the possibility, none was found or seen. The murmur must have arisen from turbulence within the aneurysm or sinusoid.

Although coronary artery aneurysms can be

found at any age, those that are obviously acquired occur later and more frequently in the male, with a ratio of 14:1 (Belsky, Scharnoff, and Gilbert, 1955), suggesting that degenerative arterial disease may have an important aetiological role. Congenital aneurysms have a more even sex distribution but their formation is difficult to understand. Several embryological possibilities have been suggested (Belsky *et al.*, 1955; Frithz, Cullhed, and Björk, 1968). One theory is secondary aneurysm formation from a previous fistula (Mozen, 1956) which could not explain the present cases. Another is that there is inhibition of the normal development of the coronary vessels with retention of the primitive sinusoids in the myocardium, so that the artery stops developing and ends in a blind sac as in Case 2. It is more difficult to explain the origin of the aneurysms of the first patient where there was no fistula or abnormal sinusoid. Whether there was an undisclosed arteriopathy is unfortunately unknown as there was no necropsy and no biopsy was taken. Histology of the arterial wall in other cases has shown that there are areas of thinning, with irregular deposits of hyaline and plaques of thick or calcified material (Plachta and Speer, 1958; Dawson and Ellison, 1972). Rupture or aneurysm formation can occur through these thin areas, and thrombus formation can occur on the irregularities.

Patients with coronary aneurysms may present with cardiac infarction or with angina if thrombus has formed and blocked a coronary artery (Crocker, Sobin, and Thomas, 1957; Barclay *et al.*, 1964; Mattern *et al.*, 1972), or breathlessness from impaired left ventricular function. The first patient presented with left ventricular failure of unknown origin and it was the presence of anteroseptal infarction which suggested that this might be due to an underlying coronary abnormality. The second presented with angina. It is likely that the onset of symptoms in the first case was precipitated by myocardial infarction which occurred at or soon after the appendicectomy; perhaps precipitated in part by the thrombotic tendency after operation or a fall in pressure during the procedure. Presumably the second patient had angina because the blood supply was inadequate for the demands on the left ventricle, but if this is the explanation it is curious that it did not occur earlier, and that the symptoms disappeared after obliteration of the sac. The improvement may relate to closure of an unrecognized fistula.

The electrocardiogram in coronary artery aneurysm can be normal if the coronary circulation is not interfered with by pressure, or thrombus, or, as has been shown here, it may show myocardial ischaemia or infarction. It is difficult to know if the muscle in

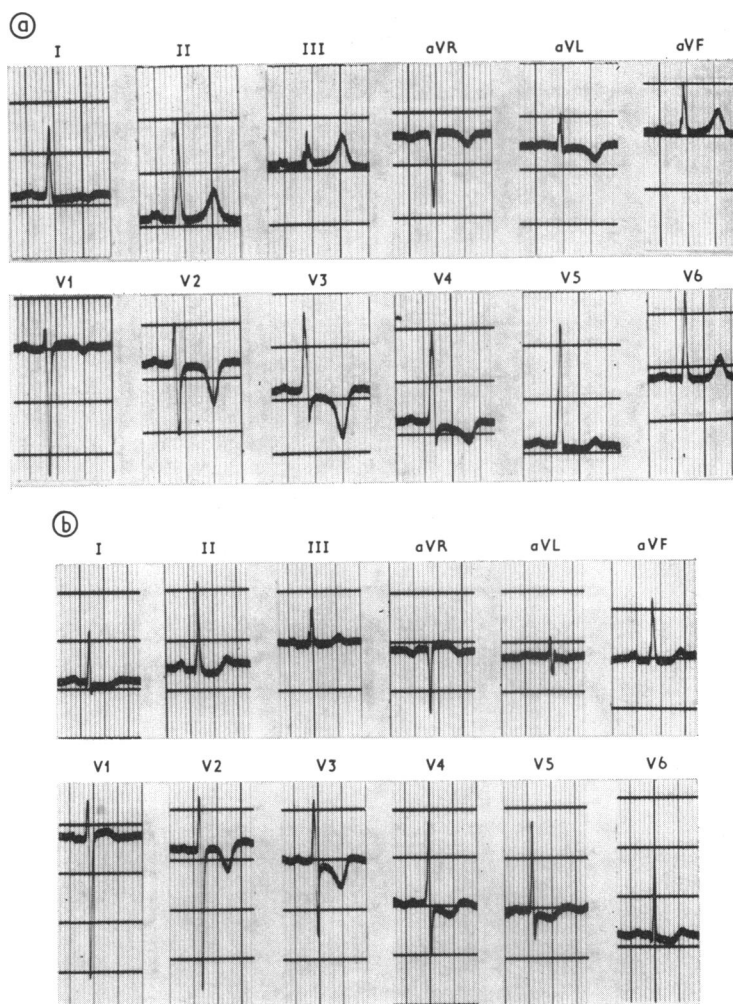


FIG. 5 Electrocardiograms from Case 2. (a) Before operation showing anteroseptal myocardial ischaemia with deep and symmetrical T wave inversion in V2-3. (b) Six months after operation showing similar changes.

Case 2 was ischaemic or whether the T wave changes resulted from a 'bare' area in the myocardium where the aneurysm and sinusoid were taking up the space normally made up of cardiac septal muscle.

One of the helpful diagnostic tests in both patients was the chest radiograph which in both showed the unusual bulge near the base of the pulmonary artery. Dawson and Ellison (1972) have noted this, and calcification may also be present either in clot or the aneurysm wall.

Surgical treatment must be based on accurate anatomical demonstration and requires selective coronary angiography and careful right heart samp-

ling to detect fistulas. Left ventricular angiography is needed, as in any form of coronary disease, to assess left ventricular function.

The complications of coronary aneurysms show the need for surgical treatment which has been achieved successfully in 9 reported cases (Sherkat, Kavanagh-Gray, and Edworthy, 1967; Björk and Björk, 1967; Frithz *et al.*, 1968; Cafferky *et al.*, 1969; Ghahramani *et al.*, 1972; Dawson and Ellison, 1972; Mattern *et al.*, 1972). Initially, ligation of vessels arising from the aneurysm was performed and is compatible with survival, but this does nothing to maintain or improve the blood

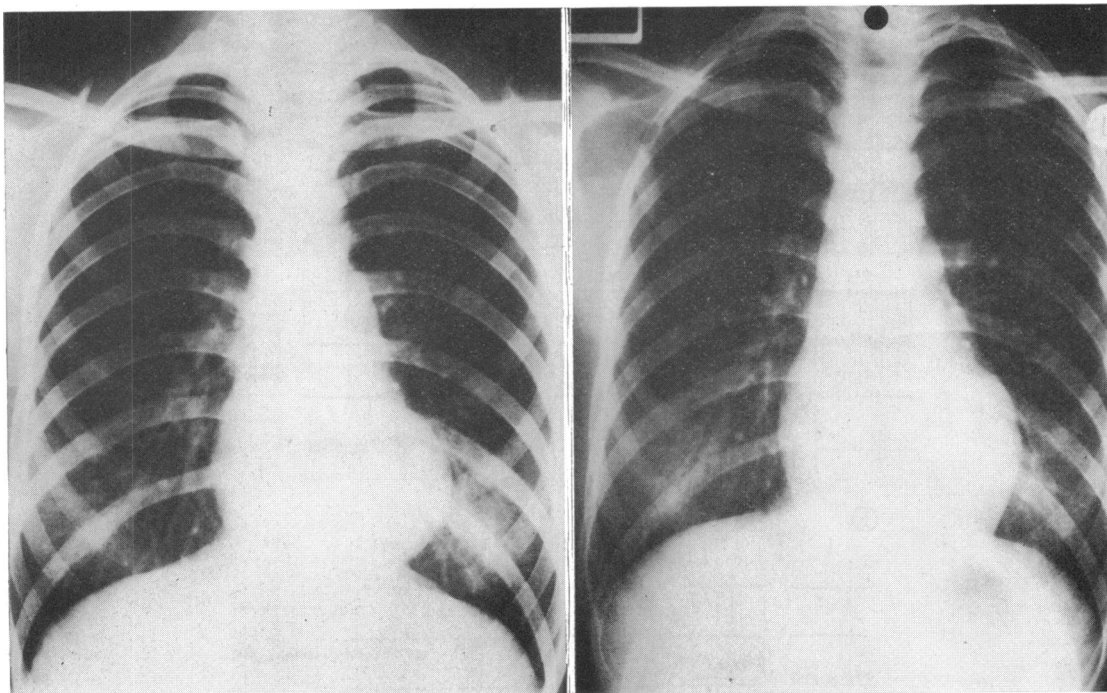


FIG. 6 Preoperative (left) and postoperative (right) chest radiographs from Case 2, showing the disappearance of the bulge at the lower left heart border after operation.

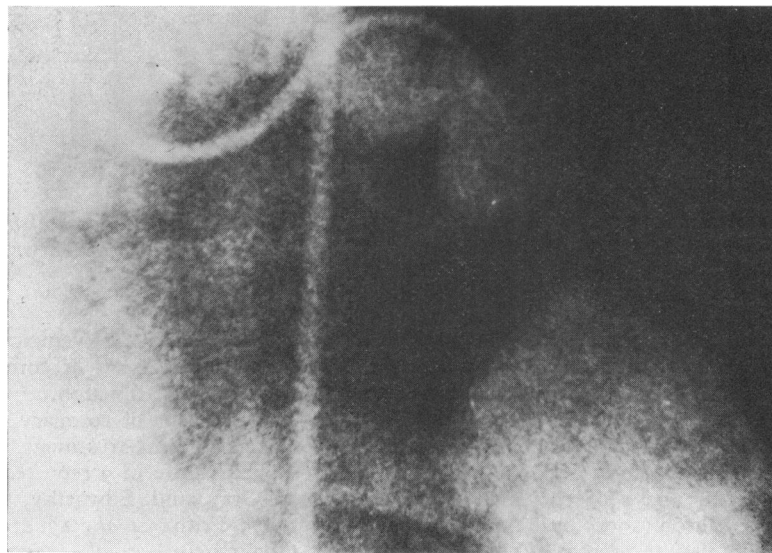


FIG. 7 Left coronary arteriogram in right anterior oblique projection (Case 2) showing the aneurysm at the origin of the left anterior descending coronary artery and a small vessel communicating with a large sac inside the myocardial mass.

supply to the myocardium unless an arteriovenous fistula was present.

More recently the continuity of the artery has been preserved or re-established with a saphenous vein graft (Ghahramani *et al.*, 1972; Dawson and Ellison, 1972; Mattern *et al.*, 1972). This was done in the first case in which interposition of the vein was performed on the left between the orifice at the bifurcation of the left coronary artery and the distal anterior descending, and on the right between the two orifices within the aneurysm. The right interposition was technically difficult due to the short graft (2.0 cm) needed, and its occlusion probably caused the death of the patient. In retrospect it would probably have been more satisfactory to have performed an aorta-to-distal coronary artery graft with ligation of the vessels entering the aneurysm.

In the second case there was no distal artery and thus obliteration of the sinusoid and aneurysm was all that could be achieved.

Coronary angiography was performed by Dr. R. Sutton in the first case and Dr. J. Dow of Guy's Hospital in the second.

### References

- Barclay, C. C., Glenney, W. R., Hobbs, R. E., and Bohnenblust, W. R. (1964). Aneurysms of the coronary artery. A case report. *American Journal of Roentgenology*, **91**, 1315.
- Belsky, H., Sharnoff, J. G., and Gilbert, S. (1955). Aneurysm of the coronary artery. *New York State Journal of Medicine*, **55**, Part 2, 3151.
- Björk, V. O., and Björk, L. (1967). Intramural coronary artery aneurysm. A coronary artery steal syndrome. *Journal of Thoracic and Cardiovascular Surgery*, **54**, 50.
- Cafferky, E. A., Crawford, D. W., Turner, A. F., Lau, F. Y. K., and Blankenhorn, D. H. (1969). Congenital aneurysm of the coronary artery with myocardial infarction. *American Journal of the Medical Sciences*, **257**, 320.
- Crocker, D. W., Sobin, S., and Thomas, W. C. (1957). Aneurysms of the coronary arteries. Report of three cases in infants and review of the literature. *American Journal of Pathology*, **33**, 819.
- Daoud, A. S., Pankin, D., Tulgan, H., and Florentin, R. A. (1963). Aneurysms of the coronary artery - report of ten cases and review of the literature. *American Journal of Cardiology*, **11**, 228.
- Dawson, J. E., and Ellison, R. G. (1972). Isolated aneurysm of the anterior descending coronary artery. Surgical treatment. *American Journal of Cardiology*, **29**, 868.
- Ebert, P. A., Peter, R. H., Gunnells, J. C., and Sabiston, D. C. (1971). Resecting and grafting of coronary artery aneurysm. *Circulation*, **43**, 593.
- Frithz, G., Cullhed, I., and Björk, L. (1968). Congenital localized coronary artery aneurysm without fistula. Report of a pre-operatively diagnosed case. *American Heart Journal*, **76**, 674.
- Ghahramani, A., Iyengar, R., Cunha, D., Jude, J., and Sommer, L. (1972). Myocardial infarction due to congenital coronary arterial aneurysm (with successful saphenous vein bypass graft). *American Journal of Cardiology*, **29**, 863.
- Hallman, G. L., Cooley, D. A., and Singer, D. B. (1966). Congenital anomalies of the coronary arteries: anatomy, pathology, and surgical treatment. *Surgery*, **59**, 133.
- Jarcho, S. (1969). Bougon on 'Coronary Aneurysm' (1812). *American Journal of Cardiology*, **24**, 551.
- Konecke, L. L., Spitzer, S., Mason, D., Kasparian, H., and James, P. M. (1971). Traumatic aneurysm of the left coronary artery. *American Journal of Cardiology*, **27**, 221.
- Mattern, A. L., Baker, W. P., McHale, J. J., and Lee, D. E. (1972). Congenital coronary aneurysms with angina pectoris and myocardial infarction treated with saphenous vein bypass graft. *American Journal of Cardiology*, **30**, 906.
- Mozen, H. E. (1956). Congenital cirroid aneurysm of a coronary artery with associated arterio-atrial fistula, treated by operation. A case report. *Annals of Surgery*, **144**, 215.
- Packard, M., and Wechsler, H. F. (1929). Aneurysm of the coronary arteries. *Archives of Internal Medicine*, **43**, 1.
- Plachta, A., and Speer, F. D. (1958). Aneurysm of the left coronary artery. Review of literature and report of three cases. *Archives of Pathology*, **66**, 210.
- Sayegh, S., Adad, W., and Macleod, C. A. (1968). Multiple aneurysms of the coronary arteries. *American Heart Journal*, **76**, 266.
- Scott, D. H. (1948). Aneurysm of the coronary arteries. *American Heart Journal*, **36**, 403.
- Sherkat, A., Kavanagh-Gray, D., and Edworthy, J. (1967). Localized aneurysms of the coronary arteries. *Radiology*, **89**, 24.

Requests for reprints to Dr. Jane Somerville, Cardiothoracic Institute, 2 Beaumont Street, London W1N 2DX.