

Long-term treatment of refractory supraventricular tachycardia by patient-controlled inductive atrial pacing

David O. Williams¹ and P. H. Davison

From the Department of Cardiology, The Queen Elizabeth Hospital, Queen Elizabeth Medical Centre, Edgbaston, Birmingham

Two patients with a long history of paroxysmal supraventricular tachycardia are presented. The episodes of arrhythmia had been refractory to a wide variety of suppressive drugs and a significant deterioration in life style had resulted. Cardiac conduction studies demonstrated a re-entry mechanism, and it was possible to induce and terminate the tachycardia by appropriately timed electrical stimuli. The application of this principle to long-term control using inductive right atrial pacing is discussed. Both patients have repeatedly abolished episodes of tachycardia using this technique.

A sustained supraventricular tachycardia may be caused by enhanced automaticity of an ectopic focus or result from re-entry within the AV node. It is now considered that at least two functionally separate pathways are present within the AV node (Moe, Preston, and Burlington, 1956), and that a single spontaneous ectopic impulse occurring early in the relative refractory period is capable of antegrade conduction down one pathway with return to the atrium along another. If this reciprocal depolarization re-enters the AV node a self-perpetuating circus movement may be established with repeated retrograde atrial activation (Goldreyer and Bigger, 1969, 1971). The arrhythmia can be reproduced and abolished by a single timed electrical pacing stimulus, and these are important diagnostic features of the re-entry mechanism (Bigger and Goldreyer, 1970). Under laboratory conditions this can be easily achieved and it is a logical extension to apply these principles for long-term control of such refractory supraventricular arrhythmias. Two patients with this condition have been investigated, and treatment with the inductively coupled cardiac pacemaker (Abrams, Hudson, and Lightwood, 1960) has been assessed in this clinical situation.

Case reports

Case 1

A 69-year-old woman presented with a 14-year history of paroxysmal supraventricular tachycardia. Digoxin, pro-

Received 12 November 1973.

¹ Present address: Division of Cardiology, Mount Sinai Medical Center, 4300 Alton Road, Miami Beach, Florida 33140, U.S.A.

cainamide, propranolol, and practolol had failed to control the arrhythmia. Over the past 5 years she had experienced 2 to 3 episodes a week, the most severe lasting for up to 20 hours. She felt faint during the attacks and was forced to rest. Her social activities had been severely affected and she had not left her house for 5 years. Admission to hospital for cardioversion had been necessary on several occasions. Past medical history included pulmonary tuberculosis, rheumatoid arthritis, and right mastectomy with radiotherapy for carcinoma. On examination there were no abnormal signs within the cardiovascular system. The electrocardiogram during sinus rhythm was normal (Fig. 1). Chest x-ray revealed healed calcified tuberculous foci and a normal heart shadow.

In view of flexion deformity at both hips and the anticipated difficulty in entering the femoral vein, His bundle electrography was not undertaken. A No. 6 bipolar electrode was advanced from an arm vein to the right atrium and extrastimulus studies performed; this comprised a sequence of 10 atrial paced beats at a rate of 80/min, followed by a single impulse of variable prematurity. The tachycardia was repeatedly provoked by the premature extrastimulus within the range 240 to 250 msec after the tenth pacing impulse of the sequence (Fig. 2). Competitive fixed rate atrial pacing at 120/min promptly abolished the tachycardia and captured the atrial rhythm. Sinus rhythm was restored when pacing was stopped (Fig. 3). In view of the severe incapacity resulting from this refractory arrhythmia and the ease with which it could be abolished by pacing, it was decided to attempt to achieve long-term control with a permanent inductive atrial pacing system. In view of previous radiotherapy to the right mammary region, epicardial leads were sutured onto the left atrium and connected to a subcutaneous coil implanted in the left lower anterolateral chest wall (Mr. L. D. Abrams).

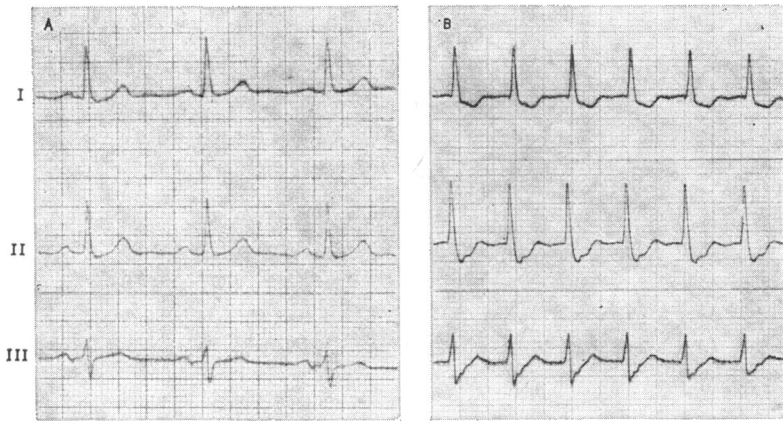


FIG 1 Case I. Leads I, II, and III recorded during (A) sinus rhythm; and (B) supraventricular tachycardia 150/min.

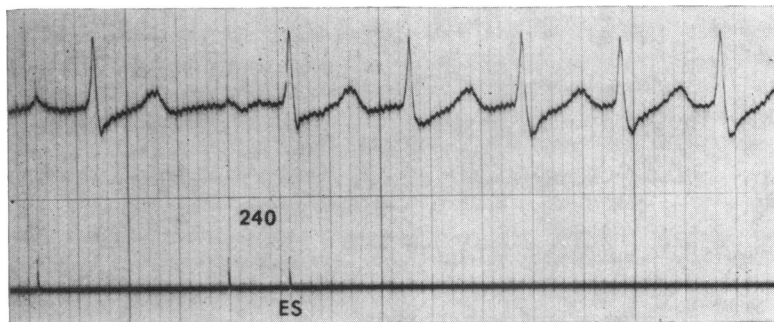


FIG 2 Tachycardia induced by a single premature extrastimulus (ES) 240 msec after the preceding pacing stimulus.

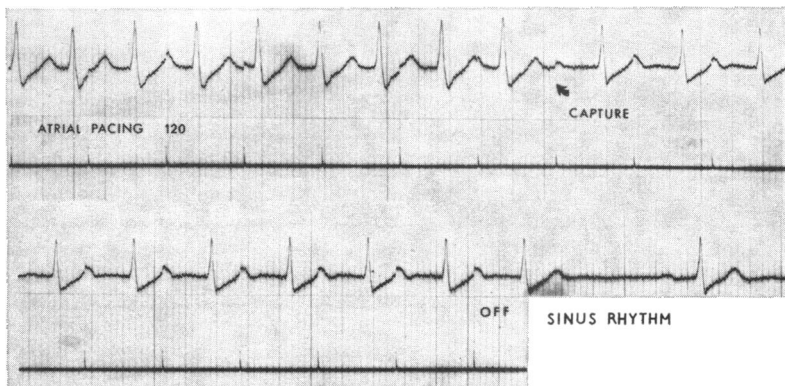


FIG 3 Competitive atrial pacing 120/min. Tachycardia is abolished and atrial capture achieved. Sinus rhythm restored when pacing stopped.

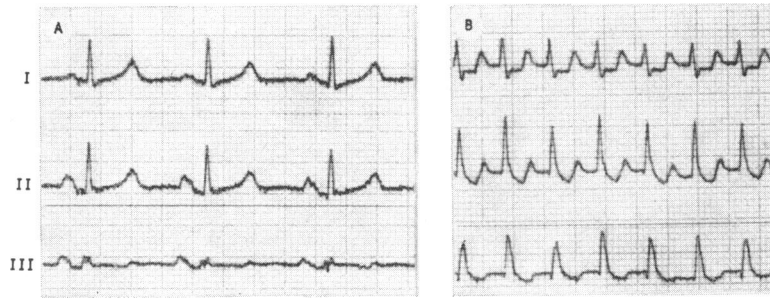


FIG 4 Case 2. Leads I, II, and III recorded during (A) sinus rhythm; and (B) supraventricular tachycardia 200/min.

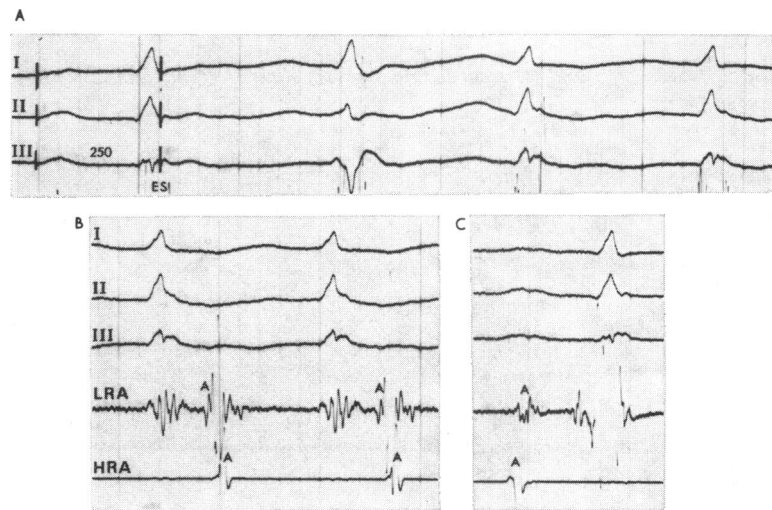


FIG. 5 (A) Tachycardia induced by a single premature extrastimulus (ES) 250 msec after the preceding pacing stimulus. (B) Simultaneous recording from low right atrium (LRA) and high right atrium (HRA) during tachycardia. Atrial depolarization (A) is recorded earlier in LRA than in HRA, confirming retrograde activation. (C) Normal activation sequence in sinus rhythm. Atrial depolarization (A) in HRA precedes that in LRA.

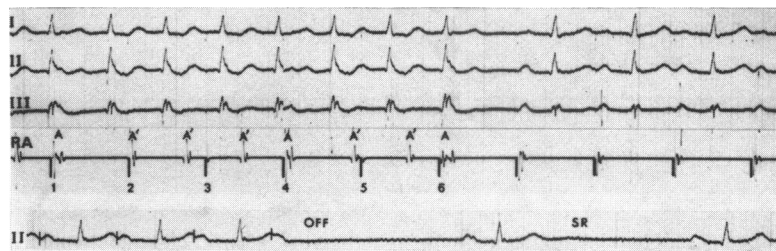


FIG. 6 Simultaneous recordings from leads I, II, III, and right atrial electrogram (RA) during competitive atrial pacing 120/min. Pacemaker stimuli have been highlighted for clarity. 'A' represents retrograde atrial depolarization during tachycardia. Pacemaker stimuli 1 and 4 achieve atrial capture (note prematurity of A) but do not affect re-entry. Stimulus 6 abolishes the tachycardia. Pacing-induced Wenckebach block is evident before pacing is stopped. Sinus rhythm restored (see text).

Case 2

A 40-year-old woman presented with a 23-year history of palpitations. The episodes would start suddenly and were not associated with any obvious precipitating factors. The duration varied from 3 to 12 hours when the arrhythmia ceased abruptly. Vagal stimulation had not been effective in abolishing the attacks. There was associated sweating, dyspnoea, polyuria, and light-headedness at the onset; she was forced to rest for the duration of the arrhythmia. Valvotomy for mitral stenosis (valve orifice 1.0 × 0.5 cm) was performed in 1966, and since this time she has been asymptomatic and unrestricted between the episodes of tachycardia. However, they have increased in frequency and duration, and over the past two years have occurred at least once weekly. Urgent admission to hospital has been necessary on 15 occasions and each time cardioversion has been required to terminate the arrhythmia. Digoxin, quinidine, procainamide, propranolol, and practolol have not satisfactorily controlled the recurrent tachycardia. Examination revealed a short mitral diastolic murmur but no other clinical abnormality. Haematological and biochemical profiles were normal. Chest x-ray was normal. In sinus rhythm, the electrocardiogram showed P mitrale but no other abnormality (Fig. 4).

At investigation the tachycardia was repeatedly provoked by a premature extrastimulus within the range 250 to 300 msec after the tenth pacing impulse of the sequence, as previously described (Fig. 5A). Simultaneous recordings from high and low right atrium confirmed retrograde activation of the atria (Fig. 5B). This contrasted with the normal activation pattern seen in sinus rhythm (Fig. 5C). Intraventricular conduction time was normal (HQ 40 msec) and remained constant during pacing acceleration of the atrium up to 160/min. Competitive atrial pacing at 80, 100, and 120/min abolished the tachycardia and captured the atrial rhythm. In the example shown (Fig. 6) stimuli 1 and 4 capture the atrium, as evidenced by the prematurity of atrial depolarization, but do not abolish the arrhythmia. Stimulus 6, which is delivered fractionally earlier, is able to penetrate the AV node and depolarize the pathway used for antegrade conduction. Thus the re-entrant stimulus is blocked and the tachycardia is terminated. A Wenckebach conduction sequence due to the atrial pacing at 120/min is then evident. This did not, however, occur at the slower pacing rates studied, which were also capable of abolishing the arrhythmia. In view of these findings a permanent inductive atrial pacing system was used for long-term control. At operation (Mr. L. D. Abrams) epicardial leads were attached to the right atrium and connected to a subcutaneous coil implanted in the right pectoral region.

Technique and results

The patient is supplied with two external pacemaker units; both generators have been preset to provide a suitable rate for competitive pacing and the patient is instructed not to alter this control. The patient periodically checks this rate before application using the audible signal and changes the bat-

teries every six weeks. Battery life will be determined by the frequency of usage and selected power setting, but it has been felt desirable for the patient to follow an instructed course when using the pacemaker in this way. One unit is always kept immediately available; thus outside the home one is carried in a handbag or basket. When the arrhythmia develops, the external coil is applied to the skin overlying the implanted internal coil and the generator turned on for 5 to 10 seconds. It is then removed and the pulse checked. Only on a few occasions has a second longer application been necessary to abolish the tachycardia. Both patients have preferred this method to keeping the coil strapped onto the skin in readiness for pacing, but the alternative may be more suitable on social occasions outside the home when simply plugging the coil lead into the generator will be the only preparation required. They have found this technique easy to follow and have become increasingly confident in applying it themselves.

Both patients experienced several episodes of supraventricular tachycardia in the immediate postoperative period; this was expected in view of the surgical manipulation of the atrium. On each occasion, competitive inductive atrial pacing abolished the arrhythmia. One of the patients (Case 1) has successfully reverted more than 100 episodes of the arrhythmia during the 5-month period which has elapsed since the pacemaker was inserted. In neither patient has the tachycardia failed to respond to treatment in this way.

Discussion

A re-entrant supraventricular tachycardia may be abolished by an appropriately timed atrial stimulus. This is effective by premature depolarization of the re-entrant pathway and thus blocking the self-perpetuating circus movement. Competitive fixed rate pacing at a slower frequency will stimulate the atrium at various parts in its cycle until one of the impulses is eventually delivered at this appropriate moment; thus it achieves the same effect as the single programmed stimulus. The time taken to obtain this specific temporal relation will be determined by the rate of the tachycardia and the frequency of stimulation. The inductively coupled cardiac pacemaker provides a very satisfactory method of achieving this. An essential feature of treatment in this way is that pacing is only required intermittently and for short periods; thus the external unit can be switched off and removed from the body when not required. No intricate sensing circuit is necessary; the only 'demand' feature this technique involves is the patient's own awareness that an episode of tachycardia has begun. The ex-

ternal control which is a feature of this type of pacemaker enables battery supply to be changed without the need for further operation and allows variation of rate and stimulus intensity when required. If an arrhythmia is due to rapidly discharging ectopic focus, competitive pacing at a slower rate might not be expected to affect it. However, a short period of pacing at a faster rate can suppress such a tachycardia. At present this has only been used at this centre as a temporary measure, but the external rate control would allow this technique to be used for intermittent overdrive suppression on a long-term basis.

Ventricular pacing may also abolish a re-entrant supraventricular tachycardia by retrograde conduction and depolarization of the circus pathway within the AV node. Kitchen and Goldreyer (1972) have reported the successful use of an implanted right ventricular endocardial demand unit which the patient was able to convert into the fixed mode with a magnet during tachycardia. Preliminary trials in the atrium, which was initially the elected site for stimulation in this patient, were unsuccessful because of frequent mechanical induction of the arrhythmia by the electrode. Ventricular competitive pacing has the potential disadvantage of precipitating a more serious arrhythmia, and, when possible, it appears that the atrium is at least theoretically the safer and more rational site for therapeutic stimulation in this way. This may be achieved with a right atrial endocardial electrode, but instability and failure to maintain long-term pacing is common; the introduction of curved J-shaped electrodes to lie within the right atrial appendage has, however, reduced this complication. The atrium may also be stimulated by an electrode positioned within the coronary sinus, but thrombosis or migration of the electrode so as to stimulate the epicardial aspect of the ventricle are possible long-term hazards. A right ventricular electrode with proximal poles for atrial pacing would perhaps be the most satisfactory means of achieving long-term atrial stimulation. Despite the disadvantages of thoracotomy, the use of epi-

cardial leads is preferred at this centre to provide the most consistent and stable method of long-term atrial pacing. The ability to provide 'high-power' pacing with the inductively coupled system overcomes the occasional problem of a higher threshold.

It is clear that intermittent pacing to terminate ectopic arrhythmias in this way does not necessarily obviate the need for continuous drug therapy; this will still be required to suppress those factors responsible for the initiation of the arrhythmia. It is, however, the duration and severity of the episodes which cause distress, and the ability to terminate them quickly and safely is of considerable benefit. Under these circumstances, the inductively coupled cardiac pacemaker appears at present to be the treatment of choice.

The authors wish to thank Mr. Michael Norton who designed and built the equipment used for cardiac conduction studies in this laboratory. This work was supported by the Endowment Fund Medical Research Committee, United Birmingham Hospitals.

References

- Abrams, L. D., Hudson, W. A., and Lightwood, R. (1960). A surgical approach to the management of heart-block using an inductive coupled artificial cardiac pacemaker. *Lancet*, **1**, 1372.
- Bigger, J. T., and Goldreyer, B. N. (1970). The mechanism of supraventricular tachycardia. *Circulation*, **42**, 673.
- Goldreyer, B. N., and Bigger, J. T. (1969). Spontaneous and induced re-entrant tachycardia. *Annals of Internal Medicine*, **70**, 87.
- Goldreyer, B. N., and Bigger, J. T. (1971). Site of re-entry in paroxysmal supraventricular tachycardia in man. *Circulation*, **43**, 15.
- Kitchen, J. G., and Goldreyer, B. N. (1972). Demand pacemaker for refractory paroxysmal supraventricular tachycardia. *New England Journal of Medicine*, **287**, 596.
- Moe, G. K., Preston, J. B., and Burlington, H. (1956). Physiologic evidence for a dual A-V transmission system. *Circulation Research*, **4**, 357.

Requests for reprints to Dr. P. H. Davison, Department of Cardiology, Queen Elizabeth Hospital, Queen Elizabeth Medical Centre, Edgbaston, Birmingham B15 2TH.