

Oesophageal intramural pseudodiverticulosis

SABARATNAM SABANATHAN, FAYEK D SALAMA, WILLIAM E MORGAN

From the Department of Thoracic Surgery, City Hospital, Nottingham

ABSTRACT Twelve cases of oesophageal intramural pseudodiverticulosis are described and the findings in 85 previously reported cases are reviewed. The condition occurs in all age groups, predominantly in the sixth and seventh decades, with a slight predilection for males. The characteristic radiographic appearance is of multiple flask shaped outpouchings of 1-4 mm with narrow necks communicating with the oesophageal lumen. The source of the pseudodiverticula has been shown to be pathologically dilated excretory ducts of the submucous glands due to chronic submucosal inflammation. The distribution was segmental in 57 cases (59%) and diffuse in 40 (41%). Dysphagia is the main symptom and was found in 85 cases (88%); 88 cases out of 97 had radiological narrowing of the oesophagus; of these, 39 (44%) were in the upper oesophagus, 20 (23%) in the middle oesophagus, and 29 (33%) in the lower oesophagus. Treatment is directed towards management of the associated disorder, as the diverticula themselves rarely cause problems.

Oesophageal intramural pseudodiverticulosis is an uncommon condition characterised by multiple diverticula contained within the wall of the oesophagus and therefore not visible externally, either at operation or at necropsy. Since the original description by Mendl *et al.*,¹ 91 cases have been described in published reports worldwide.¹⁻⁵⁵ There has been much confusion and speculation about the aetiology and pathogenesis of this disease. The purpose of this paper is to review the available information on the condition and to present 12 cases of our own.

Patients and methods

The present study is a retrospective analysis of all patients with intramural pseudodiverticulosis diagnosed and treated at Nottingham City Hospital since 1977 and a review of all the previously reported cases. In each case we have reviewed the clinical presentation, radiographic and endoscopic appearance, biopsy, intraoesophageal pH and manometric studies, treatment and subsequent progress. For the review, a case originally reported by Zatzkin and co-workers⁷ as intramural

pseudodiverticulosis that was subsequently proved to be monilial oesophagitis⁵⁶ has been excluded; also excluded are the cases reported by Bender and Haddad,¹⁶ Schatzki (addendum to Hodes *et al.*⁶), and Minnigerode *et al.*,²⁶ because of lack of sufficient clinical and/or radiological data.

Results

PRESENT SERIES (TABLE 1)

Clinical features

In our series of 12 patients there were eight women and four men, ranging in age from 35 to 84 years (mean 60.9 years). All the patients presented with dysphagia which had been present for one month to 14 years (mean 41.6 months). All 12 had strictures (that is, fibrous stenosis of the oesophagus), of which five were in the lower third, four in the middle third, and three in the upper third of the oesophagus. Associated conditions included sliding hiatal hernia in nine patients, sarcoidosis in one, and diabetes mellitus in another patient.

pH monitoring

All patients were studied by intraoesophageal pH monitoring for periods of up to 18 hours. Pathological acid reflux was considered to occur whenever the pH in the lower oesophagus decreased to less than 4 for more than 30 minutes. Of the 12 patients, seven had had eight episodes of acid reflux and the remaining five had had more than 10 such episodes.

Address for reprint requests: Mr FD Salama, FRCS, City Hospital, Nottingham, NG5 1PB.

Accepted 14 June 1985

Table 1 Details of the 12 patients

Patient No	Age (y)	Sex	Dysphagia		Radiological localisation		
			Type	Duration	Fibrous stricture	Pseudodiverticula	
						Diffuse	Segmental
1	76	F	Progressive	3 y	Lower 1/3	—	Lower 1/3
2	58	M	Constant	4 w	Upper 1/3	+	—
3	58	M	Progressive	3 m	Lower 1/3	+	—
4	60	F	Intermittent	10 m	Lower 1/3	—	Distal 1/2
5	72	M	Intermittent	6 y	Upper 1/3	—	Distal 2/3
6	84	F	Constant	6 m	Middle 1/3	—	Lower 1/3
7	37	F	Constant	4 y	Lower 1/3	—	Confined to stricture
8	64	F	Intermittent	3 y	Upper 1/3	+	—
9	66	M	Progressive	2 y	Middle 1/3	—	Confined to stricture
10	35	F	Intermittent	2 y	Middle 1/3	—	Confined to stricture
11	56	F	Intermittent	14 y	Lower 1/3	+	—
12	65	F	Intermittent	6 y	Middle 1/3	—	At and above stricture

Oesophageal manometry

Oesophageal manometry was performed in four patients by a standard station pull through technique with a triple lumen catheter. This showed synchronous normal amplitude activity in the body of the oesophagus in three and high amplitude synchronous activity in one.

Endoscopy and biopsy

At oesophagoscopy examination nine patients had oesophagitis and three had Barrett's mucosa. Ostia of the diverticula were not seen in any of the 12

cases. Ten of the 12 patients had biopsies, which showed oesophagitis in seven and Barrett's epithelium in three.

Treatment and progress

Dilatation and antireflux medication in five, antireflux surgery in six, and oesophagectomy in one were the treatments used successfully in our series of patients. All but one of the patients have been followed up for periods ranging from five months to five years. One patient died of unrelated acute renal failure four years after diagnosis. Six patients who

Table 2 Results of treatment in published cases (including the present series)

Treatment	Good result	Some benefit	Failure	Results not stated	Total
Oesophageal dilatation	29	6	3	2	40
Antifungal medication	5	0	0	1	6
Antireflux medication	12	1	1	0	14
Antireflux surgery	7	0	0	0	7
Oesophagoscopy only	7	0	0	0	7
Resection or bypass of stricture	5	0	0	0	5
Spontaneous improvement	2	0	0	0	2
Division of oesophageal band	1	0	0	0	1
Extended oesophagomyotomy	1	0	0	0	1
Other treatment (antibiotics etc)	0	0	1	0	1
No treatment given					12
Refused treatment					2
Treatment method not stated					8
Total	69	7	5	3	106
Combined treatment					
Dilatation and antireflux medication	6	1	0	0	7
Dilatation and antifungal medication	1	0	0	0	1
Antifungal and antireflux medication	1	0	0	0	1
Total	8	1	0	0	9

Endoscopic findings	Treatment	Result	Follow up
Oesophagitis lower $\frac{2}{3}$	Dilatation and antireflux medication	Well	Died 4 y later of acute renal failure
Oesophagitis entire length	Dilatation and antireflux medication	Well	No change in diverticula after 5 y
Oesophagitis entire length	Dilatation and antireflux medication	Well	Lost to follow up after 2 y
Oesophagitis lower $\frac{1}{2}$	Belsey Mk IV antireflux surgery	Well	No change in diverticula at 4 y
Barrett's oesophagus lower $\frac{2}{3}$	Dilatation and antireflux medication	Well	No follow up barium study
Barrett's oesophagus below stricture	Dilatation and antireflux medication	Well	No change in diverticula after 4 y
Barrett's oesophagus below stricture	Oesophagectomy and oesophagogastrostomy	Well	No follow up barium study
Oesophagitis entire length	Total fundoplication, gastroplasty	Well	No change in diverticula after 3 m
Oesophagitis lower $\frac{2}{3}$	Total fundoplication, gastroplasty	Well	No follow up barium study
Oesophagitis lower $\frac{1}{3}$	Nissen fundoplication	Well	No follow up barium study
Oesophagitis lower $\frac{2}{3}$	Total fundoplication, gastroplasty	Well	No change in diverticula after 1 y
Extensive oesophagitis lower $\frac{1}{3}$	Total fundoplication, gastroplasty	Well	No change in diverticula after 5 m

had a follow up barium swallow examination showed no change in either the number or the size of diverticula for up to five years.

REVIEW OF PUBLISHED CASES (TABLE 2)

Clinical features

In the total series of 97 reported cases (which include our own 12 cases) there were 56 men (58%) and 41 women (42%). The ages ranged from 8 months to 86 years (mean 53.5 years). The incidence related to sex and age at presentation is shown in figure 1. Most cases (54%) were diagnosed in the sixth and seventh decades. No racial predilection exists.

Dysphagia, predominantly for solids, was present in 88% of patients. Twelve patients were symptom free and the pseudodiverticulosis was discovered incidentally. Only three cases presented with acute dysphagia, the remaining cases having a chronic course. Dysphagia was either constant (22 cases), intermittent (25 cases), or progressive (30 cases). Episodes of acute bolus obstruction, in most instances resolving spontaneously, occurred in 15 of 97 cases. The mean duration of symptoms was 60.5 months (range two days to 26 years).

Twenty cases (21%) were associated with a hiatal hernia. Evidence of free gastro-oesophageal reflux was obtained in 29 cases, in 12 by intraoesophageal pH monitoring and in the rest during barium swallow examination. Other accompanying diseases were diabetes mellitus in 15 cases (15.5%) and

chronic alcoholism in 15 (15.5%). Lye ingestion, Plummer-Vinson syndrome, carcinoma of the oesophagus, and bronchial asthma requiring steroid treatment were each encountered twice. Pulmonary tuberculosis, Wegener's granulomatosis, pneumoconiosis, immune deficiency, Gram negative sepsis, pharyngeal diverticulum, and ovarian carcinomatosis were present in one case each. One case was complicated by a fistula into the mediastinum with resulting fatal mediastinitis.²⁷

Radiological features

The barium swallow findings in this condition are characteristic. Many flask or collar stud shaped out-pouchings measuring 1–4 mm in length are seen. They usually project at right angles to the lumen and communicate with it through narrow necked openings. Computed tomography has shown considerable thickening of the oesophageal wall, diffuse irregularity of the oesophageal lumen, and intramural gas collections.⁵² The distribution of the pseudodiverticula was segmental in 57 cases and diffuse (fig 2) in 40. Of those cases with a segmental distribution, 21 had the upper third affected, 16 the middle third, and 26 the lower third.

Radiological narrowing of the oesophagus was present in 91% of cases—44% in the upper third, 23% in the middle third, and 33% in the distal third. A cervical web was found in five cases. Pseudodiverticula were limited to the narrowed segment in 24 cases (fig 3). In the other cases with segmental

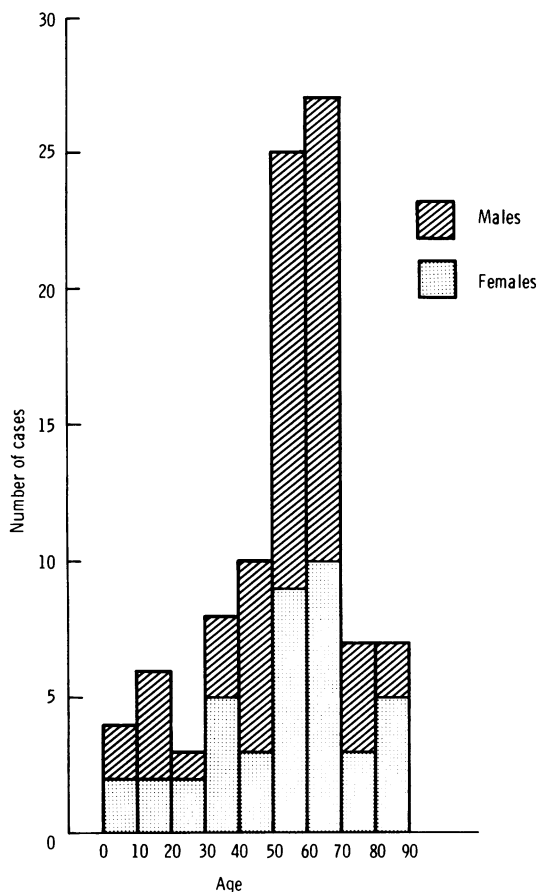


Fig 1 Incidence of oesophageal intramural pseudodiverticulosis in relation to sex and age at the time of diagnosis.

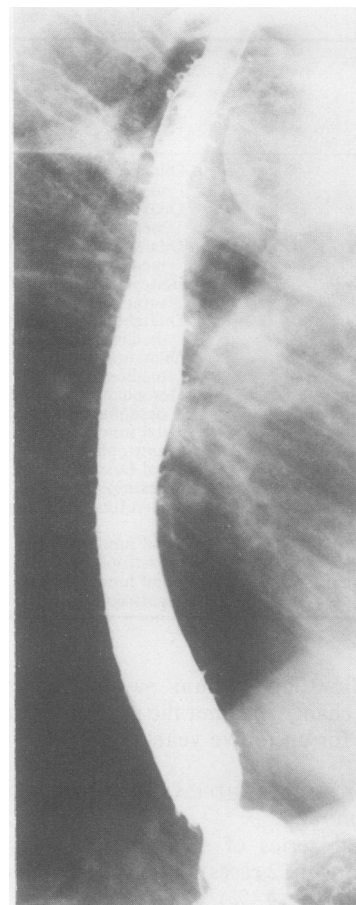


Fig 2 Barium swallow showing diffuse intramural pseudodiverticulosis: case 8.

distribution they were found above the oesophageal narrowing in seven, at the oesophageal narrowing and above in 13 (fig 4), below the oesophageal narrowing in five (fig 5), and at the oesophageal narrowing and below in eight instances. Evidence of disordered motility, manifested by irregular tonic simultaneous contractions (six cases), tertiary contractions (five cases), aperistalsis (five cases), impaired peristalsis (three cases), lack of distensibility (two cases), exaggerated normal peristalsis (one case), and a non-specific motility defect (seven cases), was present in 29 of the total of 97 cases. Motility was described as normal in two patients.

Manometry

Despite the fact that oesophageal dysmotility was suggested in the first description of the condition,¹

only 19 patients have had manometric studies, 15 being shown to have either generalised or local abnormalities. Localised aperistalsis confined to the area of oesophageal narrowing was seen in two cases, complete aperistalsis in three, decreased amplitude normal peristalsis in two, primary diffuse oesophageal spasm in one, and high amplitude peristaltic contractions in one. Synchronous tertiary contractions with normal amplitude were seen in five cases (fig 6) and with high amplitude in one case.

Endoscopy

Endoscopy was performed in 84 cases. This showed the orifices of the pseudodiverticula in 21 cases (25%), changes of oesophagitis in 57 (68%), Barrett's mucosa in five (6%), and endoscopic oesophageal narrowing in 57 (68%). In 22 patients

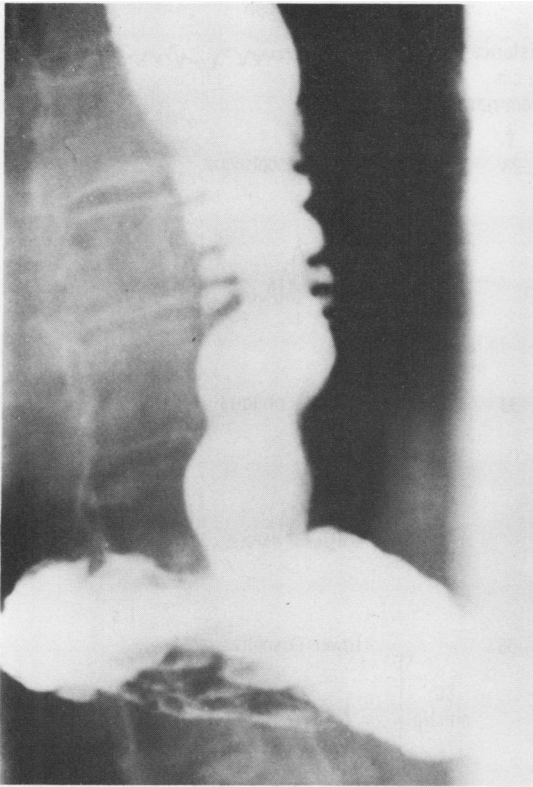

Fig 3 Intramural pseudodiverticulosis within an area of stricture: case 10.

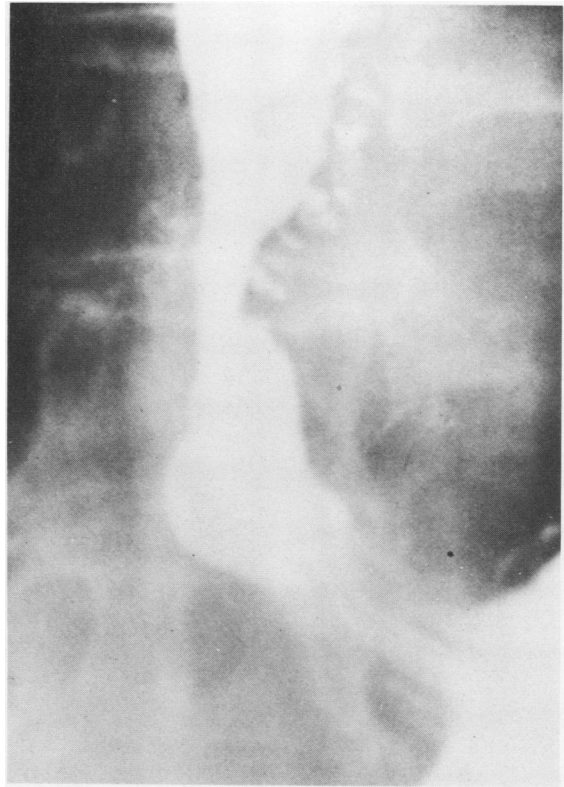


Fig 4 Barium swallow showing pseudodiverticulosis at and above stricture: case 12.

(27%) the oesophageal mucosa was described as normal. The ostia of the outpouchings were described as pinhead sized, yellow white mucosal elevations with a thick, creamy liquid expressible from a central opening,² as multiple punctate openings with²¹ or without^{24,30} expressible fluid, or as multiple red orifices protruding from the oesophageal lumen.³⁹ When visualised the mouths of the diverticula were found to be distributed in a linear fashion along the wall between the normal oesophageal folds, a location corresponding to that of normal oesophageal glands.²¹ Endoscopic oesophagitis was manifested by hyperaemia, mucosal oedema, friability, erosions, or ulceration.

Pathology and microbiology

Oesophageal biopsy specimens (58 cases) or full thickness necropsy sections (seven cases) were available for examination for 65 patients. Evidence of acute or chronic inflammatory infiltrate was seen in 55 (85%) of the 65 patients. Other abnormalities

in antemortem specimens were submucosal fibrosis and Barrett's epithelium. Biopsy specimens are of limited value in detecting lesions because the pseudodiverticular formations are intramural and usually not included in the submitted specimen. *Candida albicans* was cultured from the oesophagus in 15 of 37 cases and biopsy specimens showed evidence of tissue invasion in five cases. Both culture and biopsy specimens were positive for *Candida albicans* in only two cases.

Treatment and prognosis (table 2)

Dilatation of oesophageal narrowings was performed in 40 cases and relieved symptoms completely or substantially in 35 (87.5%). No direct treatment was required in at least 12 patients. Other treatments that have been used are antimycotic drugs (six cases, successful in five), hiatal hernia repair (seven cases, successful in all), antireflux medication (14 cases, successful in 12), and antibiotics (one case, unsuccessful). Two patients improved

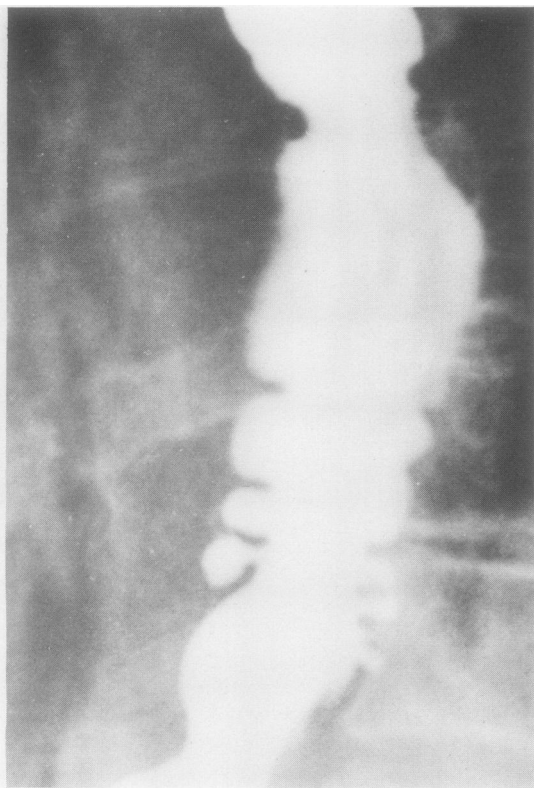

Fig 5 Intramural pseudodiverticulosis distal to stricture: case 6.

spontaneously.^{23 38} Among the 36 patients followed up, disappearance (seven cases) or a decrease in the number of pseudodiverticula (six cases) has occurred in 36%. In 23 patients the pseudodiverticula remained unchanged in appearance for up to 16 years after treatment⁴⁵ (range three months to 16 years, mean follow up 1.9 years).

The course of the disease is benign and only one fatal complication, with a fistula into the anterior mediastinum, has been reported.²⁷

Discussion

Oesophageal intramural pseudodiverticulosis is a rare benign disorder occurring at all ages and more frequent in males. The condition usually presents with dysphagia, which typically is not severe and is usually intermittent or slowly progressive. There is a high incidence of oesophageal narrowing, usually in the upper third of the oesophagus, associated with the 1–4 mm flask shaped diverticula seen on barium

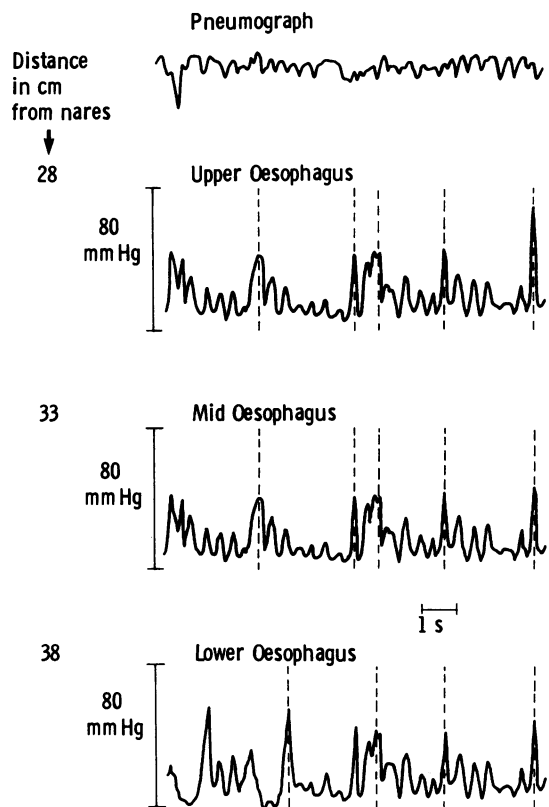


Fig 6 Oesophageal manometric tracing showing normal amplitude synchronous activity: case 9.

swallow examination. Endoscopy is not helpful in the diagnosis but shows inflammatory changes; in only a few cases are the ostia of the pseudodiverticula visible. Biopsy is not usually diagnostic as the pseudodiverticula are too deep to be included in the specimen. Radiology therefore offers the most sensitive method of diagnosis. Although the radiological appearances at a barium swallow examination are virtually pathognomonic they have been confused with monilial oesophagitis. With monilial infection, however, the typical smooth, flask shaped diverticula are not seen.

The aetiology of the pseudodiverticulosis remains speculative. In their original report Mendl *et al*¹ proposed that the basic defect in intramural pseudodiverticulosis was a herniation of the mucosa along the pathways of blood vessels and nerves into the intramural portion of the oesophagus, due to an increase in intraluminal pressure in the oesophagus. Necropsy studies, however, have shown pseudodiverticula to be dilated pre-existing excret-

ory ducts of the submucous glands.^{4 5 27 29}

Lupovitch and Tippins³ postulated a congenital or acquired adenosis predisposing to chronic inflammation, resulting in cystic dilatation and squamous metaplasia. Wightman and Wright,⁴ on the basis of histological examination of a postmortem case, rejected the theory of adenosis and proposed that the oesophageal gland ducts undergo squamous metaplasia in response to chronic irritation. Umlas and Sakkuja⁵ and Hammon *et al*¹⁹ studied several normal oesophagi by serial sections and observed that ducts of the oesophageal glands are normally lined by stratified squamous epithelium and therefore it is not necessary to postulate a metaplastic change. There appear to be the same number of pseudodiverticula in the pathological state as of gland duct units in the normal state; the main difference is the dilatation and surrounding inflammation. Pseudodiverticula are the result of pathological dilatation of these ducts.^{4 5 27 29} Not surprisingly, since most of the gland duct units occur in the upper half of the normal oesophagus,¹⁹ pseudodiverticula are most numerous there. The aetiology of the pathological dilatation of the submucosal gland ducts to form pseudodiverticula remains controversial. Because most patients are in their sixth and seventh decades, and also because stricture formation precedes pseudodiverticulosis in some cases,^{11 39 44} we believe, like most authors, that this is an acquired lesion,^{2 5 9 11 13-15 17 19 20 27-30 32 35 36 39 43-45 52 54} despite the occurrence of a few cases in childhood.

Most of the evidence suggests that the initiating event is chronic inflammation—whether the cause is fungal (candidiasis), bacterial, or chemical as in gastro-oesophageal reflux—of the submucosal oesophageal glands.^{2 5 9 11 14 17-19 27 29-32 35 36 39 43 45 46 52 54} Obstruction of the ductal orifices by periductal inflammation or fibrosis, or both, produces dilatation of the ducts and the typical outpouchings seen on barium swallow examination. The thickening of the oesophagus seen in postmortem specimens and computed tomography scans has been shown to be due to submucosal fibrosis.^{3 5 19 27 29} Failure to demonstrate oesophagitis endoscopically in 22 cases does not exclude the possibility of oesophagitis in the absence of histological examination, because inflammatory changes in the oesophagus begin microscopically in the area of the lamina propria and only later affect the epithelial layer.⁵⁷⁻⁵⁹ Histological examination of the oesophageal mucosa will often show inflammatory changes in the submucosa even when the mucosa appears normal on endoscopic examination.⁵⁸ Failure to detect inflammation in four cases could be explained if the biopsy specimens came from an area where inflammation had disappeared.

The association of *Candida albicans* with oesophageal intramural pseudodiverticulosis deserves further consideration. When specifically sought for *Candida* has been present in almost half the cases (18 of 37 patients). As it is a common inhabitant of the oropharynx⁶⁰ it has been given an incidental rather than an aetiological role. Orringer and Sloan³¹ and others,^{6 28 52} however, believe that chronic infection of the oesophageal submucosal glands by *Candida albicans* must be recognised as one cause of pseudodiverticulosis.

Oesophageal narrowing was found in most of the reported cases (91%), with a predilection toward the cervical and upper thoracic oesophagus (44%). It has been suggested that strictures in this disorder may result from localised peridiverticulitis.²¹ The absence of oesophageal narrowing in some cases, however, and the presence of pseudodiverticula distal to the oesophageal narrowing in many cases suggest that oesophageal narrowing is also a secondary consequence of the diffuse oesophagitis, as is the commonly found abnormal motor activity. Chronic oesophagitis is a relatively common condition while pseudodiverticulosis is rare. Conceivably failure to detect pseudodiverticula could result from blockage of the ducts by mucoid and inflammatory material, preventing their filling with barium.^{39 44 54} The work of Hammon *et al*,¹⁹ who studied oesophagi obtained at routine postmortem examination, supports this view.

All the 12 patients in our series proved to have gastro-oesophageal reflux; similar findings have been published previously.^{11 17 22 25 28 32 39 43 44 46} This suggests that intramural pseudodiverticulosis of the oesophagus may represent yet another complication of reflux oesophagitis. Intramural pseudodiverticulosis of the oesophagus seems to have no clinical importance as such, but is an indication that "something is amiss" in the oesophagus. Treatment is directed at relieving oesophageal obstruction, if any, and dealing with the underlying inflammatory condition. The results of long follow up in many cases^{2 6 18 23 25 44 45} indicate that the condition may remain relatively stable for long periods.

References

- 1 Mendl K, McKay JM, Tanner CH. Intramural diverticulosis of the oesophagus and Rokitsansky-Aschoff sinuses in the gall-bladder. *Br J Radiol* 1960;33:496-501.
- 2 Boyd RM, Bogoch A, Greig JH, Trites EW. Oesophageal intramural pseudodiverticulosis. *Radiology* 1974;113:267-70.
- 3 Lupovitch A, Tippins R. Oesophageal intramural pseudodiverticulosis: a disease of adnexal glands. *Radiology* 1974;113:271-2.

- 4 Wightman AJA, Wright EA. Intramural oesophageal diverticulosis: a correlation of radiological and pathological findings. *Br J Radiol* 1974;**47**:496-8.
- 5 Umlas J, Sakhuja R. The pathology of oesophageal intramural pseudodiverticulosis. *Am J Clin Pathol* 1976;**65**:314-20.
- 6 Hodes PJ, Atkins JP, Hodes BL. Esophageal intramural diverticulosis. *Am J Roentgenol* 1966;**96**:410-3.
- 7 Zatzkin HR, Green S, Lavine JJ. Esophageal intramural diverticulosis. *Radiology* 1968;**90**:1193-4.
- 8 Culver GJ, Chaudhari KR. Intramural esophageal diverticulosis. *Am J Roentgenol* 1967;**99**:210-11.
- 9 Troupin RH. Intramural esophageal diverticulosis and moniliasis. *Am J Roentgenol* 1968;**104**:613-6.
- 10 Creely JJ, Trail ML. Intramural diverticulosis of the esophagus. *South Med J* 1970;**63**:1257-60.
- 11 Weller MH, Lutzker SA. Intramural diverticulosis of the esophagus associated with postoperative hiatal hernia, alkaline esophagitis and esophageal stricture. *Radiology* 1971;**97**:373-7.
- 12 Cramer KR. Intramural diverticulosis of the oesophagus. *Br J Radiol* 1972;**45**:857-9.
- 13 Weller MH. Intramural diverticulosis of the esophagus: report of a case in a child. *J Pediatrics* 1972;**80**:281-5.
- 14 Lane JW. Intramural esophageal diverticulosis: a case report. *Journal of the Arkansas Medical Society* 1972;**69**:87-90.
- 15 Sperling HV, D'Altorra RA. Intramural diverticulosis of the esophagus. *Digest Dis* 1973;**18**:978-82.
- 16 Bender MD, Haddad JK. Disappearance of multiple esophageal diverticula following treatment of esophagitis: serial endoscopic, manometric, and radiologic observations. *Gastrointestinal Endoscopy* 1973;**20**:19-22.
- 17 Mendl K, Montgomery RD, Stephenson SF. Segmental intramural diverticulosis associated with and confined to a spastic area of muscular hypertrophy in a columnar lined oesophagus. *Clin Radiol* 1973;**24**:440-4.
- 18 Beauchamp JM, Nice CM, Belanger MA, Neitzschman HR. Esophageal Intramural pseudodiverticulosis. *Radiology* 1974;**113**:273-76.
- 19 Hammon JW jun, Rice RP, Postlethwait RW, Young WG jun. Esophageal Intramural Diverticulosis: a clinical pathological survey. *Ann Thorac Surg* 1974;**17**:260-7.
- 20 Hupscher DN. Intramural diverticulosis of the oesophagus. *Radiol Clin Biol* 1974;**43**:144-54.
- 21 Graham DY, Goyal RK, Sparkman J, Cagan ME, Pogonowska MJ. Diffuse intramural esophageal diverticulosis. *Gastroenterology* 1975;**68**:781-5.
- 22 Schwegler N, Faust H. Radiologische aspekten der intramuralen oesophagus-divertikulose. *Fortschr Roentgenstr* 1975;**122**:151-5.
- 23 Montgomery RD, Mendl K, Stephenson SF. Intramural diverticulosis of the oesophagus. *Thorax* 1975;**30**:278-84.
- 24 Fee BE, Dvorak AD. Intramural pseudodiverticulosis of the esophagus. *Nebraska Med Jnl* 1976;Jan:9-13.
- 25 Redlich FH. Zur intramuralen Oesophagusdivertikulose. *Radiol Diagn (Berlin)* 1976;**17**:217-24.
- 26 Minnigerode B, Bartholome W, Kupper R. The endoscopic picture of the intramural oesophageal diverticulosis. *Endoscopy* 1977;**9**:203-7.
- 27 Rahlf G, Wilbert L, Lankisch PG, Ruttemann-U. Intramural esophageal diverticulosis. *Acta Hepatogastroenterol* 1977;**24**:110-5.
- 28 Shapiro MJ, Sloan WC. Intramural pseudodiverticulosis of the esophagus. *Ann Otol* 1977;**86**:594-7.
- 29 Fromkes J, Thomas FB, Mekhjian H, Caldwell JH, Johnson JC. Esophageal intramural pseudodiverticulosis. *Digest Dis* 1977;**22**:690-700.
- 30 Castillo S, Aburashed A, Kimmelman J, Alexander LC. Diffuse intramural esophageal pseudodiverticulosis: new cases and review. *Gastroenterology* 1977;**72**:541-5.
- 31 Orringer MB, Sloan H. Monilial esophagitis: an increasingly frequent cause of esophageal stenosis? *Ann Thorac Surg* 1978;**26**:364-74.
- 32 Braun P, Nussle D, Roy CC, Cuendet A. Intramural diverticulosis of the esophagus in an eight-year-old boy. *Pediatr Radiol* 1978;**6**:235-7.
- 33 Van Overbeek JJM, Edens ET, Gokemeijer JDM, Broker FHL. Intramural diverticulosis of the esophagus. *Laryngoscope* 1978;**88**:1671-9.
- 34 Libert M, De Toef J, Andre P. Pseudo-diverticulose intramurale de L'oesophage. *Acta Gastroenterol Belg* 1978;**41**:162-8.
- 35 Hermanutz VKD, Lindstaedt H, Miederer SE. Intramurale Pseudodivertikulose des Oesophagus. *Fortschr Rontgenstr* 1978;**128**:115-8.
- 36 Lammer J, Biffi H. Die oesophageale intramurale Pseudodivertikulose. *Radiologe* 1979;**19**:445-50.
- 37 Farack VUM, Kinnear DG, Jabbari M. Die intramurale Pseudodivertikulose des Ösophagus—eine primär radiologische. *Diagnose Fortschr Rontgenstr* 1979;**130**:508-9.
- 38 Starinsky R, Manor A, Pajewsky M, Varsano D. Intramural esophageal diverticulosis in an infant. *Israel J Med Sci* 1980;**16**:604-6.
- 39 Muhletaler CA, Lams PM, Johnson AC. Occurrence of oesophageal intramural pseudodiverticulosis in patients with pre-existing benign oesophageal stricture. *Br J Radiology* 1980;**53**:299-303.
- 40 Lübke HJ, Bloch R. Die intramurale Divertikulose des Ösophagus. *Leber Magen Darm* 1981;**11**:139-43.
- 41 Delgoffe C, Regent D, Stines J, Humbert B, Treheux A. La Pseudo-diverticulose intramurale de l'oesophage: aspects radiologiques à propos de 2 cas. *J Radiol* 1981;**12**:635-8.
- 42 Broeckaert I, Lecocq E. Pseudo-diverticulose intramurale de L'oesophage. *Gastroenterol Clin Biol* 1981;**5**:522-6.
- 43 Cho SR, Sanders MM, Turner MA, Liu CI, Kipreos BE. Esophageal intramural pseudodiverticulosis. *Gastrointestinal Radiology* 1981;**6**:9-16.
- 44 Brühlmann WF, Zollikofer CL, Maranta E, et al. Intramural pseudodiverticulosis of the esophagus: report of seven cases and literature review. *Gastrointest Radiol* 1981;**6**:199-208.
- 45 Peters ME, Crummy AB, Wojtowycz MM, Toussaint JB. Intramural esophageal pseudodiverticulosis: a report in a child with a sixteen-year follow up. *Pediatr Radiol* 1982;**12**:262-3.
- 46 Greenstein R, Shah HV. Esophageal intramural pseudodiverticulosis. *Ill Med J* 1982;**162**:32-3.
- 47 Cantor DS, Riley TL. Intramural pseudodiverticulosis of the esophagus. *Am J Gastroenterol* 1982;**77**:454-6.
- 48 Walter K. Ungewöhnliche Divertikel-intramurale Oesophagusdivertikulose, intraduodenale Divertikel: zwei Fallberichte. *Radiologe* 1983;**23**:551-2.

- 49 Bavastro VP, Gerlach A. Die intramurale Divertikulose des Ösophagus. *Z Gastroenterol* 1983;**21**:159–63.
- 50 Schmutz G, Zeller C, Doffoel M, Kempf F. Une cause rare de blocage alimentaire: la pseudo-diverticulose intra-murale de l'oesophage. *Presse Méd* 1983;**12**:641–2.
- 51 Murney RG, Linne JH, Curtis J. High-amplitude peristaltic contractions in a patient with esophageal intramural pseudodiverticulosis. *Digest Dis Sci* 1983;**28**:843–7.
- 52 Pearlberg JL, Sandler MA, Madrazo BL. Computed tomographic features of esophageal intramural pseudodiverticulosis. *Radiology* 1983;**147**:189–90.
- 53 Gerlach VA, Bavastro P, Reichardt W. Beitrag zur Röntgenmorphologie der intramuralen Pseudodivertikulose des Ösophagus. *Fortschr Röntgenstr* 1984;**140**:281–3.
- 54 Santos GH, Baker SR, Frater RWM. Intramural pseudodiverticulosis of the esophagus. *J Thorac Cardiovasc Surg* 1984;**87**:120–3.
- 55 Cronen PW. Diffuse esophageal intramural pseudodiverticulosis. *South Med J* 1984;**77**:771–2.
- 56 Smulewicz IJ, Dorfman J. Esophageal intramural diverticulosis: a re-evaluation. *Radiology* 1971;**101**:527–9.
- 57 Henderson RD, Pearson FG. Preoperative assessment of oesophageal pathology. *J Thorac Cardiovasc Surg* 1976;**72**:512–7.
- 58 Svoboda AC, Knauer M, Gamble CN, Sommers SC, Monroe LS. Problems in the early diagnosis of peptic oesophagitis. *Gastrointestinal Endoscopy* 1967;**13**:14–7.
- 59 Ballem CM, Fletcher HW, McKenna RD. The diagnosis of oesophagitis. *Am J Digest Dis* 1960;**5**:88–93.
- 60 Cohen R, Roth FJ, Delgado E, Ahearn DG, Kalsner MH. Fungal flora of the normal human small and large intestine. *N Engl J Med* 1969;**280**:638–41.