

Pulmonary veno-occlusive disease after chemotherapy

BK KNIGHT, AG ROSE

From the Department of Pathology, Groote Schuur Hospital and University of Cape Town, Cape Town, South Africa

Pulmonary veno-occlusive disease is a rare cause of pulmonary hypertension and its aetiology is unknown. Multifactorial aetiology is likely.¹ It has recently been shown that pulmonary veno-occlusive disease may be caused by bleomycin treatment administered for malignant tumours, but reports of only three such patients have been published.^{2,3} We here report a fourth case.

Case report

The patient, a 36 year old woman, presented in October 1982 complaining of postcoital bleeding. Colposcopy showed a cervical carcinoma, which also affected the upper third of the vagina. Biopsy showed an invasive, poorly differentiated squamous carcinoma. Clinical examination and computed tomography indicated that the tumour had spread to both pelvic walls. Radiotherapy (5800 rads (cGy) in 27 fractions) was administered to the pelvis over six weeks, followed by locally inserted radium needles. The treatment was well tolerated and the tumour became smaller. Vaginal vault necrosis occurred, which healed in time. Three months later she complained of anorexia, diarrhoea, and lumbar pain. An intravenous pyelogram showed a left sided hydronephrosis. Computed tomography confirmed these findings and showed tumour within para-aortic lymph nodes.

Fourteen months after receiving radiotherapy the patient developed a pericardial effusion and cytological examination of the fluid showed malignant cells. Mediastinal irradiation (2400 rads in six fractions) controlled the pericardial effusion for three months, after which it accumulated again. She then developed bilateral pleural effusions and lymphoedema of the right leg. Pericardiocentesis was not performed. Seventeen months after her initial treatment the following combination chemotherapy was instituted: mitomycin C (12 mg statim), followed by cisplatin (60 mg/m² statim), bleomycin (15 mg weekly), and vinblastine (4 mg every three weeks). The total dose of bleomycin was 210 mg.

Over the next three months the patient became progressively more dyspnoeic and was admitted to hospital with signs of right sided cardiac failure two days before her death on 14 October 1984. At necropsy the patient weighed only 55.5 kg and had peripheral oedema. Radiotherapy had caused fibrous obliteration of the cervix,

the lower two thirds of the uterus, and both parametria. Some thick walled pelvic blood vessels had undergone thrombosis. The ovaries were fibrosed, but the fallopian tubes looked normal. No viable tumour was detected within this pelvic fibrous tissue. Partially viable metastatic tumour was found within the para-aortic, iliac, and mediastinal lymph nodes. Inguinal nodes were free of tumour but there were widespread metastases in both abdominal and thoracic lymphatic channels. Metastatic tumour deposits were also present in the left upper lobe of the lung, on the peritoneal surface, and in the lumbar vertebrae. Left sided hydronephrosis was confirmed.

The liver showed passive venous congestion and the spleen and other organs also appeared congested. The pericardial cavity contained 550 ml of blood stained fluid; similar fluid was present in pleural and peritoneal cavities. The heart was atrophied in appearance and tumour deposits were seen on the epicardium. The right ventricle was slightly dilated and showed minimal hypertrophy.

Histological examination of the lungs showed focal intra-alveolar oedema with intra-alveolar haemosiderin laden macrophages. Focal scanty interstitial pneumonitis with intra-alveolar exudation, such as may be seen as an effect of bleomycin treatment,^{4,5} was present too. Some of the small pulmonary arteries showed intimal fibrous thickening. A notable additional feature was the presence of pulmonary veno-occlusive disease affecting many of the small intrapulmonary venules. The venous nature of these affected vessels (figs 1 and 2) was confirmed by observing that they either lay within or drained into the fibrous septa of the lungs. Many veins and venules showed severe luminal narrowing or even complete occlusion by intimal fibrous tissue. A few venules showed multiple intraluminal channels suggesting recanalisation. Elastic stains were needed to demonstrate these structural alterations properly.

Discussion

The present case report provides further evidence for the idea that chemotherapy for malignant disease may produce pulmonary veno-occlusive disease. Both of our previously reported patients⁵ had received their chemotherapy for lymphoma; one patient was treated with bleomycin and vincristine, while the other received bleomycin, vincristine, and prednisone. The patient reported from the United States² had received chemotherapy (bleomycin, mitomycin C, and cisplatin) for metastatic cervical carcinoma. Both bleomycin and mitomycin C are known to cause lung damage. Bleomycin toxicity produces diffuse alveolar damage leading to interstitial pneumonitis and fibrosis. The

Address for reprint requests: Professor AG Rose, Department of Pathology, Medical School, University of Cape Town, Observatory, South Africa 7925.

Accepted 29 March 1985

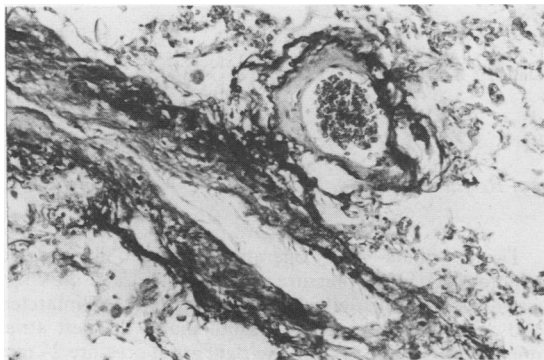


Fig 1 Pulmonary vein in an interlobular septum and a tributary venule draining into it, showing fibrous intimal thickening. (Elastic van Gieson, $\times 150$.)

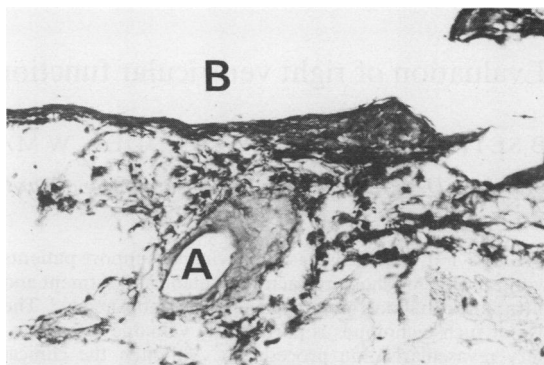


Fig 2 Obliquely sectioned pulmonary venule (A) draining into septal vein (B) and showing intimal fibrous thickening. (Elastic van Gieson, $\times 150$.)

pathological changes are thought to result from a direct action of the drug on the small pulmonary vessels.^{2,6} Mitomycin C may also produce considerable pulmonary damage. A recent report⁷ of hepatic veno-occlusive disease due to mitomycin C provides further support for the idea that alkylating agents may damage parenchymal veins, and indicates that the latter should be carefully examined in all patients receiving such treatment.⁸

Thoracic radiotherapy increases the incidence of severe bleomycin pulmonary toxicity and the pulmonary reaction affects the entire lung and not just the radiation portal.⁵ Patients treated for non-Hodgkin's lymphoma with combinations containing cyclophosphamide are more vulnerable to bleomycin pulmonary toxicity.⁵ It has been claimed that non-Hodgkin's lymphoma per se may lead to an increased propensity to develop severe reactions to bleomycin.⁹ Pulmonary veno-occlusive disease has recently been described in a patient with Hodgkin's disease.¹⁰ This patient had been treated with mustine, vincristine, procarbazine, and prednisolone and the possibility of the pulmonary veno-occlusive disease being related to the chemotherapy was not considered. While the thought that pulmonary veno-occlusive disease may be associated with malignancy per se is intriguing, the available evidence points to chemotherapy as the cause of the condition in such patients.

Pulmonary veno-occlusive disease associated with chemotherapy for cancer is probably more common than the published reports indicate, and the diagnosis may be missed unless the possibility of the condition is borne in

mind and elastic staining is performed to delineate the pulmonary vessels.

We acknowledge the help of the South African Medical Research Council in providing grant support.

References

- 1 Wagenvoort CA, Wagenvoort N. *Pathology of pulmonary hypertension*. New York: John Wiley and Sons, 1977:217-31.
- 2 Joselson R, Warnock M. Pulmonary veno-occlusive disease after chemotherapy. *Hum Pathol* 1983;14:88-91.
- 3 Rose AG. Pulmonary veno-occlusive disease due to bleomycin therapy for lymphoma. *S Afr Med J* 1983;64:636-8.
- 4 Ichikawa T. Studies of bleomycin. *GANN Monograph Cancer Res* 1976;19:99-113.
- 5 Ginsberg SJ, Comis RL. The pulmonary toxicity of anti-neoplastic agents. *Sem Oncol* 1982;9:34-51.
- 6 Jones AW. Bleomycin lung damage: the pathology and nature of the lesion. *Br J Dis Chest* 1978;72:321.
- 7 Gothfried MR, Sudilovsky O. Hepatic veno-occlusive disease after high-dose mitomycin-C and autologous bone marrow transplantation therapy. *Hum Pathol* 1982;13:646-50.
- 8 Rose AG. Pulmonary veno-occlusive disease after chemotherapy with bleomycin [letter]. *Hum Pathol* 1984;15:199.
- 9 Blum RH, Carter SK, Agre K. A clinical review of bleomycin: a new antineoplastic agent. *Cancer* 1973;31:903-14.
- 10 Capewell SJ, Wright AJ, Ellis DA. Pulmonary veno-occlusive disease in association with Hodgkin's disease. *Thorax* 1984;39:554-5.