

Synchronous pulmonary carcinoid tumour and non-Hodgkin's lymphoma: report of two cases

F M JUETTNER, C FELLBAUM, H POPPER, M LEHNERT, M NEUBAUER, W WAGNER, H BECKER

From the Departments of Thoracic and Hyperbaric Surgery, Pathology, and Internal Medicine, Graz University Medical School, Graz, Austria

ABSTRACT Two cases of synchronous pulmonary carcinoid tumour and non-Hodgkin's lymphoma are described.

The synchronous occurrence of two different tumours may cause diagnostic problems with serious therapeutic consequences, especially where the tumours are of a rare type and where an association is not expected. We report two cases of synchronous atypical pulmonary carcinoid tumour and non-Hodgkin's lymphoma.

Case reports

CASE 1

A 58 year old woman, a smoker, presented with cough and weight loss, bilateral supraclavicular lymph node enlargement, and crepitations and wheezing over the right chest. Radiography and conventional tomography showed a left perihilar mass and enlarged subcarinal and contralateral hilar lymph nodes. Bronchoscopy showed a tumour in the left lower lobe bronchus, which bled on contact. The histological appearances of the biopsy specimen suggested an oat cell carcinoma, whereas the cytological appearances of the fine needle aspirate from a supraclavicular node were interpreted as those of a necrotic, probably squamous cell tumour. A diagnosis of inoperable mixed oat and squamous cell bronchogenic carcinoma was made. The patient refused further treatment, and was discharged.

Two months later she was admitted with abdominal pain and bilateral inguinal lymphadenopathy. Ultrasound showed a parapancreatic mass 7 cm in diameter, consistent with enlarged lymph nodes. Histologically, an inguinal node (fig 1a) was infiltrated by a centroblastic lymphoma, polymorphic subtype,¹² with monotypic immunoglobulin expression (IgM lambda). The hilar mass had increased in size, and repeat bronchoscopy confirmed that a tumour was infiltrating the left main bronchus. A further biopsy specimen consisted of an epithelial tumour, composed of sheets and nests of cells with enlarged, atypical nuclei. Immunohistochemical reactions for cytokeratin 18 fragment (TPA) and neurone specific enolase were positive. An atypical bronchial carcinoid was diagnosed (fig 2a).

Address for reprint requests: Dr F M Juettner, Department of Thoracic and Hyperbaric Surgery, University Medical School, A-8036 Graz, Auenbruggerplatz, Austria.

Accepted 10 March 1989

The patient was treated with methotrexate, doxorubicin (Adriamycin), cyclophosphamide, vincristine, prednisolone, and bleomycin (MACOP-B), and eight months after the start of treatment both the lymphoma and the carcinoid tumour are in complete remission.

CASE 2

A 62 year old woman, a smoker, presented with left supraclavicular and cervical lymph node enlargement. Histological examination of a resected node showed an immunoblastic lymphoma (fig 1b) with monotypic immunoglobulin expression (IgM lambda). Chest radiographs showed a parahilar coin lesion in the left upper lobe, which was thought to be a secondary deposit. Cyclophosphamide, doxorubicin, vincristine, and prednisone (CHOP) were administered, and after six months there was complete nodal remission. The coin lesion, however, had enlarged from 15 to 22 mm in diameter, and fine needle aspiration cytology suggested bronchioloalveolar carcinoma.

A left upper lobectomy and dissection of the hilar and subcarinal lymph nodes were performed. Histologically, the tumour was an atypical carcinoid, composed of sheets and clusters of rather uniform cells with abundant cytoplasm and enlarged, atypical nuclei. Mitotic figures were present in moderate numbers (fig 2b). Positive reactions to cytokeratin 18 fragment (TPA), polycytokeratin (Lu 5), neurone specific enolase, and chromogranin A were obtained. Other immunocytochemical reactions for hormone and peptide antibodies were negative. The patient is now very well and free from disease 31 months after the primary diagnosis of non-Hodgkin's lymphoma was made.

Discussion

To our knowledge, there are no previous reports of coincident non-Hodgkin's lymphoma and pulmonary carcinoid. Probably the two tumours arose in our patients by chance, though there is an association between lymphatic leukaemia and various types of carcinoma,³⁻⁵ and experimental viral coinduction of lung cancer and lymphoid interstitial pneumonia has been described.⁶

A synchronous second primary tumour in a patient in whom an uncommon neoplasm has been diagnosed is difficult to detect, particularly when the clinical patterns of the two neoplasms overlap. In neither of our cases was a second primary suspected until it became obvious that the initially diagnosed tumour was pursuing an unusual clinical course. The lesions that had been assumed to be secondary deposits were then investigated further, and their true nature

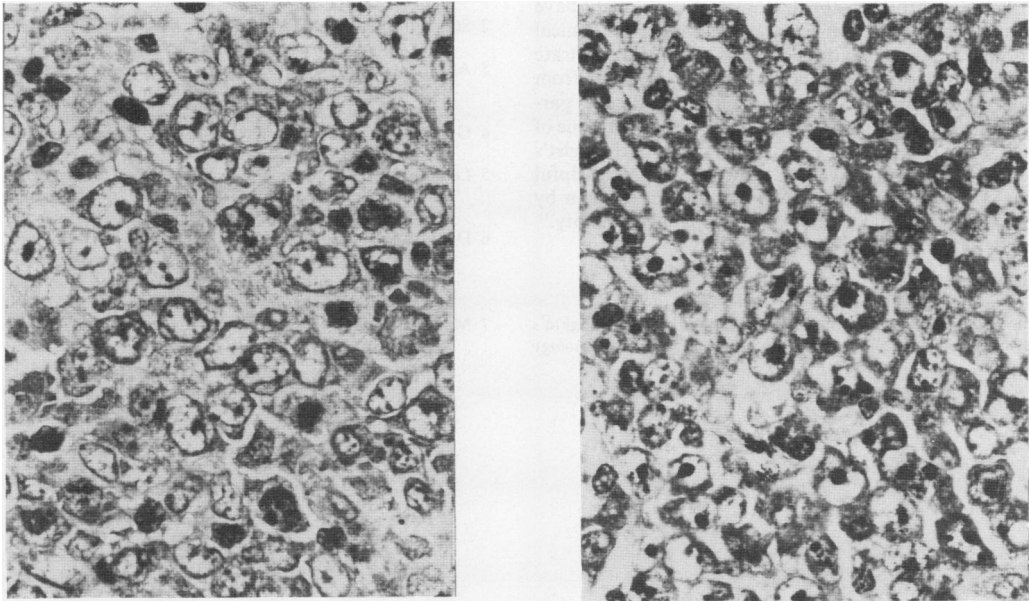


Fig 1 (a) Case 1: Diffuse lymph node infiltration by cells with round or slightly indented nuclei and one to four small to medium sized nucleoli, often located near the nuclear membrane, interspersed with some cells with a centrally located solitary nucleolus: centroblastic lymphoma, polymorphous subtype. (b) Case 2: Diffuse lymph node infiltration by sheets of cells with large, pale nuclei and prominent, solitary nucleoli: immunoblastic lymphoma. (Giemsa.)

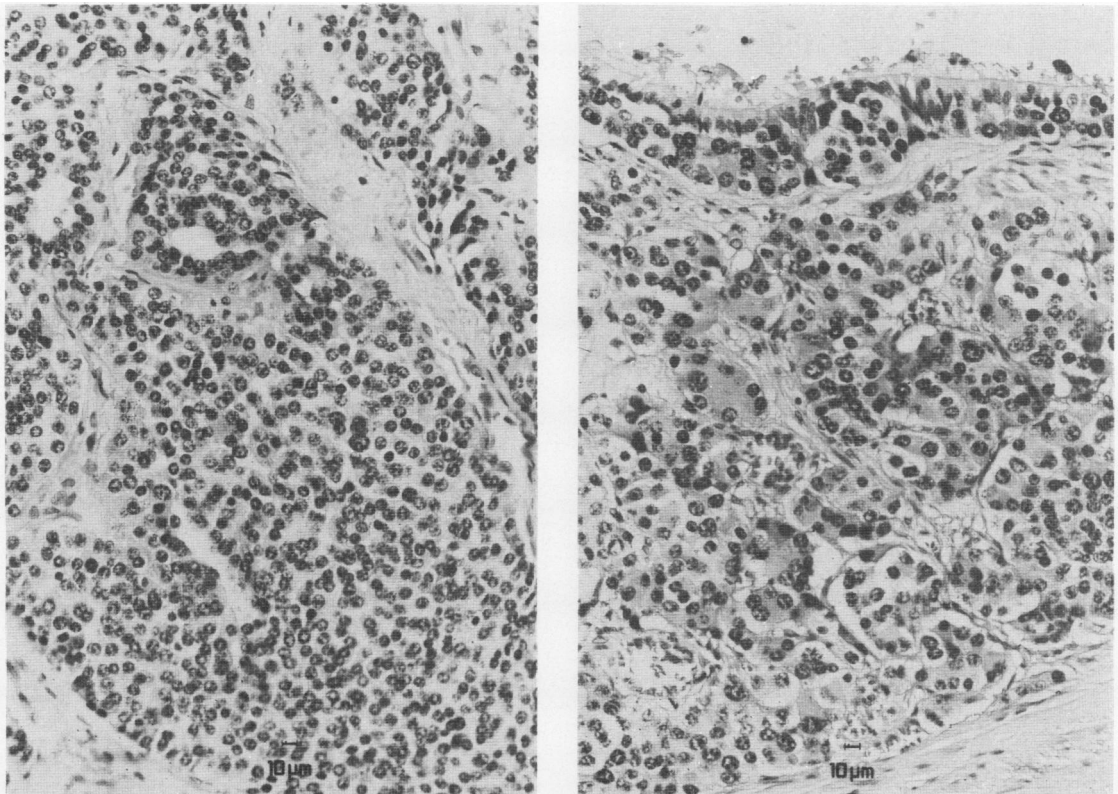


Fig 2 (a) Case 1: Atypical carcinoid tumour, solid type. The tumour shows nuclear atypia, nuclear polymorphism, and a few mitoses. In the upper portion two typical rosettes may be seen. (b) Case 2: Atypical bronchial carcinoid tumour composed of solid nests and invading the surface epithelium, showing mild nuclear polymorphism with a few mitoses. Typical rosettes are not present. (Haematoxylin and eosin.)

established. In retrospect, the diagnostic pitfalls might have been avoided by a more critical interpretation of the clinical findings and by further biopsies. These cases also illustrate the difficulty in distinguishing oat cell carcinoma from carcinoid tumour in bronchoscopic biopsy specimens, particularly when there is crush artefact,⁷ and the limited value of cytology in the diagnosis of rare tumours. The pathologist's information about a pre-existing diagnosis—however helpful in other contexts—may contribute to misinterpretation by creating a bias in favour of the “most probable possibility.”

References

- 1 Hui PK, Feller AC, Lennert K. High-grade non-Hodgkin's lymphoma of B-cell type. I. Histopathology. *Histopathology* 1988;12:127–43.
- 2 Stansfeld AG, Diebold J, Noel H, *et al*. Updated Kiel classification for lymphomas. *Lancet* 1988;i:292–3.
- 3 Adami HO, Bergkvist L, Krusemo UB, Persson I. Breast cancer as a risk factor for other primary malignant diseases. A nationwide cohort study. *J Natl Cancer Inst* 1984;73:1049–55.
- 4 Gunz FW, Angus HB. Leukemia and cancer in the same patient. *Cancer* 1965;18:145–52.
- 5 Lennert K. Histopathology and diagnosis of non-Hodgkin's lymphomas. In: Lennert K, ed. *Malignant lymphomas other than Hodgkin's disease*. Berlin: Springer, 1978:132–3.
- 6 DeMartini JC, Rosadio RH, Sharp JM, Russel HI, Lairmore MD. Experimental conduction of type D retrovirus-associated pulmonary carcinoma and lentivirus-associated lymphoid interstitial pneumonia in lambs. *J Natl Cancer Inst* 1987;79:167–78.
- 7 Mark EJ. *Lung biopsy interpretation*. Baltimore: Williams and Wilkins, 1984:189.