

# Chickenpox pneumonia: an association with pregnancy

T F ESMONDE, G HERDMAN, G ANDERSON

From Newport Chest Clinic, Newport, Gwent

**ABSTRACT** Three pregnant patients with chickenpox pneumonia are described. A review of reports published since 1965 together with these cases shows that 28 of the 46 women (61%) were pregnant, and 21 were in the last trimester. Although the disease is more common and more severe in pregnancy, the proportion of deaths was no greater than usual. In this retrospective analysis there was no evidence that treatment with acyclovir conferred benefit but this may have reflected its use only in very ill patients.

## Introduction

In our hospital over two years we have seen three pregnant women with chickenpox pneumonia. This prompted a search of reports published worldwide to find whether chickenpox pneumonia was associated with pregnancy and whether pregnancy affected the outcome.

## Case reports

### CASE 1

A 27 year old woman at 16 weeks' gestation was admitted with a five day history of rash and dyspnoea of two days' duration. She was centrally cyanosed and dyspnoeic at rest, and had a widespread erythematous maculopapular rash with vesicles and harsh breath sounds throughout both lung fields.

Chest radiography showed extensive confluent mottling throughout both lung fields. Arterial blood gas analysis while she was breathing air showed that pH was 7.42, oxygen tension ( $P_{aO_2}$ ) 2.3 kPa, and carbon dioxide tension ( $P_{aCO_2}$ ) 4.3 kPa. She was initially treated with 90% oxygen, which caused the  $P_{aO_2}$  to rise to 6.9 kPa while the  $P_{aCO_2}$  remained unchanged. As the patient was exhausted, however, ventilation was instituted and nine days later a tracheostomy was performed. Her condition improved subsequently, the tracheostomy was closed, and the patient was discharged 23 days after admission. Blood gas tensions and the chest radiograph had returned to normal. She delivered a healthy female infant by spontaneous vaginal delivery at 40 weeks' gestation.

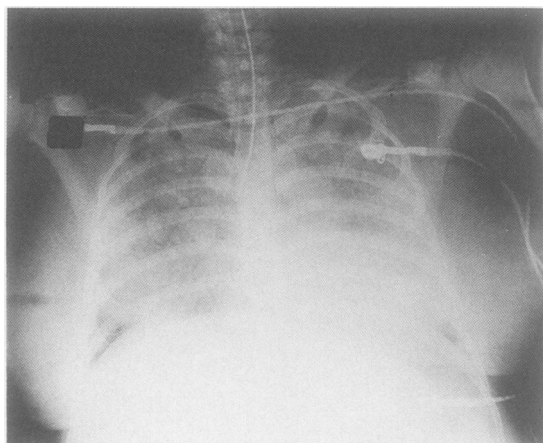
Address for reprint requests: Dr G Anderson, Newport Chest Clinic, 129 Stow Hill, Newport, Gwent NP9 4GA.

Accepted 13 July 1989

### CASE 2

A 35 year old woman at 30 weeks' gestation was admitted with a two day history of rash and dyspnoea of one day's duration, having had contact with a case of chickenpox two weeks before. She was centrally cyanosed and dyspnoeic at rest, with a widespread erythematous macular rash with vesicles.

Arterial blood gas analysis on admission showed pH to be 7.43,  $P_{aO_2}$  6.5 kPa, and  $P_{aCO_2}$  3.3 kPa. The chest radiograph (figure) showed homogeneous shadowing throughout both lung fields. Administration of 100% oxygen did not produce appreciable improvement and assisted ventilation was instituted. Intravenous acyclovir was begun at a dose of 5 mg/kg eight hourly. Despite this her condition deteriorated rapidly and she died 12 hours after admission. Necropsy showed congested lungs with a liver like



Chest radiograph of patient 2 on admission, showing homogeneous shadowing throughout both lung fields.

appearance. Microscopy showed bacterial superinfection but no specific changes attributable to chickenpox pneumonia.

**CASE 3**

A 25 year old woman at 36 weeks' gestation presented with a two day history of increasing dyspnoea and dry cough. Four days before this she had developed a chickenpox rash. At presentation she was febrile (38°C), with a typical chickenpox rash, a respiratory rate of 25/min, and tachycardia (130 beats/min). Examination of the chest showed nothing remarkable.

The chest radiograph showed bilateral confluent mottling. Arterial blood gas analysis on admission showed pH to be 7.38, PaCO<sub>2</sub> 3.5 kPa, and PaCO<sub>2</sub> 5.5 kPa. The patient was given 60% oxygen and intravenous acyclovir 10 mg/kg eight hourly. Her condition deteriorated over the next six hours and an emergency caesarian section was performed. Assisted ventilation was continued postoperatively. A healthy baby girl was delivered, who developed chickenpox six days after birth. The mother was ventilated for a total of five days and had acyclovir for seven days. Recovery was complicated by a deep venous thrombosis in the right calf. Mother and baby were discharged three weeks later. Arterial blood gas tensions and the chest radiograph had returned to normal.

**Review of previous reports**

A review of the reports published since 1965<sup>1-34</sup> combined with our three cases yields a description of 99 adults with chickenpox pneumonia (table 1).

Of the 46 women (in nine others the sex was not stated), 28 were pregnant, indicating a clear association with pregnancy. The disease occurred in the third trimester in 21 and in the second in three; the duration of pregnancy was not stated in four. As judged by the number requiring assisted ventilation, chickenpox pneumonia appeared to be a more serious illness in pregnancy, but mortality (11%) was similar to that in non-pregnant patients. Treatment with antiviral agents did not appear to confer benefit; five of 44 patients (11%) receiving acyclovir and none of six

patients receiving other antiviral agents died, compared with five of 49 (10%) patients who received no antiviral drug ( $\chi^2 = 0.178$ ,  $p > 0.5$  for summation of results). The benefit from acyclovir could be obscured if patients were given the drug only if they were more ill than those who were not. When adult mortality in the era before the introduction of acyclovir was compared with that in the period after its introduction no significant difference was found (table 2).

When the mother survived infant mortality was low and only one infant died. Six infants were delivered during the illness and 15 after it. Only two infants born alive developed chickenpox.

**Discussion**

The varicella-zoster virus is a highly contagious DNA virus. Five per cent of women in the child bearing age lack specific IgG and are therefore susceptible. Varicella has been thought to be relatively infrequent in pregnancy, with an incidence of 0.7 per 1000 pregnancies.<sup>35</sup> In the United States the mean incidence for women of 15-45 years of age is 2.2/1000/year.

Carstairs and Emond<sup>36</sup> in 1963 reported 120 patients from published reports with acute chickenpox pneumonia, and Knyvett (1965)<sup>37</sup> described a personal series of 35 cases. In these earlier descriptions clinical data were scanty and Knyvett did not record the age or sex incidence, or whether any of the patients were pregnant. For these reasons we have confined our analysis to patients described since 1965.

Only four of the cases that occurred during pregnancy occurred outside the last trimester. This may be explained by the progressive changes in the immune system that occur in pregnancy,<sup>38</sup> the immune system

Table 2 *Numbers of patients surviving before and after the introduction of acyclovir*

	Survived	Died
Before acyclovir	29	1
Acyclovir era	60	9

$\chi^2 = 1.23$ ,  $p > 0.02$ .

Table 1 *Adult chickenpox pneumonia: a review of previously published cases combined with the present three (number (%))*

	Sex	Ventilated	Died	Acyclovir used	Other antiviral agents‡	Fetus died
Non-pregnant (n = 71)	M 44 F 18 ? = 9†	13 (18) (?18†)	7 (10)	28 (39)	2 (3)	
Pregnant (n = 28)*		13 (46)	3 (11)	16 (57)	4 (14)	3 (11)

\*Twenty one in last trimester and four unknown.

†Not stated.

‡Cytosine arabinoside, idoxuridine, gammaglobulin, adenine arabinoside.

being required to mount a normal immune response to exogenous antigen while not mounting a response against the foreign antigen of the fetal trophoblast. This task is accomplished by several changes in the immune system: the thymus becomes progressively involuted owing to increased concentrations of oestradiol and corticosteroids, the number of monocytes is increased (though there are conflicting reports about the number of T and B cells), and there is an increase in leucocyte phagocytic and bactericidal responses. Other abnormalities, such as antibody and allergen responses, are less clearly defined. These immunological disturbances of pregnancy may be mediated by pregnancy associated globulins. Pregnancy is associated with an increased incidence of influenza, cytomegalovirus and *Haemophilus influenzae* infections, and tuberculosis.<sup>39-41</sup> Early delivery of the infant during the illness is unnecessary to save the mother's life. This is at variance with the experience in Lassa fever.<sup>42</sup>

Only two infants developed chickenpox after delivery. In both cases delivery occurred within four days of the mother's developing chickenpox, allowing no time for her protective IgG to cross the placenta to protect the infant.

Antiviral treatment, in particular the introduction of acyclovir in 1979, does not appear to have altered the outcome and its role in treatment is unproved.

Diffuse pulmonary calcification may occur three to 10 years after chickenpox pneumonia, and this was present in three of 21 patients who underwent prolonged follow up. In the present review of 99 patients none had pulmonary calcification, but this probably reflects the brief duration of follow up.

Patient 3 was under the care of Dr J Davies and we are grateful for his permission to describe the case.

## References

- 1 Leen CL, Mandal BK, Ellis ME, Brettle RP. Acyclovir and pregnancy [letter]. *Br Med J* 1987;294:308.
- 2 Weber DM, Pellicchia JA. Varicella pneumonia: a study of prevalence in adult men. *JAMA* 1965;192:228-9.
- 3 Pillans P. Chicken-pox pneumonia. *S Afr Med J* 1983;63:861-2.
- 4 Triebwasser JH, Harris RE, Bryant RE, Rhoades ER. Varicella pneumonia in adults: report of seven cases and review of the literature. *Medicine (Baltimore)* 1967;46:409-23.
- 5 Harris RE, Rhoades ER. Varicella pneumonia complicating pregnancy: report of a case and review of the literature. *Obstet Gynecol* 1965;25:734-40.
- 6 Hankins GD, Gillstrap III LC, Patterson AR. Acyclovir treatment of varicella pneumonia in pregnancy [letter]. *Crit Care Med* 1987;15:336-7.
- 7 Williams MT, Marsland DW. Varicella pneumonia at parturition: a non-fatal case. *J Fam Pract* 1976;3:153-4.
- 8 Winkelmann RK, DeRemee RA, Ritts RE. Treatment of varicella-zoster pneumonia with transfer factor. *Cutis* 1984;34:278-81.
- 9 Scully RE, Galdabini JJ, McNeely BU, eds. Case records of the Massachusetts General Hospital: weekly clinicopathological exercises: case 9: 1976. *N Engl J Med* 1976;294:485-93.
- 10 MacFarlane JT, Smith FD, Finch RG. Vidarabine in fulminating chickenpox pneumonia. *Thorax* 1982;37:226-7.
- 11 Boyd K, Walker E. Use of acyclovir to treat chickenpox in pregnancy. *Br Med J* 1988;296:393-4.
- 12 Lowthian JT, Gillard LJ. Varicella pneumonia in the gravid patient. *J L A State Med Soc* 1980;132:69-70.
- 13 Duong CM, Munns RE. Varicella pneumonia during pregnancy. *J Fam Pract* 1979;8:277-80.
- 14 Chitkara R, Gordon RE, Khan FA. Acyclovir in the treatment of primary varicella pneumonia in non-immunocompromised adults [letter]. *NY State J Med* 1987;87:237-8.
- 15 Munnich D. Nagy kiterjedesu ketoldali tudogyulladassal jaro felnottkori varicella progressiva esetunk sikeres intravenas Zovirax/acyclovir/kezelese. *Orvosi Hetilap* 1985;126:1663-5.
- 16 Kuster W, Hofner W, Wicke L, Kuhböck J. Varicellenpneumonie bei Morbus Hodgkin. *Radiologe* 1987;18:398-400.
- 17 Raidt H, Gottschalk D, Krummenerl T, et al. Acyclovir bei schwerer Varizellapneumonie und bei Herpes ophthalmicus. *Praxis* 1983;72:1179-82.
- 18 Tatti V. La pneumonie à varicelle chez l'adulte. *Rev Med Suisse Romande* 1975;95:263-7.
- 19 Landsberger EJ, Hager WD, Grossman III JH. Successful management of varicella pneumonia complicating pregnancy: a report of 3 cases. *J Reprod Med* 1986;31:311-4.
- 20 Ellis ME, Neal KR, Webb AK. Is smoking a risk factor for pneumonia in adults with chickenpox? *Br Med J* 1987;294:1002.
- 21 van der Meer JW, Thompson J, Tan WD, Versteeg J. Treatment of chickenpox pneumonia with acyclovir [letter]. *Lancet* 1980;ii:473-4.
- 22 Teare EL, Cohen JA. Treatment of chickenpox pneumonia with adenine arabinoside [letter]. *Lancet* 1979;i:873.
- 23 Aizawa H, Ohsaki Y, Sakai E, Ikeda Y, Kuwajima T, Onodera S. Two cases of primary varicella pneumonia [Japanese]. *Nippon Kyobu Shikkan Gakkai Zasshi* 1986;24:195-9.
- 24 Sellegger C. Pneumonie varicelleuse mortelle chez l'adulte: rapport de deux cas et revue de la littérature. *Rev Fr Mal Respir* 1979;7:9-18.
- 25 Bryer A, Potgeiter PD, Moodie J. Acyclovir and varicella pneumonia [letter]. *S Afr Med J* 1984;66:515.
- 26 Eder SE, Apuzzio JJ, Weiss G. Varicella pneumonia during pregnancy: treatment of two cases with acyclovir. *Am J Perinatol* 1988;5:16-8.
- 27 Myint SS, Lee SK. Chickenpox pneumonia: a case report. *Singapore Med J* 1986;27:80-3.

- 28 Wolters J, Maesen F, Lamers J. Varicellapneumonie. *Ned Tijdschr Geneesk* 1979;**123**:1777-82.
- 29 Davidson RN, Lynn W, Savage P, Wansbrough-Jones MH. Chickenpox pneumonia: experience with antiviral treatment. *Thorax* 1988;**43**:627-30.
- 30 Hammershoy O. Primaer varicelpneumoni. *Ugeskr Laeger* 1979;**141**:1855.
- 31 Harper JR, Marshall RD, Parkinson MS. Intermittent positive-pressure ventilation in chickenpox pneumonitis. *Br Med J* 1969;iii:637-8.
- 32 Glaser JB, Loftus J, Ferragamo V, Mootabar H, Castellano M. Varicella-zoster infection in pregnancy. [letter]. *N Engl J Med* 1986;**315**:1416.
- 33 Paryani SG, Arvin AM. Intrauterine infection with varicella-zoster virus after maternal varicella. *N Engl J Med* 1986;**314**:1542-6.
- 34 Schlossberg D, Littman M. Varicella pneumonia. *Arch Intern Med* 1988;**148**:1630-2.
- 35 Enders G. Varicella-zoster virus infection in pregnancy. *Prog Med Virol* 1984;**29**:166-96.
- 36 Carstairs LS, Emond RTD. Chickenpox virus pneumonia. *Proc R Soc Med* 1963;**56**:267-70.
- 37 Knyvett AF. The pulmonary lesions of chickenpox. *Q J Med* 1966;**166**:313-23.
- 38 Head JR, Billingham RE. Immunobiological aspects of the maternal-fetoplacental relationship. In: Lachmann PJ, Peters DK, eds. *Clinical aspects of immunology*. 4th ed. Vol 1. Oxford: Blackwell 1982:243-82.
- 39 Eickoff TC, Shermon IL, Serfling RE. Observations on excess mortality associated with epidemic influenza. *JAMA* 1969;**176**:776-82.
- 40 Kumar ML, Prokay SL. Experimental primary cytomegalovirus infection in pregnancy: timing and foetal outcome. *Am J Obstet Gynecol* 1983;**145**:56-60.
- 41 Sanberg T, Dahlbert T. Meningitis and septicaemia due to *Haemophilus influenzae* type B in pregnancy. *Br Med J* 1981;**282**:584-6.
- 42 Price ME, Fisher-Hoch SP, Craven RB, *et al.* A prospective study of maternal and fetal outcome in acute Lassa Fever infection during pregnancy. *Br Med J* 1988;**297**:584-6.