

Short reports

“Slurry lung”: a report of three cases

J V Fahy, T Walley, R T N Gibney,
M McCabe, M X FitzGerald

Abstract

Three cases of “slurry lung” are reported, which occurred after accidental total immersion in a slurry pit.

Liquid organic animal waste (manure or slurry) is potentially hazardous to farm workers. Decaying organic matter produces toxic gases, such as ammonia, carbon monoxide, methane, and hydrogen sulphide, which if inhaled may cause asphyxia or pulmonary oedema,¹⁻⁷ and the bacteria in the slurry, if aspirated, may cause severe pulmonary infection.¹⁷

Case reports

PATIENT 1

A 37 year old man fell into a slurry pit because the lid had not been properly sealed. He aspirated a large amount of slurry and on arrival at a local hospital was severely dyspnoeic with an arterial oxygen tension (PaO₂) of 5.3 kPa and a carbon dioxide tension

(Paco₂) of 6.57 kPa when breathing air. He was intubated and given assisted ventilation and penicillin and corticosteroids intravenously. On transfer to our unit 24 hours later his chest radiograph showed bilateral infiltrates. Endotracheal suction produced small quantities of organic material, from which anaerobic *Bacteroides* and aerobic enteric organisms were cultured. Corticosteroids were discontinued and the patient improved on a regimen of intravenous gentamicin, penicillin, and metronidazole. He required assisted ventilation for 48 hours and was discharged well within two weeks, remaining in good health one year later with normal lung function and a normal chest radiograph.

CASE 2

A 61 year old farmer was immersed in bovine slurry when the tractor he was driving overturned into an open slurry pit. He aspirated a large quantity of slurry and on arrival at hospital four hours later was febrile, tachypnoeic, and coughing up large quantities of slurry. He had no prior history of lung disease, but had smoked 20 cigarettes daily for 30 years. The chest radiograph showed extensive bilateral basal consolidation (fig 1). Blood gas analysis when he was breathing air showed a PaO₂ of 6.8 kPa and a Paco₂ of 6.45 kPa. Sputum culture yielded *Escherichia coli* and *Proteus vulgaris*. He was treated with oxygen and high dose intravenous amoxycillin, flucloxacillin, gentamicin, and metronidazole. Corticosteroids were not given. He improved initially with some resolution of the shadowing on the chest radiograph, but four days later he deteriorated with worsening hypoxaemia and a repeat chest radiograph showed diffuse pulmonary infiltrates. Continuous positive airways pressure and oxygen were administered by face mask. He improved over three weeks. Prior to discharge he was mildly hypoxaemic and, although spirometric values were normal, transfer factor for carbon monoxide (TLCO) was reduced (62% predicted). Six weeks later it was 68% predicted and the chest radiograph remained abnormal with cystic changes at the left base.

CASE 3

A 15 year old boy fell into a slurry pit. He was of low intelligence and unable to give details of the nature and duration of the immersion. He was symptomless for one week, but then developed progressive severe dyspnoea on exertion and was admitted to hospital two weeks after exposure. A chest radiograph showed bilateral infiltrates. He was severely hypoxaemic (PaO₂ 3.5 kPa breathing air). Sputum culture grew no organisms. He was treated initially with oxygen, intravenous erythromycin, and gentamicin but deteriorated further and required intubation

Department of
Respiratory Medicine,
St Vincent's Hospital,
Dublin 4, Ireland

J V Fahy
T Walley
R T N Gibney
M McCabe
M X FitzGerald

Reprint requests to:
Professor FitzGerald

Accepted 6 December 1990

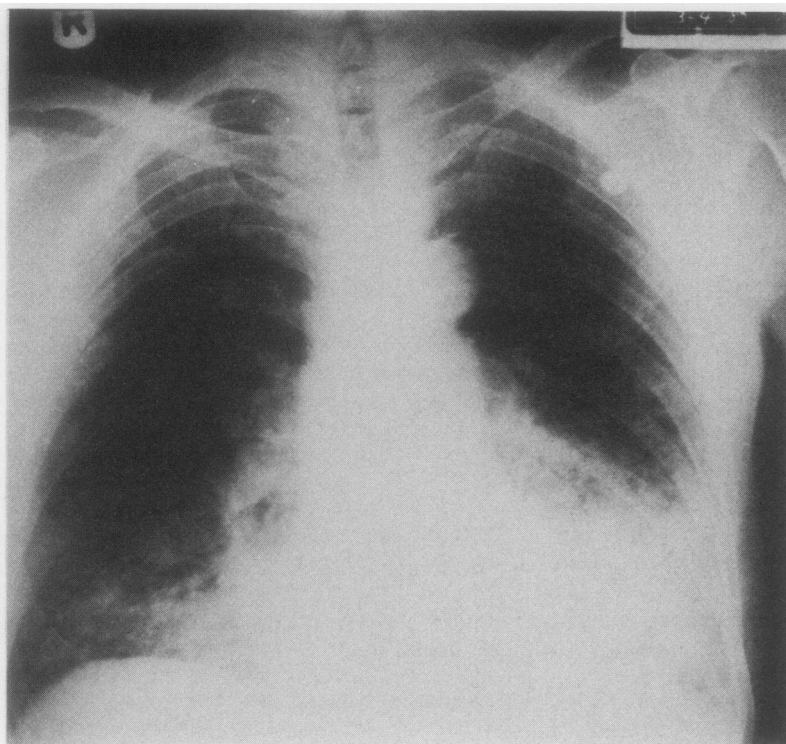
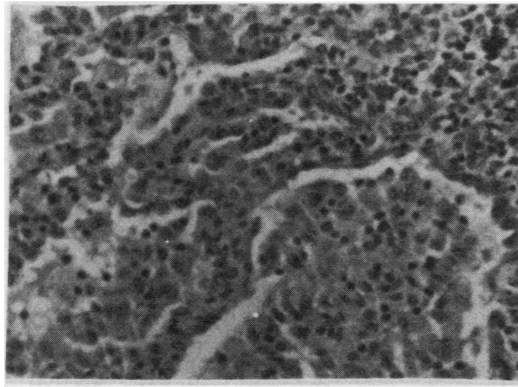


Figure 1 Chest radiograph (patient 2) showing bilateral basal consolidation at admission.

Figure 2 Intra-alveolar aggregates of macrophage like cells, with some lymphocytic infiltration of the alveolar walls. The appearances are characteristic of desquamative interstitial pneumonitis.



and assisted ventilation. Bronchoscopic appearances were normal but histological evaluation of an open lung biopsy specimen showed appearances indistinguishable from those of desquamative interstitial pneumonitis (fig 2). No organisms, birefringent materials, or hyaline membranes were seen. Reticulin was moderately increased in the alveolar walls and there was extensive reticulin deposition within the intra-alveolar spaces. Assisted ventilation was continued for three weeks and progress was complicated by nosocomial infections and bilateral pneumothoraces. The patient eventually made a good recovery and was discharged after eight weeks in hospital. Two years later he remained well with no treatment. His chest radiograph was normal. Lung function testing showed a mildly restrictive pattern and a TLCO of 83% predicted.

Discussion

This report documents the outcome of accidental aspiration of bovine slurry in three farmworkers. Previous reports have emphasised the dangerous and sometimes fatal consequences of the associated toxic gas (particularly hydrogen sulphide) exposure.¹⁻⁶ The cases presented here differ in that these men accidentally fell into improperly covered slurry pits. In two cases there was an immediate and obvious pulmonary aspiration injury characterised by active expectoration of slurry, respiratory distress, fever, hypoxaemia and pulmonary infiltrates on the chest radiograph. This initial reaction was clearly due to the direct effects of a large inoculum of slurry in the lung, giving rise to gross aspira-

tion pneumonia. Toxic gas inhalation may also have contributed. Two patients also sustained a delayed pulmonary reaction, one apparently in isolation one week after exposure and the other four days after temporary subsidence of an initial acute reaction. These "late" reactions presented clinically as the adult respiratory distress syndrome. Histological material was available in one case and the appearance was indistinguishable from that of desquamative interstitial pneumonia. This finding presumably represents a non-specific reaction of the lung in response to various noxious agents.^{8,9}

The management of these patients was governed by considerations related to the likely bacterial load of unusual organisms found in the liquid animal manure. Thus all cases were treated with high doses of broad spectrum antibiotics directed against aerobic and anaerobic organisms. We elected not to give corticosteroid treatment because of the potential for aggravating severe Gram negative and anaerobic lung infection. The oldest patient did not recover fully and this may have been due to the severity of his exposure or to his prior lung function, which could have been compromised by cigarette smoking. In summary, these cases illustrate the wide range of lung disease that may result from exposure to slurry and underline the need for caution by farm workers in servicing liquid manure pits.

- 1 Osbern L, Crapo R. Dung lung: a report of toxic exposure to liquid manure. *Ann Intern Med* 1981;95:312-4.
- 2 Donham KJ, Knapp LW, Monson R, Gustafson K. Acute toxic exposure to gases from liquid manure. *J Occup Med* 1982;24:142-5.
- 3 Morse DL, Woodbury MA, Rentmeester K, Farmer D. Death caused by fermenting manure. *JAMA* 1981; 245:63-4.
- 4 Anonymous. Deaths associated with liquid-manure systems—United States. *Morbidity and Mortality Weekly Reports* 1981;30:152-7.
- 5 Anonymous. Death in a farm-worker associated with toxic gases from a liquid manure system—Wisconsin. *Morbidity and Mortality Weekly Reports* 1978;27:47-8.
- 6 Lam de Kort W, Sangster B. Acute intoxication during work. *Vet Hum Toxicol* 1988;30:9-11.
- 7 Guerin CK, Owen R, Keys T. Aspiration of barnyard manure. *Minnesota Med* 1983;66:359-60.
- 8 Spencer J. *Pathology of the lung*. 3rd ed. Oxford: Pergamon Press, 1977:768-71.
- 9 Thurlbeck WM. *Pathology of the lung*. New York: Thieme, 1988:440-1.