

Medical Progress

Uveitis

A Review

CAREEN Y. LOWDER, MD, PhD, and DEVRON H. CHAR, MD, San Francisco

Uveitis is the term used to describe most intraocular inflammations. The classification of uveitis into anterior, posterior and diffuse is based on the physical appearance of an inflamed eye. Diagnosis is usually on the basis of a thorough history, a review of systems to uncover any systemic diseases known to be associated with uveitis and a complete eye examination. We review the most common types of uveitis, the pertinent laboratory investigations and different therapeutic aspects.

(Lowder CY, Char DH: Uveitis—A review [Medical Progress]. West J Med 1984 Mar; 140: 421-432)

Uveitis is the term used to describe many forms of intraocular inflammation involving the uveal tract (iris, ciliary body and choroid) and adjacent ocular structures (retina, vitreous and optic nerve). Uveitis is derived from the Latin *uva*, or "grape"; a peeled blue grape has a bluish vein structure that resembles the middle, vascular layer of the eye, the uvea. The uvea consists of the iris anteriorly and the ciliary body and choroid posteriorly. Inflammation of the anterior uvea is termed anterior uveitis or "iritis." If only the iris is involved, the condition is called "iritis." Inflammation of the ciliary body is "cyclitis," and choroidal inflammation is termed "choroiditis." In clinical usage, uveitis has come to describe most forms of intraocular inflammation. If a layer contiguous with the uvea is predominantly involved in an inflammatory process, the term used for the intraocular inflammation is modified accordingly—that is, retinochoroiditis, retinitis or vitritis.¹

Intraocular biopsy is associated with significant morbidity including loss of the eye, loss of vision or contralateral ocular inflammation. In most cases of uveitis, diagnosis is established on the basis of a thorough history, a review of systems and a physical examination. The physical appearance of an inflamed eye is classified by a variety of methods. Hogan and co-workers² have used the classification anterior, posterior and diffuse uveitis. Anterior uveitis consists of either iritis or iridocyclitis. Uveitis involving the middle portion of the eye is termed either cyclitis or intermediate uveitis. The classification of posterior uveitis depends on which

intraocular layer is predominantly involved. It is termed choroiditis or retinitis when just the choroid or the retina is involved. Retinochoroiditis or chorioretinitis is used when both layers are involved; in the latter situation the first portion of the term denotes the most intensely involved layer of the eye. Another commonly used ophthalmic uveitis classification is the division into granulomatous or nongranulomatous. These terms refer to the clinical appearance—especially the inflammatory cell pattern—on the posterior corneal surface. In granulomatous uveitis, deposits of cells on the posterior cornea (keratic precipitates) appear rather large and greasy in contradistinction to nongranulomatous deposits, which are discrete (Figure 1). The clinical designations of granulomatous or nongranulomatous do not correlate with histopathologic findings.

Clinical Signs of Uveitis

Inflammation of the Anterior Segment

In anterior uveitis there is often vascular congestion of the conjunctiva and the sclera (ciliary flush) (Figure 2). Inflammation of the anterior uvea (iris and ciliary body) results in increased vascular permeability; cells and protein are detectable on slit-lamp biomicroscopy of the anterior chamber (aqueous humor) (Figure 3). Inflammatory cells may be deposited on the posterior corneal surface, anterior chamber angle or on either the anterior surface or pupillary border of the iris. These depositions may result in an adhesion between the pupillary margin of the iris and the lens. These adhesions are termed "posterior synechiae" (Figure 4). Peripheral

From the Francis I. Proctor Foundation and the Department of Ophthalmology, University of California, San Francisco, School of Medicine.

Supported in part by an unrestricted grant from Research to Prevent Blindness, and from National Institutes of Health (NIH) grants EY-01441, EY-03675, EY-01759, EY-07058 and EY-01597. Dr Char is a recipient of an NIH Career Development Award (KO4-EY00117).

Reprint requests to Devron H. Char, MD, Director, Ocular Oncology Unit, Science 315, University of California, San Francisco, CA 94143.

ABBREVIATIONS USED IN TEXT

AIDS=acquired immune deficiency syndrome
 CT=computed tomography
 HLA=human leukocyte antigen

anterior synechiae may occur between the anterior iris and the cornea; if these peripheral anterior synechiae occur for 360 degrees, the anterior chamber angle is closed and the intraocular pressure increases (resulting in glaucoma). Alternatively, as a result of uveitis, intraocular pressure may decrease and aqueous humor production by the inflamed ciliary body be diminished. Chronic or recurrent anterior uveitis often leads to opacification of the lens with visually significant cataract formation.

Inflammation of the Posterior Segment

Vision often decreases as a result of posterior segment inflammation, due to opacities in the vitreous, or from inflammation or vascular occlusions of the macular area (fovea) or the optic nerve. Inflammatory single cells

or aggregates in the vitreous cavity are perceived by a patient as "floaters" and may be detected either by a slit-lamp examination or with an ophthalmoscope (Figure 5). The retina, which is normally transparent, appears cloudy or white when inflamed. Inflammation involving only the choroid appears as yellow, white or grey patches with well-defined borders (Figure 6). Retinal vasculitis may occur with vascular cuffing, arterial or venous occlusions or hemorrhages (Figure 7). Histologically, there are lymphocytes cuffing the inflamed retinal vessels. Increased vascular permeability of retinal vessels in either the macula or the optic nerve leads to edema and diminution of vision. Persistent macular edema results in permanent visual disability due to the formation of macular cysts (Figure 8). Optic atrophy may occur as a consequence of chronic inflammation of the optic nerve.

Uveitis Syndromes

General Comments

The laboratory workup for patients with uveitis is relatively limited. A patient's age, mode of onset of

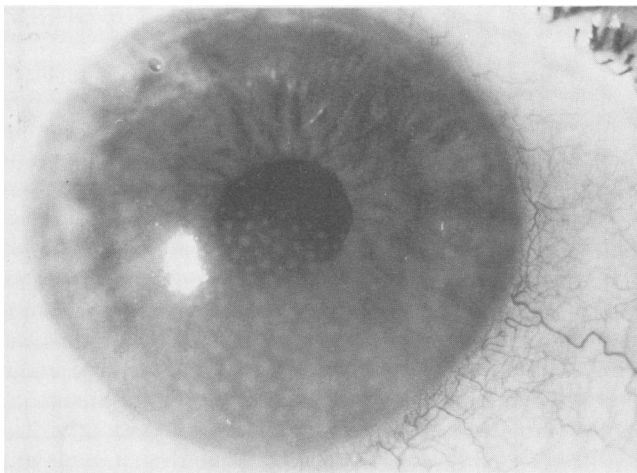


Figure 1.—Photograph of an eye showing keratic precipitates (large "mutton-fat" deposits).

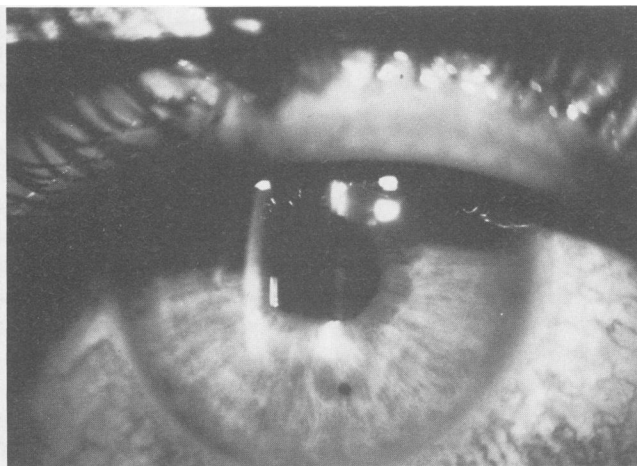


Figure 2.—Photograph shows an example of ciliary flush (perilimbal injection of ciliary vessels).

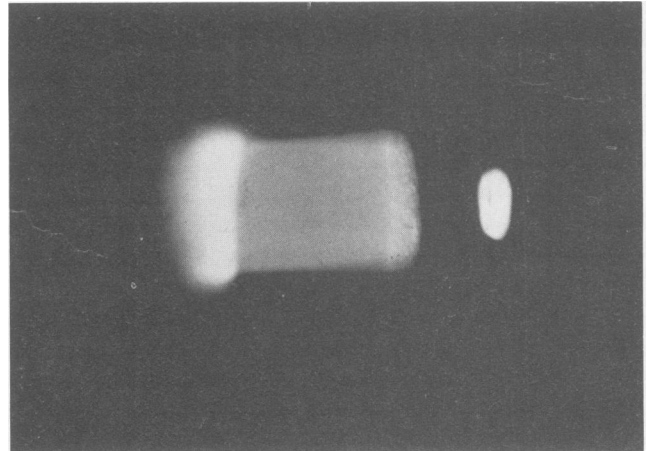


Figure 3.—An example of aqueous flare—increased protein content in the aqueous humor—as viewed with a slit-lamp biomicroscope.

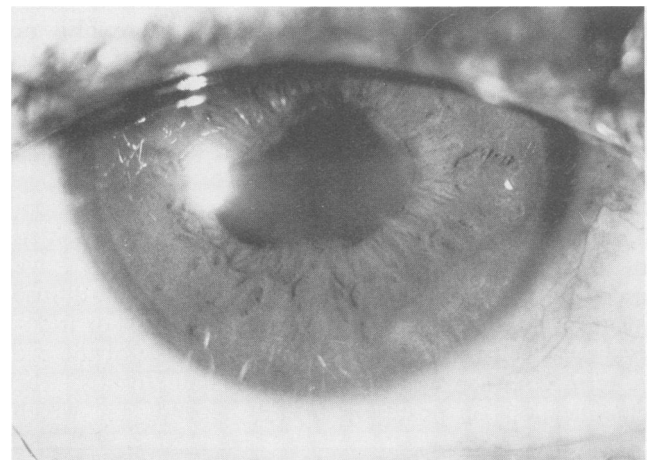


Figure 4.—The eye shows posterior synechiae (adhesions between pupillary margin and lens), causing an irregular pupil.

disease and intraocular location of the main focus of inflammation are useful in establishing a differential diagnosis and in selecting the appropriate laboratory tests. Table 1 lists common uveitis syndromes that occur at different ages and in different parts of the eye.

In Tables 2 and 3 are listed hematologic, radiologic and nuclear medicine tests for the diagnostic workup of patients who have uveitis.

It is impossible in a short review to exhaustively discuss all forms of uveitis and their therapies. We present below the clinical findings, diagnostic evaluation and treatment of the most common forms.

Acute Anterior Uveitis

Acute anterior uveitis (iritidocyclitis) is usually associated with rheumatoid-negative spondyloarthropathies. Patients have ocular pain, redness, photophobia and tearing. They may have a history of low back pain, but many will present with ocular involvement before the discovery of the systemic disease. Many patients will have a family history of rheumatoid-negative spondyloarthropathies. Patients with acute anterior uveitis re-

quire a limited laboratory workup. There is a strong human leukocyte antigen (HLA)-disease association between HLA-B27 and a number of the rheumatoid-negative spondyloarthropathies. In some series almost 100% of patients with acute anterior uveitis and ankylosing spondylitis are HLA-B27-positive.³ The reason for the HLA-disease association in uveitis is unclear; a number of hypotheses, including immunogenetic factors, molecular mimicry or HLA antigen receptors serving as receptors for pathogens, have been cited, but the evidence is not definitive.^{4,5} The frequency of HLA-B27 in various diseases associated with acute anterior uveitis is shown in Table 4.

Ankylosing Spondylitis

Unilateral acute iridocyclitis occurs in a high percentage of patients with ankylosing spondylitis. The eye disease may precede systemic signs and symptoms; 80% of patients are men between 15 and 40 years of age. Between 85% and 100% of white patients with ankylosing spondylitis who have acute anterior uveitis will have the HLA-B27 antigen. Many of these patients do

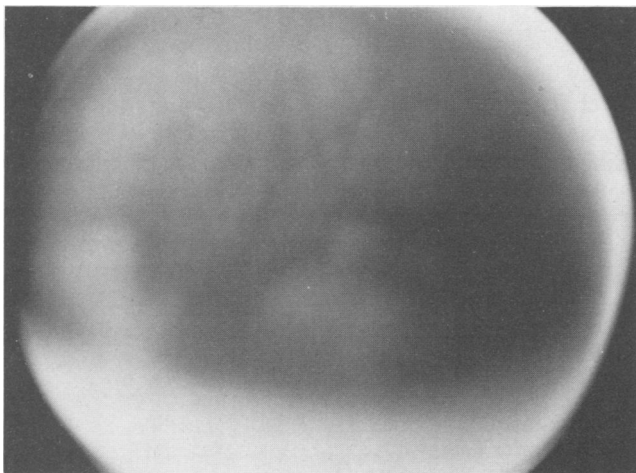


Figure 5.—The photograph shows a vitreous floater. Note the inflammatory aggregates and “snowbanking.”

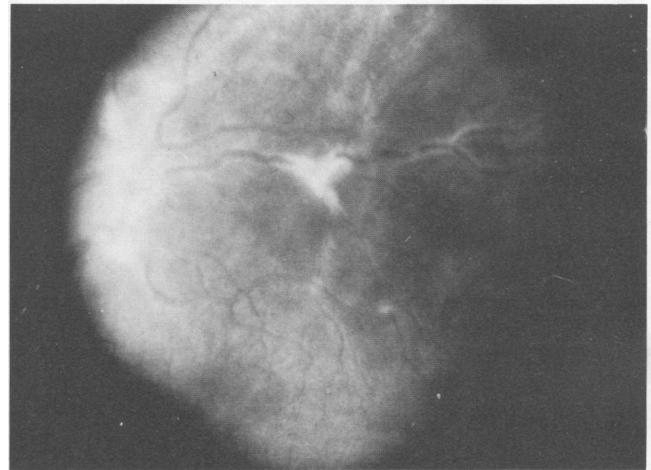


Figure 7.—The vascular sheathing noted in this photograph is seen in periphlebitis.

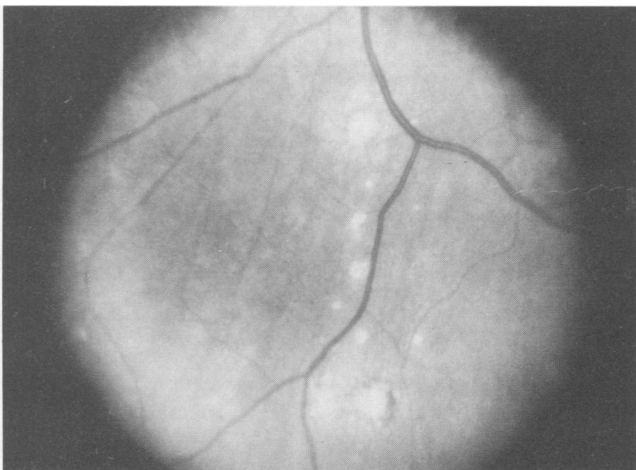


Figure 6.—An eye showing choroiditis: round and occasionally pigmented scars from choroidal inflammation.

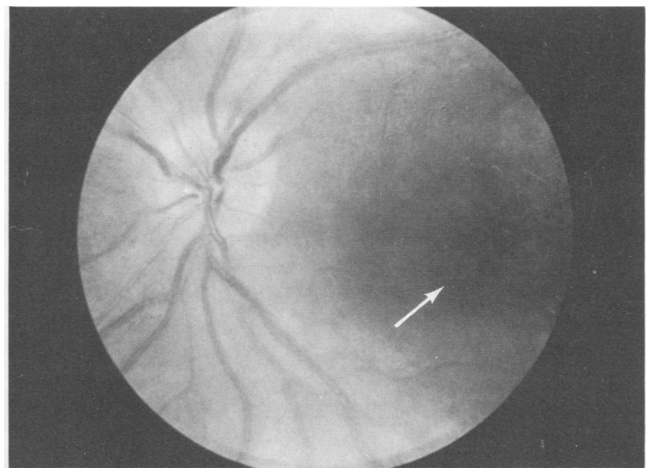


Figure 8.—Photograph of an eye showing the typical appearance of cystoid macular edema. Intraretinal cystic spaces indicated by arrow.

UVEITIS

not at first have lower back symptoms but have positive findings on sacroiliac joint films. Those patients who are HLA-B27-positive but who have no radiologic abnormalities should be examined biannually for the development of sacroiliitis. Computed tomography (CT) ap-

pears to be more sensitive and specific for early sacroiliitis than technetium Tc 99m scintigraphy.⁶

Reiter's Syndrome

Reiter's syndrome was initially described with urethritis, conjunctivitis and arthritis. Acute alternating unilateral iridocyclitis may also occur as part of this syndrome. Approximately 65% of patients who have Reiter's syndrome have the HLA-B27 antigen, and in patients with uveitis, HLA-B27 is present in 97% of the cases. In addition to the uveitis and the conjunctivitis, a peripheral corneal inflammation will occasionally develop.⁷

The cause of Reiter's syndrome is unknown. Many patients give a history of a gastrointestinal or urinary tract infection. Chlamydial agents have been recovered in 20% of patients with this syndrome.⁸

Miscellaneous Syndromes Associated With Acute Anterior Uveitis

In patients with psoriatic arthritis⁹ and inflammatory bowel disease, an acute anterior iridocyclitis will occasionally develop. Often these patients will have an associated sacroiliitis and the HLA-B27 antigen.¹⁰ In patients who have ulcerative colitis, anterior uveitis usually develops in conjunction with attacks of colitis¹¹; bowel resection has been reported to eliminate ocular disease.¹² Systemic immune complexes have been described in patients during the active phase of inflamma-

TABLE 1.—Common Uveitis Syndromes

	In Children	In Adults
Anterior Uveitis		
<i>Acute</i>		
Juvenile rheumatoid arthritis	X	..
Ankylosing spondylitis	X	X
Reiter's syndrome	X
Inflammatory bowel disease	X
Herpes zoster	X
Herpes simplex	X	X
<i>Chronic</i>		
Juvenile rheumatoid arthritis	X	..
Ankylosing spondylitis	X
Reiter's syndrome	X
Syphilis	X
Sarcoidosis	X	X
Heterochromic iridocyclitis	X	X
Herpes zoster	X
Masquerade Syndromes		
Large cell lymphoma	X
Retinoblastoma	X	..
Leukemia	X	X
Melanoma	X
Posterior Uveitis		
Toxoplasmosis	X	X
Toxocariasis	X	X
Syphilitic retinitis	X
Tuberculosis	X	X
Cytomegalovirus retinitis	X	X
Candidiasis	X
Masquerade	X	X
Diffuse Uveitis		
Chronic cyclitis	X	X
Sarcoidosis	X	X
Masquerade syndrome	X	X
Behçet's disease	X	X
Vogt-Koyanagi-Harada's syndrome	X	X

TABLE 2.—Ancillary Tests in the Evaluation of Uveitis

Radiologic Tests	
Chest roentgenogram	
Sacroiliac joint roentgenogram	
Limited gallium scan	
Blood Tests	
<i>Toxocara canis</i> ELISA	
<i>Toxoplasma</i> serology	
Angiotensin-converting enzyme	
Lysozyme	
HLA typing	
VDRL and FTA-ABS	
Skin	
Purified protein derivative (PPD)	
Anergy tests for mumps, <i>Candida</i>	
Vitreous Aspiration	
Cytologic examination	
ELISA	
Culture, smear	

ELISA = enzyme-linked immunosorbent assay; HLA = human leukocyte antigen; FTA-ABS = fluorescent treponemal antibody absorption

TABLE 3.—Diagnostic Workup for Uveitis Syndromes

Uveitis Syndromes	Children	Adults
Iridocyclitis		
Erythrocyte sedimentation rate	X	X
Antinuclear antibodies	X	..
VDRL, FTA-ABS	X	X
Chest x-ray film	X
Skin tests for anergy	X
Purified protein derivative (PPD)	X
HLA-B27	X
Sacroiliac joint x-ray films	X
Retinitis and Choroiditis		
Chest x-ray film, PPD	X	X
<i>Toxoplasma</i> serology	X	X
<i>Toxocara canis</i> ELISA	X	..
Diffuse Uveitis		
Angiotensin-converting enzyme	X	X
Serum lysozyme	X	X
Limited gallium scan	X	X

FTA-ABS = fluorescent treponemal antibody absorption; ELISA = enzyme-linked immunosorbent assay

TABLE 4.—Relative Frequency of HLA-B27 in Diseases Associated With Acute Anterior Uveitis

	Positive for HLA-B27 Percent	Reference Source
Ankylosing spondylitis	95	Scharf & Zonis, 1980 ⁹ ; Russell et al, 1976 ⁸
Reiter's syndrome	65	Lancet, 1979 ⁷
Inflammatory bowel disease	65	Russell, 1977 ¹⁰
Psoriasis	65	Russell, 1977 ¹⁰

tory bowel disease and may play a role in the production of anterior uveitis.¹³ We¹⁴ and others^{15,16} have observed immune complexes both in aqueous and in the systemic circulation of patients with uveitis; however, the role of these immune complexes in the pathophysiology of ocular inflammation is not clear.

The treatment of the various types of acute anterior uveitis is relatively straightforward. Topical corticosteroids are applied hourly at first and then slowly tapered. Because significant ocular morbidity can occur with the topical administration of steroids, this therapy should always be monitored by an ophthalmologist.¹⁷ (pp50-53) Cycloplegic drops are used to prevent the development of synechiae in cases with extensive aqueous cells and cellular deposits on the pupillary margin of the iris. Rarely do patients require short-term systemic corticosteroids. Nonsteroidal anti-inflammatory agents are seldom useful in the management of uveitis.

Virally Associated Anterior Uveitis

Herpes simplex. Acute or chronic iridocyclitis can occur in association with herpetic corneal inflammation (stromal or epithelial keratitis); it is usually delayed a few days following the onset of keratitis. The anterior uveal inflammation may be quite extensive with deposition of inflammatory cells on the posterior corneal surface ("mutton-fat" keratic precipitates—Figure 1) and on the surface and pupillary border of the iris. Herpetic iridocyclitis may occur as a result either of herpes infection of the anterior uvea¹⁸ or of a hypersensitivity reaction to viral antigens, or both.¹⁹ Diagnosis is based on the distinctive pattern of corneal and anterior uveal inflammation. Treatment usually consists of topical corticosteroids and cycloplegics to avoid the development of synechiae and their sequelae. Topical antiviral agents are given in conjunction with corticosteroids to prevent exacerbations of the herpetic keratitis.

Herpes zoster. Herpes zoster ophthalmicus usually affects immunodepressed or elderly patients.²⁰ (pp9-10) Iridocyclitis does not usually occur unless there is involvement of the nasal ciliary division of the fifth cranial nerve; often vesicles are present on the tip of the nose (Hutchinson's sign). The clinical picture is diagnostic; usually the uveitis has an indolent onset and a chronic course. It may, however, have a sudden onset with severe pain due to increased intraocular pressure. Herpes zoster uveitis is usually responsive to topical corticosteroid therapy; secondary glaucoma may be difficult to control, however.²¹ Rarely, posterior segment inflammation (occlusive retinal vasculitis or cerebral vasculitis) may occur months after the onset of facial vesicles. Patients who have herpes zoster should be carefully watched by both ophthalmologists and neurologists for these late sequelae.²²

Chronic Anterior Uveitis

Juvenile Rheumatoid Arthritis

The chronic iridocyclitis associated with juvenile rheumatoid arthritis usually affects young girls who

have the pauciarticular form of the disease. Uveitis develops in 10% of patients with juvenile rheumatoid arthritis; 95% of these cases of uveitis occur in patients with pauciarticular joint involvement. Unlike with acute iridocyclitis, there is rarely discomfort, redness or photophobia associated with this form of uveitis.²³ Antinuclear antibodies are present in 82% of patients with juvenile rheumatoid arthritis who have iridocyclitis²⁴ and there is an association with HLA-DR5.²⁵ Because many of these patients who have uveitis do not have ocular symptoms, it is imperative that all patients with juvenile rheumatoid arthritis—especially those with pauciarticular joint involvement—be closely followed by an ophthalmologist to prevent the development of visually destructive sequelae. Ocular morbidity occurs as a result of glaucoma, cataracts, macular degeneration or disorganization of the globe due to inflammation (phthisis bulbi). A cataract operation in patients with juvenile rheumatoid arthritis who have uveitis has an increased incidence of complications.²⁶

About 10% of these patients who have uveitis present with ocular findings before the onset of systemic disease. There is another group of young girls who have similar ocular findings but in whom systemic manifestations of juvenile rheumatoid arthritis do not develop. This syndrome is known as "uveitis in young girls." In this group tests for antinuclear antibody and human leukocyte antigen are negative.²⁷

Syphilis

Chronic and recurrent iridocyclitis may occur in patients with secondary syphilis. Iris papules and adhesions between the iris and lens are common. Cutaneous lesions may precede or accompany iris lesions. Although iridocyclitis is resistant to topical corticosteroid therapy, it responds well to systemic penicillin.²⁸

Fuchs's Heterochromic Cyclitis

Fuchs's heterochromic cyclitis is a syndrome characterized by the insidious onset of a smoldering iritis and ciliary body inflammation that results in heterochromia, often with the secondary development of glaucoma and cataract formation.²⁹ The cause is unknown. The diagnosis is based solely on the clinical appearance of diffuse, small keratic precipitates and a unilateral lightly colored iris, with relatively mild inflammation and the absence of synechiae. Histologic studies show iris atrophy with plasma cell infiltration of the iris. Most patients have a self-limited course of inflammation and do not require ocular therapy unless glaucoma develops. Cataracts, which eventually develop in almost 70% of patients, are amenable to standard surgical removal.³⁰

Posterior Uveitis

Toxoplasmosis

Toxoplasmosis accounts for about 25% of cases of posterior uveitis. Necrotizing retinochoroiditis occurs as a direct result of invasion of the host cells by the parasite *Toxoplasma gondii*. The human infection is acquired by the ingestion of raw or undercooked meats

UVEITIS

from contaminated food sources. Almost all cases of ocular toxoplasmosis occur from primary or reactivated congenital infection. Infection is transplacentally acquired; mothers who have *Toxoplasma* antibody titers before pregnancy will not transmit the disease to their children. Pregnant women who acquire toxoplasmosis during the first trimester will often have infected children.³¹

Patients present with either vitreous floaters or blurred vision. Localized vitreous opacities occur directly over retinal lesions, which appear as yellowish white fuzzy infiltrates (Figure 9). Inactive chorioretinal scars have a characteristic appearance (Figure 10). Occasionally, an anterior "spillover" uveitis occurs due to a hypersensitivity reaction. *Toxoplasma* organisms have not been found in the human anterior uveal tract.³²

Serologic tests to detect antibodies to *T gondii* antigens are helpful in establishing a diagnosis. While commercial laboratories usually report only titers greater than 1:16, we have encountered histologically documented cases of toxoplasmosis uveitis in which the serum antibody was positive only at 1:1.³³ Repeat anti-

body titers are not useful in following disease activity. Once a patient has a positive titer for toxoplasmosis antibodies, changes do not correlate with disease activity.

Many lesions of toxoplasmic retinochoroiditis are self-limited. If a lesion occurs near the visually vital structures (optic nerve, papillomacular bundle or the macula) treatment should be started. Multidrug therapy (pyrimethamine, sulfonamides, clindamycin, folate and oral steroids) in various combinations and dosages is effective.³⁴⁻³⁷

Cytomegalovirus Uveitis

Cytomegalovirus uveitis occurs either as a congenital infection or as an acquired infection in immunosuppressed patients.³⁸ Congenital cytomegalovirus ocular disease is characterized by bilateral chorioretinitis, cataracts and associated systemic findings. This pattern of ocular findings is almost diagnostic. Acquired cytomegalovirus chorioretinitis has become more common since the advent of cytotoxic agents.

The appearance of the fundus in cytomegalovirus retinitis is characterized by yellowish white areas of retinal necrosis, with hemorrhages, vascular sheathing and vessel occlusion (Figure 11). Retinal infiltrates regress in organ-transplant patients when immunosuppressive therapy is discontinued.³⁹ All patients receiving high doses of cytotoxic agents should have frequent fundus examinations. A diagnosis of cytomegalovirus uveitis can be made on the basis of the clinical appearance, urine cultures and serial serum complement fixing antibodies. The presence of Roth's spots in a healthy appearing homosexual man suggests the possibility of acquired immune deficiency syndrome (AIDS) associated with cytomegalovirus uveitis. Many patients with AIDS have an atypical cytomegalovirus chorioretinitis.^{40,41}

Syphilis

Syphilis is very rarely a cause of uveitis. Bilateral posterior segment inflammation can occur in cases of

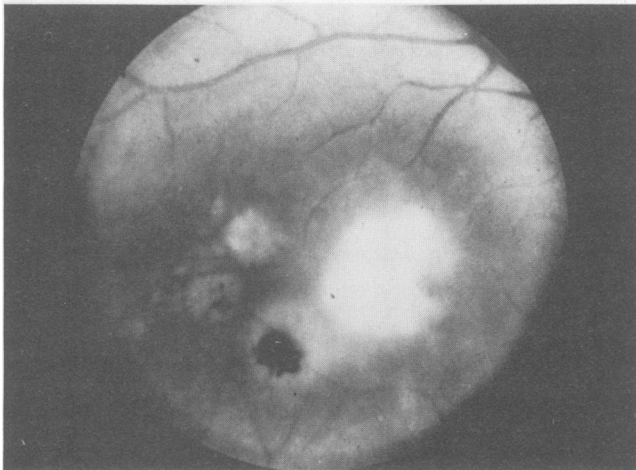


Figure 9.—Toxoplasmosis: there is active retinitis (white area) around an old scar (dark, pigmented area).

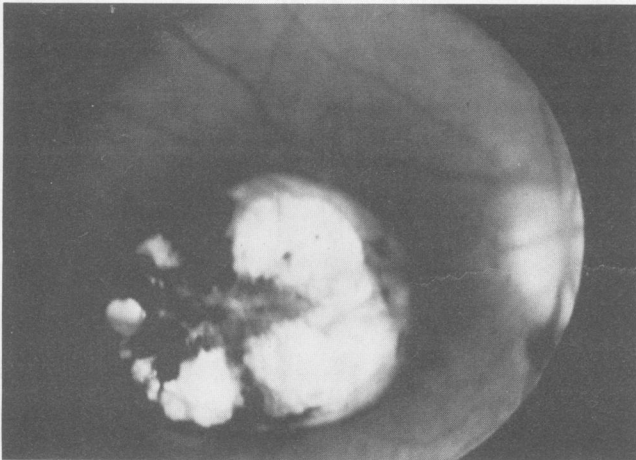


Figure 10.—Toxoplasmosis: the eye shows an inactive macular lesion.

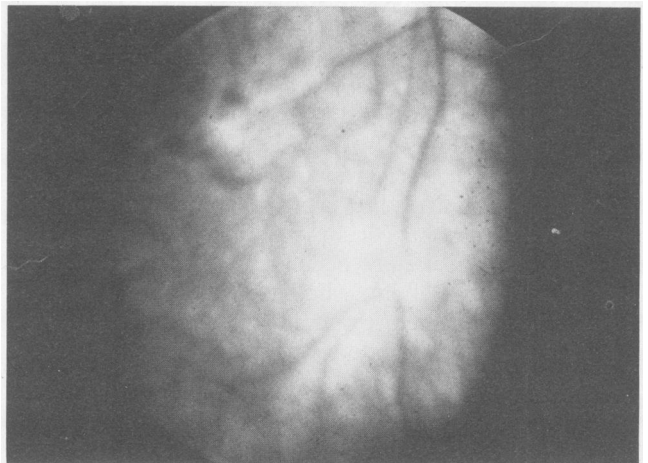


Figure 11.—Photograph shows the fundus of an eye involved with cytomegalovirus retinitis.

secondary or tertiary lues. In secondary syphilis, posterior segment disease presents with vitreous cells, flame-shaped retinal hemorrhages and a retinal vasculitis. In tertiary lues, a pseudoretinitis pigmentosa may occur (Figure 12). All patients have a positive fluorescent treponemal test for antibody absorption.⁴²

Tuberculosis

Tuberculous uveitis is extremely rare in well-nourished Americans, though it was previously thought to be a common cause of uveitis.⁴³ Almost all patients with tuberculous uveitis we have examined have been malnourished immigrants who have a hematogenous disease. Tuberculous uveitis may present in many forms: granulomatous iritis, necrotizing retinochoroiditis, miliary choroiditis, choroidal pseudotumor or a subacute endophthalmitis. In malnourished or immunosuppressed patients, the possibility of tuberculosis should be considered and a standard tuberculosis workup should be instituted.⁴⁴

Candidiasis

Ocular candidiasis has become more frequent with the widespread use of immunosuppressive agents, indwelling catheters and hyperalimentation and the increased prevalence of intravenous drug abuse.⁴⁵ Patients have necrotizing retinitis characterized by yellowish white retinal lesions with "fluffy" borders (Figure 13). Initial lesions are at the retinal surface; vitreous involvement and endophthalmitis develop rapidly. Vitreous organization and traction retinal detachments are common. Diagnosis is established by smear and cultures from a vitreous biopsy. Many patients require subtotal vitrectomy.⁴⁶ Antifungal agents are delivered by perocular, intravitreal and intravenous routes.^{47,48}

Acquired Immune Deficiency Syndrome

Since 1981 a new syndrome of acquired immunodeficiency has been reported predominantly in homosexual men, Haitian immigrants, patients receiving plasma concentrate transfusions from homosexual men

and female drug addicts and prostitutes. Patients have anergy and lymphopenia with alterations in the normal T-cell suppressor-helper populations. The pathogenesis of AIDS is unclear.⁴⁹⁻⁵¹ Ocular findings are common.⁵² The possibility of AIDS should be considered in a young homosexual man who has cotton-wool spots (Figure 14).⁵³ Histologic studies have shown that ocular inflammation occurs as a result of cytomegalovirus or *Pneumocystis carinii* infection.⁵⁴ Current treatment is of limited efficacy.

Diffuse Uveitis

Chronic Cyclitis

Chronic cyclitis (intermediate uveitis, peripheral uveitis or pars planitis) is the most common form of diffuse uveitis in young adults. It accounts for approximately 10% of uveitis cases. Laboratory tests are not indicated; the diagnosis is based on history and clinical findings. The disease usually develops in adolescents and young adults. It has an insidious, painless onset with vitreous floaters and blurred vision in a white, noninflamed eye. In 80% of cases, both eyes are

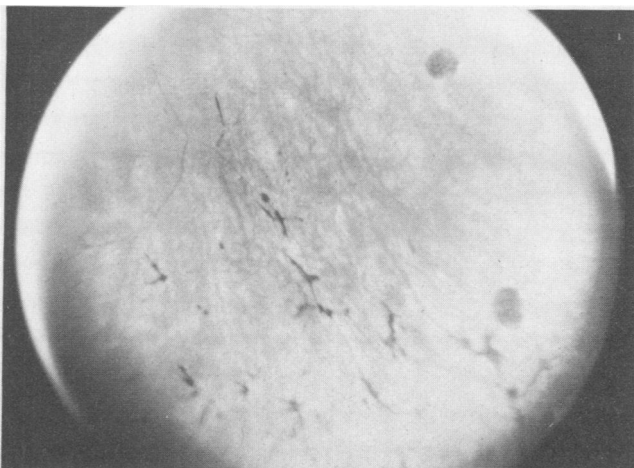


Figure 12.—"Bone spicule" formation is seen in a case of pseudoretinitis pigmentosa.

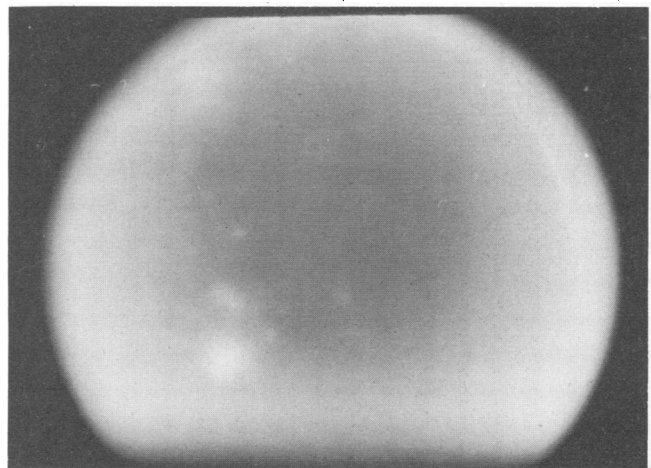


Figure 13.—*Candida* endophthalmitis: the eye shows vitreous opacities and cloudy vitreous.

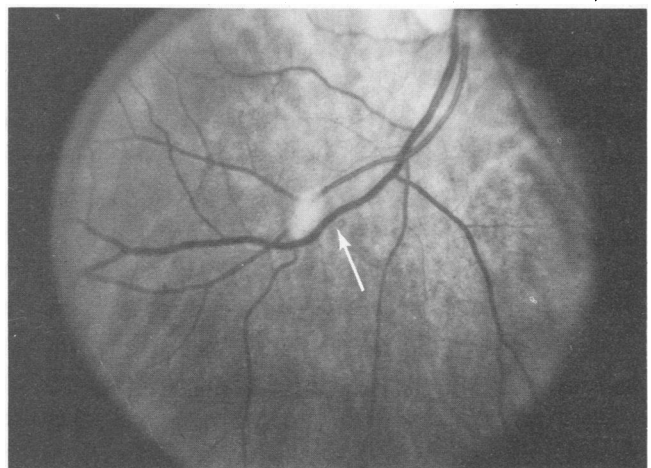


Figure 14.—A cotton-wool spot (arrow) obscures a retinal vessel in a patient with AIDS.

UVEITIS

affected. Patients do not have ocular pain and the eyes are white. Slit-lamp examination shows little or no anterior segment inflammation. Vitreous cells are present and with the progression of the disease, vitreous opacities coalesce and form "snowbanks" on the inferior ora serrata.⁵⁵

The prognosis in chronic cyclitis is generally favorable. It is a chronic disease with remissions and exacerbations. More than 80% of patients will retain a visual acuity of better than 20/40. If visually threatening complications (macular edema, cataract, retinal neovascularization) develop, therapeutic intervention with steroids, cryotherapy or vitrectomy is indicated.⁵⁶

Toxocariasis

Ocular toxocariasis has three ophthalmic presentations. It may occur as chronic, unilateral and diffuse endophthalmitis, a localized granuloma in the macula or peripapillary region or as unilateral chronic cyclitis. The disease is produced by the ingestion of *Toxocara* ova. These in turn produce larvae in the human intestine that invade the eye. Histologic sections of involved eyes

show *Toxocara* larvae. In very young children the disease usually presents as endophthalmitis, whereas in older children or teenagers it is more commonly seen as an isolated granuloma or unilateral chronic cyclitis. In nonendemic areas an enzyme-linked immunosorption assay for antigen has a sensitivity and specificity of about 90%.⁵⁷ Unlike those with visceral larva migrans, children with ocular toxocariasis usually do not have systemic eosinophilia. Treatment with antiparasitic drugs, such as thiabendazole, has not been effective.⁵⁸ Patients usually do well with the periocular administration of steroids, which, together with vitrectomy, are used in advanced cases with ocular complications.⁵⁹

Sarcoidosis

Sarcoidosis, a frequent cause of uveitis, is a multi-system granulomatous disease of unknown cause. As many as 25% of patients with sarcoidosis have ocular inflammatory disease. Sarcoid uveitis occurs 10 to 15 times more frequently in black patients, and female patients outnumber male patients two to one. It can occur at any age, though in most patients ocular inflammation develops between the ages of 20 and 50.⁶⁰

Ocular sarcoid can involve both anterior and posterior segments of the eye. Most patients present with anterior uveitis. Rarely, isolated posterior uveitis, optic nerve inflammation or orbital disease may occur. Many patients have conjunctival granulomas (Figure 15); histologically these have the classical appearance of noncaseating granulomas. Blind conjunctival biopsy has a low diagnostic yield, but biopsy of a conjunctival granuloma is diagnostic in more than 95% of cases.⁶¹ Patients who have sarcoid uveitis often have a granulomatous presentation with "mutton-fat" keratic precipitates (Figure 1), iris nodules, synechiae formation and both anterior chamber (aqueous) and vitreous inflammatory cells. Secondary glaucoma may be present. Posterior segment involvement occurs with large confluent cellular vitreous opacities, optic nerve inflammation (papillitis), retinal vasculitis ("candle wax drip-

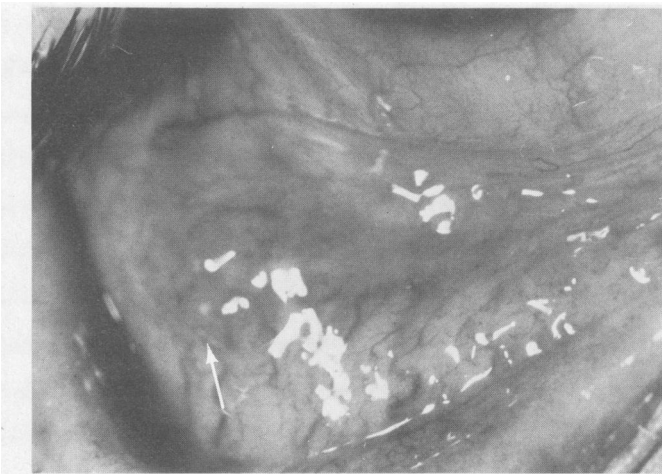


Figure 15.—A case of ocular sarcoid shows a conjunctival nodule (arrow).

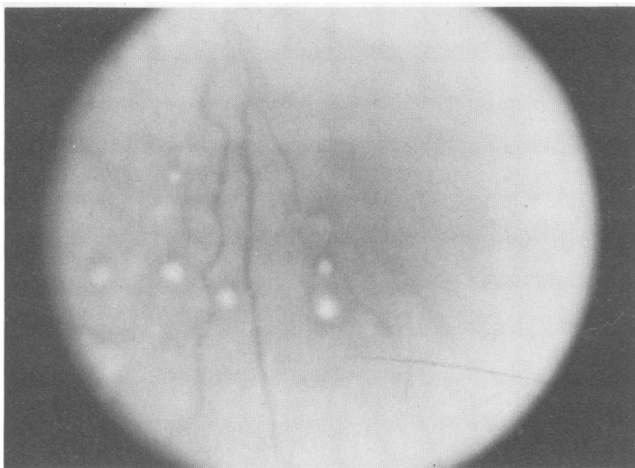


Figure 16.—An eye involved with sarcoid uveitis shows choroidal granulomas.

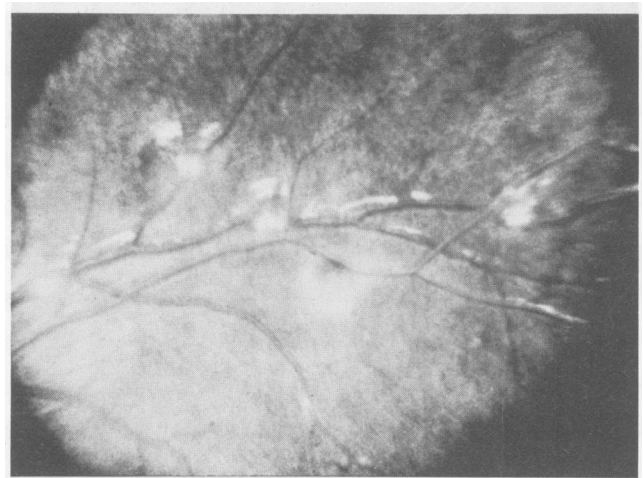


Figure 17.—A case of sarcoid uveitis showing retinal vasculitis ("candle wax drippings").

pings") and both retinal and choroidal granulomas (Figures 16, 17).

The evaluation of a possible case of sarcoid uveitis includes a standard chest roentgenogram,⁶² serum lysozyme determination,⁶³ angiotensin-converting enzyme levels^{64,65} and a limited gallium scan.^{66,67} These tests are not diagnostic of sarcoid, but they are helpful in patients who present with ocular findings before the development of systemic signs of disease.

Vigorous therapy with the topical administration of corticosteroids and cycloplegics should be initiated to prevent ocular complications as sequelae to anterior segment inflammation. Posterior segment inflammation may require periocular injections of steroids, which cause less morbidity than systemic steroid administration.⁶⁸ Tear substitutes may be necessary if the lacrimal gland is involved.

Behçet's Syndrome

Behçet's syndrome is a multisystem disease first described with a triad of recurrent oral and genital ulcers and ocular inflammation. Behçet's syndrome occurs most commonly in young men between 20 and 30 years of age who are from the eastern Mediterranean basin or Japan. Ocular findings include diffuse uveitis, often with the characteristic development of a hypopyon (leukocytes layered out in the aqueous) (Figure 18), vitreous cells and an occlusive retinal vasculitis that is characteristic of this disease. Optic nerve inflammation and macular edema are often present.⁶⁹⁻⁷¹

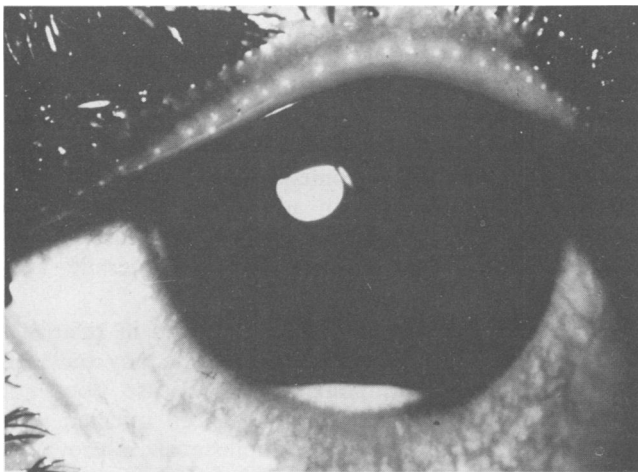


Figure 18.—In Behçet's syndrome a hypopyon (leukocytes layered in aqueous humor) may occur.

TABLE 5.—Classification of Behçet's Syndrome

Major Sites	Minor Sites
Oral ulcers	Arthritis
Genital ulcers	Neurologic lesions
Ocular lesions	Vascular lesions
Skin lesions	Intestinal lesions
	Cardiovascular lesions
	Family history

Adapted from Lehner and Barnes.⁶⁹

Most clinicians accept three major and two minor manifestations as diagnostic of Behçet's syndrome (Table 5).⁶⁹ Oral and genital ulcers are rather typical in appearance and have a prominent scarring pattern that is different from that seen with oral aphthae.⁷² In Asian and Mediterranean patients there is a strong association with HLA-B5^{73,74}; the split antigen HLA-Bw51 probably is in linkage disequilibrium with factors important in the pathophysiology of this disease.⁷⁵

A number of investigators have found immunologic alterations in cases of Behçet's syndrome. Circulating immune complexes are found in most patients with this syndrome.^{76,77} A dramatic decrease in serum complement levels has been reported in patients immediately before the onset of uveitis.⁷⁸ Immunofluorescent studies have shown the deposition of immunoglobulins and complement in vessel walls.⁷⁹ In some patients with Behçet's uveitis, injection of saline under the skin gives a typical acute wheal-and-flare reaction.⁶⁹

The ocular prognosis in cases of Behçet's syndrome is poor. Even though anterior segment inflammation responds well to topical application of corticosteroids, occlusive retinal vasculitis and other posterior inflammatory processes are relatively resistant to treatment with either steroids or cytotoxic agents. Most patients are initially given periocular or oral steroids and later a combination of cytotoxic treatment and steroids is used.^{80,81}

Vogt-Koyanagi-Harada's Syndrome

Vogt-Koyanagi-Harada's syndrome is a diffuse bilateral chronic uveitis associated with systemic and neurologic findings that include alopecia, poliosis (eyelash whitening), vitiligo, dysacusis and meningeal irritation. This uveitis syndrome occurs most commonly in patients of American Indian or Asian extraction. Patients usually have either diffuse uveitis or inflammatory serous retinal detachments. Often there is a prodrome of a mild viral illness with headache, meningeal signs and myalgia. Pleocytosis is seen in a cerebrospinal fluid specimen obtained during the acute phase of the disease.⁸²

Patients have either granulomatous or nongranulomatous anterior segment inflammation. Usually iris nodules and synechiae are present. Vitreous cells, exudative retinal detachments and optic nerve inflammation are observed (Figure 19). In many patients alopecia, poliosis and vitiligo develop after a delay of six weeks to four months.

The cause of this syndrome is unknown. There appears to be an HLA-disease association in Japanese patients but not in Americans.⁸³ All Japanese patients had positive tests for HLA-D series antigen MT3, which is not yet a workshop antigen. HLA studies may be helpful in establishing a diagnosis in Japanese patients, but in American patients the diagnosis is based on clinical findings.⁸⁴⁻⁸⁶

Masquerade Syndromes

Masquerade syndromes are primary and metastatic intraocular tumors that can mimic uveitis. In children,

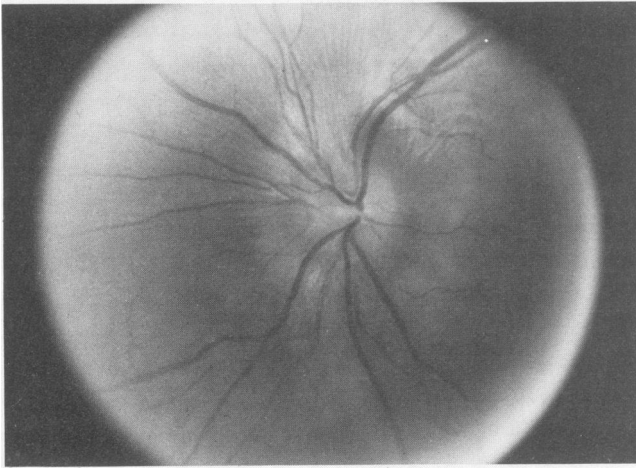


Figure 19.—Vogt-Koyanagi-Harada's syndrome: the eye shows papilledema.

retinoblastoma and leukemia are the most common entities that can simulate uveitis. In adults, the two most common causes of masquerade syndrome are intraocular large cell lymphoma and primary choroidal melanoma.

Adult Masquerade Syndromes

Ocular reticulum cell sarcoma. Ocular reticulum cell sarcoma is a common term in the ophthalmic literature. Recent studies using monoclonal antibodies directed at lymphocyte surface markers have shown that these patients have an intraocular large cell lymphoma, usually derived from malignant B-lymphocytes.⁸⁷ The development of diffuse uveitis is unusual in patients older than age 50 years, and "bilateral diffuse uveitis" in these patients should suggest the possibility of malignancy. Ocular disease can develop before, simultaneous with or after the development of central nervous system involvement. Patients have diffuse uveal, retinal and vitreal involvement by malignant lymphocytes.⁸⁸⁻⁹⁰ Yellowish white chorioretinal infiltrates have a pathognomonic appearance. Vitreous aspirate shows malignant leukocytes. The diagnostic evaluation should include CT scan of the head using contrast material and cerebrospinal fluid cytologic studies. In more than 80% of patients with intraocular large cell lymphoma, disease develops in the central nervous system. Early results using ocular and central nervous system irradiation in addition to chemotherapy appear promising.⁹¹

Choroidal melanoma. A large necrotic choroidal melanoma may simulate intraocular inflammation. A malignant choroidal melanoma should be ruled out in any adult with unilateral inflammation, glaucoma and cataract of unexplained cause. Several studies have shown that melanoma is unsuspected at the time of enucleation in as many as 10% of cases in which there are opaque media, unilateral cataract and glaucoma.⁹² Diagnostic tests helpful in the evaluation of such cases include immersion B-scan ultrasonography and quantitative echography. Much less commonly, a metastatic tumor (usually primary in breast or lung) to the choroid

can simulate uveitis. The pattern of these neoplasms on ultrasonographic examination is also characteristic and usually diagnostic.⁹³

Masquerade Syndromes in Children

Retinoblastoma. Retinoblastoma is the most common intraocular malignancy of childhood. It usually occurs in children younger than 3 years of age and has an incidence of about 1:14,000 live births. Patients with large retinoblastoma usually have a white pupil (leukokoria). Occasionally tumor may involve the anterior segment of the eye and produce a pseudohypopyon with glaucoma. Almost all these patients will have a large posterior segment retinoblastoma and careful evaluation by an ophthalmologist with ancillary tests, including ultrasound and CT studies, will establish the correct diagnosis.^{93,94}

Leukemia. Some children will present with ocular involvement before the diagnosis of systemic leukemia. Especially in children who have acute myelocytic leukemia, intraocular presentation with an endophthalmitis-like picture will initially lead parents to seek medical care. A complete blood cell count shows leukemia in almost all of these cases. Diagnostic confirmation is established by bone marrow aspiration.⁹⁵

Summary

The systemic evaluation of patients with uveitis is relatively straightforward, as outlined in Tables 2 and 3. In children, the most common causes of uveitis are juvenile rheumatoid arthritis, ankylosing spondylitis, Behçet's syndrome, sarcoidosis, toxocariasis, toxoplasmosis and chronic cyclitis. In adults with anterior uveitis, the differential diagnoses include ankylosing spondylitis, Reiter's syndrome, inflammatory bowel disease, sarcoidosis and those of infectious causes. Posterior uveitis syndromes are usually due to toxoplasmosis, syphilis, cytomegalovirus and *Candida*. Diffuse forms of uveitis in adults are usually due to chronic cyclitis, sarcoidosis, Behçet's disease, Vogt-Koyanagi-Harada's syndrome and masquerade syndromes.

It is unclear why eye disease develops in relatively few patients with systemic diseases that may have an associated ocular component. Eye disease does not develop in most people who have been infected with syphilis. Although systemic toxoplasmosis is prevalent in the general population, in only a few patients do ocular lesions develop. Immune mechanisms probably play a major role in determining which patients with a systemic disease will have eye involvement. It is likely that a number of the uveitis syndromes for which there is a strong HLA-disease association (Vogt-Koyanagi-Harada's syndrome, ankylosing spondylitis, Behçet's syndrome and Reiter's syndrome) may be due to inherited genetic factors that control the expression of HLA antigens, immune responses and, possibly, responses to endogenous inflammatory mediators.

While immunologic alterations have been observed in cases of human uveitis, the biologic importance re-

quires further elucidation. Among the issues that need further clarifying are the following:

- What is the role of genetic factors in the development of uveitis?
- If alterations in immunologic status are important in the development of uveitis, what are the events responsible for the loss of the normal tolerance toward the appropriate antigens?
- What are the nature and cause of the alterations in the immunoregulatory network of patients with uveitis?
- What ocular antigens are important in the development of immunologically mediated uveitis?

Although the treatment of uveitis syndromes usually consists of cycloplegics and the topical or periocular administration of corticosteroids, these should not be used without proper supervision by an ophthalmologist. Uveitis syndromes have serious sequelae such as synechiae formation, cataracts, macular edema, optic nerve edema with loss of vision and loss of the eye. However, treatment must be administered carefully because of well-known side effects of corticosteroids in the eye, including cataracts and secondary glaucoma with permanent damage to the optic nerve.

REFERENCES

1. Char DH, Schlaegel TF Jr: General factors in uveitis, chap 39, *In* Duane TD (Ed): *Clinical Ophthalmology*—Vol 4. Philadelphia, Harper & Row, 1982, pp 1-7
2. Hogan MJ, Kimura SJ, Thygeson P: Signs and symptoms of uveitis—I. Anterior uveitis. *Am J Ophthalmol* 1959 May; 47:155-176
3. Scharf Y, Zonis S: Histocompatibility antigens (HLA) and uveitis. *Surv Ophthalmol* 1980 Jan-Feb; 24:220-228
4. Druery C, Bashir H, Geczy AF, et al: Search for Klebsiella cell wall components cross-reactive with lymphocytes of B27+ AS+ individuals. *Hum Immunol* 1980 Sep; 1:151-160
5. Edmonds J, Macauley D, Tyndall A, et al: Lymphocytotoxicity of anti-Klebsiella antisera in ankylosing spondylitis and related arthropathies: Patient and family studies. *Arthritis Rheum* 1981 Jan; 24:1-7
6. Russell AS, Lentle BC, Tercy JS, et al: Scintigraphy of sacroiliac joints in acute anterior uveitis. *Ann Intern Med* 1976 Nov; 85:606-608
7. Reiter's syndrome (Editorial). *Lancet* 1979 Sep 15; 2:567
8. Dawson CR, Schachter J, Ostler HB, et al: Inclusion conjunctivitis and Reiter's syndrome in a married couple—Chlamydia infections in a series of both diseases. *Arch Ophthalmol* 1970 Mar; 83:300-306
9. Laurent MR, Panayi GS, Shepherd P: Circulating immune complexes, serum immunoglobulins and acute phase proteins in psoriasis and psoriatic arthritis. *Ann Rheum Dis* 1981 Feb; 40:66-69
10. Russell AS: Arthritis, inflammatory bowel disease and histocompatibility antigens. *Ann Intern Med* 1977 Jun; 86:820-821
11. Macoul KL: Ocular changes in granulomatous ileocolitis. *Arch Ophthalmol* 1970 Jul; 84:95-97
12. Korelitz BI, Coles RS: Uveitis (iritis) associated with ulcerative and granulomatous colitis. *Gastroenterology* 1967 Jan; 52:78-82
13. Lawley TJ, Ames SP, Jones EA: Circulating immune complexes: Their detection and potential significance in some hepatobiliary and intestinal diseases. *Gastroenterology* 1980 Mar; 78:626-641
14. Char DH, Stein P, Masi R, et al: Immune complexes in uveitis. *Am J Ophthalmol* 1979 May; 87:678-681
15. Dernouchamps JP, Vaerman JP, Michiels J, et al: Immune complexes in the aqueous humor and serum. *Am J Ophthalmol* 1977 Jul; 84:24-31
16. Andrews BS, McIntosh J, Petts V, et al: Circulating immune complexes in acute uveitis: A possible association with the histocompatibility complex locus antigen B27. *Int Arch Allergy Appl Immunol* 1979; 58:313-321
17. Smith RE, Nozik RM: *Uveitis: A Clinical Approach to Diagnosis and Management*. Baltimore, Williams & Wilkins, 1983
18. Oh JO: Primary and secondary herpes simplex uveitis in rabbits. *Surv Ophthalmol* 1976 Sep/Oct; 21:178-184
19. Sundmacher R, Neumann-Haefelin D: Herpes simplex virus positive and negative keratouveitis. *In* Silverstein AM, O'Connor GR (Eds): *Immunology and Immunopathology of the Eye*. New York, Masson, 1979, pp 225-229
20. Schlaegel TF: Uveitis associated with viral infections, chap 46, *In* Duane TD (Ed): *Clinical Ophthalmology*—Vol 4. Philadelphia, Harper & Row
21. Womack LW, Liesegang TJ: Complications of herpes zoster ophthalmicus. *Arch Ophthalmol* 1983; 101:42-45
22. Gilbert GJ: Herpes zoster ophthalmicus and delayed contralateral hemiparesis. *JAMA* 1974 Jul; 229:302-304

23. Kanski JJ: Anterior uveitis in juvenile rheumatoid arthritis. *Arch Ophthalmol* 1977; 95:794-797
24. Schaller JG, Johnson CJ, Ansell BM, et al: Antinuclear antibody (ANA) in patients with iridocyclitis and juvenile rheumatoid arthritis (JRA, Still's disease). *Arthritis Rheum* 1973; 16:130-131
25. Suci-Foca N, Jacobs J, Godfrey M, et al: HLA-DR5 in juvenile rheumatoid arthritis confined to few joints (Letter). *Lancet* 1980 Jul 5; 2:40
26. Jaffe WS: *Cataract Surgery and Its Complications*. St Louis, CV Mosby, 1976
27. Ohno S, Char DH, Kimura SJ, et al: HLA antigens and antinuclear antibody titres in juvenile chronic iridocyclitis. *Br J Ophthalmol* 1977 Jan; 61:59-61
28. Schwartz LK, O'Connor GR: Secondary syphilis with iris papules. *Am J Ophthalmol* 1980 Sep; 90:380-384
29. Lowenfeld IE, Thompson HS: Fuchs's heterochromic cyclitis. *Surv Ophthalmol* 1973 May-Jun; 17:394-457
30. Melamed S, Lahav M, Sandbank U, et al: Fuch's heterochromic iridocyclitis: An electron microscopic study of the iris. *Invest Ophthalmol Vis Sci* 1978 Dec; 17:1193-1199
31. O'Connor GR: Endogenous uveitis: Part I, chap 3, *In* Kraus-Mackiw E, O'Connor GR (Eds): *Uveitis, Pathophysiology and Therapy*. New York, Thieme-Stratton, 1983, pp 45-116
32. O'Connor GR: The influence of hypersensitivity on the pathogenesis of ocular toxoplasmosis. *Trans Am Ophthalmol Soc* 1970; 68:501-547
33. Zscheile FP: Recurrent toxoplasmic retinitis with weakly positive methylene blue dye test. *Arch Ophthalmol* 1964 May; 71:645-648
34. O'Connor GR, Frenkel JK: Dangers of steroid treatment in toxoplasmosis—Periocular injections and systemic therapy (Editorial). *Arch Ophthalmol* 1976 Feb; 94:213
35. Tabbara KF, O'Connor GR: Treatment of ocular toxoplasmosis with clindamycin and sulfadiazine. *Ophthalmology (Rochester)* 1980 Feb; 87:129-134
36. Giles CL: Pyrimethamine (Daraprim) and the treatment of toxoplasmic uveitis. *Surv Ophthalmol* 1971 Sep-Oct; 16:88-91
37. Acers TE: Toxoplasmic retinochoroiditis: A double-blind therapeutic study. *Arch Ophthalmol* 1964 Jan; 71:58-62
38. De Venecia G, Zu Rhein GM, Pratt MV, et al: Cytomegalic inclusion retinitis in an adult. *Arch Ophthalmol* 1971 Jul; 86:44-57
39. Egbert PR, Pollard RB, Gallagher JG, et al: Cytomegalovirus retinitis in immunosuppressed hosts—II. Ocular manifestations. *Ann Intern Med* 1980 Nov; 93:664-670
40. Neuwirth J, Gutman I, Hofeldt AJ, et al: Cytomegalovirus retinitis in a young homosexual with acquired immunodeficiency. *Ophthalmology (Rochester)* 1982 Jul; 89:805-808
41. Bachman DM, Rodrigues MM, Chu F, et al: Culture proven cytomegalovirus retinitis in a homosexual man with the acquired immunodeficiency syndrome. *Ophthalmology (Rochester)* 1982 Jul; 89:797-804
42. Schlaegel TF Jr, Kao SF: A review (1970-1980) of 28 presumptive cases of syphilitic uveitis. *Am J Ophthalmol* 1982 Apr; 93:412-414
43. Abrams J, Schlaegel TF Jr: The role of the isoniazid therapeutic test in tuberculous uveitis. *Am J Ophthalmol* 1982; 94:511-515
44. Schlaegel TF Jr, O'Connor GR: Tuberculosis and syphilis (Letter). *Arch Ophthalmol* 1981 Dec; 99:2206-2207
45. Aguilar GL, Blumenkrantz MS, Egbert PR, et al: Candida endophthalmitis after intravenous drug abuse. *Arch Ophthalmol* 1979 Jan; 97:96-100
46. Griffin JR: Ocular indicator for Candida endophthalmitis. *Arch Ophthalmol* 1978 Jun; 96:1095
47. Griffin JR, Pettit TH, Fishman L: Blood borne Candida endophthalmitis. *Arch Ophthalmol* 1973 Jun; 89:450-456
48. Stone RD, Irvine AR, O'Connor GR: Candida endophthalmitis: Report of an unusual case with isolation of the etiologic agent by vitreous biopsy. *Ann Ophthalmol* 1975; 7:757-762
49. Siegal FP, Lopez C, Hammer GS, et al: Severe acquired immunodeficiency in male homosexuals manifested by chronic ulcerative perianal herpes simplex lesions. *N Engl J Med* 1981 Dec; 305:1439-1444
50. Davis KC, Horsburgh CR, Hasiba U, et al: Acquired immunodeficiency syndrome in a patient with hemophilia. *Ann Intern Med* 1983 Mar; 98:284-286
51. Gottlieb MS, Schroff R, Schanker HM, et al: Pneumocystis carinii pneumonia and mucosal candidiasis in previously healthy homosexual men: Evidence of a new acquired cellular immunodeficiency. *N Engl J Med* 1981 Dec; 305:1425-1431
52. Holland GN, Gottlieb MS, Yee RD, et al: Ocular disorders associated with a new severe acquired cellular immunodeficiency syndrome. *Am J Ophthalmol* 1982 Apr; 93:393-402
53. Kwok S, O'Donnell JJ, Wood I: Retinal cotton wool spots in a patient with Pneumocystis carinii infection. *N Engl J Med* 1982 Jul; 307:184-185
54. Holland GN, Gottlieb MS, Foos RY: Retinal cotton-wool patches in acquired immunodeficiency syndrome (Letter). *N Engl J Med* 1982 Dec; 307:1704
55. Smith RE, Godfrey WA, Kimura SJ: Chronic cyclitis—I. Course and visual prognosis. *Trans Am Acad Ophthalmol Otolaryngol* 1973 Nov-Dec; 77:760-768
56. Smith RE, Godfrey WA, Kimura SJ: Complications of chronic cyclitis. *Am J Ophthalmol* 1976 Aug; 82:277-282
57. Pollard ZF, Jarrett WH, Hagler WS: ELISA for diagnosis of ocular toxocariasis. *Ophthalmology (Rochester)* 1979 May; 86:743-752
58. Biglan AW, Glickman LT, Lobes LA: Serum and vitreous toxocara antibody titer in nematode endophthalmitis. *Am J Ophthalmol* 1979 Nov; 88:898-901
59. Belmont JB, Irvine A, Benson W, et al: Vitrectomy in ocular toxocariasis. *Arch Ophthalmol* 1982 Sep; 100:912-916
60. Obenaus CD, Shaw HE, Sydnor CF, et al: Sarcoidosis and its ophthalmic manifestations. *Am J Ophthalmol* 1978 Nov; 86:648-655

UVEITIS

61. Nichols CW, Eagle RC Jr, Yanoff M, et al: Conjunctival biopsy as an aid in the evaluation of the patient with suspected sarcoidosis. *Ophthalmology* (Rochester) 1980 Apr; 87:287-291
62. Simpson GV: Diagnosis and treatment of uveitis in association with sarcoidosis. *Trans Am Ophthalmol Soc* 1968; 66:117-140
63. Weinberg R, Tessler H: Serum lysozyme in sarcoid uveitis. *Am J Ophthalmol* 1976 Jul; 82:105-108
64. Weinreb RN, Kimura SJ: Uveitis associated with sarcoidosis and angiotensin-converting enzyme. *Am J Ophthalmol* 1980 Feb; 89:180-185
65. Studdy P, Bird R, James DG: Serum angiotensin-converting enzyme (SACE) in sarcoidosis and other granulomatous disorders. *Lancet* 1978 Dec; 2:1331-1334
66. Weinreb RN, Barth R, Kimura SJ: Limited gallium scans and angiotensin-converting enzyme in granulomatous uveitis. *Ophthalmology* (Rochester) 1980 Mar; 87:202-209
67. Nosal A, Schleissner LA, Mishkin FS, et al: Angiotensin-I-converting enzyme and gallium scan in noninvasive evaluation of sarcoidosis. *Ann Intern Med* 1979 Mar; 90:328-331
68. Schlaegel TF Jr: Nonspecific treatment of uveitis, chap 43, *In* Duane TD (Ed): *Clinical Ophthalmology—Vol 4*. Philadelphia/New York, JB Lippincott, 1980, pp 2-7
69. Lehner T, Barnes CG: Behçet's Syndrome: Clinical and Immunological Features. New York, Academic Press, 1979
70. Geraint JD, Spiteri MA: Behçet's disease. *Ophthalmology* (Rochester) 1982 Nov; 89:1279-1284
71. James DG: Behçet's syndrome. *N Engl J Med* 1979 Aug; 301:431-432
72. Aphthous immunology (Editorial). *Lancet* 1978 Aug; 2:412-413
73. Ono S, Aoki K, Sugiura S, et al: HLA-B5 and Behçet's disease (Letter). *Lancet* 1973 Dec; 2:1383-1384
74. Ersoy F, Berkel I, Firat T, et al: HLA antigens associated with Behçet's disease. *Arch Dermatol* 1977 Dec; 113:1720-1721
75. Yazici H, Chamberlain MA, Schreuder I, et al: HLA antigens in Behçet's disease: A reappraisal by a comparative study of Turkish and British patients. *Ann Rheum Dis* 1980 Aug; 39:344-348
76. Gupta RC, O'Duffy JD, McDuffie FC, et al: Circulating immune complexes in active Behçet's disease. *Clin Exp Immunol* 1978 Nov; 34:213-218
77. Levinsky RJ, Lehner T: Circulating immune complexes in recurrent oral ulceration and Behçet's syndrome. *Clin Exp Immunol* 1978 May; 32:193-198
78. Shimada K, Kogure M, Kawashima T, et al: Reduction of complement in Behçet's disease and drug allergy. *Med Biol* 1974 Aug; 52:234-239
79. Gamble CN, Wiesner KB, Shapiro RF et al: The immune complex pathogenesis of glomerulonephritis and pulmonary vasculitis in Behçet's disease. *Am J Med* 1979 Jun; 66:1031-1039
80. Miyachi Y, Taniguchi S, Ozaki M, et al: Colchicine in the treatment of the cutaneous manifestations of Behçet's disease. *Br J Dermatol* 1981 Jan; 104:67-69
81. Mamo JG, Azzam SA: Treatment of Behçet's disease with chlorambucil. *Arch Ophthalmol* 1970 Oct; 84:446-450
82. Snyder DA, Tessler HH: Vogt-Koyanagi-Harada syndrome. *Am J Ophthalmol* 1980; 90:69-73
83. Moriuchi J, Katagiri M, Wakisawa A, et al: Association of B-cell alloantigen determinant Hon-7 with Harada's disease. *Immunogenetics* 1979; 9:47-49
84. Ohno S, Char DH, Kimura SJ, et al: Vogt-Koyanagi-Harada syndrome. *Am J Ophthalmol* 1977 May; 83:735-740
85. Tagawa Y, Sugiura S, Yakura H, et al: HLA and Vogt-Koyanagi-Harada syndrome (Letter). *N Engl J Med* 1976 Jul; 295:173
86. Yakura H, Wakisaka A, Aizawa M, et al: HLA-D antigen of Japanese origin (LD-Wa) and its association with Vogt-Koyanagi-Harada syndrome. *Tissue Antigens* 1976 Jul; 8:35-42
87. Azar HA, Jaffe ES, Berard CW, et al: Diffuse large cell lymphomas (reticulum cell sarcomas, histiocytic lymphomas)—Correlation of morphologic features with functional markers. *Cancer* 1980 Sep; 46:1428-1441
88. Minckler DS, Font RL, Zimmerman LE: Uveitis and reticulum cell sarcoma of brain with bilateral neoplastic seeding of vitreous without retinal or uveal involvement. *Am J Ophthalmol* 1975 Sep; 80:433-439
89. Sullivan SF, Dallow I: Intraocular reticulum cell sarcoma: Its dramatic response to systemic chemotherapy and its angiogenic potential. *Ann Ophthalmol* 1977 Apr; 9:401-406
90. Char DH: *Immunology of Uveitis and Ocular Tumors*. New York, Grune & Stratton, 1978
91. Char DH, Margolis L, Newman AB: Ocular reticulum cell sarcoma. *Am J Ophthalmol* 1981 Apr; 91:480-483
92. Shields JA, McDonald PR, Leonard BC, et al: The diagnosis of uveal malignant melanomas in eyes with opaque media. *Am J Ophthalmol* 1977; 83:85-105
93. Coleman DJ: Reliability of ocular tumor diagnosis with ultrasound. *Trans Am Acad Ophthalmol Otolaryngol* 1973; 77:677-686
94. Coleman JT, Lizzie FL, Jack RL: *Ultrasonography of the Eye and Orbit*. Philadelphia, Lea & Febiger, 1977
95. Robb RM, Ervin LD, Sallan SE: A pathological study of eye involvement in acute leukemia of childhood. *Trans Am Ophthalmol Soc* 1978; 76:90-101