



# Subaxial Lateral Mass Prosthesis for Posterior Reconstruction of Cervical Spine

Qiang Jian<sup>1,\*</sup> Zhenlei Liu<sup>1,\*</sup> Wanru Duan<sup>1</sup> Fengzeng Jian<sup>1</sup> Zan Chen<sup>1</sup>

<sup>1</sup>Department of Neurosurgery, Xuanwu Hospital, Beijing, China

Address for correspondence Zan Chen, MD, Department of Neurosurgery, Xuanwu Hospital, Beijing, China (e-mail: chenzan66@163.com).

J Neurol Surg A Cent Eur Neurosurg 2023;84:316–320.

## Abstract

**Background** Posterior facetectomy or lateral mass resection is often used during cervical dumbbell tumor resection, jeopardizing the stability of cervical spine. The space after resection of one or more lateral masses, if left unfilled might hamper bone fusion and structural support.

**Purpose** There were the aims to obtain the relevant morphometry of the lateral mass of the subaxial cervical spine (C3–C7) and to design a lateral mass prosthesis for the posterior reconstruction of the cervical spine.

**Methods** The computed tomography (CT) scans of healthy volunteers were obtained. RadiAnt DICOM Viewer software (Version 2020.1, Medixant, Poland) was used to measure the parameters of lateral mass, such as height, anteroposterior dimension (APD), mediolateral dimension (MLD), and facet joint angle. According to the parameters, a series of cervical lateral mass prostheses were designed. Cadaver experiment was conducted to demonstrate its feasibility.

**Results** Twenty-three volunteers with an average age of  $30.1 \pm 7.1$  years were enrolled in this study. The height of the lateral mass was 14.1 mm on average. The facet joint angle, APD, and MLD of the lateral mass averaged 40.1 degrees, 11.2 mm, and 12.2 mm, respectively. With these key data, a lateral mass prosthesis consisting of a column and a posterior fixation plate was designed. The column has a 4.0-mm radius, 41-degree surface angle, and adjustable height of 13, 15, or 17 mm. In the cadaver experiment, the column could function as a supporting structure between adjacent facets, and it would not violate the exiting nerve root or the vertebral artery.

**Conclusion** This study provided a detailed morphology of the lateral mass of the subaxial cervical spine. A series of subaxial cervical lateral mass prostheses were designed awaiting further clinical application.

## Keywords

- ▶ cervical vertebral tumor
- ▶ lateral mass prosthesis
- ▶ lateral mass morphology
- ▶ posterior reconstruction
- ▶ cervical spine

## Introduction

The subaxial cervical lateral mass is located lateral to the cervical spine canal, one on each side. Two adjacent lateral masses, along with the articular cartilage, form the facet

joint.<sup>1</sup> Together with the vertebral body and cervical disks, the bilateral mass takes part in the mobility of the cervical spine and shares approximately two-thirds of the vertical load of the cervical vertebrae<sup>2</sup>. In case of hyperlordosis, high and prolonged weight loading, and disk degeneration, the percentage of vertical loading can increase<sup>1</sup>

\*Qiang Jian and Zhenlei Liu contributed equally to this study as co-first authors.

received  
September 8, 2021  
accepted after revision  
December 27, 2021  
article published online  
July 12, 2022

DOI <https://doi.org/10.1055/a-1739-2488>.  
ISSN 2193-6315.

© 2022. The Author(s).

This is an open access article published by Thieme under the terms of the Creative Commons Attribution-NonDerivative-NonCommercial-License, permitting copying and reproduction so long as the original work is given appropriate credit. Contents may not be used for commercial purposes, or adapted, remixed, transformed or built upon. (<https://creativecommons.org/licenses/by-nc-nd/4.0/>)

Georg Thieme Verlag KG, Rüdigerstraße 14, 70469 Stuttgart, Germany

Posterior facetectomy or lateral mass resection is often used during cervical dumbbell tumor resection, jeopardizing the stability of cervical spine.<sup>3,4</sup> Cervical instability can occur in as much as 20% of patients who underwent posterior surgery for cervical cord tumors.<sup>3,5</sup> Fixation with bone grafting was commonly used to re-establish stability and to reconstruct the posterior cervical spine.<sup>4,6</sup> Bone grafting bed and graft quantity are two of the key factors for bony fusion. However, the space after resection of one or more lateral masses, was left unfilled after surgery due to its vicinity to nerve root (NR), which hampers osteoconduction and structural support<sup>7</sup>. We hypothesize that with a properly designed lateral mass prosthesis, we can improve bony fusion rate and prognoses for patients. In this article, morphometry of the subaxial (C3–C7) cervical lateral mass was measured. A series of prostheses of the cervical lateral mass was designed accordingly. We also conducted a cadaver experiment to demonstrate the feasibility of these prostheses.

## Material and Methods

### Participants

Adult healthy volunteers were recruited and enrolled in this study. Written informed consent was obtained from each participant. The institutional review board of our hospital approved this study. Cervical computed tomography (CT) scan (layer thickness of 0.625 mm) was performed to exclude fractures, dislocations, tumorous lesions, infection, overt degenerative conditions, and previous surgery, which could change the morphology of the lateral mass.

### Measurement Parameters

Thin-layer CT data were loaded with RadiAnt DICOM Viewer software (Version 2020.1, Medixant, Poland). The following key parameters were measured on CT in bone mode to design a lateral mass prosthesis. The anteroposterior dimension (APD), height (→Fig. 1A), and facet joint angle (FJA; →Fig. 1B) were measured on the sagittal plane. The height is the distance between the midpoints of the superior and inferior APD of the lateral mass. The FJA is the angle between the articular surface and the line crossing the two midpoints on the sagittal plane. The mediolateral dimension (MLD) of the lateral masses was measured on the coronal plane (→Fig. 1C). Therefore, each lateral mass has 1 height, 2 APDs, 2 MLDs, and 2 FJAs.

All assessments were conducted by two authors who were double-blinded (demography of patient, measurement calculated by the other author), and each author performed the assessment twice to reduce inter- and intraobserver variations.

### Prosthetic Design

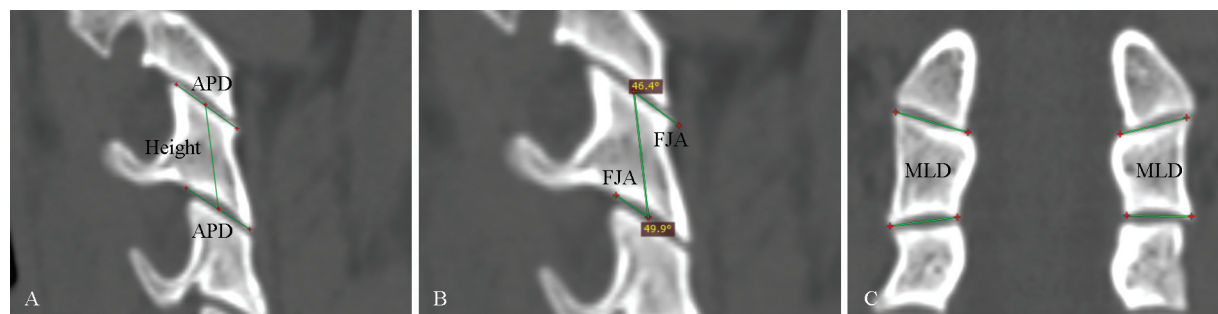
The design of the prosthesis is based on the following: the prosthesis is designed as a columnar structure with two sloping articular processes for support and is attached with a fixation device to implant screws to secure the adjacent lateral mass. The superior and inferior articular processes are approximately parallel. The parameters of the prosthesis were determined using morphological data. The insertion point of the fixation device was set near the midpoint of the dorsal cortex of the adjacent lateral mass, so half height was taken as the distance between the insertion point and the bone graft column. The radius of the columnar structure is determined by the values of half MLD and  $1/2APD \sin FJA$ . The implant is made of titanium alloy.

### Statistics

The statistical analysis was performed using SPSS 17.0 statistical software (SPSS Inc., Chicago, Illinois, United States). Considering the symmetry of the left and right sides of the same level, the parameters of both sides of each level were combined into one for analysis. In consideration of the simplified design of the prosthesis, the superior and inferior lateral mass parameters of the same level were combined for analysis. After summarizing the superior, inferior, left, and right parameters, each segment contains one MLD, APD, FJA, and height. All data were recorded as mean  $\pm$  standard deviation. The one-way analysis of variance (ANOVA) was used to compare the mean of each parameter between segments. Statistical significance was set as  $p < 0.05$ .

## Results

Twenty-three volunteers, with average age  $31.0 \pm 7.1$  years (21–45 years), were enrolled in this study, including 13 males and 10 females (→Supplementary Material). They reported no neck pain or other discomfort apparently related to cervical spine. CT scan ruled out fracture, tumor or overt degenerative diseases.



**Fig. 1** Measurement of key parameters for lateral mass prosthesis design. (A) APD, the anteroposterior dimension of facet joint surface in the sagittal plane. Height, the distance between the midpoints of the superior and inferior APD of the lateral mass. (B) Facet joint angle (FJA), the angle between the facet joint surface and the height line. (C) MLD, the mediolateral dimension of the facet joint surface in the coronal plane.

**Table 1** Key parameters for the lateral mass prosthesis design

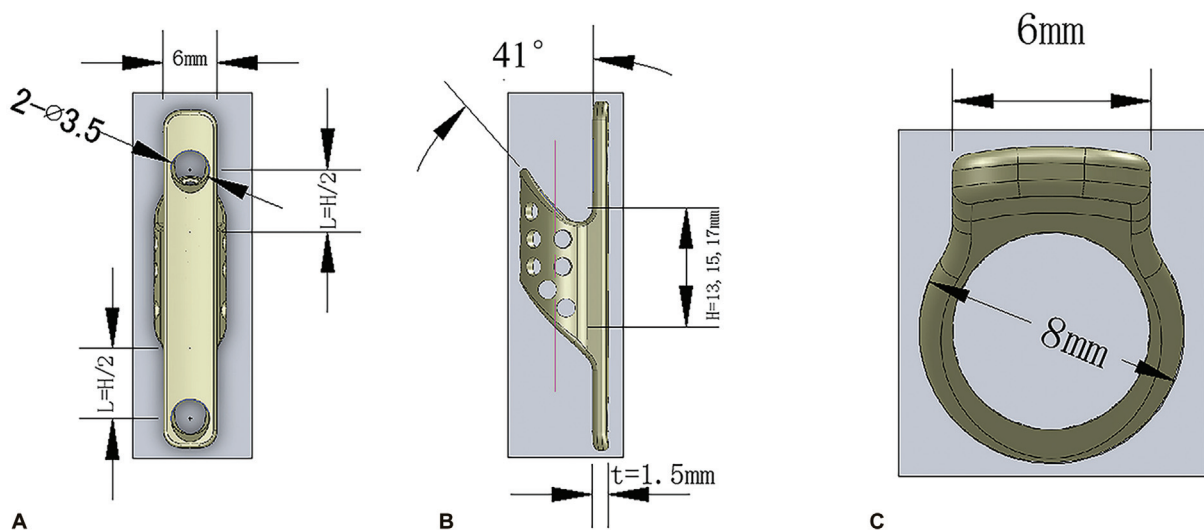
	MLD (mm) <sup>a</sup>	APD (mm) <sup>b</sup>	Height (mm) <sup>c</sup>	Angle (degrees) <sup>d</sup>
C3	11.6 ± 1.2	11.5 ± 1.7	13.3 ± 1.3	51.8 ± 9.7
C4	11.7 ± 1.3	11.6 ± 1.5	13.3 ± 1.1	43.4 ± 6.6
C5	12.0 ± 1.2	11.1 ± 1.2	13.6 ± 1.1	43.4 ± 7.4
C6	12.3 ± 1.3	10.9 ± 1.2	14.0 ± 1.4	33.6 ± 7.7
C7	13.3 ± 1.4	11.0 ± 1.5	16.4 ± 1.6	28.1 ± 8.1
Average	12.2 ± 1.4	11.2 ± 1.5	14.1 ± 1.8	40.1 ± 11.5

<sup>a</sup>MLD, the mediolateral dimension of the facet joint surface in the coronal plane.

<sup>b</sup>APD, the anteroposterior dimension of the facet joint surface in the sagittal plane.

<sup>c</sup>Height, the distance between the midpoints of the superior and inferior APD of the lateral mass.

<sup>d</sup>Facet joint angle, the angle between the facet joint surface and the height line.



**Fig. 2** Design of the lateral mass prosthesis. (A) Anteroposterior, (B) lateral, and (C) axial views of the prosthesis. Key parameters were labeled.

The morphometry of lateral mass related to prosthesis design is shown in ▶ **Table 1**. The average FJA of lateral mass is 40.1 degrees with a decreasing trend from C3 through C7 ( $C3 > C4 > C5 > C6 > C7$ ,  $p < 0.05$ ). Height and MLD of lateral mass averaged 14.1 and 12.2 mm, respectively, with an increasing trend from C3 through C7 ( $C3 < C4 < C5 < C6 < C7$ ,  $p < 0.05$ ). The APD followed the order of  $C6 < C7 < C5 < C3 < C4$  ( $p < 0.05$ ).

With the morphometry of subaxial lateral mass, we designed the following prosthesis. It consists of two parts, the column and posterior fixation plate (▶ **Fig. 2A**). The column wall is full of holes for blood infiltration, which will facilitate bone growth (▶ **Fig. 2B**). Grafting surface engaging adjacent articular processes is 41 degrees to the posterior fixation plate, which may need trimming of articular surfaces during a surgical procedure to achieve a perfect fit. The height of the column was 13, 15, and 17 mm. The external radius of grafting column is 4.0 mm (▶ **Fig. 2C**). The posterior fixation plate is 6 mm in width, 1.5 mm in thickness with two 3.5-mm holes for fixation screws.

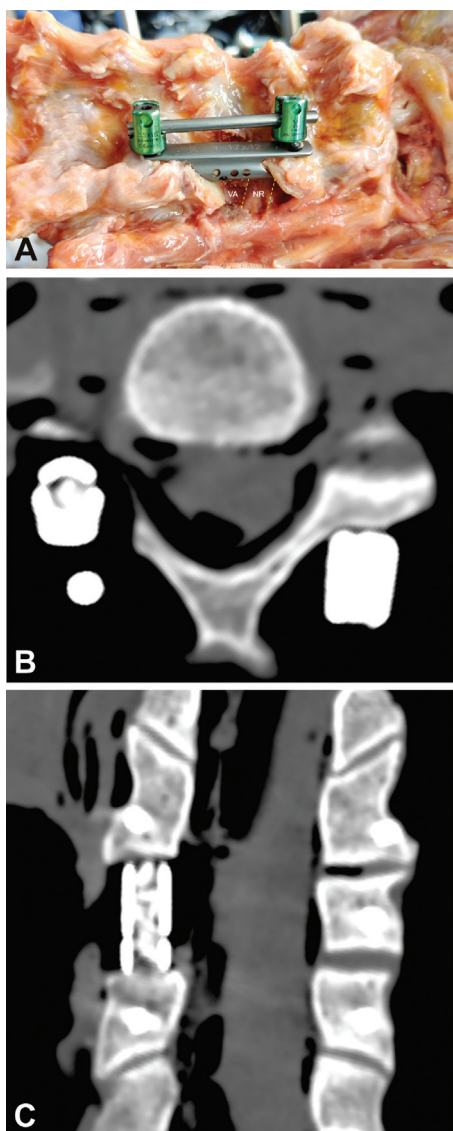
In the cadaver experiment, with the posterior plate fixed by lateral mass screws, the column functioned as a support-

ing structure fitting into the adjacent facets, and it did not violate the exiting NR or vertebral artery (VA; ▶ **Fig. 3A-C**).

## Discussion

Posterior surgical resection of cervical vertebral tumor or intra-/extraspinal communicating tumor is a common treatment modality in orthopaedics and neurosurgery. These procedures often involve resection of lateral masses with the risk of cervical spine instability,<sup>3-5</sup> which deteriorates with the extent of resection.<sup>8</sup> Several studies have shown that facet joints play an important role in maintaining stability of the cervical spine. When foraminotomy was performed by resecting more than 50% of the facet joint, the stability is significantly impaired.<sup>8-11</sup> However, the space between adjacent lateral masses after resection of one or more lateral masses was usually left unfilled during posterior screw and rod reconstruction.

Although the widespread use of internal fixation has ensured spinal stability at once, arthrodesis is still necessary to achieve long-term stability. The fusion site of intervertebral fusion is located in the load-bearing area of the vertebra,



**Fig. 3** The application of a lateral mass prosthesis. (A) There is no compression of the vertebral artery (VA) or the nerve root (NR). (B,C) Computed tomography (CT) of the prosthesis in the axial and coronal planes.

so the fusion rate was higher and the hardware mechanical complications were lower than in posterolateral fusion.<sup>12,13</sup> Hence, we aim to take advantage of the vacant space to perform interfacet fusion.

According to Wolff's law, the interfacet space should be a better choice for placing a bone graft than the posterolateral bone surface. Ji et al reconstructed the lateral mass in a patient with a strip allograft and achieved fusion.<sup>14</sup> However, there is a risk of immune response to allogeneic bone. In addition, the displacement of the strip bone graft along the slanted facet is another potential risk. Clarke et al reconstructed the lateral mass using titanium cage and fibula in seven patients. To prevent the caudal end of the cage from shifting along the articular surface, a screw was needed to secure the contact area between the cage and the facet, and another screw was used to connect the cage and a posterior rod. At the same time, to prevent the cephalic end of the cage

from shifting, the cephalic end of the titanium cage needs to be made into a hook to hold the facet. Still, postoperative hardware failure occurred in two patients.<sup>15</sup> Intraoperative cage shaping is very important for screw fixation and postoperative stability, thus increasing the operation time and difficulty.

In addition, the lateral mass is adjacent to the VA and the exiting NR, and there is a risk of nerve and artery lesion. A proper lateral mass prosthesis can function as a container for granular bone to improve bone grafting and bony fusion rate.

Previous studies focused on efficacy and safety of screw insertion.<sup>16–20</sup> No lateral mass prosthesis was designed to reconstruct the posterior column of the cervical spine after facet resection. Furthermore, the definitions of the morphological parameters of the lateral mass vary in previous studies. Therefore, we used a new method to measure the subaxial lateral mass with the aims of the simplification of its morphology and designing a prosthesis. The results showed that MLD and height increased, and FJA decreased gradually from C3 to C7, indicating that the lateral mass gradually became wide, tall, and steep from C3 to C7. Although the measurement method in this study was different from those conducted by Patil et al and Abdullah et al, the changes from C3 to C7 are similar with theirs.<sup>18,21</sup> We found that the overall morphology of subaxial lateral masses is quite uniform. Thus, one set of prostheses could meet the need of the majority of the patients in clinical practice. For example, the superior and inferior articular surfaces of the lateral mass are approximately parallel in the sagittal plane, simplifying the design of the prosthesis. However, this does not go for everyone. FJA varies at different levels. Fortunately, we can adapt the angle of the articular processes so that the prosthesis fits well. That step removes the bone cortex and makes a good bone graft bed improving fusion.

One of the most important aspects of new hardware devices is safety and efficacy. The diameter of the column not only affects the amount of bone used for filling and the contact area with the upper and lower bony structures but is also a vital parameter to prevent spinal canal, NR, and VA violation. The anteromedial side of the lateral mass forms the outer wall of the intervertebral foramen through which the NR passes. Anterior to the lateral mass is the transverse foramen of the VA. To measure the distance between the dorsal bone surface of the lateral mass and the VA or NR would be most accurate, but the VA is tortuous, and CT cannot display the NR. Thus, the distance between the center of the dorsal bone surface and VA was not used for defining the APD. Nonetheless, measurement of the dimension of the bony structure of the lateral mass should allow to develop an implant which reconstructs the lateral mass structure without encroachment on the VA and NR. To ensure that the common lateral mass screws can be successfully implanted, we designed the plate to be thin enough (1.5 mm) without affecting the screw trajectory.

The core of the column has a volume of 0.75-mL (4-mm radius and 15-mm height column), which is almost twice the volume of a typical cage for anterior cervical discectomy and



fusion (ACDF; ~0.4 mL as per the design of the ACDF cages). Further, the surface of the implant engages the bone surface of adjacent lateral masses, providing structural support for the posterior column and thereby promoting stability, osteoconduction and bone formation.<sup>7,22</sup> Plenty of holes on the column wall facilitate blood infiltration into the bone-filled core of the implant, stimulating bony fusion.

The most important parameter is the height of the prosthesis, because a proper height together with facetoplasty provides strong support and thus achieves good osteoconduction. Therefore, the series of prostheses are designed in different heights to meet the clinical needs of a specific patient.

We also conducted a cadaveric study to demonstrate the feasibility of the prosthesis fixed with a commonly used lateral mass screws. The prosthesis can fully fit into the lateral mass space and play a supporting role in the posterior column without compression of the VA or NR. What is more, it makes full use of the space between lateral masses for bone grafting.

Limitations of our study include the following: (1) We enrolled only adult Chinese participants. This prosthesis may be not suitable for children or other ethnicities. (2) We do notice the chirality of bilateral lateral masses. The orientation of the articular surface of the facet joint is angular in the coronal, sagittal, and axial planes.<sup>20</sup> Incorporating this in the prosthesis design will dramatically increase the complexity and manufacturing costs. Therefore, we measured the FJA only in the sagittal plane. For practicality, we designed that the column is just anterior to the fixation plate. With a 4-mm radius, the column will not impinge the NR. (3) Clinical applications are underway to demonstrate its safety and efficacy.

## Conclusion

This study provided a detailed morphology of the lateral mass of the subaxial cervical spine. A series of subaxial cervical lateral mass prostheses were designed awaiting further clinical application.

### Conflict of Interest

None declared.

## References

- Izzo R, Guarnieri G, Guglielmi G, Muto M. Biomechanics of the spine. Part I: spinal stability. *Eur J Radiol* 2013;82(01):118–126
- Pal GP, Sherk HH. The vertical stability of the cervical spine. *Spine* 1988;13(05):447–449
- Asazuma T, Toyama Y, Maruiwa H, Fujimura Y, Hirabayashi K. Surgical strategy for cervical dumbbell tumors based on a three-dimensional classification. *Spine* 2004;29(01):E10–E14
- Jiang L, Lv Y, Liu XG, et al. Results of surgical treatment of cervical dumbbell tumors: surgical approach and development of an anatomic classification system. *Spine* 2009;34(12):1307–1314
- Kim JH, Han S, Kim JH, Kwon TH, Chung HS, Park YK. Surgical consideration of the intraspinal component in extradural dumbbell tumors. *Surg Neurol* 2008;70(01):98–103
- Kandziora F, Pflugmacher R, Scholz M, et al. Posterior stabilization of subaxial cervical spine trauma: indications and techniques. *Injury* 2005;36(Suppl 2):B36–B43
- Albrektsson T, Johansson C. Osteoinduction, osteoconduction and osseointegration. *Eur Spine J* 2001;10(Suppl 2):S96–S101
- Raynor RB, Pugh J, Shapiro I. Cervical facetectomy and its effect on spine strength. *J Neurosurg* 1985;63(02):278–282
- Zdeblick TA, Zou D, Warden KE, McCabe R, Kunz D, Vanderby R. Cervical stability after foraminotomy. A biomechanical in vitro analysis. *J Bone Joint Surg Am* 1992;74(01):22–27
- Voo LM, Kumaresan S, Yoganandan N, Pintar FA, Cusick JF. Finite element analysis of cervical facetectomy. *Spine* 1997;22(09):964–969
- Cusick JF, Yoganandan N, Pintar F, Myklebust J, Hussain H. Biomechanics of cervical spine facetectomy and fixation techniques. *Spine* 1988;13(07):808–812
- Wu Y, Tang H, Li Z, Zhang Q, Shi Z. Outcome of posterior lumbar interbody fusion versus posterolateral fusion in lumbar degenerative disease. *J Clin Neurosci* 2011;18(06):780–783
- Levin JM, Tanenbaum JE, Steinmetz MP, Mroz TE, Overley SC. Posterolateral fusion (PLF) versus transforaminal lumbar interbody fusion (TLIF) for spondylolisthesis: a systematic review and meta-analysis. *Spine J* 2018;18(06):1088–1098
- Ji W, Cheng Y, Zhu Q, et al. Posterior unilateral exposure and stability reconstruction with pedicle and lamina screw fixation for the cervical dumbbell tumorectomy: a case report and biomechanical study. *Eur Spine J* 2021;30(02):568–575
- Clarke MJ, Zadnik PL, Groves ML, et al. Fusion following lateral mass reconstruction in the cervical spine. *J Neurosurg Spine* 2015;22(02):139–150
- Nishinome M, Iizuka H, Iizuka Y, Takagishi K. An analysis of the anatomic features of the cervical spine using computed tomography to select safer screw insertion techniques. *Eur Spine J* 2013;22(11):2526–2531
- Pesenti S, Lafage R, Lafage V, Panuel M, Blondel B, Jouve JL. Cervical facet orientation varies with age in children: an MRI study. *J Bone Joint Surg Am* 2018;100(09):e57
- Patil ND, Srivastava SK, Bhosale S, Purohit S. Computed tomography- and radiography-based morphometric analysis of the lateral mass of the subaxial cervical spine in the Indian population. *Asian Spine J* 2018;12(01):18–28
- Stemper BD, Marawar SV, Yoganandan N, Shender BS, Rao RD. Quantitative anatomy of subaxial cervical lateral mass: an analysis of safe screw lengths for Roy-Camille and magerl techniques. *Spine* 2008;33(08):893–897
- Rong X, Liu Z, Wang B, Chen H, Liu H. The facet orientation of the subaxial cervical spine and the implications for cervical movements and clinical conditions. *Spine* 2017;42(06):E320–E325
- Abdullah KG, Steinmetz MP, Mroz TE. Morphometric and volumetric analysis of the lateral masses of the lower cervical spine. *Spine* 2009;34(14):1476–1479
- Turner CH. Three rules for bone adaptation to mechanical stimuli. *Bone* 1998;23(05):399–407