
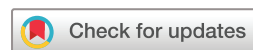
# Re-sensitization to pembrolizumab following PSMA-CD3 T-cell redirection therapy with JNJ-081 in a patient with mismatch repair-deficient metastatic castration-resistant prostate cancer: a case report

Darien E Reed-Perino ,<sup>1,2</sup> Michael Lai,<sup>1</sup> Evan Y Yu,<sup>1,3</sup> Michael T Schweizer<sup>1,3</sup>

**To cite:** Reed-Perino DE, Lai M, Yu EY, *et al.* Re-sensitization to pembrolizumab following PSMA-CD3 T-cell redirection therapy with JNJ-081 in a patient with mismatch repair-deficient metastatic castration-resistant prostate cancer: a case report. *Journal for ImmunoTherapy of Cancer* 2023;**11**:e006794. doi:10.1136/jitc-2023-006794

Accepted 03 May 2023



© Author(s) (or their employer(s)) 2023. Re-use permitted under CC BY-NC. No commercial re-use. See rights and permissions. Published by BMJ.

<sup>1</sup>Division of Oncology, Department of Medicine, University of Washington, Seattle, Washington, USA  
<sup>2</sup>Division of Human Biology, Fred Hutchinson Cancer Center, Seattle, Washington, USA  
<sup>3</sup>Clinical Research Division, Fred Hutchinson Cancer Center, Seattle, Washington, USA

**Correspondence to**  
Dr Michael T Schweizer;  
schweize@uw.edu

## ABSTRACT

While checkpoint inhibitor therapy has revolutionized the treatment landscape of some solid tumors, it has shown limited efficacy in metastatic castration-resistant prostate cancers (mCRPC). A small (~3–5%) but clinically distinct subset of mCRPC tumors have a DNA mismatch repair deficiency (dMMR) and develop a hypermutation phenotype with elevated tumor mutational burden and high microsatellite instability (MSI-H). Retrospective analyses have shown dMMR/MSI-H status to be a predictive biomarker for response to pembrolizumab in prostate tumors. Here, in this report, we present a case of a patient with mCRPC harboring a somatic dMMR who had progressed on pembrolizumab after an initial response. He enrolled on a clinical trial with JNJ-081, a prostate-specific membrane antigen-CD3 bispecific T-cell engager antibody and experienced a partial response with course complicated by cytokine release syndrome. On progression, he was reinitiated on pembrolizumab and experienced an exceptional second response, with his prostate-specific antigen falling from a high of 20.01 to undetectable after 6 weeks and remaining undetectable for >11 months. To our knowledge, this represents the first reported case of bispecific T-cell engager-mediated re-sensitization to checkpoint inhibitor therapy in any cancer.

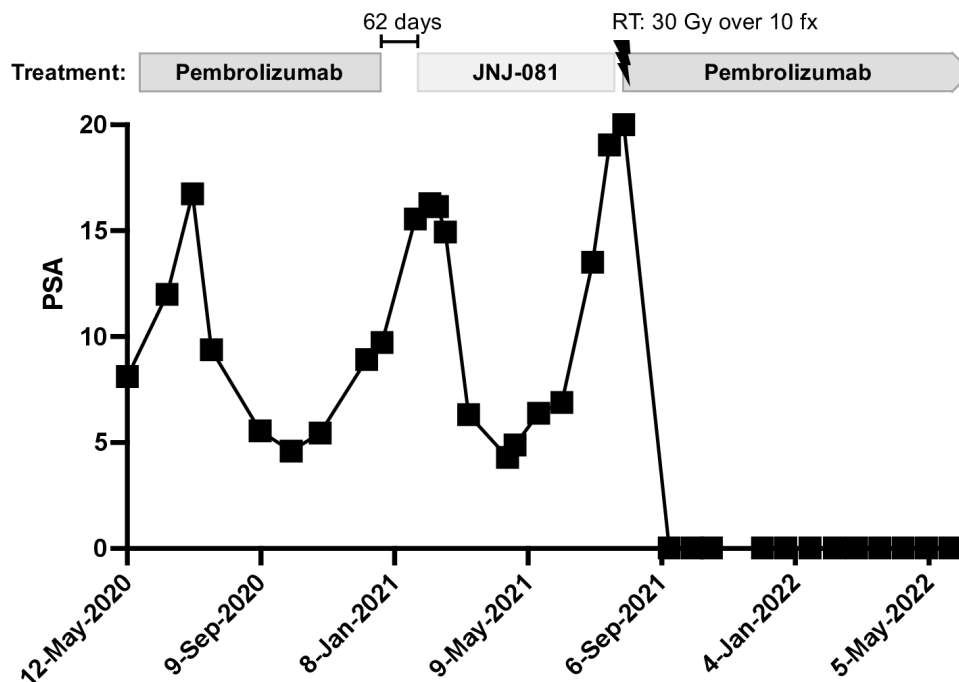
## INTRODUCTION

Checkpoint inhibitor therapies have revolutionized the treatment of some solid tumors but have not proven to be effective for most men with metastatic castration-resistant prostate cancer (mCRPC). A small (~3–5%) clinically distinct subset of these tumors harbor mutations in mismatch repair (MMR) genes (ie, *MLH1*, *MSH2*, *MSH6* or *PMS2*), which in turn leads to a high tumor mutational burden (TMB) and microsatellite instability (MSI).<sup>1</sup> MMR deficient (dMMR) prostate tumors have aggressive pathologic and clinical features, including high Gleason scores and

the presence of de novo metastatic disease at diagnosis.<sup>1</sup> Prospective clinical studies in tumor type-agnostic dMMR/MSI-high (MSI-H) solid tumors showed high response rates and long progression-free survival with the anti-programmed cell death protein-1 (PD-1) monoclonal antibody pembrolizumab. Retrospective analyses showed dMMR/MSI-H status to be a useful predictive biomarker for response to pembrolizumab in the few prostate tumors included in these trials, whereas clinical response in unselected patients with mCRPC is exceedingly low (3–5%).<sup>1</sup>

Secondary resistance mechanisms have hindered realizing the full potential of immunotherapy in mCRPC. Given that a large proportion of tumors lack T-cell infiltration, so called ‘cold tumors’, significant research has been dedicated to triggering T-cell infiltration into the tumor, creating a ‘hot tumor’. One avenue has been through bispecific antibodies comprised of two single-chain variable fragments linked together, one recognizing CD3 on T-cells and the other binding a tumor-associated antigen of interest, stimulating cytolytic T-cell activity independent of T-cell receptor-major histocompatibility complex signaling. Bispecific T-cell engager antibodies have been successful in the treatment of hematologic malignancies. Blinatumomab, a CD19-CD3 bispecific T-cell engager antibody, is now a component of standard-of-care treatment for acute lymphoblastic leukemia. Tebentafusp, a bp100-CD3 bispecific T-cell engager, was recently Food and Drug Administration-approved for the treatment of metastatic uveal melanoma.

We participated in a Phase I clinical trial of JNJ-081, a bispecific T-cell engager antibody



**Figure 1** PSA trend through first pembrolizumab course, the JNJ-081 bispecific antibody clinical trial, and second course of pembrolizumab. Radiation treatment is denoted by lightning bolt. PSA levels below the limit of detection (<0.03) for our laboratory are plotted as 0.029. PSA, prostate-specific antigen; RT, radiation treatment.

recognizing CD3 and prostate-specific membrane antigen (PSMA), expressed by the majority of mCRPC.<sup>2</sup> Although transient decreases in prostate-specific antigen (PSA) were seen, most patients treated developed anti-drug antibodies resulting in loss of exposure to the drug and limiting its therapeutic potential. We present the case of a patient with dMMR/MSI-H mCRPC who developed secondary resistance to pembrolizumab and then proceeded to receive JNJ-081. On progression on JNJ-081, he was rechallenged with pembrolizumab and subsequently experienced an ongoing durable response.

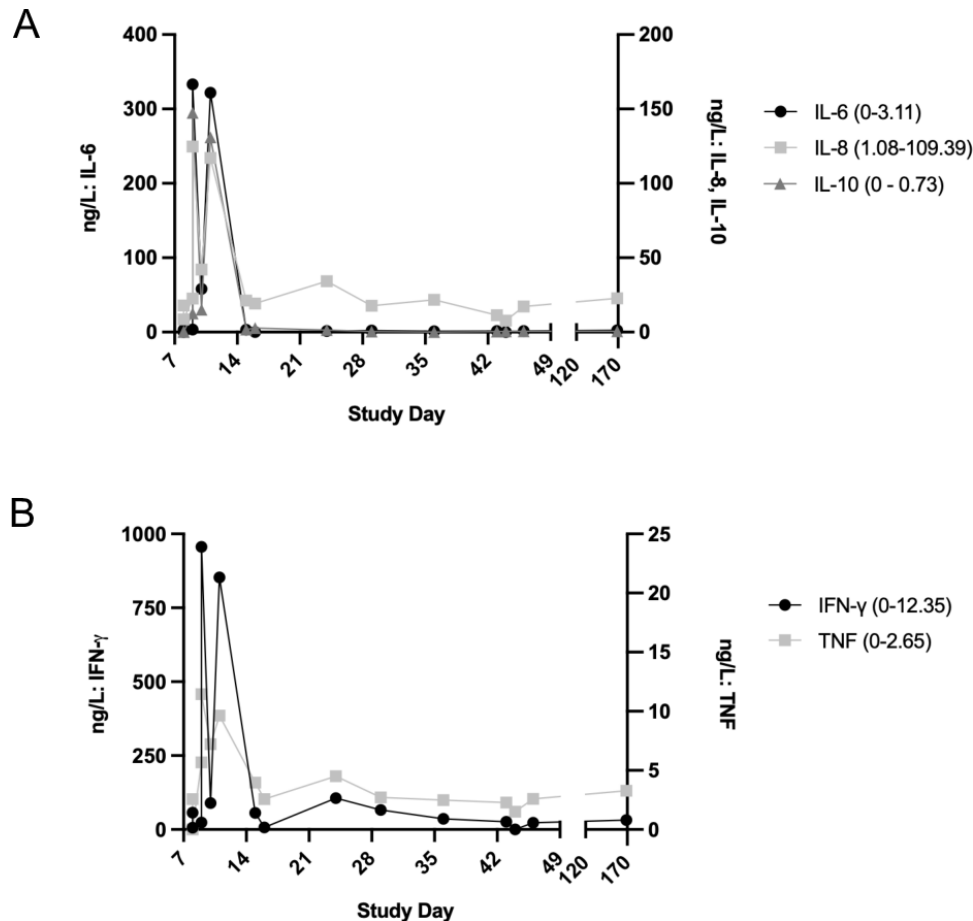
## CASE

A man >70 years old was diagnosed with Gleason 4+5=9 localized prostate adenocarcinoma in 2013 with a PSA of 2.39 and underwent robotic-assisted radical prostatectomy. He experienced early biochemical recurrence before 12 months and completed salvage radiation therapy without PSA response and 6 months later he began androgen deprivation therapy with leuprolide. His PSA continued to increase, consistent with castration-resistant disease, and enzalutamide was added 9 months later resulting in a durable response with an undetectable PSA for several years. Fluciclovine PET 3 years later for a rising PSA revealed progressive bone and lymph node metastases. He was treated with sipuleucel-T without any PSA response followed by abiraterone and prednisone resulting in a 1-month PSA response.

He underwent biopsy of a left supraclavicular lymph node with pathology consistent with metastatic prostatic adenocarcinoma. Immunohistochemical staining for DNA mismatch repair proteins revealed loss of nuclear MSH6

expression in tumor cells, suggestive of dMMR. Targeted somatic sequencing of his tumor with UW-OncoPlex revealed bi-allelic *MSH6* mutations, a TMB of 21 mutations per megabase and MSI-H. Other findings included an *AR* missense mutation in the ligand binding domain (p.T878A) reported to confer resistance to androgen receptor signaling inhibitors, *CHD1* homozygous copy loss, bi-allelic inactivation of *RBI* and a pathogenic *SPOP* mutation.<sup>3</sup> Germline testing was notably negative. He was initiated on pembrolizumab without baseline imaging, and his PSA declined by 73% reaching a nadir 5 months into treatment before rising again. Pembrolizumab was discontinued after 7 months and he was referred to our cancer center for a second opinion (figure 1).

Restaging scans showed new mediastinal lymph node and bone metastases compared with baseline scans 6 years prior. At that point, he enrolled on a Phase I clinical trial testing the PSMA-CD3 T-cell engager, JNJ-081, and began treatment 62 days after discontinuing pembrolizumab. He received a 10 mcg/kg subcutaneous priming dose on week 1 followed by weekly 55 mcg/kg doses thereafter. His course was complicated by Grade 1 cytokine release syndrome (CRS) following his third dose, managed with antipyretics and intravenous fluids, with a negative infectious work-up. He developed Grade 3 transaminitis, with liver function tests normalizing following a 1 week dose hold. He had an acute increase in inflammatory cytokines following study drug administration, which was marked following the first few doses coinciding with the occurrence of CRS but persisted throughout treatment and progression in the case of interferon-gamma and remained intermittently elevated in the case of tumor



**Figure 2** Inflammatory marker trends while on the JNJ-081 bispecific antibody trial. (A) Interleukin-6 (IL-6), interleukin-8 (IL-8) and interleukin-10 (IL-10) levels. (B) Interferon-gamma (IFN- $\gamma$ ) and tumor necrosis factor (TNF) levels. Normal reference ranges for all inflammatory markers are denoted in parentheses following label in legend.

necrosis factor (figure 2A–B). He developed evidence of anti-drug antibody formation on Day 8 of treatment. Baseline PSA of 16.14 declined to a nadir of 4.30 (73% decrease) on Day 84. Best imaging response was assessed as stable disease with a 9.3% decline in lymph node size.

He developed radiographic progression on Day 181 in thoracic and retroperitoneal lymphadenopathy, most notably in a left lower jugular/retrosternal lymph node conglomerate with narrowing of the left internal jugular vein and mass effect on the left brachiocephalic vein. He concurrently developed acute onset dysphonia with clinical concern for compression or involvement of the recurrent laryngeal nerve and was referred for palliative radiation to the affected area. Docetaxel chemotherapy was discussed, however, the patient elected to rechallenge with pembrolizumab, initiated concurrently with radiation. PSA fell from a high of 20.01 to undetectable after 6 weeks. More than 11 months later, his PSA remained undetectable at  $<0.03$  (figure 1).

## DISCUSSION

Identifying strategies to overcome the resistance to immunotherapy is an active area of research. Reported re-sensitization strategies to immune checkpoint inhibitors

include combinations with tyrosine kinase inhibitors and intratumoral chemotherapy.<sup>4,5</sup> Case reports show resistance to blinatumomab through increased expression of the immunoinhibitory protein PD-L1, and re-sensitization with the addition of pembrolizumab.<sup>6,7</sup> To our knowledge, this represents the first possible case of bispecific T-cell engager-mediated re-sensitization to checkpoint inhibitor therapy in any cancer.

Prostate tumors harbor multiple mechanisms of immune suppression and evasion including a hostile tumor microenvironment (TME) comprised of myeloid-derived cells secreting immunosuppressive cytokines, tumor cells overexpressing immunoinhibitory ligands and prostate cell secretion products causing T-cell dysfunction.<sup>8,9</sup> While checkpoint blockade is effective for many dMMR/MSI-H prostate tumors, mechanisms of immunosuppression beyond PD-1 activation likely mediate primary and secondary resistance to pembrolizumab. Bispecific T-cell engagers are resistant to some mechanisms of tumor immune suppression and evasion by bypassing the requirement for a co-stimulatory secondary signal. We hypothesize that the exceptional response to pembrolizumab observed in this case was mediated by recruitment of T-cells to the TME by the bispecific T-cell

engager JNJ-081, which were subsequently reactivated on pembrolizumab rechallenge. Whether persistent effector T cells in the tumor were required for ongoing response to pembrolizumab rechallenge or whether the initial tumor-killing effect was robust enough to result in a persistently undetectable PSA remains unknown. This patient's partial response, CRS and elevated cytokines following treatment with JNJ-081 are consistent with immune system activation and support this theory. While it is possible the activity of JNJ-081 may have been augmented by prior pembrolizumab, we suspect that the effect of prior anti-PD1 therapy was minor given that 2.8 half-lives had elapsed when he initiated step-up dosing of this T-cell engager.<sup>10</sup> It is also possible that radiation therapy augmented his response to pembrolizumab; however, whether radiation is able to induce a clinically meaningful abscopal effect in prostate cancer remains unclear.

CRS is a well-documented adverse effect from T cell-engaging therapies, and it is not remarkable that our patient experienced CRS. Rather, it is remarkable that he experienced a complete biochemical response to subsequent line immunotherapy. Can a response to T-cell engaging therapies serve as one mechanism for turning a 'cold tumor' into a 'hot tumor', even after progression? Might we be able to hardwire into a tumor a response to the next line of treatment, potentially months before it's needed? Clinical trials combining concurrent administration of bispecific antibodies, including T-cell engagers, with checkpoint inhibitors in solid tumors are ongoing, but our case suggests testing sequential administration of bispecific T-cell engagers followed by immunotherapy may be effective. Sequential treatment strategies are likely to be better tolerated and associated with decreased rates of immune-related adverse effects.

Although our patient was the ideal candidate for pembrolizumab with dMMR/MSI-H and an elevated TMB, he only experienced a 7-month long partial response at first exposure. If treatment with a bispecific T-cell engager short-circuits the immunosuppressive TME in 'cold' tumors like prostate, pancreatic and breast tumors by trafficking in effector T cells, could they be a pre-designed method to creating 'hot' tumors? The field of T-cell engaging therapies is growing, and one could imagine adding trispecific antibodies (or multiple bispecific antibodies) to traffic additional immune-supportive cell subsets into the TME or an antibody-drug conjugate carrying a favorable cytokine payload toward the TME. Rational combinations, based on our case, may potentially

open an opportunity for further investigation of checkpoint inhibitors on progression.

**Acknowledgements** The authors would like to thank Sonia Goyal for her assistance with clinical research coordination.

**Contributors** DER, ML, EYY and MTS analyzed and interpreted data. DER, EYY and MTS contributed to writing the manuscript. DER, EYY and MTS edited the manuscript. All authors reviewed and approved the final version of the manuscript.

**Funding** Janssen Pharmaceuticals provided funding for the clinical trial.

**Competing interests** No, there are no competing interests.

**Patient consent for publication** Not applicable.

**Ethics approval** Approved by WCG IRB for the The University of Washington/Fred Hutchinson Cancer Center, IRB number is RG1004978. Participants gave informed consent to participate in the study before taking part.

**Provenance and peer review** Not commissioned; externally peer reviewed.

**Open access** This is an open access article distributed in accordance with the Creative Commons Attribution Non Commercial (CC BY-NC 4.0) license, which permits others to distribute, remix, adapt, build upon this work non-commercially, and license their derivative works on different terms, provided the original work is properly cited, appropriate credit is given, any changes made indicated, and the use is non-commercial. See <http://creativecommons.org/licenses/by-nc/4.0/>.

#### ORCID iD

Darien E Reed-Perino <http://orcid.org/0000-0002-0401-3541>

#### REFERENCES

- Graham LS, Schweizer MT. Mismatch repair deficiency and clinical implications in prostate cancer. *Prostate* 2022;82 Suppl 1:S37–44.
- Lim EA, Schweizer MT, Chi KN, *et al.* Safety and preliminary clinical activity of JNJ-63898081 (JNJ-081), a PSMA and Cd3 Bispecific antibody, for the treatment of metastatic Castrate-resistant prostate cancer (mCRPC). *JCO* 2022;40(6\_suppl):279.
- Romanel A, Gasi Tandefelt D, Conteduca V, *et al.* Plasma AR and Abiraterone-resistant prostate cancer. *Sci Transl Med* 2015;7:312re10.
- Houessonin A, Moreira A, Bettoni J, *et al.* Resensitization to Nivolumab after Intratumoral chemotherapy in recurrent head and neck squamous cell cancer: A report of 2 cases. *Case Rep Oncol* 2020;13:835–42.
- Kwilas AR, Ardiani A, Donahue RN, *et al.* Dual effects of a targeted small-molecule inhibitor (Cabozantinib) on immune-mediated killing of tumor cells and immune tumor Microenvironment Permissiveness when combined with a cancer vaccine. *J Transl Med* 2014;12:294:294..
- Feucht J, Kayser S, Gorodezki D, *et al.* T-cell responses against Cd19 + pediatric acute Lymphoblastic leukemia mediated by Bispecific T-cell Engager (bite) are regulated Contrarily by PD-L1 and Cd80/Cd86 on Leukemic blasts. *Oncotarget* 2016;7:76902–19.
- Wunderlich M, Manning N, Sexton C, *et al.* PD-1 inhibition enhances Blinatumomab response in a UCB/PDX model of Relapsed pediatric B-cell acute Lymphoblastic leukemia. *Front Oncol* 2021;11:642466.
- Dorff TB, Narayan V, Forman SJ, *et al.* Novel redirected T-cell Immunotherapies for advanced prostate cancer. *Clin Cancer Res* 2022;28:576–84.
- Wong RL, Yu EY. Refining Immuno-oncology approaches in metastatic prostate cancer: Transcending current limitations. *Curr Treat Options Oncol* 2021;22:13.
- Keytruda [package insert]. Whitehouse Station, NJ: Merck & Co., Inc; 2014. Available: [https://www.accessdata.fda.gov/drugsatfda\\_docs/label/2021/125514s096lbl.pdf](https://www.accessdata.fda.gov/drugsatfda_docs/label/2021/125514s096lbl.pdf) [Accessed 15 Mar 2023].