

FOREIGN BODY REACTION TO INHALATION OF LENTIL SOUP: GIANT CELL PNEUMONIA*

BY

MARY A. HEAD

From the Pathology and Cancer Research Departments, Royal Beatson Memorial Hospital, Glasgow

(RECEIVED FOR PUBLICATION NOVEMBER 26, 1955)

Granulomatous lesions of the stomach, peritoneum, and lungs caused by an unidentified foreign body have been described at intervals for the past 30 years. Muir (1929) illustrates a nodule from the peritoneal cavity showing giant cell and macrophage reaction around a foreign body probably of vegetable origin. Barnard (1940) illustrates a foreign body reaction in the lung round inhaled particles which have a similar appearance. Sherman and Moran (1954a) describe six cases of granuloma of the stomach associated with gastric ulceration, two of which were caused by vegetable material composed of starch-containing cells. Similar lesions were found in the lungs in the cases now presented, which varied from suppurative aspiration pneumonia to granulomatous lesions with foreign body giant cells and fibrosis.

Case Reports

Case 1.—A man, aged 63, was admitted to hospital with carcinoma of the oesophagus and metastases in the lymph nodes and lungs. Six months previously he had had a carcinoma of the larynx which appeared to have healed after x-ray therapy. He remained well until two months before admission, when severe dysphagia developed, and on radiological examination an extensive carcinoma of the oesophagus was found.

His diet consisted of fluids, sieved soup, gruel, and milk puddings. When eating he sometimes choked and coughed, and particles of food were presumably inhaled into the lungs.

At necropsy the larynx showed no evidence of tumour. A large carcinoma, 7.5 cm. in diameter, was found on the anterior wall of the oesophagus about the middle third. Enlarged pre-aortic glands were also present. The lungs were enlarged and oedematous, and small, hard, white nodules about 0.5 to 1.0 cm. in diameter were seen in both.

On histological examination of the lung nodules, some were seen to be metastases of squamous-celled carcinoma similar to the primary tumour in the

oesophagus, whereas others were pneumonic, consisting of a granulomatous reaction around small oval bodies about 100 μ in diameter which had caused a foreign body reaction consisting of macrophages, giant cells, and fibrosis (Fig. 1). Some of these bodies were lying in bronchioles in which many pus cells were present, and others had penetrated more deeply and lay in the lung alveoli surrounded by a zone of fibrosis and granulation tissue, and a few were also noted in the malignant ulcer of the oesophagus.

Similar bodies were found in the lungs of two patients dying from bronchopneumonia in mental hospitals; there was a history of tube feeding in each case.

Case 2.—A woman, aged 38, had been in a mental hospital for some years. About a month before death she fell and struck her head, but did not appear to suffer any serious injury. Thereafter, her condition deteriorated and she had to be tube-fed. Finally she lapsed into coma, and at necropsy was found to have widespread bronchopneumonia with foci of suppuration in both lungs.

On histological examination the lesions were all seen to be fairly recent and the alveoli contained vegetable foreign bodies, similar to those seen in Case 1, in various stages of disintegration; other vegetable particles of different kinds were also observed. Foreign body giant cells were seen in many alveoli in relation to these bodies.

Case 3.—A woman, aged 34, died in a mental hospital from bronchopneumonia. She had been tube-fed for some time. At necropsy foci of suppurative bronchopneumonia were found.

On histological examination the lungs showed patches of organizing pneumonia and some fibrous encapsulation of the older lesions. Similar vegetable foreign bodies were seen, some being free in the alveoli, but others causing a markedly granulomatous reaction with foreign body giant cells and radiating macrophages, the whole lesion being surrounded by a zone of newly formed connective tissue (Fig. 2).

Case 4.—The patient was a child of 22 months, who had had several attacks of aspiration pneumonia, the first being diagnosed at 1 month of age. The child had never been breast-fed, was always in poor

* A preliminary account of this work was given before the Caledonian Branch of the Association of Clinical Pathologists in Glasgow, November 5, 1955.

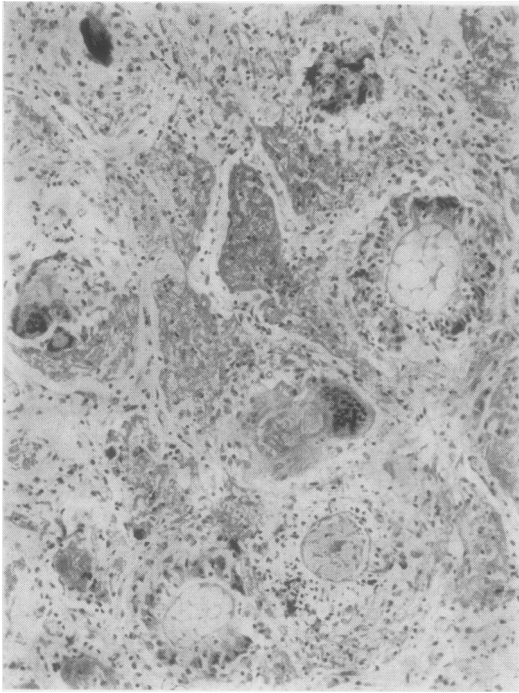


FIG. 1.—Section of lung (Case 1) showing foreign body reaction around starch-containing lentil cells. Haematoxylin and eosin. $\times 120$.

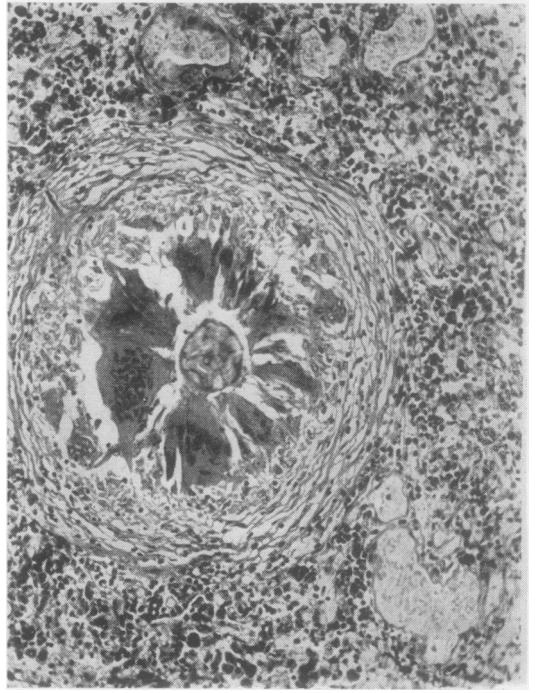


FIG. 2.—Section of lung (Case 3) showing fibrous reaction around starch-containing vegetable cell. $\times 115$.

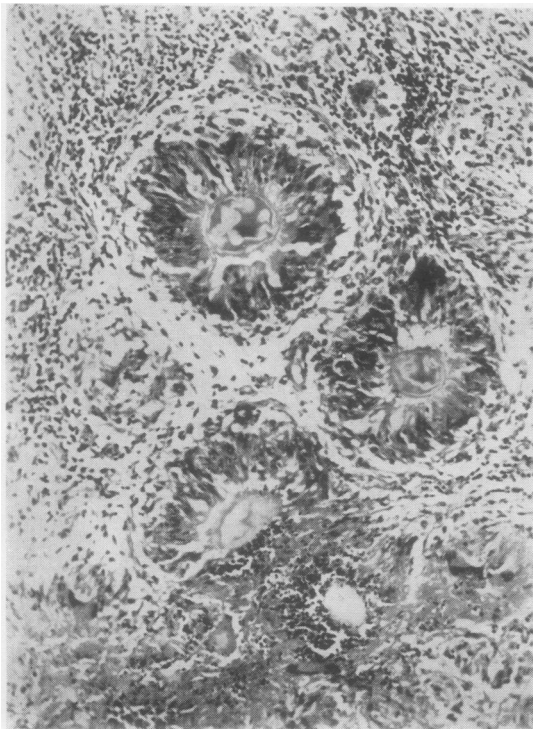


FIG. 3.—Section of omental nodule (Case 5) showing numerous lentil starch cells embedded in cellular tubercles, with remains of a subacute inflammatory reaction.

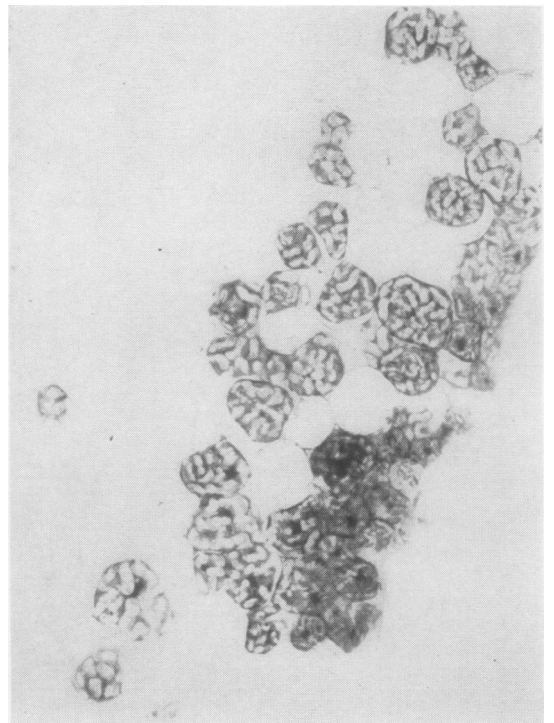


FIG. 4.—Section of lentil soup showing starch-containing cells and cellulose framework. Haematoxylin and eosin. $\times 120$.

health and anaemic, and had been given sieved soup while in hospital. After operation for cleft palate the child had another, fatal attack of aspiration pneumonia.

At necropsy areas of suppurative pneumonia were found.

On histological examination vegetable foreign bodies similar to those in the previous cases were seen. They were causing a foreign body reaction which in some areas was of a chronic granulomatous nature and in others was suppurative and of recent origin.

Case 5.—A middle-aged man was admitted to the Western Infirmary, Glasgow, under the care of the late Mr. G. H. Edington, complaining of abdominal pain and dyspepsia of several months' duration. At laparotomy the peritoneum was studded with small, whitish, firm nodules and there were thickening and adhesions about the pyloric end of the stomach. A portion of omentum containing several nodules was removed for confirmation of the clinical diagnosis of gastric carcinoma with peritoneal metastases.

Microscopic examination revealed no evidence of carcinoma. The nodules consisted of numerous small vegetable bodies singly and in clusters, surrounded by a very pronounced granulomatous and fibrous reaction. The single bodies were enclosed in well-defined tubercles, consisting of large multinucleated giant cells and radiating reticulo-endothelial cells: where the vegetable bodies were clustered together the remains of a subacute suppurative reaction could be seen (Fig. 3). The patient made a good immediate recovery, and it was presumed that the condition was, in fact, one of peptic ulceration with a minute perforation through which gastric contents had gained entrance to the peritoneal cavity. Beyond recognition of the vegetable nature of the bodies their exact source and nature were not identified at the time.

Histology

Sections of lung from the first four cases were stained by various methods to identify the bodies, which were about $100\ \mu$ in diameter and had a capsule which was seen to be doubly refractile when examined by polarized light. Within the capsule there were several small, eosinophil, ovoid bodies which had a lengthwise, narrow clear zone in the centre. They stained faintly pink by the periodic-acid-Schiff method. The central bodies stained blue and the capsule pink with carbol thionin. When stained with iodine the central bodies gave a deep blue starch reaction. It seemed clear that they were starch-containing vegetable cells. The starch grains in these bodies were oval with the hilum lengthwise; this is typical of the parenchyma cells of peas, beans and lentils (Brimble, 1953). Inquiry into the diet of the first patient revealed that he had been fed with lentil soup repeatedly during his stay in hospital. In the uncooked state the pulp cells of pulses are arranged in solid sheets of small rectangular cells. When cooked, these cells swell and break away from the

cellulose framework, and, when free, appear as small encapsulated oval bodies containing several ovoid starch grains. Even after prolonged boiling and sieving the starch-containing cells remain intact within their capsules (Fig. 4), but the starch grains become markedly convoluted and the hilum appears as a fine clear slit, especially after staining with iodine. Lentil soup was sieved and the *purée* was processed as for small biopsy specimens; paraffin sections were cut and stained by the same methods as used for the lung sections. The staining reactions and morphological appearances were similar (Fig. 4) to those seen in the human lungs.

Experimental

In order to determine whether the lentil bodies could produce a similar reaction to that described above, mice were given intraperitoneal and subcutaneous injections of cooked lentil *purée* and were killed at intervals of from two days to seven weeks.

Intraperitoneal Injections.—Two days after intraperitoneal injection clumps of starch-containing lentil parenchyma cells, surrounded by macrophages, were seen on the surface of the omentum and penetrating into the folds (Fig. 5).

After four days there was a more intense macrophage reaction around the lentil cells and some had penetrated the capsule of the cells. A fibroblastic reaction had begun, and round and plasma cells were present.

Seven days after intraperitoneal injection many lentil cells were still intact and surrounded by a mantle of macrophages. Other lentil cells contained macrophages and were being digested by them. Many fibroblasts were present and new capillaries were being formed. One lesion was situated deeply in the omentum, which was adherent to the parietal peritoneum (Fig. 6), and a similar nodule was present in the capsule of the liver indenting but not invading the organ (Fig. 7).

Fourteen days after intraperitoneal injection a lesion was found in the capsule of the liver in which lentil cells were seen surrounded by macrophages and fibroblasts. Similar lesions were seen in the perirenal fat 26 days after injection and in the capsule of the liver after seven weeks.

Subcutaneous Injections.—Mice were killed two, four, five, and seven weeks after subcutaneous injection of lentil *purée*. Nodules, 0.5 to 1 cm. in diameter, were found at the site of injection. Histologically these were seen to be granulomata in which many lentil cells were still intact, and others were being digested by macrophages. The outer part was composed of cellular fibrous tissue and the centre of necrotic material (Fig. 8). A deep blue starch reaction was still present in these lentil cells.

Comment

The foreign bodies causing the granulomatous lesions in these cases had the morphological and

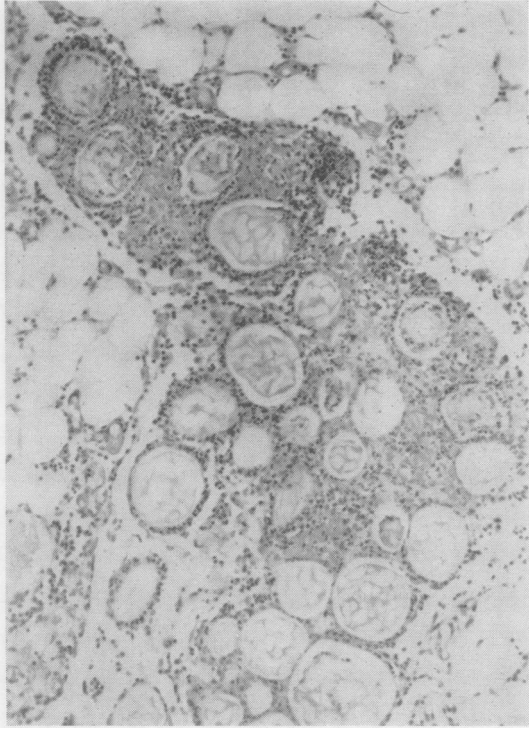


FIG. 5.—Section of mouse omentum showing starch-containing lentil cells surrounded by macrophages two days after intraperitoneal injection. Haematoxylin and eosin. $\times 120$.

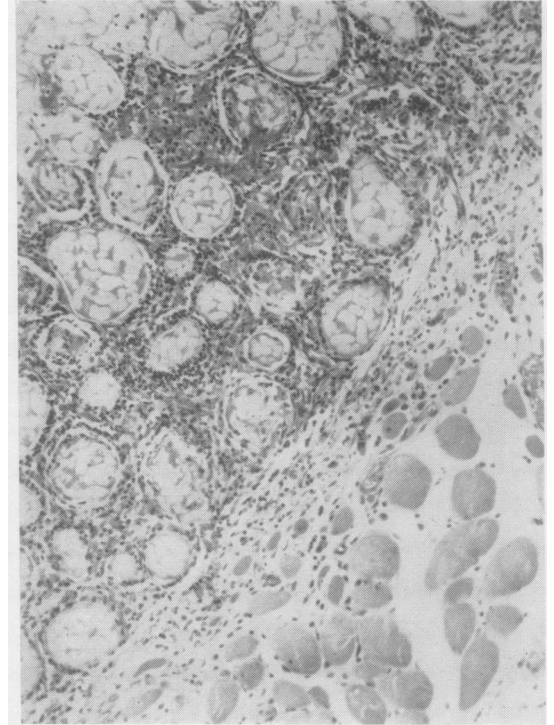


FIG. 6.—Section of mouse omentum containing lentil cells adherent to peritoneum seven days after intraperitoneal injection. Haematoxylin and eosin. $\times 120$.

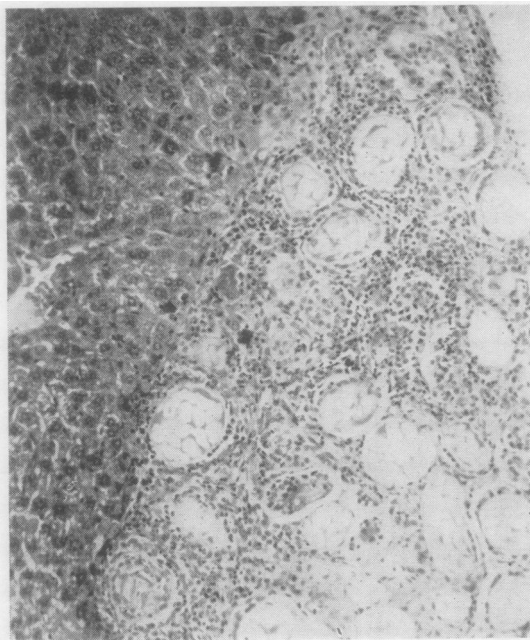


FIG. 7.—Section from same mouse as in Fig. 6, showing lentil cells in capsule of liver. Haematoxylin and eosin. $\times 120$.

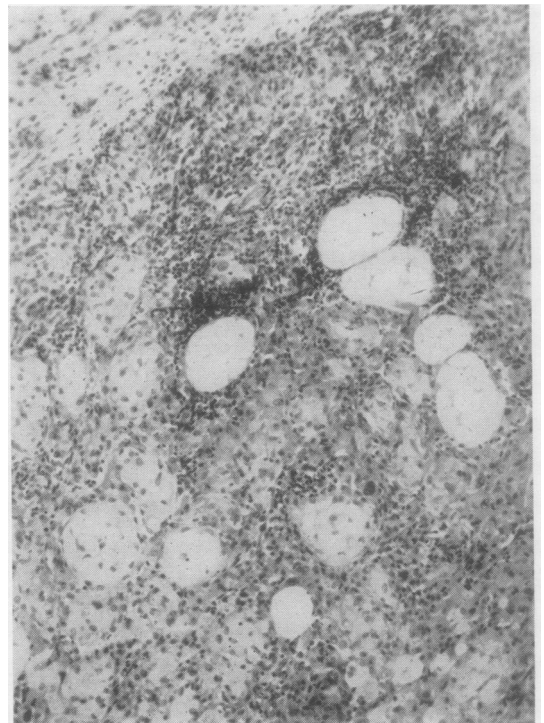


FIG. 8.—Section of fibrous nodule five weeks after subcutaneous injection, showing well-preserved lentil cells. Haematoxylin and eosin. $\times 120$.

tinctorial appearances of starch-containing lentil cells. The fact that the patients were on a restricted diet consisting, in Case 1, of milk puddings and lentil soup helped to confirm this diagnosis. The swollen, cooked lentil cells, with thick cellulose capsules, appear to be very resistant to digestion by macrophages, even after prolonged boiling for two or three hours, and well-preserved lentil cells were found in the lesions in mice seven weeks after intraperitoneal and subcutaneous injections.

Lesions containing similar bodies have been found in various types of case. In the one observed by Cappell and illustrated by Muir (1929) the lesions were found scattered throughout the peritoneum at laparotomy which was undertaken on account of pain and dyspepsia. Although there was no history of perforation it is probable that a minute, self-sealing perforation had occurred allowing the escape of gastric contents into the peritoneum.

The lesions described by Sherman and Moran (1954a) were in the base and edge of gastric ulcers, which had been removed by subtotal gastrectomy. These authors (1954b) also produced granulomatous lesions in the wall of the rabbit's stomach by injecting various substances, including ground peas, but did not show the characteristic starch-containing cells in the lesions.

These cells can only be seen in cooked peas, beans, and lentils, and are not recognizable as such in uncooked ground pulses. When first seen they

may be mistaken for worm embryos because of their coiled structure, and in old lesions the starch reaction cannot always be demonstrated.

These bodies are fairly well known, but their exact source and nature have not previously been recorded.

Summary

Suppurative and granulomatous lesions of the lung due to a foreign body are described.

Sections of lentil soup show that the foreign body is a starch-containing lentil cell.

Intraperitoneal and subcutaneous injections of lentil *purée* into mice produced similar granulomatous lesions.

Lesions were seen in the omentum within 48 hours and in the peritoneum and subcutaneous tissue persisted up to seven weeks, continuing to show easily identified starch-containing lentil cells.

I am indebted to Dr. A. A. Charteris for the clinical notes of Case 1, to Professor D. F. Cappell for the notes and preparations of Cases 2, 3, and 5, to Dr. A. M. MacDonald for the notes of Case 4, and to Dr. P. R. Peacock for his interest in this work and for reading the manuscript.

REFERENCES

- Barnard, W. G. (1940). *Elementary Pathological Histology*, 2nd ed., p. 10. Lewis, London.
- Brimble, L. J. F. (1953). *Intermediate Botany*, 4th ed., p. 70. Macmillan, London.
- Muir, R. (1929). *Text-Book of Pathology*, 2nd ed., p. 128. Arnold, London.
- Sherman, F. E., and Moran, T. J. (1954a). *Amer. J. clin. Path.*, **24**, 415.
- (1954b). *Ibid.*, **24**, 422.