

PULMONARY PLATELET THROMBO-EMBOLISM

BY

M. LEVENE AND C. I. LEVENE

From the Departments of Pathology, Christie Hospital and Holt Radium Institute, Manchester, and Royal Victoria Infirmary, Newcastle upon Tyne

(RECEIVED FOR PUBLICATION OCTOBER 18, 1956)

The purpose of this communication is to record the results of light and electron microscopic examination of a massive pulmonary embolus which was observed at necropsy to be unusually white and crumbly.

Clinical History

A married woman, aged 74 years, was admitted to the Christie Hospital for gastrectomy. She had been investigated for persistent melaena two years previously, and a chronic gastric ulcer of the lesser curve was demonstrated radiologically. Apart from a symptomless mitral stenosis, examination revealed no other abnormality.

Nine years previously a right radical mastectomy had been performed for a scirrhus carcinoma; the axillary lymph nodes were tumour-free and a careful follow-up did not show evidence of either local or distant recurrence.

At the time of admission the blood picture was as follows: Hb 7.1 g., R.B.C.s 3,960,000/c.mm., C.I. 0.6, W.B.C.s 12,700/c.mm. (polymorphs 10,600, lymphocytes 1,800, monocytes 180, eosinophils 120). Platelets were increased in number and were larger than usual, and the red cells showed aniso- and poikilocytosis, with some macrocytosis.

Gastrectomy had been advised after two years' conservative treatment with diet and iron preparations, because, in spite of temporary relief and a rise in the haemoglobin level, the patient had had further episodes of melaena. The operation was performed under epidural anaesthesia and the ulcer located, when her pulse stopped. Intracardiac adrenaline was administered, and cardiac massage and artificial respiration were temporarily successful, but 15 minutes later her pulse again failed and she was dead.

Post-mortem Findings

Necropsy was performed 28 hours later (body refrigerated).

Death was due to a massive, white friable thrombus in the pulmonary tree and the right side of the heart. Similar material was found in the common iliac and femoral veins and the meningeal sinuses. The lymph nodes and bone marrow were normal, and the spleen (240 g.) was

coloured a homogeneous pink with no distinct Malpighian bodies. The heart (400 g.) showed a moderate degree of mitral stenosis and incompetence. A small gastric ulcer was found. All other organs appeared normal and there was no evidence of residual tumour.

Immediate squash preparations of the pulmonary thrombus showed it to consist of bodies of the size of platelets.

Histology

All sections were stained with haematoxylin and eosin.

The gastric ulcer showed no evidence of malignancy and the basal vessels were free of thrombus.

There was no evidence of active rheumatic carditis.

The lungs showed some emphysema and oedema. The arteries were filled with thrombi of a pale pink-staining granular substance, in which could be seen a few intact red and white cells (Figs. 1 and 2).

In the spleen there was no increase in fibrous tissue or arterial thickening, and the Malpighian bodies were very insignificant. The splenic pulp appeared to consist mainly of pale granular material resembling the material forming the pulmonary thrombus, with scattered aggregates of lymphocytes (Fig. 3).

There was a marked increase in the number of megakaryocytes in the bone marrow but not in the spleen, lungs, or liver (Fig. 4).

Special Stains

The following special stains were used to investigate the nature of the material forming the pulmonary thrombus and the splenic pulp. Sections of these were stained with Giemsa, Turnbull's iron, benzidine thionine stain for haemoglobin, Mallory's phosphotungstic-acid-haematoxylin, picro-Mallory, Weigert's fibrin, pyronin methyl green, periodic-acid-Schiff, Foot's reticulin method, and cresyl blue.

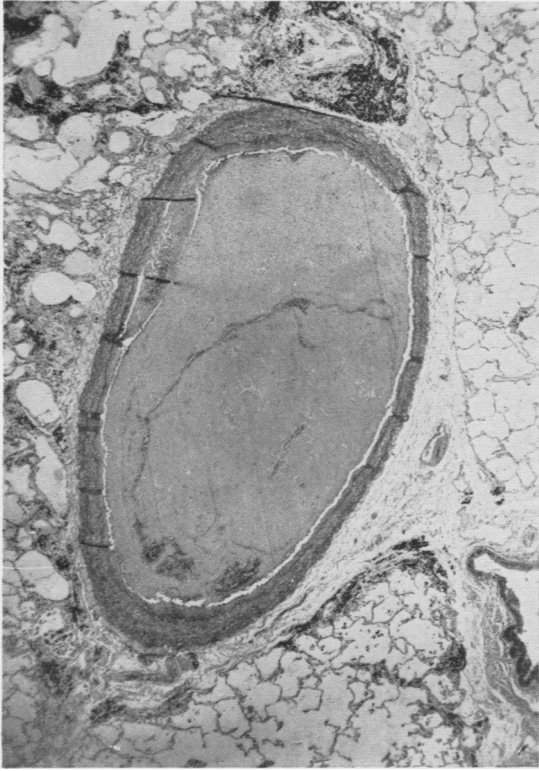


FIG. 1.—Section demonstrating small branch of pulmonary artery filled with thrombus (haematoxylin and eosin, $\times 18$).




FIG. 2.—Thrombus in Fig. 1 magnified $\times 850$ to show granular appearance.




FIG. 3.—Spleen demonstrating marked absence of Malpighian bodies (haematoxylin and eosin, $\times 18$).

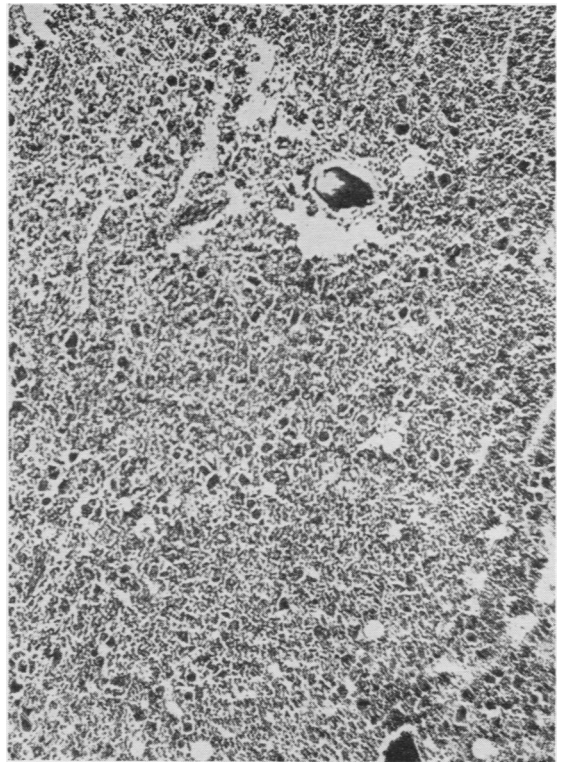


FIG. 4.—Marrow from body of sternum. The megakaryocytes stand out as distinct larger black specks ($\times 18$).

The staining reactions of the splenic pulp and pulmonary thrombus were practically identical. The stains revealed tiny amounts of fibrin in the pulmonary thrombus, and the absence of haemoglobin and free iron.

Electron Microscopy

Several portions of the formalin-fixed thrombus were teased and homogenized in distilled water, and drops of the suspension allowed to dry on Formvar-covered electron microscopic specimen grids, which were then shadowed with gold-palladium metal and scanned in a "metro-vick" electron microscope, type 3. Apart from a few fibres which resembled fibrin, the bulk of the material consisted of granular "debris," suggesting a non-fibrillary character. Ultra-thin sections of the thrombus were then prepared by a modification of the method of Palade (1952), and electron microscopic examination showed them to consist almost entirely of roughly spherical bodies measuring $1-2\frac{1}{2} \mu$ in diameter (Fig. 5). A comparison of these with similarly prepared ultra-thin sections of formalin-fixed fibrin from human fibrinous pericarditis (Fig. 6), and formalin-fixed human blood platelets prepared artificially by a modification of the method of Stefanini, Damashek, Chatterjea, Adelson, and Mednicoff (1953) (Fig. 7), further suggested the platelet nature of the thrombus.

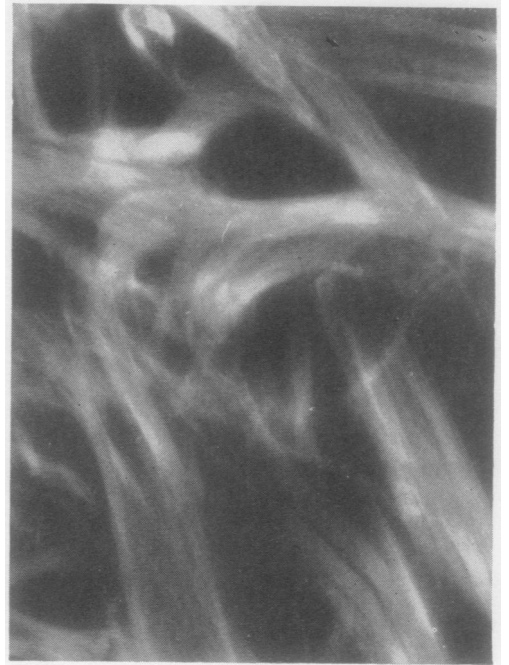


FIG. 6.—Electron microscopic photograph of thin section of fibrinous pericarditis ($\times 20,000$) to show fibrillary structure.

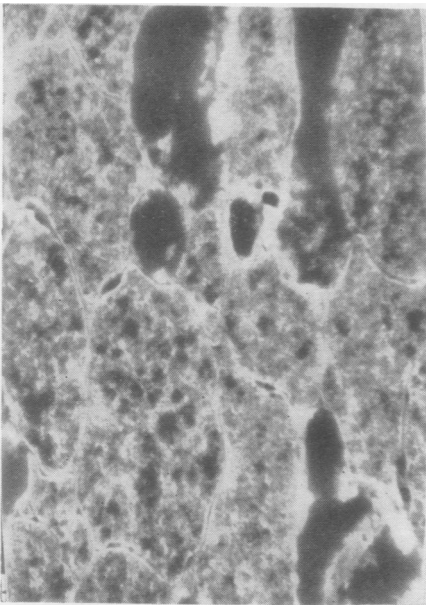


FIG. 5.—Electron microscopic photograph of thin section of thrombus ($\times 15,000$) to show non-fibrillary character.

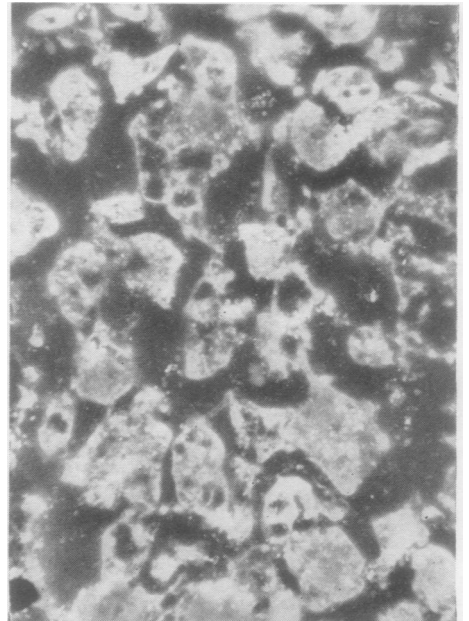


FIG. 7.—Electron microscopic photograph of thin section of preparation of platelets ($\times 5,000$) to show non-fibrillary character.

Discussion

This case appears to have been one of chronic bleeding peptic ulcer associated with unsuspected thrombocythaemia. In this respect it resembles the case described by Stefanini and Dameshek (1955) of a bleeding chronic peptic ulcer with thrombocythaemia and increase in marrow megakaryocytes, where partial gastrectomy eventually produced a return of the normal blood picture.

The association of atrophy of the Malpighian bodies of the spleen in the present case with thrombocythaemia has been reported by Epstein and Goedel (1934), and there is also a point of resemblance with some of the cases of haemorrhagic thrombocythaemia described by Hardisty and Wolff (1955).

The histological resemblance between the splenic pulp and the pulmonary thrombus might possibly suggest that the spleen is a reservoir of platelets and unable to dispose of them efficiently. On this supposition the administration of adrenaline may have released large numbers of platelets into the circulation, as the work of Bierman, Byron, and Kelly (1953) has shown its effect in producing splenic contraction, as well as releasing large numbers of platelets and leucocytes from the pulmonary circulation.

Summary

A case is presented reporting death from pulmonary thrombo-embolism in an elderly woman while she was undergoing a gastrectomy operation for a bleeding chronic ulcer. The thrombus was white and crumbly, and was shown to be mainly formed from platelets. This was the result of an unsuspected thrombocythaemia, and a similar case is cited from the literature. The presence of an abnormal spleen suggested that it might have acted as a reservoir for these platelets.

We wish to thank Mr. G. O. Jelly for permission to publish this case, and Dr. H. Russell for her advice. We are indebted to Dr. L. Bernstock for the preparation of platelets, E. H. Boulton, B.Sc., of the Chemistry Department, King's College, Durham University, for help with the electron microscopy, and Mr. R. Schofield and Mr. J. Higgins, of the Christie Hospital, for the photographic and histological preparations respectively.

REFERENCES

- Bierman, H. R., Byron, R. L. jr., and Kelly, K. H. (1953). *Blood*, **8**, 153.
Epstein, E., and Goedel, A. (1934). *Virchows Arch. path. Anat.*, **292**, 233.
Hardisty, R. M., and Wolff, H. H. (1955). *Brit. J. Haemat.*, **1**, 390.
Palade, G. E. (1952). *J. exp. Med.*, **95**, 285.
Stefanini, M., and Dameshek, W. (1955). *The Hemorrhagic Disorders*, p. 199. Grune and Stratton, New York and London.
———, Chatterjea, J. B., Adelson, E., and Mednicoff, I. B. (1953). *Blood*, **8**, 26.