

# Pulmonary blood flow after total cavopulmonary shunt

Andrew N Redington, Daniel Penny, Elliot A Shinebourne

## Abstract

The pattern of pulmonary blood flow was studied in three patients after a total cavopulmonary shunt procedure. Doppler studies showed a phasic pattern of flow which varied with the respiratory cycle. Pulmonary blood flow was increased with normal inspiration, and was much augmented by the Mueller manoeuvre. This suggests that flow was occurring when a negative intrathoracic pressure was generated. During a brief Valsalva manoeuvre blood flowed away from the lungs. With a sustained Valsalva manoeuvre there was no spontaneous forward flow; instead there was low velocity pulsatile pulmonary blood flow that coincided with ventricular systole. Left ventricular cavity dimensions decreased, reflecting a considerably reduced pulmonary blood flow.

Pulmonary blood flow after the total cavopulmonary shunt operation is critically dependant on changes in intrathoracic pressure. This has important implications in terms of the immediate postoperative management of these patients.

The total cavopulmonary shunt procedure was first performed by Kawashima and co-workers.<sup>1</sup> It is usually performed in patients with isomerism of the left atrial appendages and complex intracardiac abnormalities which

preclude a biventricular repair. Abnormalities of systemic venous drainage are common in these patients; there is usually no intrahepatic portion of the inferior vena cava and systemic venous blood from the lower body drains to a superior vena cava via an azygos or hemiazygos vein.<sup>2</sup> Anastomosis of the superior vena cava (or venae cavae) to the pulmonary arteries thus provides a "physiological" correction of the circulation. Unlike the Fontan procedure and its modification, however, the right side of the heart is completely bypassed, with only venous blood from the coronary sinus and liver draining directly to the atria. Thus pulmonary blood flow occurs without the direct influence of a pumping chamber between systemic veins and pulmonary artery. Despite the uniqueness of this circulation, there is little known about the pattern of pulmonary blood flow in these patients.<sup>3</sup>

We used Doppler echocardiography to show the pattern of pulmonary blood flow at rest. We also examined how changes in intrathoracic pressure induced by the Mueller and Valsalva manoeuvres affected this pattern.

## Patients and methods

Three patients were studied. The table shows the full sequential diagnosis, details of previous surgery, and anthropometric data for each patient. There was left atrial isomerism with complex intracardiac anomalies precluding a biventricular repair in all of the patients. Two had undergone previous aortic-to-

Full sequential diagnosis, anthropometric data, and details of previous surgery for each of the patients

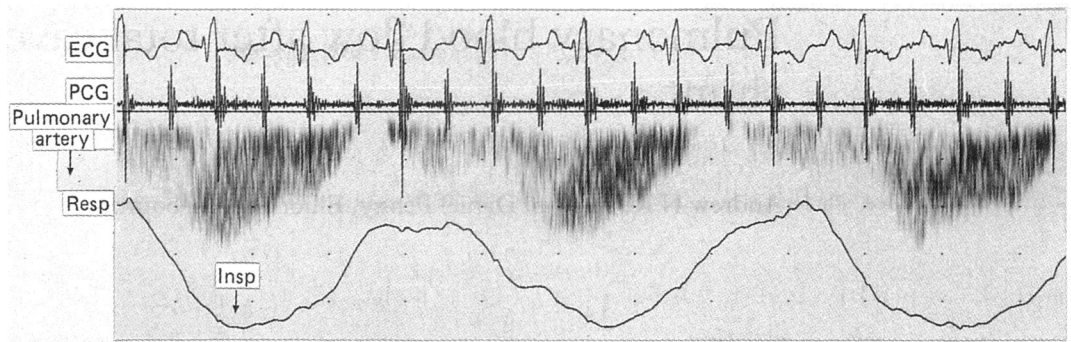
Data	Patient 1	Patient 2	Patient 3
Sex	Female	Female	Female
Date of birth	July 1983	June 1977	February 1976
Atrial situs	Left atrial isomerism	Left atrial isomerism	Left atrial isomerism
Systemic venous drainage	Hemiazygos continuation to left superior vena cava. Separate right superior vena cava	Azygos continuation to right superior vena cava. Left superior vena cava to innominate vein	Azygos continuation to right superior vena cava. Separate left superior vena cava
Atrioventricular connection	Double inlet right ventricle (common valve)	Double inlet left ventricle (common valve)	Double inlet left ventricle (common valve)
Ventriculoarterial connection	Double outlet right ventricle, pulmonary atresia	Double outlet left ventricle, pulmonary atresia	Concordant
Previous procedures	Modified left Blalock-Taussig shunt, right Glenn anastomosis	Classic right Blalock-Taussig shunt	Pulmonary artery banding, left Glenn anastomosis
Date of total cavopulmonary anastomosis	May 1986	February 1989	April 1990
Follow up	4 years	15 months	3 months

Department of Paediatric Cardiology, Royal Brompton National Heart and Lung Hospital, London  
A N Redington  
D Penny  
E A Shinebourne

Correspondence to Dr Andrew N Redington, Royal Brompton National Heart and Lung Hospital, Sydney Street, London SW3 6NP.

Accepted for publication 15 November 1990

**Figure 1** Pattern of pulmonary blood flow in one of the patients during normal spontaneous respiration. Blood flow was synchronous with respiration, increasing on inspiration. ECG, electrocardiogram; PCG, phonocardiogram; resp, respiratory motion trace; insp, inspiration. Velocity calibration interval 12.5 cm/s.



pulmonary shunt procedures; the other had had banding of the pulmonary artery (patient 3). Patients 1 and 3 had also undergone a bidirectional Glenn procedure (anastomosis of a separately draining superior vena cava to the contralateral pulmonary artery) before completion of the total cavopulmonary shunt. In none of the patients was there an intrahepatic portion of the inferior vena cava. The hepatic veins and coronary sinus drained directly to the right sided left atrium in all.

The postoperative course was uncomplicated in all of the patients. The mean hospital stay was nine days. At follow up all patients gave a history of mild cyanosis on exertion but were otherwise symptom free. All patients had normal atrioventricular synchrony with a normal PR interval on the resting electrocardiogram. The axis of the P wave was suggestive of an ectopic atrial focus in all of the patients, however, as is commonly the case in patients with left isomerism.

#### DOPPLER ECHOCARDIOGRAPHY

All patients were studied with a 5 MHz range gated pulsed wave Doppler imaging system (Toshiba Instruments). They were examined at least three hours after their last meal. Recordings were made with the patient lying at 45° with the neck slightly extended. Suprasternal cross sectional images of the cavopulmonary anastomosis were first obtained to ensure the smallest angle of incidence between blood flow and Doppler beam. Pulsed wave Doppler flow measurements were then recorded with the sample volume at the junction of the superior vena cava with the pulmonary artery in each patient. This site was chosen because flow in this region was laminar and the site of the anastomosis has a relatively fixed

cross sectional area. Thus changes in velocity can be assumed to represent changes in the volume of flow. In the two patients in whom both superior venae cavae were anastomosed separately, Doppler recordings were taken in the caval vein to which the azygos vein was connected. Doppler flow-velocity profiles were first recorded during spontaneous respiration and during held end tidal expiration. The patient was then asked to breathe through a mouthpiece that was connected to a valve which allowed rapid occlusion of the airway. The airway pressure was measured by an analogue pressure gauge (Bourdon Instruments), which could be seen by the patient. Doppler flow recordings were then made during several respiratory manoeuvres:

(a) Brief Valsalva manoeuvre—that is, intermittent forced expiration (at normal end tidal inspiration) with an open glottis but a closed airway, to a peak airway pressure of 25 cmH<sub>2</sub>O. Repeated after 3–5 seconds.

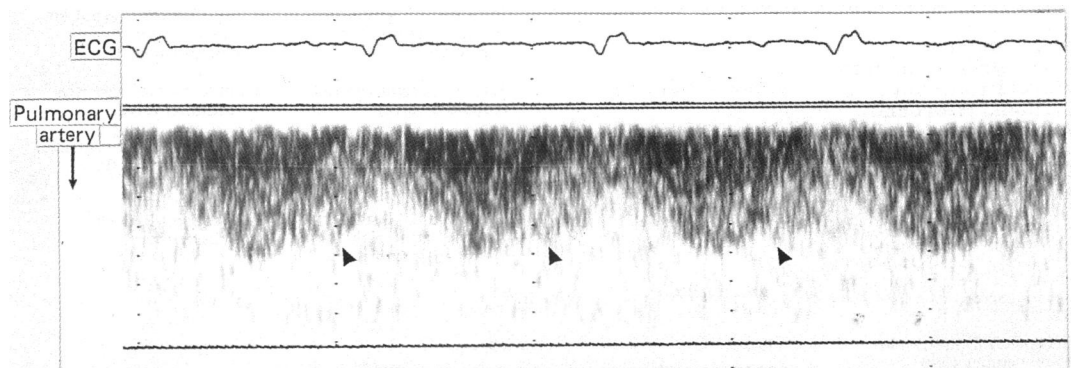
(b) Prolonged Valsalva manoeuvre—procedure as above, but the patient encouraged to maintain airway pressure at approximately 25–35 cmH<sub>2</sub>O for 20 seconds.

(c) Brief Mueller manoeuvre—that is, intermittent forced inspiration (at normal end tidal expiration) with open glottis but a closed airway, to reach a negative airway pressure of –25 cmH<sub>2</sub>O, followed by release. Repeated after 3–5 seconds.

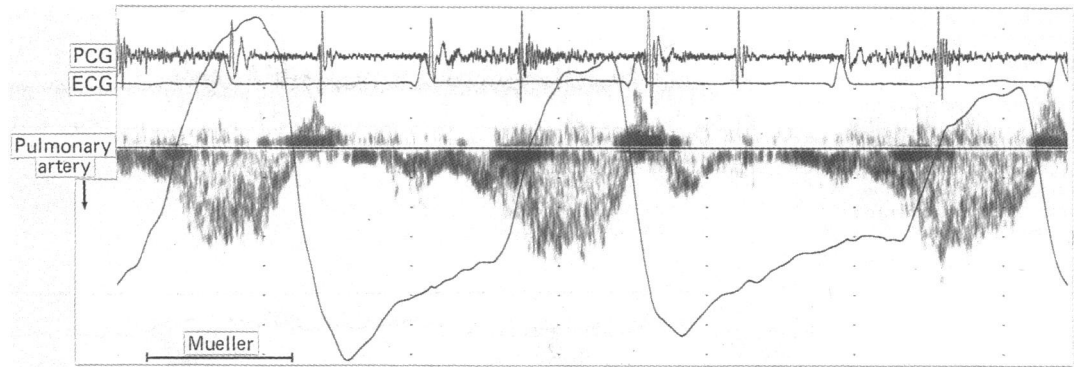
(d) Prolonged Mueller manoeuvre—as above, with the patient encouraged to maintain negative airway pressure of 25–35 cmH<sub>2</sub>O for 20 seconds.

In patients 2 and 3 we recorded an M mode echocardiogram of the left ventricle during a prolonged Valsalva manoeuvre. Cavity dimensions were measured from a parasternal

**Figure 2** Doppler recording of pulmonary blood flow at held end tidal expiration showing a biphasic pattern. Flow towards the lungs was increased during both ventricular and atrial systole (arrows mark onset of flow coinciding with atrial systole). ECG, electrocardiogram. Velocity calibration interval 12.5 cm/s.



**Figure 3** Recording of pulmonary blood flow during repeated brief Mueller manoeuvres in another patient. There was considerable augmentation of blood flow during the manoeuvres. In this patient inspiratory motion registered as an upward deflection on the respiratory motion trace. ECG, electrocardiogram; PCG, phonocardiogram. Velocity calibration interval 12.5 cm/s.



long axis section recorded at the level of the atrioventricular valve tips. Doppler inflow velocities across the common atrioventricular valve were also recorded at rest and during a prolonged Valsalva manoeuvre in these two patients. All measurements were made with a simultaneous electrocardiogram, phonocardiogram, and respiratory motion trace and recorded on paper at a speed of 50 or 100 mm per second.

### Results

The patterns of flow at rest and the effect of Mueller and Valsalva manoeuvres were similar in all of the patients.

#### NORMAL SPONTANEOUS RESPIRATION

Figure 1 shows the effect of normal respiration on pulmonary blood flow. There was a phasic variation of flow velocity that was synchronous with respiratory movements. With inspiration there was considerable augmentation of flow towards the lungs. At end inspiration (at the onset of active expiration) there was cessation of flow towards the lungs in two of the patients (fig 1) and considerable attenuation of flow in the other. During normal resting respiration there was no discernible influence of cardiac contraction on the pattern of pulmonary blood flow in any of the patients. The respiratory variation in flow was lost at held end tidal expiration. In one of the patients there was continuous low velocity non-phasic flow. In the other two patients the flow pattern could be related to the cardiac cycle. In one there was an increase in flow velocity during ventricular systole, and in

the other there was a biphasic pattern with an increase in flow velocity coincident with both ventricular and atrial systole (fig 2).

#### EFFECT OF THE MUELLER MANOEUVRE

Figure 3 shows the effect of repeated brief Mueller manoeuvres in one of the patients. There was considerable augmentation of flow towards the lungs during the manoeuvre in all of the patients. With a prolonged Mueller manoeuvre there was an initial surge of blood flow, followed by continuous, non-phasic flow towards the lungs. There was no phasic element to suggest any effect of cardiac contraction.

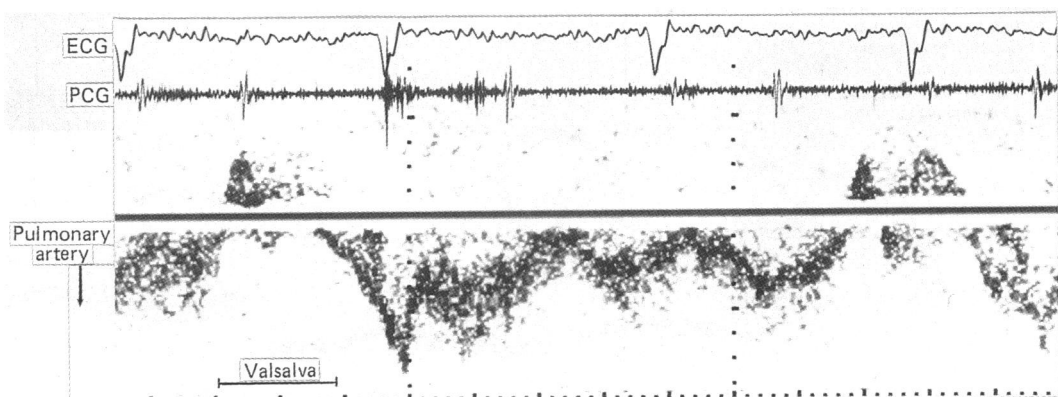
#### VALSALVA MANOEUVRE

There was retrograde flow (away from the lungs) in the superior vena cava in all of the patients during the brief Valsalva manoeuvre (fig 4). With the sustained Valsalva manoeuvre the pattern was quite different. Initially the direction of flow was away from the lungs, as in the brief manoeuvre. After 2–5 seconds phasic forward flow (towards the lungs) was established. Figure 5 shows this pattern. There was virtually no spontaneous flow into the pulmonary artery; the only forward flow occurred during ventricular systole. There was no separate diastolic component to forward flow. In each patient there was a surge of flow towards the lungs on release of the Valsalva manoeuvre.

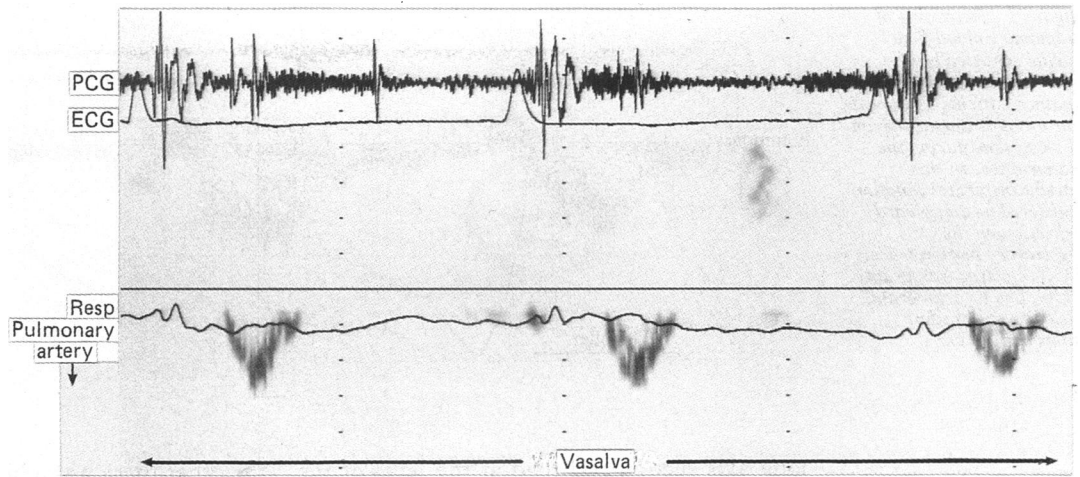
#### LEFT VENTRICULAR CAVITY DIMENSIONS

Left ventricular cavity dimensions were recorded at rest and during a prolonged Valsalva manoeuvre in two patients. There were similar

**Figure 4** Recording to show the effect of repeated brief Valsalva manoeuvres in patient 1. There was blood flow away from the lungs with each manoeuvre. ECG, electrocardiogram; PCG, phonocardiogram.



**Figure 5** Pulmonary blood flow during a prolonged Valsalva manoeuvre. Flow towards the lungs coincided with early ventricular systole. ECG, electrocardiogram; PCG, phonocardiogram; resp, respiratory motion trace. Velocity calibration interval 5 cm/s.



findings in both. Figure 6 shows that the cavity size was much reduced during the prolonged Valsalva manoeuvre in each of the patients. In the patient illustrated there was a dilated cavity with very incoordinate wall motion; cavity dimensions and basal wall motion were normal in the other patient. The end diastolic cavity dimension fell by 7 and 13 mm respectively during a prolonged Valsalva manoeuvre. Doppler inflow velocities recorded across the common atrioventricular valve were reduced in both, suggesting reduced flow. The ratio of the A wave to the E wave was unchanged, however.

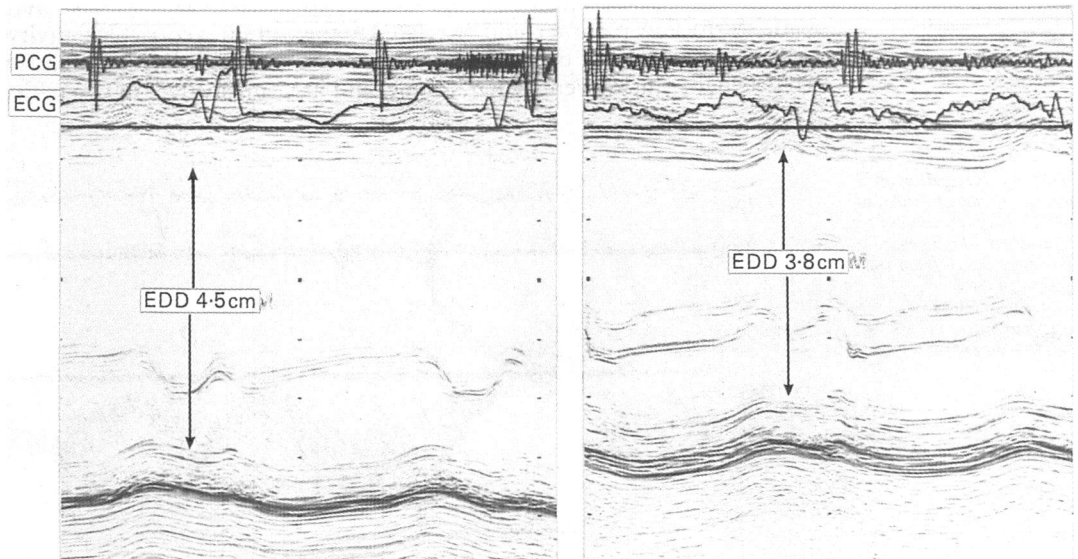
### Discussion

The total cavopulmonary shunt operation is an extracardiac procedure that provides a physiological "correction" of the circulation in children with complex congenital heart disease. It is usually performed when there is an interrupted inferior vena cava with return of venous blood from the lower body via an azygos or hemiazygos continuation to a superior vena cava. There is usually isomerism of the left atrial appendages with complex associated intracardiac anomalies that preclude a bi-ventricular repair in these patients.

Anastomosis of the distal superior vena cava (or venae cavae) end to side with the pulmonary artery thus directs most of the systemic venous return to the pulmonary vascular bed. Unlike the Fontan operation or its modifications,<sup>4,5</sup> the right atrium and ventricle are completely bypassed. There is therefore a unique opportunity to examine the factors that may influence pulmonary blood flow when there is no pumping chamber in the pathway between the systemic veins and the pulmonary artery.

It is clear from our study that respiratory movements have a major influence on pulmonary blood flow in these patients. At rest the flow in the superior vena cava towards the lungs is synchronous with and increased by inspiration. It is likely that the negative intrathoracic pressure generated during normal inspiration draws blood from the systemic venous reservoir towards the lungs. Certainly, this flow is considerably increased during the Mueller manoeuvre, when a much larger negative intrathoracic pressure is generated. When respiration was suspended at end expiration the respiratory variation in pulmonary blood flow, not surprisingly, was lost. In one patient there was continuous low velocity flow with no phasic element. In the other two, however, there was a

**Figure 6** M mode echocardiograms of the left ventricle recorded before (right hand panel) and during (left) a prolonged Valsalva manoeuvre. There was a considerable reduction in cavity dimension as a consequence of diminished pulmonary blood flow (see fig 5). ECG, electrocardiogram; PCG, phonocardiogram; EDD, end diastolic dimension.



phasic variation with the cardiac cycle. Flow towards the lungs occurred predominantly during ventricular systole, but in one of the patients there was a biphasic flow pattern with an increase in flow velocity occurring with atrial systole (fig 3). This latter observation confirms the findings of Miura and coworkers,<sup>3</sup> in the only other study of pulmonary blood flow in these patients. The effect of respiration was not specifically examined, but in their two patients examined after total cavopulmonary shunt operation there was a biphasic pattern of pulmonary blood flow at held end expiration. A biphasic pattern of pulmonary blood flow has also been shown in patients after the Fontan operation.<sup>6,7</sup> Similarly, the effects of respiration have not been specifically examined in these patients, but there is some evidence that pulmonary blood flow increases during inspiration in patients with an atriopulmonary anastomosis.<sup>8,9</sup>

There was an important, and potentially clinically significant, effect of the Valsalva manoeuvre in our patients. With a brief increase in intrathoracic pressure to 25 cmH<sub>2</sub>O there was a reversal of flow in the superior vena cava. That is, blood flowed away from the lungs. With the sustained Valsalva manoeuvre, spontaneous blood flow towards the lungs was abolished. There was, instead, a small amount of forward flow with each ventricular systole (fig 6). The considerable reduction in ventricular cavity size during this manoeuvre presumably reflects this reduction in pulmonary blood flow. The exact mechanism responsible for this pattern of flow is unknown, however. It is possible that it reflects the effects of a raised systemic venous pressure with an additional pulsatile element imposed by ventricular systole. Thus there is transmission of the arterial pulse to the venous system which overcomes the effects of the raised intrathoracic pressure—that is, blood is being pushed into the lungs. Alternatively, this pattern may occur as a consequence of a fixed intrathoracic volume. During ventricular systole blood leaves the thorax and so must be replaced, either from the hepatic veins (a limited blood reservoir) or via the systemic veins. We speculate therefore that this flow pattern may reflect physiology similar to that of the x descent of the jugular venous pressure pulse, flow in the pulmonary artery occurring during ventricular systole—that is, the blood is “pulled” into the lungs.

Whatever the mechanism these findings may have important clinical implications. In the immediate postoperative period these patients require positive pressure ventilation during their recovery from operation. It is likely that

any increase in mean airway pressure will decrease pulmonary blood flow. Indeed an important reduction in cardiac output with increasing values of positive end expiratory pressure has been shown in patients immediately after the Fontan operation.<sup>10</sup> It is therefore important to maintain the mean airway pressure as low as possible during the postoperative period in these patients. An alternative strategy might be to ventilate these patients with a negative extrathoracic pressure device. Our preliminary data suggest that this mode of ventilation may have two potential advantages. Firstly, the detrimental effects of positive pressure ventilation may be avoided. Secondly, because negative intrathoracic pressure is generated, pulmonary blood flow is augmented.<sup>11</sup>

In summary, pulmonary blood flow in patients after a total cavopulmonary shunt procedure is much influenced by respiratory movements. There is increased flow during normal inspiration, and this is augmented during the Mueller manoeuvre. The Valsalva manoeuvre, by producing a positive intrathoracic pressure, leads to a clinically significant reduction in pulmonary blood flow.

- 1 Kawashima Y, Kitamura S, Matsuda H, Shimazaki Y, Nakano S, Hirose H. Total cavopulmonary shunt operation in complex cardiac anomalies. A new operation. *J Thorac Cardiovasc Surg* 1984;87:74–81.
- 2 Rose V, Izukawa T, Moës CAF. Syndromes of asplenia and polysplenia. A review of cardiac and non-cardiac malformations in 60 cases with special reference to diagnosis and prognosis. *Br Heart J* 1975;37:840–52.
- 3 Miura T, Matsuda H, Nakano S, et al. Assessment of pulmonary blood flow after total cavopulmonary shunt operation and the modified Fontan procedure for univentricular heart. *J Cardiol* 1988;18:837–44.
- 4 Fontan F, Baudet E. Surgical repair of tricuspid atresia. *Thorax* 1971;26:240–8.
- 5 Gale AW, Danielson GK, McGoan DC, Mair DD. Modified Fontan operation for univentricular heart and complicated congenital lesions. *J Thorac Cardiovasc Surg* 1979;78:831–8.
- 6 DiSessa TG, Child JS, Perloff JK, et al. Systemic venous and pulmonary arterial flow patterns after Fontan's procedure for tricuspid atresia and single ventricle. *Circulation* 1984;70:898–902.
- 7 Nakazawa M, Nojima K, Okuda H, et al. Flow dynamics in the main pulmonary artery after the Fontan procedure in patients with tricuspid atresia and single ventricle. *Circulation* 1987;75:1117–23.
- 8 Hagler DJ, Seward JB, Tajik AJ, Ritter DG. Functional assessment of the Fontan operation: combined M-mode, two-dimensional and Doppler echocardiographic studies. *J Am Coll Cardiol* 1984;4:756–64.
- 9 Nakazawa M, Nakanishi T, Okuda H, et al. Dynamics of right heart flow in patients after Fontan procedure. *Circulation* 1984;69:306–12.
- 10 Williams DB, Keirnan PD, Metke MP, Marsh HM, Danielson GK. Hemodynamic response to positive end-expiratory pressure following right atrium-pulmonary artery bypass (Fontan procedure). *J Thorac Cardiovasc Surg* 1984;87:856–61.
- 11 Penny DJ, Hayek Z, Redington AN. The effect of positive and negative extrathoracic pressure on pulmonary blood flow after total cavopulmonary connexion. *Int J Cardiol* 1991;30:128–30.