

## CASE REPORTS

## Severe haemolysis after transcatheter duct occlusion: a non-surgical remedy

Alison M Hayes, A N Redington, M L Rigby

### Abstract

**Severe mechanical haemolysis occurred in a seven month old infant after the insertion of a 17 mm Rashkind double umbrella device. The placement of a second device 23 days after the initial procedure abolished haemolysis.**

Transcatheter occlusion with the Rashkind double umbrella device is now widely accepted as treatment for small and moderate sized arterial ducts. The reported complications include embolisation of the device, pseudo-coarctation, left pulmonary artery stenosis, residual shunts, and mechanical haemolysis.<sup>1-3</sup> We describe a case of severe mechanical haemolysis resulting from incomplete closure after placement of a 17 mm Rashkind occluder. Complete closure was achieved and the haemolysis ceased when a second 17 mm device was inserted.

### Case report

A seven month old infant was referred for cardiac assessment because of a cardiac murmur. The clinical findings were consistent with a persistent arterial duct. The chest radiograph showed cardiomegaly and pulmonary plethora. Cross sectional echocardiography confirmed the presence of a moderate sized persistent arterial duct with left ventricular volume overload. Cardiac catheterisation was performed when the child was 13 months old and weighed 10 kg. The preliminary aortogram showed a large arterial duct which was 6 mm in diameter. A 17 mm Rashkind double umbrella device was placed in a good position without difficulty. However, a further aortogram indicated some residual left to right flow through the duct, above the device (fig 1A). Doppler echocardiography 24 hours later confirmed a small residual shunt.

Two weeks later the child re-presented with pallor and a history of haematuria, jaundice, and vomiting. The haemoglobin was 54 g/l. Red cell fragments and polychromasia were noted on the blood film and the reticulocyte count was 23%. After a blood transfusion (haemoglobin 117 g/l) the haemolysis continued and there was further haemoglobinuria. Forty eight hours later the haemoglobin con-

centration had fallen to 95 g/l. Cross sectional echocardiography indicated appropriate placement of the original device, though the distal prongs could be seen projecting into the aorta. In view of continued severe haemolysis cardiac catheterisation was undertaken 23 days after the original procedure. The initial aortogram showed a large residual shunt through the duct. A second 17 mm Rashkind double umbrella was placed without complication (fig 1B). Initial Doppler studies after the procedure showed a trivial residual shunt which on review at one month had disappeared. There was no further haemolysis. The haemoglobin concentration one month after the second procedure was 131 g/l and the reticulocyte count was 0.8%.

### Discussion

There have been two previous reports of severe mechanical haemolysis after percutaneous transcatheter duct occlusion.<sup>2,3</sup> In one the device was removed surgically and the duct was ligated.<sup>2</sup> It was thought that the haemolysis in this patient, who also had a small "residual leak", may have been related to the poor position of the device, with the proximal arms impinging on the left pulmonary artery. This was not true of our patient. It is much more likely that red cell destruction was caused by a high velocity jet of blood passing over or through the device within the duct. Furthermore, because of the late presentation we were concerned that surgical removal might prove difficult and possibly require cardiopulmonary bypass. We therefore elected to place a second device. The placement of a second device for a residual left to right shunt has been described previously.<sup>1,4</sup> In the Toronto series 5.7% of patients required a second 12 mm double umbrella because of important residual flow after the initial procedure. Five of the six had successful reocclusion.

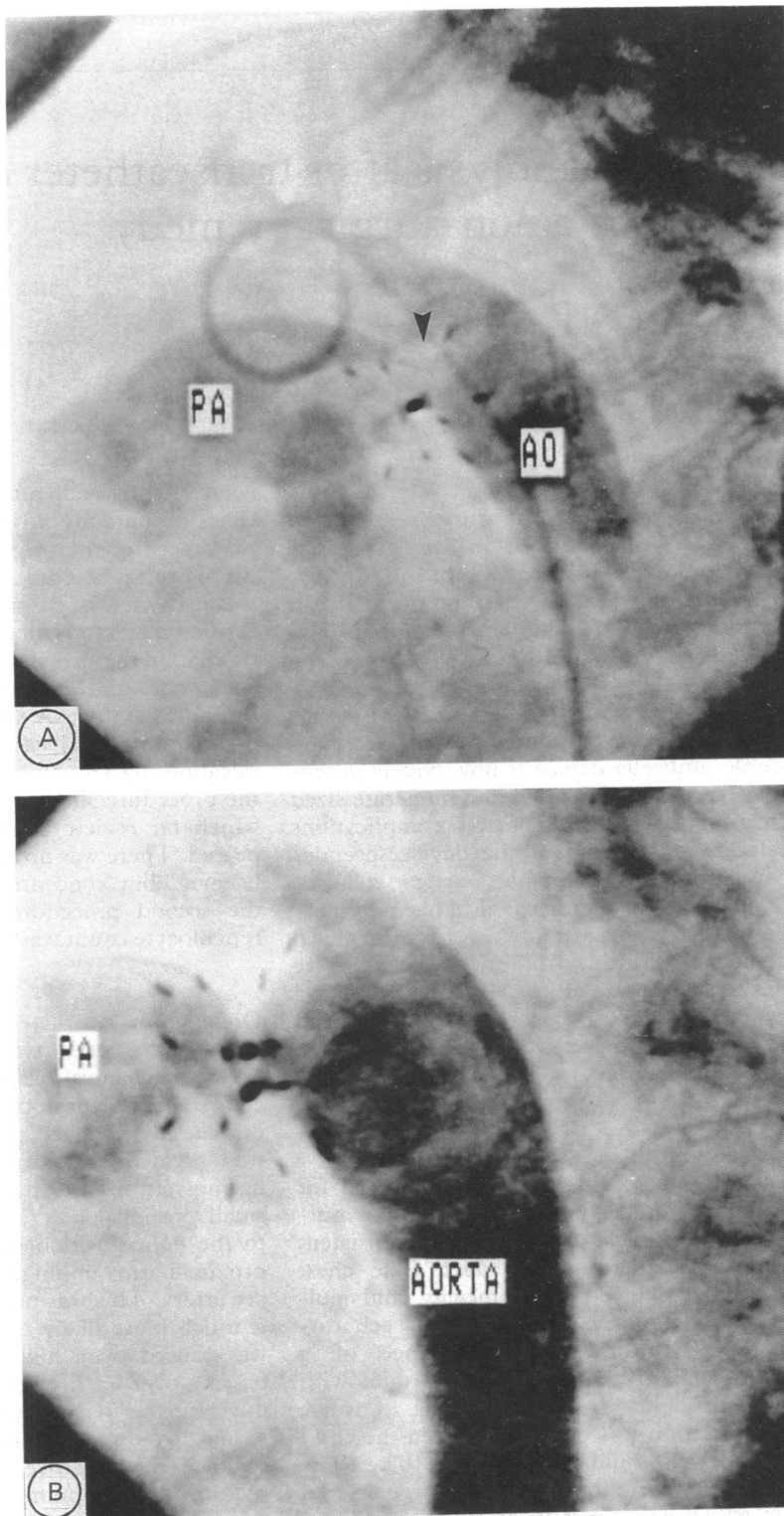
To our knowledge the successful use of a second umbrella to treat severe mechanical haemolysis has been reported only once before by Rohmer and colleagues when they described the initial experience of percutaneous duct occlusion in the Netherlands.<sup>3</sup> The second umbrella also promptly stopped the haemolysis.

Royal Brompton  
National Heart and  
Lung Hospital, London  
A M Hayes  
A N Redington  
M L Rigby

Correspondence to  
Dr Alison M Hayes, Royal  
Brompton National Heart  
and Lung Hospital, Sydney  
Street, London SW3 6NP

Figure (A) Aortogram showing satisfactory positioning of the first 17 mm device. There was a significant residual left to right shunt above the device (arrow).

(B) A further aortogram showing two 17 mm Rashkind double umbrellas positioned in the duct. At this stage, immediately after release of the second device, there was a small residual leak through the fabric of the umbrellas.



- 1 Rashkind WJ, Mullins CE, Hellenbrand WE, Tait MA. Nonsurgical closure of patent ductus arteriosus: clinical application of the Rashkind PDA Occluder System. *Circulation* 1987;75:583-92.
- 2 Ladusans EJ, Murdoch I, Franciosi J. Severe haemolysis after percutaneous closure of a ductus arteriosus (arterial duct). *Br Heart J* 1989;61:548-50.
- 3 Rohmer J, Hess J, Talsma MD. Closure of the persistent

ductus arteriosus (Botalli) using a catheter procedure; the initial 50 patients treated in The Netherlands. *Ned Tijdschr Geneesk* 1990;134:2347-51.

- 4 Hosking MC, Benson LN, Musewe N, Freedom RM. Reocclusion for persistent shunting after catheter placement of the Rashkind patent ductus arteriosus occluder. *Can J Cardiol* 1989;5:340-2.