

CASE REPORTS

Streptokinase treatment of a thrombosed Björk-Shiley prosthesis in the aortic position

Vivek K Mehan, Bharat V Dalvi, Purshottam A Kale

Abstract

Dysfunction of a mechanical prosthetic valve caused by thrombus formation is usually treated surgically. A patient with a thrombosed Björk-Shiley valve in the aortic position was treated successfully with intravenous streptokinase. The considerable improvement in the patient's clinical condition and the phonocardiographic, echocardiographic, and cinefluoroscopic evidence of normalisation of prosthetic valve function established the efficacy of thrombolytic therapy of a thrombosed prosthetic valve in this patient.

Thrombosis is a major complication of mechanical prosthetic valves, causing valve occlusion or systemic thromboembolism.^{1,2} The reported annual incidence of these complications was 5%.^{2,3} Surgery is the usual treatment in patients with prosthetic valve dysfunction caused by thrombosis: mortality is high.²⁻⁴ A few attempts to treat thrombosed prosthetic valves with thrombolytic agents have been successful.⁵⁻⁷ We report here a patient with a thrombosis of a Björk-Shiley prosthesis in the aortic position that responded to thrombolytic therapy.

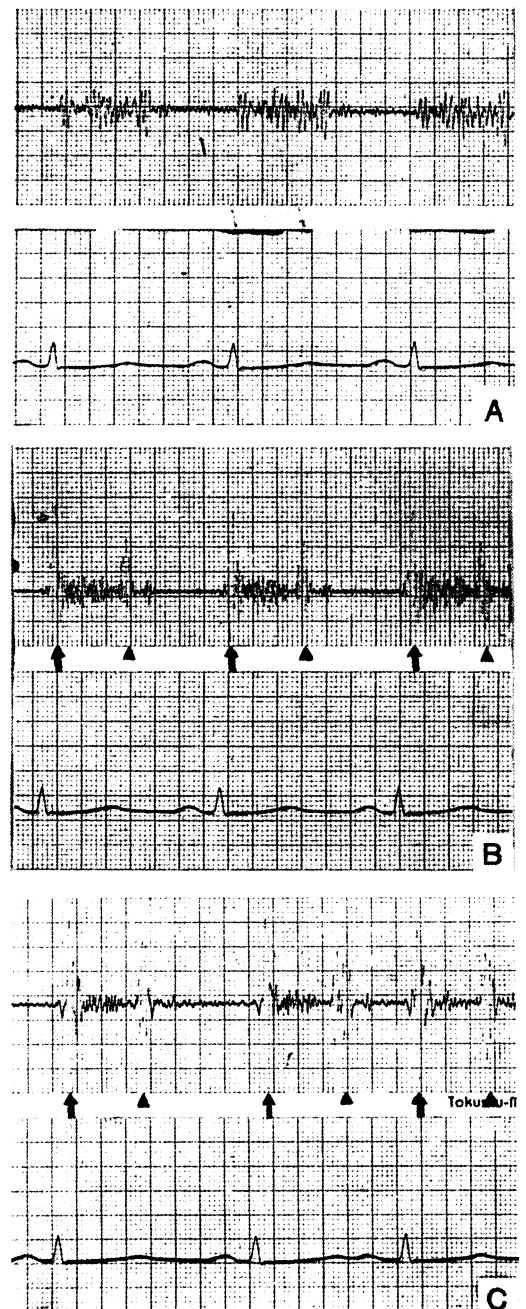
Case report

A 33 year old man had aortic valve replacement with a 23 mm planoconvex Björk-Shiley valve seven years before and he was adequately anticoagulated with warfarin 2.5 mg daily. He presented with a five day history of exertional dyspnoea (New York Heart Association class II) and reported that he could no longer hear the valve clicks. He had stopped taking warfarin three months before. He had a pulse rate of 100 per minute and a blood pressure when supine of 120/80 mm Hg. There was no evidence of heart failure or endocarditis. No prosthetic valve sounds were heard and a grade 3/6 aortic ejection murmur was present. The prothrombin time by Quick's one stage test was 13/12 seconds.

A cross sectional echocardiogram showed restricted mobility of the prosthetic valve disc with no clots or vegetations. Cinefluoroscopic examination showed that the prosthetic valve disc opened by only 20°. A phonocardiogram obtained with the transducer placed at the "aortic area" in the second right intercostal

space parasternally showed an aortic ejection murmur and no prosthetic valve sounds (fig 1A).

The patient was given 1.5 million units of streptokinase intravenously over 30 minutes,



Phonocardiograms recorded at the aortic area: (A) on admission, (B) two hours after treatment with streptokinase, and (C) six hours after treatment with streptokinase. The closing sounds (arrow heads) and opening sounds (arrows) of the prosthetic valve are indicated.

Department of
Cardiology, KEM
Hospital, Parel,
Bombay, India
V K Mehan
B V Dalvi
P A Kale

Correspondence to:
Dr Vivek K Mehan,
Department of Cardiology,
KEM Hospital, Parel,
Bombay 400 012, India.

followed by an infusion of heparin at the rate of 1000 units per hour for 24 hours to maintain the clotting time at one and a half times his basal clotting time (measured at the start of treatment), and aspirin (150 mg per day). Phonocardiographic recordings were obtained every hour with the microphone placed at the same position.

Two hours after treatment started the patient reported that he could hear faint valve sounds. Physical examination showed a decrease in the aortic ejection murmur and the closing sounds of the prosthetic valve were clearly audible. The phonocardiographic recording confirmed the findings (fig 1B). Six hours later the patient could clearly hear the prosthetic valve sounds "normally". At auscultation sharp opening and closing prosthetic valve sounds and a soft aortic ejection murmur were heard. The phonocardiogram confirmed these findings (fig 1C). A repeat cross sectional echocardiogram showed a normally functioning valve. Cinefluoroscopy showed that the prosthetic valve disc opened to a full 60°. The patient was symptom free on discharge and experienced no complications related to the streptokinase therapy.

At follow up one month later there was no evidence of a recurrence of thrombosis and the phonocardiographic, echocardiographic, and cinefluoroscopic findings remained normal.

Discussion

Although modern prosthetic heart valves are becoming less thrombogenic, thrombotic complications do occur.²⁻⁴

For aortic prosthetic valves (especially of the Björk-Shiley type) the wide variability of the ratio of the intensity of the opening and closing sounds makes clinical interpretation of this sign inaccurate.⁶ Phonocardiography provides one of the most reliable positive indices of a thrombosed prosthesis, especially when a previous phonocardiographic record is available for comparison.⁶ Cross sectional echocardiography and cinefluoroscopy are other non-invasive methods of confirming the diagnosis and monitoring the efficacy of thrombolytic therapy.

In this patient the complete absence of prosthetic valve sounds and development of exertional dyspnoea along with his history of not taking anticoagulant therapy pointed strongly to a diagnosis of prosthetic valve thrombosis. Serial phonocardiograms provided an objective index of thrombolysis (figure). Though the patient's symptoms were mild, there was every likelihood of life-threatening valve obstruction or systemic embolisation,¹⁶ so urgent intervention was warranted. When thrombolytic treatment is not effective, surgical intervention is indicated. In our patient streptokinase therapy was successful and the patient experienced complete relief of dyspnoea and the return of audible valve sounds. Potential complications of thrombolytic therapy include allergic reactions to streptokinase, haemorrhages owing to the systemic lytic state or systemic thromboembolism caused by loss of adhesion between a partially lysed thrombus and the prosthesis.⁸ Our patient experienced no complications of the thrombolytic therapy.

As thrombolytic agents become more potent, safe, and thrombus-specific, the need for surgical intervention for thrombotic complications of prosthetic valves should be reduced.

- 1 Kloster FE. Diagnosis and management of complications of prosthetic heart valves. *Am J Cardiol* 1975;35:872-85.
- 2 Brawley RK, Donahoo JS, Gott VL. Current status of the Beall, Björk-Shiley, Braunwald-Cutter, Lillehai-Kaster, and Smellof-Cutter cardiac valve prosthesis. *Am J Cardiol* 1975;35:855-65.
- 3 Ben-Zvi J, Hildner FJ, Chandraratna PA, Samet P. Thrombosis on Björk-Shiley aortic valve prosthesis. *Am J Cardiol* 1974;34:538-44.
- 4 Fernandes J, Damel J, Yang SS, et al. Late thrombosis of the aortic Björk-Shiley prosthesis. *Chest* 1976;70:12-6.
- 5 Inberg MV, Havia T, Arstila M. Thrombolytic treatment for thrombotic complications of valve prosthesis after tricuspid valve replacement. *Scand J Thorac Cardiovasc Surgery* 1977;11:195-8.
- 6 Witchitz S, Veyrat C, Moisson P, Scheinman N, Rozenstajn L, et al. Fibrinolytic treatment of thrombus on prosthetic heart valves. *Br Heart J* 1980;44:545-54.
- 7 Gagnon RM, Beaudet R, Lemire J, et al. Streptokinase thrombolysis of a chronically thrombosed mitral prosthetic valve. *Cathet Cardiovasc Diagn* 1984;10:5-10.
- 8 Kurzrok S, Singh AK, Most AS, Williams DO. Thrombolytic therapy for prosthetic cardiac valve thrombosis. *J Am Coll Cardiol* 1987;9:592-8.