

MEASUREMENT

Evaluation of aortic coarctation after surgical repair: role of magnetic resonance imaging and Doppler ultrasound

Eberhard G Mühler, Jörg M Neuerburg, Andreas Rüben, Ralf G Grabitz, Rolf W Günther, Bruno J Messmer, Götz von Bernuth

Abstract

Objective—To compare the usefulness of magnetic resonance imaging (MRI) and Doppler ultrasound with that of cross sectional echocardiography and oscillometric blood pressure measurement for the evaluation of aortic coarctation after surgical repair.

Design—Prospective study. Aortic diameters measured by cross sectional echocardiography, MRI, and angiography (selected cases) and functional data determined by physical examination, oscillometric blood pressure measurement, and continuous wave Doppler.

Setting—Tertiary referral centre.

Patients—40 patients aged 2–28 years (mean 10.6 years) who had had surgical correction of aortic coarctation (mean follow up 5.7 years).

Results—In all patients MRI gave diameter measurements of the aortic arch and the thoracic aorta whereas in half of them cross sectional echocardiographic measurement of the isthmic region failed. The correlation coefficient for aortic diameters measured by MRI and angiography was 0.97 and that between MRI and echocardiography was 0.89. Peak velocities in the descending aorta correlated better with residual narrowing of the aortic isthmus or distal aortic arch or both than systolic blood pressure gradients between the upper and lower limbs. A peak velocity of <2 m/s in the descending aorta during systole excluded important restenosis. Prolongation of anterograde blood flow during diastole always indicated a morphological abnormality—either important restenosis or aneurysmal dilatation.

Conclusions—MRI was better than cross sectional echocardiography for imaging the aortic arch after coarctation repair and measuring its diameter. Peak velocity in the descending aorta correlated better with residual stenosis than did the systolic blood pressure gradient between the upper and lower limbs and this index could be used to indicate a need for MRI.

Several types of operation have been developed but despite this long experience there is still controversy about which method is appropriate in an individual patient.¹⁻³ Obviously the choice requires detailed information on the morphological and functional state after surgical repair of aortic coarctation. Until now, retrograde aortic catheterisation with measurement of the intra-aortic pressure drop and angiography have been the standard methods of assessing the functional and morphological condition after coarctation repair. But this investigation is invasive and requires the use of x rays.

Cross sectional echocardiography from a suprasternal approach usually allows visualisation of the aortic arch and its branches and detects aortic coarctation.⁴⁻⁶ Image quality is often poor, however, (particularly in older patients) after coarctation repair because of the small acoustic window and the long distance between the transducer position and the isthmic region.^{7,8} Furthermore, assessment by ultrasound is disappointing because the acoustic window is inadequate when a prosthetic vascular conduit is used for surgical correction of coarctation.⁹ Recent studies cast doubt on the reliability of measurements of luminal diameter by cross sectional echocardiography without additional colour Doppler flow mapping, which enhances the contrast between the vessel lumen and its wall.¹⁰

Several groups have reported on the usefulness of MRI in detecting morphological anomalies of the great vessels, especially in aortic coarctation.¹¹⁻¹³

Diminished pulses in the lower limbs after coarctation repair suggests restenosis or persisting stenosis. Gradients can be measured from blood pressures in the upper and lower limbs. Flow velocities in the descending aorta distal and proximal to the isthmic region can be measured throughout the cardiac cycle by Doppler ultrasound and it has become clear that not only Doppler determined velocities in the descending aorta but also the flow profile are important in the assessment of the functional state after coarctation repair.¹⁴⁻¹⁶ We have evaluated whether the morphological situation after surgical repair of aortic coarctation can be properly demonstrated and measured by MRI and cross sectional echocardiography. We compared morphometric data with the functional data obtained by oscillometric measurement of blood pressure and Doppler ultrasound measurements.

Department of
Paediatric Cardiology,
Rheinisch-
Westfälische
Technische
Hochschule Aachen,
Germany
E G Mühler
A Rüben
R G Grabitz
G von Bernuth

Department of
Radiology, Rheinisch-
Westfälische
Technische
Hochschule Aachen,
Germany
J M Neuerburg
R W Günther

Department of
Thoracic and
Cardiovascular
Surgery, Rheinisch-
Westfälische
Technische Hochschule
Aachen, Germany
B J Messmer

Correspondence to:
Dr Eberhard G Mühler,
Department of Paediatric
Cardiology RWTH Aachen,
Pauwelsstrasse 30 5100
Aachen, Germany.

Accepted for publication
31 March 1993

(Br Heart J 1993;70:285-290)

There are now over 40 years of experience in the operative treatment of aortic coarctation.

Patients and methods

PATIENTS

Forty patients (28 male and 12 female; aged 2–28 years, mean 10.6 (5.0) were examined 5.7 (3.2) years (range 3 weeks–17 years) after surgical repair of aortic coarctation. Cineangiograms obtained before operation in all but one patient showed distinct hypoplasia of the distal aortic arch in 13 patients as well as localised coarctation of the isthmus. The following associated anomalies were present: patent ductus arteriosus ($n = 15$), bicuspid aortic valve ($n = 25$), aortic stenosis ($n = 10$), ventricular septal defect ($n = 7$), and mitral valve anomalies ($n = 14$). Twenty five patients underwent resection and end-to-end anastomosis of the coarctation, five patients had a subclavian flap angioplasty, and 10 had a graft patch angioplasty. At the time of investigation three patients with coarctation repair in the first year of life (end-to-end-anastomosis in two, patch graft aortoplasty in one) had already undergone reoperation because of recoarctation (patch graft aortoplasty in all).

In two of the 40 patients and in four additional patients with uncorrected coarctation, cineangiograms and magnetic resonance images were available for comparative measurements.

METHODS

Investigations included a physical examination, magnetic resonance imaging, cross sectional echocardiography of the aortic arch and the descending aorta, oscillometric blood pressure measurements of the upper and lower limbs, and recording the velocity flow profile in the descending aorta by Doppler ultrasound.

The magnetic resonance examinations were performed on an outpatient basis without sedation, except in the youngest patient who had a suspected aneurysmal dilatation. We used a superconductive magnetic resonance unit (Siemens, Magnetom) operating at 1.5 T to examine all the patients. T1 weighted images were obtained in a body coil except for the youngest patient. We used an ECG-gated single echo multislice spin echo technique. The repetition time ranged from 450 ms to 1100 ms depending on the heart rate. Magnetic resonance images were obtained in 3–6 mm contiguous transverse ($n = 40$), sagittal ($n = 35$), and rotated sagittal ($n = 36$) slices with echo times of 15 ms–28 ms. The total imaging time was 45 min–60 min. We used a 256×256 matrix with a field of view of 500×500 mm and a zoom factor of 1.4–1.8 (pixel size 1.1–1.4 mm). In each patient, the diameter of the aortic lumen was measured in all available planes distal to the innominate, the left carotid, and the left subclavian arteries in the isthmus region and at the diaphragmatic level. In six patients end diastolic diameters were also measured at corresponding levels on left anterior oblique or lateral angiograms and compared by linear regression analysis with the measurements derived from MRI. In 36 patients the aortic

arch was examined by cross sectional echocardiography from the suprasternal position with a mechanical sector scanner and a 5 MHz or 3.5 MHz transducer and simultaneous recording of the electrocardiogram. We measured the end diastolic luminal diameter of the aorta whenever possible distal to the innominate, left carotid, and left subclavian arteries and in the isthmus region (inner edge method). We used linear regression analysis to compare these data with those obtained by MRI. MRI and echocardiographic measurements were performed without knowledge of the dimensions obtained by the other method.

Systolic arm-to-leg blood pressure gradients were determined by the oscillometric method with cuffs of adequate size (Dinamap). In all but one patient with an aberrant right subclavian artery we used the right arm; leg pressure was measured on the side not used for previous retrograde arterial catheterisation. The systolic blood pressure difference was determined as the mean of three measurements for each limb. Systemic hypertension was diagnosed according to the guidelines of the second Task Force study.¹⁷

We used a 2.25 MHz continuous wave Doppler transducer in the suprasternal position to measure (without angle correction) the velocity flow profile in the descending aorta. The systolic peak velocity of blood flow was measured. The velocity profiles were also carefully examined for evidence of prolonged antegrade flow during diastole. To evaluate the surgical result we defined residual narrowing as a percentage reduction in the diameter of the aortic isthmus (Ao_{isth}) compared with the diameter of the descending aorta (Ao_{desc}) at diaphragmatic level ($(Ao_{desc} - Ao_{isth}) \times 100 / Ao_{desc}$) measured by MRI.

STATISTICAL ANALYSIS

To compare the morphological data obtained by MRI, cineangiography, and echocardiography we used linear regression analysis (Pearson method). We used a non-parametric test (Kruskal-Wallis) to compare MRI data with functional data obtained by Doppler ultrasound and oscillometric blood pressure measurements.

Results

MRI imaged the aortic arch and identified its major branches in all cases. Because we used different slice orientations (that is, transverse, sagittal, and parasagittal), partial volume effects could be minimised and we were able to measure the diameters of the isthmus, descending aorta, and aortic arch in all patients. Though the parasagittal planes proved to be the most valuable for assessing the morphology of the aortic arch and isthmus, we were able to image the complete aortic arch region in a single slice in only 13 patients because the aorta was curved in more than one plane.

Figure 1 shows the excellent correlation between the values of luminal diameter

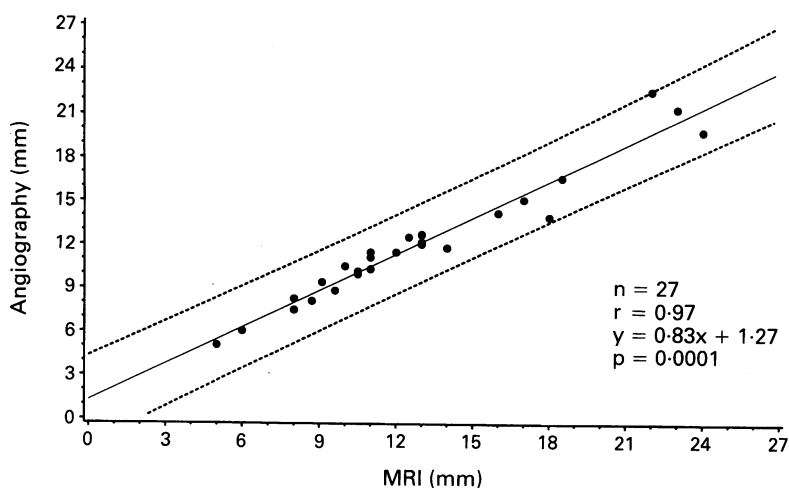


Figure 1 Linear regression of aortic diameters determined by angiography (end diastolic) and MRI in six patients with aortic coarctation (95% confidence interval is shown).

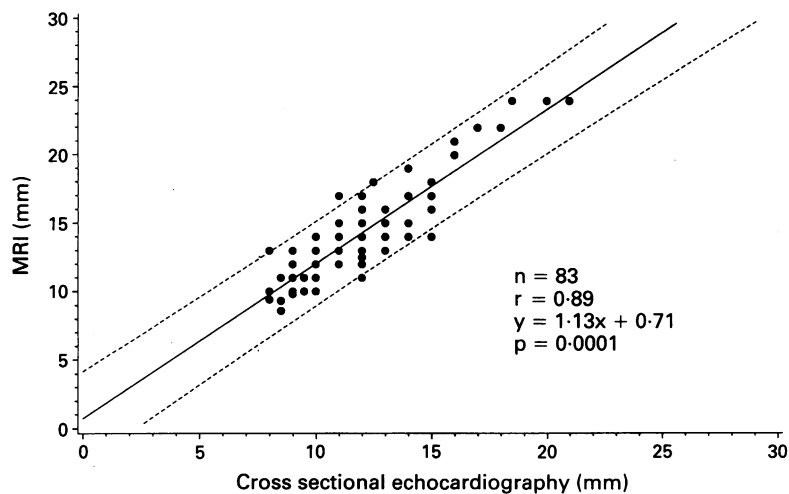


Figure 2 Linear regression of aortic diameters determined by MRI and cross sectional echocardiography (end diastolic) in 35 patients after coarctation repair (95% confidence interval shown).

obtained by MRI and angiography. In contrast to MRI, cross sectional echocardiography gave high resolution images of the aortic isthmus in only 18/36 patients whereas satisfactory images of the arch segments between the innominate and left subclavian artery were obtained in all but two patients. Figure 2 shows the linear correlation ($r = 0.89$) between measurements obtained by cross sectional echocardiography and the corresponding values obtained by MRI. The echocardiographic values were slightly lower than the MRI values in most cases, probably because of calibre differences related to the cardiac cycle. Most of the magnetic resonance images were obtained during mid-systole to early diastole, whereas all echocardiographic measurements were obtained at end diastole (onset of the R wave).

The surgical results were classified into three groups according to residual isthmic narrowing as measured by MRI and defined above: less than 10% diameter reduction ($n = 22$), 10–25% diameter reduction ($n = 12$), >25% diameter reduction ($n = 4$). These limits correspond to a reduction in cross sectional area of less than 20%, 20–45%, and more than 45%. Two patients had aneurysmal dilatation of the isthmus region: they are described separately.

As well as narrowing of the operated isthmic region, diameter reduction of the distal aortic arch seems to play an important part: the diameter of the distal aortic arch between the left carotid and the left subclavian artery was smaller than the diameter of the descending aorta in 21 patients and smaller than the isthmus diameter in 14 of them. In 10 of our 13 patients who had a hypoplastic aortic arch before operation, distal aortic arch values remained lower than those of the descending aorta (six end-to-end anastomoses, two patch grafts, and two subclavian flap aortoplasties).

To compare the morphological result with the functional state in operated coarctation we classified narrowing according to the smallest diameter, whether in the isthmus or in the distal aortic arch, in relation to the descending aorta. Table 1 shows the resulting groups. In five patients a small preisthmus arch segment led to a change of classification,—that is, from group 1 to 2 ($n = 4$) and from group 1 to 3 ($n = 1$). This classification of the morphological result was compared with the Doppler and blood pressure measurements and the result of the physical examination: Restenosis was suspected by physical examination in only two patients, both in group 3. Arterial hypertension of the upper limbs was present in 4/17, 5/16, and 3/5 patients of group 1, 2, and 3 respectively. Peak velocities in the descending aorta were significantly different in the three groups whereas blood pressure gradients did not show a significant difference between group 1 and 2 (table 2). Correlation between the morphological data (that is, percentage narrowing) and the functional data was better for Doppler measurements ($r = 0.65$; $p = 0.001$) than for oscillometric arm-to-leg gradients

Table 1 Morphological result determined by MRI

		Aortic isthmus		
Narrowing		<10%	10–25%	>25%
Aortic arch	<10%	17	8	1
	10–25%	4	4	1
	>25%	1	0	2
n = 38		22	12	4

- Group 1: Narrowing of the aortic arch and/or isthmus <10% ($n = 17$).
- Group 2: Narrowing of the aortic arch and/or isthmus 10–25% ($n = 16$).
- Group 3: Narrowing of the aortic arch and/or isthmus >25% ($n = 5$).

Table 2 A comparison between the morphological result and oscillometric blood pressure gradients and systolic peak flow velocities (mean (SD)) in the descending aorta

Narrowing (%)	Blood pressure gradient (mm Hg)	Peak velocity (m/s)
<10 (n = 17)	-0.8 (12.5)	1.98 (0.32)
10-25 (n = 16)	1.7 (9.1)	2.38 (0.37)
>25 (n = 5)	16.1 (15.6)	2.82 (0.14)

Between <10 and 10-25: NS (Blood pressure gradient), p < 0.01 (Peak velocity)
 Between 10-25 and >25: p < 0.05 (Blood pressure gradient), p < 0.03 (Peak velocity)
 Between <10 and >25: p < 0.04 (Blood pressure gradient), p < 0.001 (Peak velocity)

($r = 0.48$; $p = 0.002$). There was considerable overlap between systolic blood pressure differences in each of the three groups. Only two patients, both in group 3 and with clinical signs of restenosis, had systolic arm-to-leg blood pressure differences of more than 20 mm Hg. Whereas there were differences in blood pressure as low as -6 mm Hg in group 3 and as high as +18 mm Hg in group 1.

Doppler ultrasound investigations showed that the systolic peak flow velocity in the descending aorta exceeded 1.4 m/s in all patients. Peak flow velocities were less than 2 m/s in 11 patients in group 1 with an excellent morphological result (fig 3) and in two further patients in group 2.

On the other hand, increased peak flow velocity alone did not always separate patients with significant narrowing from those without. Peak velocities of more than 2 m/s (maximum 2.6 m/s) were found in six

patients who had an excellent morphological result (group 1). Peak velocity exceeded 2 m/s in all but two patients in group 2 (maximum 3.0 m/s). Systolic peak velocity exceeded 2.6 m/s in all five patients in group 3.

In all patients in groups 1 and 2 the velocity flow profiles were strictly limited to systole. In contrast, two patients in group 3 and in addition the two patients with aneurysmal dilatation showed prolongation of antero-grade blood flow during diastole (fig 4).

Discussion

Cross sectional echocardiography, which is the best method of recognising intracardiac structural anomalies, certainly has limitations in patients with aortic coarctation. Though high resolution images of the aortic arch can be obtained that correlate well with angiographic measurements, the aortic isthmus, the region of interest in surgically corrected coarctation, cannot be measured or even qualitatively examined in many, especially older, patients. In our study the imaging quality was acceptable for luminal diameter measurements in only half of the patients. This accords with earlier studies.^{7,8,18}

MRI gives an excellent natural contrast between flowing blood and the vessel wall. In contrast to ultrasound, MRI allows imaging of the thoracic aorta independently of an acoustic window and there is no limitation of imaging planes. Many have reported on the

Figure 3 Coarctation 8 years after end-to-end anastomosis. (A) Magnetic resonance image of the aortic arch is visualised in a single parasagittal plane. (B) Continuous wave Doppler flow profile suggests an excellent postoperative result which accords with the MRI result.

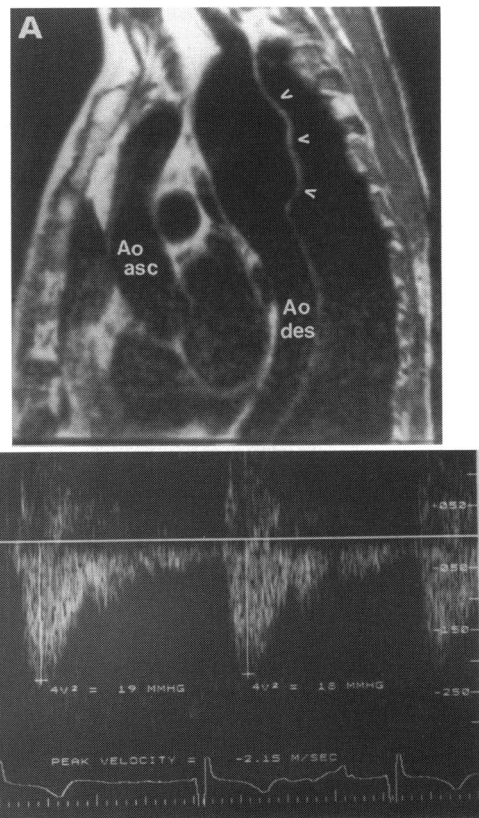
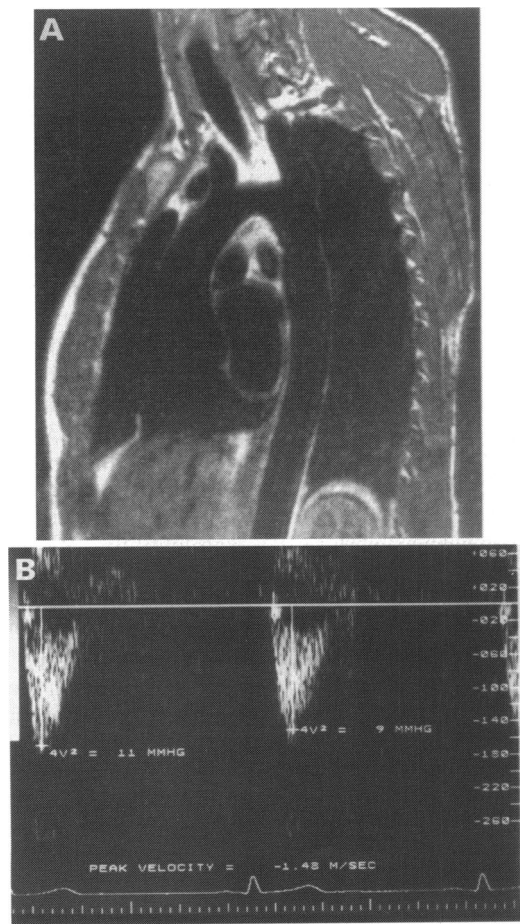
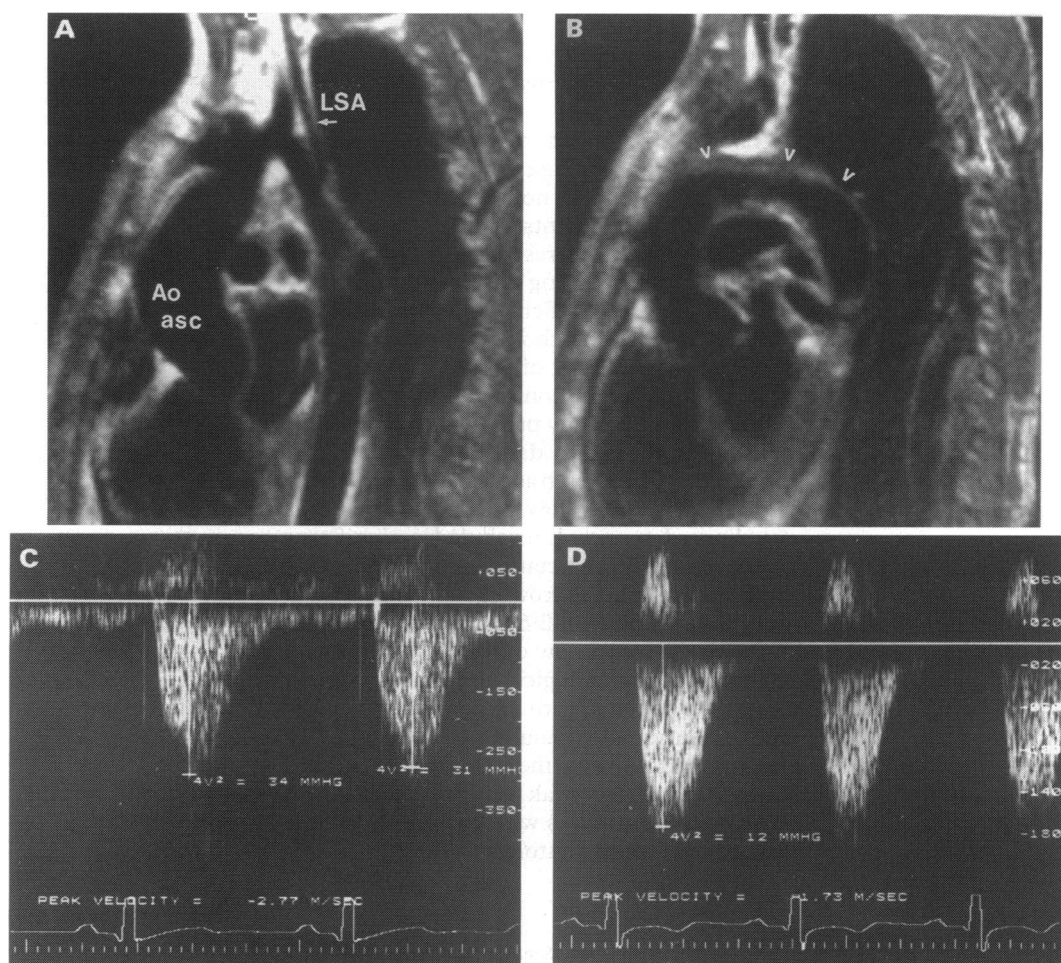


Figure 4 (A) Magnetic resonance image of large aneurysm 17 years after patch graft aortoplasty. (B) Continuous wave Doppler investigation showed an abnormal antero-grade flow during diastole in the descending aorta. (Ao asc, ascending aorta, Ao des descending aorta. Arrows indicate the aneurysm).

Figure 5 (A and B) Magnetic resonance images of a patient three months after repair (prosthetic tube graft bypass from the ascending to the descending aorta) of restenosis (44% diameter reduction) associated with considerable hypoplasia of the distal aortic arch 11 years after end-to-end-anastomosis. (C) Preoperative continuous wave Doppler echocardiogram showing a high systolic blood flow velocity and an abnormal diastolic flow profile suggesting restenosis. Incorporation of V_1 into the Bernoulli equation incorrectly reduced the determined gradient from 34 to 8 mm Hg (corresponding invasive peak-to-peak gradient = 40 mm Hg) because there was hypoplasia of the distal aortic arch. (D) Postoperative continuous wave Doppler echocardiogram of the descending aorta showing that the flow profile had been restored to normal (Ao asc, ascending aorta; LSA, left subclavian artery). The arrows indicate the tube graft.



usefulness of MRI investigation of the aorta in untreated coarctation,^{12,19} operated coarctation,^{17,20,21} or angioplasty treated coarctation,^{11,22} but only a few studies compared MRI measurements of luminal diameter with angiographic measurements.^{7,8,23} We found an excellent correlation between MRI and angiographically determined aortic diameters, as have others.⁷ In our experience, correct measurement of aortic luminal diameters that avoids partial volume effects requires at least two imaging planes (axial and parasagittal or sagittal) with adequate slice thickness. The unexpected high discordance between angiographic and MRI measurements reported in a previous study⁸ is probably due to inadequate slice thickness and partial volume effects.

Doppler ultrasound has been widely used to assess native and operated aortic coarctation. Continuous wave Doppler examination from the suprasternal position allows a simple measurement of the maximal blood flow velocity in the descending aorta. Variation of the angle between the ultrasound beam and the direction of the jet flow leads to underestimation of the true velocity. Up to an angle of 25° the error is less than 10%²⁴ but the true velocity is overestimated if mathematical correction for the apparent cosine is applied.²⁵ There are several reports of considerable overestimation of Doppler gradients in surgically corrected coarctation, when the simplified Bernoulli equation ($4v_2^2$) was used.^{14,26,27}

Aldousany *et al* pointed out, that prestenotic velocity is usually increased in patients with treated coarctation and therefore cannot be neglected in calculations of pressure drops.¹⁵ Though we measured prestenotic velocities in the distal aortic arch in only a few patients, we believe that the morphological result correlates simply with the maximal velocity measured in the descending aorta. Firstly, MRI showed that narrowing of the aortic arch was a common and important factor. In 21/40 patients the diameter of the distal aortic arch was smaller than that of the descending aorta and in 14 it was smaller than the diameter of the isthmus. In these patients increased prestenotic velocity (v_1) had a morphological basis. Consequently, incorporation of this "prestenotic" velocity in the Bernoulli equation leads to underestimation of gradients (fig 5). Secondly, sharper angulation of the aortic arch after resection and end to end-anastomosis without narrowing may cause flow acceleration and a pressure drop.²⁸ Thirdly, magnetic resonance velocity mapping in the aorta showed skewed cross sectional flow profiles which makes interpretation of a single point flow measurement in a vessel at a given level with a pulsed Doppler system liable to error.²⁹

The severity of vessel stenosis influences not only the peak systolic velocity but also the flow profile during the cardiac cycle. Experimental studies showed that antero-grade flow during diastole was prolonged by

increasing stenosis.²⁴ Recent studies reported a 90–100% specificity for severe coarctation when important flow was maintained during diastole.^{14,16}

Though prolonged diastolic flow always indicated a morphological abnormality in our study, this index was not specific for relevant restenosis: two patients with severe aneurysmal dilatation both presented with prolonged anterograde flow during diastole (fig 4).

MRI allowed excellent visualisation of the aortic arch and the thoracic aorta with reliable measurement of luminal diameter whereas cross sectional echocardiography failed in half the study patients. A comparison of the morphometric data obtained by MRI with the Doppler ultrasound measurements showed that blood flow velocities less than 2 m/s limited to systole excluded a significant restenosis after coarctation repair. None of our patients with narrowing >25% had peak velocities of less than 2.6 m/s. Prolongation of anterograde blood flow during diastole always indicated a morphological abnormality. It was found in patients with important restenosis and aneurysmal dilatation. Therefore we recommend MRI in the patient with treated coarctation if the peak velocity exceeds 2.6 m/s and in all patients with prolonged antero- grade flow during diastole.

- 1 Koller M, Rothlin M, Senning A. Coarctation of the aorta: review of 362 operated patients. Long-term follow-up and assessment of prognostic variables. *Eur Heart J* 1987;8:670–79.
- 2 Hehrlein FW, Mulch J, Rautenburg HW, Schlepper M, Scheld HH. Incidence and pathogenesis of late aneurysms after patch graft aortoplasty for coarctation. *J Thorac Cardiovasc Surg* 1986;92:226–30.
- 3 Trinquet F, Vouhé PR, Vernant F, Touati G, Roux PM, Pome G, Leca F, Neveux JY. Coarctation of the aorta in infants: which operation? *Ann Thorac Surg* 1988;45:186–91.
- 4 Huhta JC, Gutgesell HP, Latson LA, Huffines FD. Two-dimensional echocardiographic assessment of the aorta in infants and children with congenital heart disease. *Circulation* 1984;70:417–24.
- 5 Glasow PF, Huhta JC, Yoon GY, Murphy Jr DJ, Danford DA, Ott DA. Surgery without angiography for neonates with aortic arch obstruction. *Int J Cardiol* 1988;18:417–25.
- 6 Sahn DJ, Allen HD, McDonald G, Goldberg SJ. Real-time cross-sectional echocardiographic diagnosis of coarctation of the aorta. *Circulation* 1977;56:762–9.
- 7 Simpson IA, Chung KJ, Glass RF, Sahn DJ, Sherman FS, Hesselink J. Cine magnetic resonance imaging for evaluation of anatomy and flow relations in infants and children with coarctation of the aorta. *Circulation* 1988;78:142–8.
- 8 Stern HC, Locher D, Wallnöfer K, Weber F, Scheid KF, Emmrich P, Bühlmeier K. Noninvasive assessment of coarctation of the aorta: comparative measurements by two-dimensional echocardiography, magnetic resonance, and angiography. *Pediatr Cardiol* 1991;12:1–5.
- 9 Pucillo AL, Schechter AG, Kay RH, Herman MV. Magnetic resonance imaging of vascular conduits in coarctation of the aorta. *Am Heart J* 1989;117:482–5.
- 10 Simpson IA, Sahn DJ, Valdes-Cruz LM, Chung KJ, Sherman FS, Swenson RE. Color doppler flow mapping in patients with coarctation of the aorta: new observations and improved evaluation with color flow diameter and proximal acceleration as predictors of severity. *Circulation* 1988;77:736–44.
- 11 Boxer RA, Lacorte MA, Singh S, Cooper R, Fishman MC, Goldman M, Stein ML. Nuclear magnetic resonance imaging in evaluation and follow-up of children treated for coarctation of the aorta. *J Am Coll Cardiol* 1986;7:1095–8.
- 12 Baker EJ, Ayton V, Smith MA, Parsons JM, Maisey MN, Ladusans EJ, Anderson RH, Tynan M, Yates AK, Deverall PB. Magnetic resonance imaging of coarctation of the aorta in infants: use of a high field strength. *Br Heart J* 1989;62:97–101.
- 13 Parsons JM, Baker EJ, Hayes A, Ladusans EJ, Qureshi SA, Anderson RH, Maisey MN, Tynan M. Magnetic resonance imaging of the great arteries in infants. *Int J Cardiol* 1990;28:73–85.
- 14 Rao PS, Carey P. Doppler ultrasound in the prediction of pressure gradients across aortic coarctation. *Am Heart J* 1989;118:299–307.
- 15 Aldousany AW, DiSessa TG, Alpert BS, Birnbaum SE, Willey ES. Significance of the Doppler-derived gradient across a residual aortic coarctation. *Pediatr Cardiol* 1990;11:8–14.
- 16 Carvalho JS, Redington AN, Shinebourne EA, Rigby ML, Gibson D. Continuous wave Doppler echocardiography and coarctation of the aorta: gradients and flow patterns in the assessment of severity. *Br Heart J* 1990;64:133–7.
- 17 Report of the second Task Force on blood pressure control in children—1987. *Pediatrics* 1987;79:1–25.
- 18 Rees S, Somerville J, Ward C, Martinez J, Mohiaddin RH, Underwood R, Longmore DB. Coarctation of the aorta: MR imaging in late postoperative assessment. *Radiology* 1989;173:499–502.
- 19 Nyman R, Hallberg M, Sunnegaerdh J, Thuren J, Henze A. Magnetic resonance imaging and angiography for the assessment of coarctation of the aorta. *Acta Radiol* 1989;30:481–5.
- 20 Huysmans HA, Kappetein AP. Late follow-up after resection of aortic coarctation. *Z Kardiol* 1989;78:39–41.
- 21 Kaemmerer H, Theissen P, König U, Kochs M, Linden A, Höpp HW, Sechtem U, Hilger HH. Klinische und magnetresonanztomographische Verlaufskontrollen operativ behandelte Aortenisthmusstenosen im Erwachsenenalter. *Z Kardiol* 1989;78:777–83.
- 22 Soulen RL, Kan J, Mitchell S, White RI. Evaluation of balloon angioplasty of coarctation restenosis by magnetic resonance imaging. *Am J Cardiol* 1987;60:343–5.
- 23 Bank ER, Aisen AM, Rocchini AP, Hernandez RJ. Coarctation of the aorta in children undergoing angioplasty: pretreatment and posttreatment MR imaging. *Radiology* 1987;162:235–40.
- 24 Faccenda F, Usui Y, Spencer MP. Doppler measurement of the pressure drop caused by arterial stenosis: an experimental study: a case report. *Angiology* 1985;36:899–905.
- 25 Bibra von H, Stempfle HU, Poll A, Scherer M, Renner U, Moravec S, Blüml G, Blömer H. Genauigkeit verschiedener Dopplertechniken in der Erfassung von Flussgeschwindigkeiten. Untersuchungen in vitro. *Z Kardiol* 1990;79:73–82.
- 26 Houston AB, Simpson IA, Pollock JCS, Jamieson MPG, Doig WB, Coleman EN. Doppler ultrasound in the assessment of severity of coarctation of the aorta and interruption of the aortic arch. *Br Heart J* 1987;57:38–43.
- 27 Barth H, Schmaltz AA, Steil E, Apitz J. Die quantitative Beurteilung von Linksherzobstruktionen (incl. Aortenisthmusstenose) bei Kindern mittels Dopplerechokardiographie. *Z Kardiol* 1986;75:231–6.
- 28 Leval de MR, Kilner P, Gewillig M, Bull C. Total cavopulmonary connection: a logical alternative to atric-pulmonary connection for complex Fontan operations. *J Thorac Cardiovasc Surg* 1988;96:682–95.
- 29 Klipstein RH, Firmin DN, Underwood SR, Rees RSO, Longmore DB. Blood flow patterns in the human aorta studied by magnetic resonance. *Br Heart J* 1987;58:316–23.