



Published in final edited form as:

J Hum Genet. 2022 February ; 67(2): 95–101. doi:10.1038/s10038-021-00971-5.

Major brain malformations: corpus callosum dysgenesis, agenesis of septum pellucidum and polymicrogyria in patients with *BCORL1*-related disorders

Michal Gafner^{1,2,13}, Marina Michelson^{2,3,4,13}, Emanuela Argilli^{5,6}, Keren Yosovich^{2,3,7}, Elliott H. Sherr^{5,6}, Kendall C. Parks^{5,6}, Eleina M. England⁸, Ronen Hady-Cohen^{2,3,9}, Zvi Leibovitz^{10,11}, Dorit Lev^{2,3,4}, Yael Michaeli-Yosef^{2,3,9}, Tally Lerman-Sagie^{2,3,9}, Lubov Blumkin^{2,3,9,12,✉}

¹Department of Pediatrics B, Schneider Children's Medical Center of Israel, Petach Tikva, Israel.

²Sackler Faculty of Medicine, Tel Aviv University, Tel Aviv, Israel.

³Magen Center for Rare Diseases, Wolfson Medical Center, Holon, Israel.

⁴The Rina Mor Institute of Medical Genetics, Wolfson Medical Center, Holon, Israel.

⁵Department of Neurology, University of California, San Francisco, San Francisco, CA, USA.

⁶Institute of Human Genetics and Weill Institute for Neurosciences, University of California, San Francisco, San Francisco, CA, USA.

⁷Molecular Genetics Laboratory, Wolfson Medical Center, Holon, Israel.

⁸Center for Mendelian Genomics, Broad Institute of MIT and Harvard, Cambridge, MA, USA.

⁹Pediatric Neurology Unit, Wolfson Medical Center, Holon, Israel.

¹⁰Fetal Neurology Clinic, Wolfson Medical Center, Holon, Israel.

¹¹Obstetrics-Gynecology Ultrasound Unit, Rappaport Faculty of Medicine, Bnai-Zion Medical Center, The Technion, Haifa, Israel.

¹²Pediatric Movement Disorders Service, Wolfson Medical Center, Holon, Israel.

¹³These authors contributed equally: Michal Gafner, Marina Michelson

Reprints and permission information is available at <http://www.nature.com/reprints>

✉ Correspondence and requests for materials should be addressed to L.B., luba.blumkin@gmail.com.

AUTHOR CONTRIBUTIONS

All authors contributed to the study conception and design. All authors read and approved the final paper and agree to be accountable for all aspects of the work. MG—data curation; writing—original draft. MM—data curation; writing—original draft. EA—data curation. KY—formal genetic analysis. EHS—data curation. KCP—data curation. EME—data curation. RHC—conceptualization. ZL—conceptualization. DL—conceptualization, formal genetic analysis. YMY—conceptualization, formal genetic analysis. TLS—conceptualization, writing—review and editing, supervision. LB—Conceptualization, writing—review and editing, supervision.

COMPETING INTERESTS

The authors declare no competing interests.

CONSENT FOR PUBLICATION

Informed consent for publication was obtained from participants and their parents.

ETHICS APPROVAL AND CONSENT TO PARTICIPATE

The study was approved by the institutional review board [0075–17WOMC]. Informed consent to participate in the study was obtained from legal guardians.

Abstract

OBJECTIVE: *BCORL1*, a transcriptional co-repressor, has a role in cortical migration, neuronal differentiation, maturation, and cerebellar development. We describe *BCORL1* as a new genetic cause for major brain malformations.

METHODS AND RESULTS: We report three patients from two unrelated families with neonatal onset intractable epilepsy and profound global developmental delay. Brain MRI of two siblings from the first family depicted hypoplastic corpus callosum and septal agenesis (ASP) in the older brother and unilateral perisylvian polymicrogyria (PMG) in the younger one. MRI of the patient from the second family demonstrated complete agenesis of corpus callosum (CC). Whole Exome Sequencing revealed a novel hemizygous variant in NM_021946.5 (*BCORL1*):c.796C>T (p.Pro266Ser) in the two siblings from the first family and the NM_021946.5 (*BCORL1*):c.3376G>A; p.Asp1126Asn variant in the patient from the second family, both variants inherited from healthy mothers. We reviewed the patients' charts and MRIs and compared the phenotype to the other published *BCORL1*-related cases. Brain malformations have not been previously described in association with the *BCORL1* phenotype. We discuss the potential influence of *BCORL1* on brain development.

CONCLUSIONS: We suggest that *BCORL1* variants present with a spectrum of neurodevelopmental disorders and can lead to major brain malformations originating at different stages of fetal development. We suggest adding *BCORL1* to the genetic causes of PMG, ASP, and CC dysgenesis.

INTRODUCTION

BCORL1 (*BCL6 co-repressor-like 1* gene, (OMIM 300688) is located on chromosome Xq26.1 and expressed in the brain and other tissues [1]. In 2018, Shukla et al. described five patients with an X-linked disorder of intellectual disability, dysmorphic features, and behavioral abnormalities associated with variants in *BCORL1* [2]. This syndrome was named Shukla-Vernon syndrome (OMIM 301029).

So far ten patients have been reported harboring *BCORL1* pathogenic variants [1–4]. Four had early onset epilepsy, eight intellectual disability of variable severity, and six autistic spectrum disorder. Some of the children had dysmorphic facial features (Table 1). Mild manifestations such as learning difficulties were reported in carrier females. A brain MRI was reported in only 4/10 patients, and cerebellar atrophy was described in two; a major brain malformation has not been described [2].

We describe three patients from two unrelated families with two novel variants of unknown significance (VUS) in *BCORL1* who manifested neonatal onset intractable epilepsy and profound developmental delay consistent with a developmental and epileptic encephalopathy in accordance with ILAE criteria [5]. Brain MRI in two siblings depicted major malformations originating at different stages of fetal brain development: hypoplastic corpus callosum (CC) and septal agenesis (ASP) in the older brother, and unilateral opercular polymicrogyria (PMG) in the younger one. MRI of the patient from the second family demonstrated complete agenesis of the corpus callosum.

MATERIAL AND METHODS

We reviewed the patients' medical records and postnatal MRIs. The study was approved by the institutional review board [0075–17WOMC].

Genetic studies

Genomic DNA was extracted from peripheral blood by the QIAamp DNA Mini kit (QIAGEN), according to the manufacturers' instructions.

Quartet Whole exome sequencing was performed on the DNA of both patients and their parents. The samples were enriched with Twist Human Core Exome Plus Kit (Twist Bioscience). Sequencing was carried out on NovaSeq 6000 (Illumina, San diego, CA, USA) as 100-bp paired-end runs. Reads were aligned with the human reference genome (assembly GRCh37/hg19). Pipeline was performed using the Genoox platform based on BWA (version 0.7.16) for read alignment and GATK HaplotypeCaller (version 3.7) and FreeBayes (version 1.1.0) for variant calling.

Dataset files including the annotated information were analyzed with the following filtering steps: variant s which were called <9 times and synonymous variants were removed. Variants were filtered based on allele frequency <0.01 according to online databases; dbSNP, 1000G, ExAC and gnomAD. Likely pathogenicity was assessed if the variant was truncating (splicing or nonsense), missense or an in-frame indel. Missense and in-frame indels were considered if they were predicted to be pathogenic by online prediction tools, PolyPhen-2, SIFT, and Mutation Taster.

RESULTS

Family 1

Patient 1.—The patient is a 3-year-old boy, born to healthy non-consanguineous parents of Ethiopian origin. There is no family history of neurodevelopmental disorders, and they have a healthy 11-year-old daughter. Fetal ultrasound depicted absent cavum septi pellucidi, lateral ventricle synechia, and wide subarachnoid spaces. Septo-optic dysplasia (SOD) was suspected. Fetal MRI demonstrated a structural midline malformation, including partial agenesis of septum pellucidum, suspected thin optic chiasm and thin CC. The frontal lobe volume was mildly reduced. A fetal echocardiogram was normal.

The patient was born at term following a normal delivery, with APGAR scores of 9/10, birth weight of 3105 g, and head circumference (HC) of 36 cm (85th centile). During the first days of life recurrent episodes of gaze deviation and desaturation were observed and diagnosed as non-motor, autonomic with behavior arrest seizures according to the ILEA 2017 seizure classification [5]. The patient was transferred to the neonatal intensive care unit. An EEG showed sharp activity with a normal background. He was treated with phenobarbital and levetiracetam. MRI during the neonatal period showed unseparated frontal horns with mild dilatation (12 mm), absence of the septum pellucidum and a thin CC (Fig. 1). An endocrinological evaluation of the pituitary axis and an ophthalmological examination were normal.

He presented to our clinic at the age of 4 months due to intractable daily seizures, characterized by rhythmic movements of the left arm and leg, and right head deviation, lasting 5–10 min, with no postictal phase.

On physical examination, HC was 43.5 cm (90th centile), weight was 8.2 kg (95th centile). Tall and broad forehead, hypertelorism, brushy eyebrows and thick vermilion were noted. He had not achieved any developmental milestones, he did not make eye contact, nor lift his head in the prone position.

An EEG showed multifocal sharp waves, spikes and polyspikes with phase reversal in the temporal areas.

Later the patient developed multiple seizure types: generalized tonic, clonic, atonic, and myoclonic seizures according to the ILEA 2017 seizure classification [5]. The seizures evolved and manifested as brief (seconds) rapid eye blinking, tonic posturing of arms and legs, and ictal laughter with a short postictal period. The seizures occurred daily, sometimes numerous seizures per hour. Convulsive status epilepticus occurred rarely.

The seizures were drug-resistant to the following medications: phenobarbital, levetiracetam, vigabatrin, topiramate, carbamazepine, hydantoin, lacosamide, clobazam, synacthen depot, medical cannabis, and the ketogenic diet.

A video EEG at the age of 1.10 years, performed during wakefulness, showed multifocal spikes and polyspikes.

At the age of 3 years the HC was 49 cm (50th centile) and weight was 13 kg (30th centile). Neurological examination revealed severe axial and appendicular hypotonia and fisted hands. Deep tendon reflexes were increased unilaterally with sustained clonus. His only developmental milestone was smiling in reaction to his parents' voice and to music.

Patient 2.—The 6-month-old sibling of patient 1 was born at term following an uneventful delivery, birth weight and occipital frontal circumference were within normal ranges. The prenatal anatomical scans were normal.

On the second day of life he presented with seizures starting as bilateral eye blinking, left head deviation, and bilateral clonic movements of the hands continuing to left hemiclonic movements. Seizures were classified as motor clonic and myoclonic seizures [5]. The seizures abated following a phenobarbital load. EEG in quiet sleep showed a continuous and reactive background with sharp epileptic activity over the right hemisphere.

Brain MRI at the age of 1 month depicted a right temporal lobe parenchymal hematoma due to an accidental maternal trauma during pregnancy and right perisylvian PMG (Fig. 2).

He presented to our clinic at the age of 1 month. He was treated with phenobarbital due to daily seizures, characterized by flushing and left head deviation, lasting for several seconds. On physical examination, HC was 39 cm (50th centile), and he weighed 4800 g. The neurological exam was normal. Myoclonic jerks of the left arm were observed during sleep.

At the last clinic visit at the age of 6 months he continued to display weekly seizures, characterized by brief clonic movements of both arms and legs, despite treatment with phenobarbital and levetiracetam. He showed severe global developmental delay. On physical examination HC was 44 cm (85th centile). Dysmorphic features included tall and broad forehead, hyperetelorism, brushy eyebrows and prominent thick vermilion. He did not fix or follow, nor smile. He had axial hypotonia with head lag. In the prone position he lifted his head up only for a few seconds. Reflexes were brisk on the right side with right Achilles clonus. Sudden sounds triggered an extreme startle reaction. A seizure was observed, with gaze and head deviation to the right, and bilateral clonic movements of arms and legs. Myoclonic jerks were also seen. These seizures were classified as motor generalized clonic and myoclonic seizures according to the ILAE 2017 [5].

An EEG at the age of 6 months showed high voltage bilateral continuous irregular slow activity intermixed with spikes and polyspikes more prominent over the left hemisphere.

Family 2

Patient 3.—A 7-year-old boy presented with profound intellectual disability with an intellectual quotient of 17, autistic behavior, and intractable epilepsy. Seizure control failed despite multiple antiepileptic drugs including oxcarbazepine, clobazam, levetiracetam, and others.

Brain MRI demonstrated complete agenesis of CC.

Further clinical information is not available due to follow-up discontinuation.

WES results

The genetic test in the first family revealed a novel variant of uncertain significance in the BCORL1 gene: NM_021946.5 (BCORL1): c.796C>T; p.Pro266Ser, both patients are hemizygous and the mother is a heterozygous carrier (Fig. 3). This variant is located in a proline rich area in the protein and changes the conserved 266 proline into serine, it is extremely rare, and was not found in public databases (GNOMAD, EXAC) and is predicted to be deleterious by part of the in silico predicting softwares (SIFT and PolyPhen-2), the variant is classified as variant of uncertain significance according to ACMG guidelines. No other pathogenic or likely pathogenic variants were identified that can be associated with the patients' phenotype, no other VUS (non-GNOMAD) were shared by both patients. Unfortunately, expression studies could not be performed in our patients.

The genetic test in the second family, patient 3, revealed a novel hemizygous variant of uncertain significance in the BCORL1 gene: NM_021946.5 (BCORL1): c.3376G>A; p.Asp1126Asn, inherited from the mother who is a heterozygous carrier. The c.3376G>A variant results in a substitution of the negatively charged Aspartate to uncharged Asparagine at position 1126, p. Asp1126Asn. This variant is exceedingly rare, was not found in public databases (GNOMAD, EXAC) and is predicted to be deleterious by part of the in silico predicting softwares, the variant is also classified as a variant of uncertain significance according to ACMG guidelines.

DISCUSSION

We describe three male patients from two unrelated families with neonatal onset intractable epilepsy, profound global developmental delay consistent with a developmental and epileptic encephalopathy, and major brain malformations.

WES analysis revealed only one genetic abnormality—previously unreported variants in *BCORL1*: NM_021946.5 (*BCORL1*):c.796C>T; p.Pro266Ser in two siblings, and *BCORL1* NM_021946.5 (*BCORL1*): c.3376G>A; p. Asp1126Asn in the third unrelated patient, both inherited from healthy mothers, thus making these variants the most likely cause. So far, ten patients harboring hemizygous *BCORL1* variants have been reported (Table 1). The *BCORL1*-related phenotype has been named Shukla-Vernon syndrome. The phenotype is clinically heterogeneous, but almost all described patients presented with severe intellectual disability and early onset epilepsy (Table 1) [1–4]. Brain MRI was performed in only four reported cases and in two of them cerebellar atrophy was depicted. All our patients demonstrate more severe clinical manifestations and brain malformations that have not been previously reported and include CC dysgenesis in two patients associated with agenesis of the septum pellucidum in one, and unilateral perisylvian PMG in the younger sibling. Our patients' phenotype expands the Shukla-Vernon syndrome and demonstrates new features of the *BCORL1*-related spectrum of neurodevelopmental disorders.

The major brain malformations of our patients originate at distinct stages of embryogenesis.

Can *BCORL1* variants be responsible for these developmental brain anomalies?

The septum pellucidum is typically comprised of two adjacent laminae of white matter [6], that extend from the inner surface of the rostrum, genu, and body of the CC to the superior surface of the fornix. The cavum starts to develop during the 8th week of gestation [7]. Its development is linked to rapid growth of the forebrain commissures (particularly the CC). ASP can be associated with CC agenesis, schizencephaly, and SOD [8–11]. The genetic origin underlying isolated ASP, is not clear, however, the related syndrome—SOD, has been reported in association with variants in the *HESX1* [12], *SOX2*, *SOX3*, and *OTX2* genes [13–16], that have also been implicated in anomalies of the CC. They all encode regulatory transcription factors, playing an essential role in early fetal development [12–16]. Disturbed interaction between *HESX1* and nuclear co-repressors, resulting in its enhanced repression, has been suggested as a pathogenic mechanism of SOD [17].

PMG is a relatively common malformation of cortical development, characterized by an irregular cortical surface with multiple small gyri and abnormal sulcation, abnormal cortical lamination, and overfolding and fusion of the molecular layer of nearby gyri [18, 19]. Multiple mechanisms, leading to the development of PMG, have been proposed [18, 20–23]. The leptomeninges may also have a role in the development of PMG [19, 24, 25]. They also have a role in the regulation of callosal development [21, 26, 27].

The association between agenesis of the septum pellucidum, PMG and anomalies of the CC has been reported in several case reports [9, 28–30]. Mellado et al. [31] reported three patients with absent septum pellucidum and PMG, two of them also had a hypoplastic CC;

clinically they demonstrated either seizures or developmental delay. Analysis of *LHX2*, *HESX1*, and *SOX2* sequencing did not disclose any pathogenic mutations. Becker et al. also described a patient with opercular PMG and absent septum pellucidum, with childhood onset seizures and speech delay [30]. No genetic testing was performed.

BCORL1 is a transcriptional co-repressor, an exclusively nuclear protein, involved in negative gene regulation through associations with other repressors and protein complexes [32]. Germline mutations have been reported in association with the X-linked recessive Shukla-Vernon syndrome [2].

Repressors play a crucial role in negative gene regulation and their dysfunction can lead to developmental disorders and cancers [17, 33].

BCORL1 is a homolog of BCOR and both of them play a key role in early embryonic development of the cerebral cortex and cerebellum [34, 35].

BCOR functions as a transcriptional co-repressor for BCL6 repressor protein. *BCL6* downregulation in a mouse model leads to cerebellar degeneration [36, 37]. Therefore, the mechanism underlying the cerebellar atrophy, described in two patients reported by Shukla et al. may be BCL6 downregulation by a mutated *BCORL1*.

BCL6 has also been found to be involved in controlling laminar identity and neuronal migration in the developing cortex [38], thus contributing to the PMG, seen in our patient.

CtBP, another co-repressor of BCORL1, is a critical component of many transcriptional repression complexes and has an essential role in neurogenesis [39]. *CtBP* knockdown in mouse results in decreased proliferation and disruption of the cortical migration process [40]. The interaction between CtBP and BCORL1 can add to the understanding of the pathogenic role of BCORL1 in PMG.

Another BCORL1 partner is E-cadherin. It is essential for early cerebellar development [41, 42] and is involved in neuronal maturation, axonal outgrowth and guidance, and synapse formation and plasticity. BCORL1 contributes to the repression of E-cadherin since it is located on its promoter. The repression of E-cadherin may be a link between abnormal development of the leptomeninges, PMG and the CC hypoplasia, which subsequently influences the development of the septi pellucidi.

According to this data we hypothesize that *BCORL1* function in brain development is based on its interaction with other transcriptional co-repressors and their established neurodevelopmental role.

CONCLUSIONS

We suggest that *BCORL1* variants can present a spectrum of neurodevelopmental disorders: Shukla-Vernon syndrome-early onset epilepsy associated with developmental, intellectual and communication difficulties and a more severe phenotype: a developmental and epileptic encephalopathy accompanied by complex brain malformations.

Although the precise function of *BCORL1* in neurogenesis is still unclear, the contribution of its interacting co-repressors to neuronal migration, differentiation and maturation, as well as cerebellar development and protection may shed a light on its role in embryonic brain development at different stages.

We suggest adding *BCORL1* to the list of genetic causes of PMG, ASP, and CC dysgenesis. Further functional studies are needed to prove our theory.

ACKNOWLEDGEMENTS

We would like to thank members and affiliates of the International Research Consortium for the Corpus Callosum and Cerebral Connectivity (IRC5, <https://www.irc5.org>) for their collaboration and input.

DATA AVAILABILITY

Data available on request from the authors.

REFERENCES

1. Schuurs-Hoeijmakers JH, Vulto-van Silfhout AT, Vissers LE, van de Vondervoort II, van Bon BW, de Ligt J, et al. Identification of pathogenic gene variants in small families with intellectually disabled siblings by exome sequencing. *J Med Genet.* 2013;50:802–11. [PubMed: 24123876]
2. Shukla A, Girisha KM, Somashekar PH, Nampoothiri S, McClellan R, Vernon HJ. Variants in the transcriptional corepressor *BCORL1* are associated with an X-linked disorder of intellectual disability, dysmorphic features, and behavioral abnormalities. *Am J Med Genet A.* 2019;179:870–4. [PubMed: 30941876]
3. Jiang YH, Yuen RK, Jin X, Wang M, Chen N, Wu X, et al. Detection of clinically relevant genetic variants in autism spectrum disorder by whole-genome qse-quencing. *Am J Hum Genet.* 2013;93:249–63. [PubMed: 23849776]
4. Muthusamy B, Bellad A, Girimaji SC, Pandey A, Shukla-Vernon syndrome: a second family with a novel variant in the *BCORL1* gene. *Genes.* 2021;12:452. [PubMed: 33810051]
5. Scheffer IE, Berkovic S, Capovilla G, Connolly MB, French J, Guilhoto L, et al. ILAE classification of the epilepsies: position paper of the ILAE commission for classification and terminology. *Epilepsia.* 2017;58:512–21. [PubMed: 28276062]
6. Yakovlev PI, Locke S. Limbic nuclei of thalamus and connections of limbic cortex. III. Corticocortical connections of the anterior cingulate gyrus, the cingulum, and the subcallosal bundle in monkey. *Arch Neurol.* 1961;5:364–400. [PubMed: 14008719]
7. Yakovlev PI, Wadsworth RC. Schizencephalies; a study of the congenital clefts in the cerebral mantle; clefts with hydrocephalus and lips separated. *J Neuropathol Exp Neurol.* 1946;5:169–206. [PubMed: 20993391]
8. Aicardi J, Goutières F. The syndrome of absence of the septum pellucidum with porencephalies and other developmental defects. *Neuropediatrics.* 1981;12:319–29. [PubMed: 7335157]
9. Barkovich AJ, Norman D. Absence of the septum pellucidum: a useful sign in the diagnosis of congenital brain malformations. *AJR Am J Roentgenol.* 1989;152:353–60. [PubMed: 2783514]
10. Schaefer GB, Bodensteiner JB, Thompson JN Jr, Kimberling WJ, Craft JM. Subtle anomalies of the septum pellucidum and neurodevelopmental deficits. *Dev Med Child Neurol.* 1994;36:554–9. [PubMed: 7516298]
11. Malinger G, Lev D, Kidron D, Heredia F, Hershkovitz R, Lerman-Sagie T. Differential diagnosis in fetuses with absent septum pellucidum. *Ultrasound Obstet Gynecol.* 2005;25:42–9. [PubMed: 15593321]
12. McCabe MJ, Alatzoglou KS, Dattani MT. Septo-optic dysplasia and other midline defects: the role of transcription factors: *HESX1* and beyond. *Best Pract Res Clin Endocrinol Metab.* 2011;25:115–24. [PubMed: 21396578]

13. Webb EA, Dattani MT. Septo-optic dysplasia. *Eur J Hum Genet.* 2010;18:393–7. [PubMed: 19623216]
14. Kelberman D, Rizzoti K, Avilion A, Bitner-Glindzicz M, Cianfarani S, Collins J, et al. Mutations within Sox2/SOX2 are associated with abnormalities in the hypothalamo-pituitary-gonadal axis in mice and humans. *J Clin Investig.* 2006;116:2442–55. [PubMed: 16932809]
15. Alatzoglou KS, Kelberman D, Dattani MT. The role of SOX proteins in normal pituitary development. *J Endocrinol.* 2009;200:245–58. [PubMed: 19074474]
16. Ganau M, Huet S, Syrmos N, Meloni M, Jayamohan J. Neuro-ophthalmological manifestations of septo-optic dysplasia: current perspectives. *Eye Brain.* 2019;11:37–47. [PubMed: 31695544]
17. Cohen RN, Cohen LE, Botero D, Yu C, Sagar A, Jurkiewicz M, et al. Enhanced repression by HESX1 as a cause of hypopituitarism and septooptic dysplasia. *J Clin Endocrinol Metab.* 2003;88:4832–9. [PubMed: 14557462]
18. Judkins AR, Martinez D, Ferreira P, Dobyns WB, Golden JA. Polymicrogyria includes fusion of the molecular layer and decreased neuronal populations but normal cortical laminar organization. *J Neuropathol Exp Neurol.* 2011;70:438–43. [PubMed: 21572338]
19. Leventer RJ, Jansen A, Pilz DT, Stoodley N, Marini C, Dubeau F, et al. Clinical and imaging heterogeneity of polymicrogyria: a study of 328 patients. *Brain.* 2010;133:1415–27. [PubMed: 20403963]
20. Dvorak K, Feit J, Juránková Z. Experimentally induced focal microgyria and status verrucosus deformis in rats—pathogenesis and interrelation. Histological and autoradiographical study. *Acta Neuropathol.* 1978;44:121–9. [PubMed: 716839]
21. Choe Y, Siegenthaler JA, Pleasure SJ. A cascade of morphogenic signaling initiated by the meninges controls corpus callosum formation. *Neuron.* 2012;73:698–712. [PubMed: 22365545]
22. Eriksson SH, Thom M, Heffernan J, Lin WR, Harding BN, Squier MV, et al. Persistent reelin-expressing Cajal-Retzius cells in polymicrogyria. *Brain.* 2001;124:1350–61. [PubMed: 11408330]
23. Barkovich AJ. Current concepts of polymicrogyria. *Neuroradiology.* 2010;52:479–87. [PubMed: 20198472]
24. Siegenthaler JA, Ashique AM, Zarbalis K, Patterson KP, Hecht JH, Kane MA, et al. Retinoic acid from the meninges regulates cortical neuron generation. *Cell.* 2009;139:597–609. [PubMed: 19879845]
25. Squier W, Jansen A. Polymicrogyria: pathology, fetal origins and mechanisms. *Acta Neuropathol Commun.* 2014;2:80. [PubMed: 25047116]
26. Zarbalis K, Choe Y, Siegenthaler JA, Orosco LA, Pleasure SJ. Meningeal defects alter the tangential migration of cortical interneurons in Foxc1^{hi}/hith mice. *Neural Dev.* 2012;7:2. [PubMed: 22248045]
27. López-Bendito G, Sánchez-Alcañiz JA, Pla R, Borrell V, Picó E, Valdeolmillos M, et al. Chemokine signaling controls intracortical migration and final distribution of GABAergic interneurons. *J Neurosci.* 2008;28:1613–24. [PubMed: 18272682]
28. Siejka S, Strefling AM, Urich H. Absence of septum pellucidum and polymicrogyria: a forme fruste of the porencephalic syndrome. *Clin Neuropathol.* 1989;8:174–8. [PubMed: 2776383]
29. Labate A, Gambardella A, Quattrone A. Septo-optic dysplasia plus bilateral perisylvian polymicrogyria: a case report. *Neurol Sci.* 2013;34:1479–80. [PubMed: 23124487]
30. Becker PS, Dixon AM, Troncoso JC. Bilateral opercular polymicrogyria. *Ann Neurol.* 1989;25:90–2. [PubMed: 2913934]
31. Mellado C, Poduri A, Gleason D, Elhosary PC, Barry BJ, Partlow JN, et al. Candidate gene sequencing of LHX2, HESX1, and SOX2 in a large schizencephaly cohort. *Am J Med Genet A.* 2010;152a:2736–42. [PubMed: 20949537]
32. Pagan JK, Arnold J, Hanchard KJ, Kumar R, Bruno T, Jones MJ, et al. A novel corepressor, BCOR-L1, represses transcription through an interaction with CtBP. *J Biol Chem.* 2007;282:15248–57. [PubMed: 17379597]
33. Gabellini D, Tupler R, Green MR. Transcriptional derepression as a cause of genetic diseases. *Curr Opin Genet Dev.* 2003;13:239–45. [PubMed: 12787785]

34. Tiacci E, Grossmann V, Martelli MP, Kohlmann A, Haferlach T, Falini B. The corepressors BCOR and BCORL1: two novel players in acute myeloid leukemia. *Haematologica*. 2012;97:3–5. [PubMed: 22210327]
35. Damm F, Chesnais V, Nagata Y, Yoshida K, Scourzic L, Okuno Y, et al. BCOR and BCORL1 mutations in myelodysplastic syndromes and related disorders. *Blood*. 2013;122:3169–77. [PubMed: 24047651]
36. Bonnefont J, Tiberi L, van den Ameel J, Potier D, Gaber ZB, Lin X, et al. Cortical neurogenesis requires Bcl6-mediated transcriptional repression of multiple self-renewal-promoting extrinsic pathways. *Neuron* 2019;103:1096–108.e4. [PubMed: 31353074]
37. Zhou D, Xue J, Gavrialov O, Haddad GG. Na⁺/H⁺ exchanger 1 deficiency alters gene expression in mouse brain. *Physiol Genom*. 2004;18:331–9.
38. Bedogni F, Hodge RD, Elsen GE, Nelson BR, Daza RA, Beyer RP, et al. Tbr1 regulates regional and laminar identity of postmitotic neurons in developing neocortex. *Proc Natl Acad Sci USA*. 2010;107:13129–34. [PubMed: 20615956]
39. Chinnadurai G CtBP, an unconventional transcriptional corepressor in development and oncogenesis. *Mol Cell*. 2002;9:213–24. [PubMed: 11864595]
40. Karaca E, Li X, Lewicki J, Neofytou C, Guéroul N, Barnabé-Heider F, et al. The corepressor CtBP2 is required for proper development of the mouse cerebral cortex. *Mol Cell Neurosci*. 2020;104:103481. [PubMed: 32169478]
41. Mizuhara E, Minaki Y, Nakatani T, Kumai M, Inoue T, Muguruma K, et al. Purkinje cells originate from cerebellar ventricular zone progenitors positive for Neph3 and E-cadherin. *Dev Biol*. 2010;338:202–14. [PubMed: 20004188]
42. Redies C, Neudert F, Lin J. Cadherins in cerebellar development: translation of embryonic patterning into mature functional compartmentalization. *Cerebellum*. 2011;10:393–408. [PubMed: 20820976]

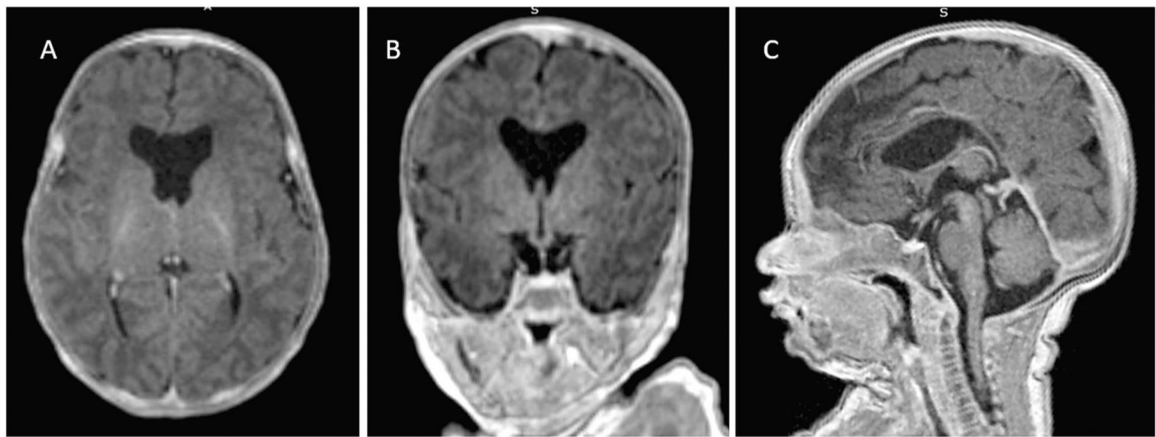


Fig. 1. T1 weighted images, patient 1: axial (**A**) and coronal (**B**) demonstrate absence of the septum pellucidum. Sagittal (**C**) shows hypoplasia of the corpus callosum

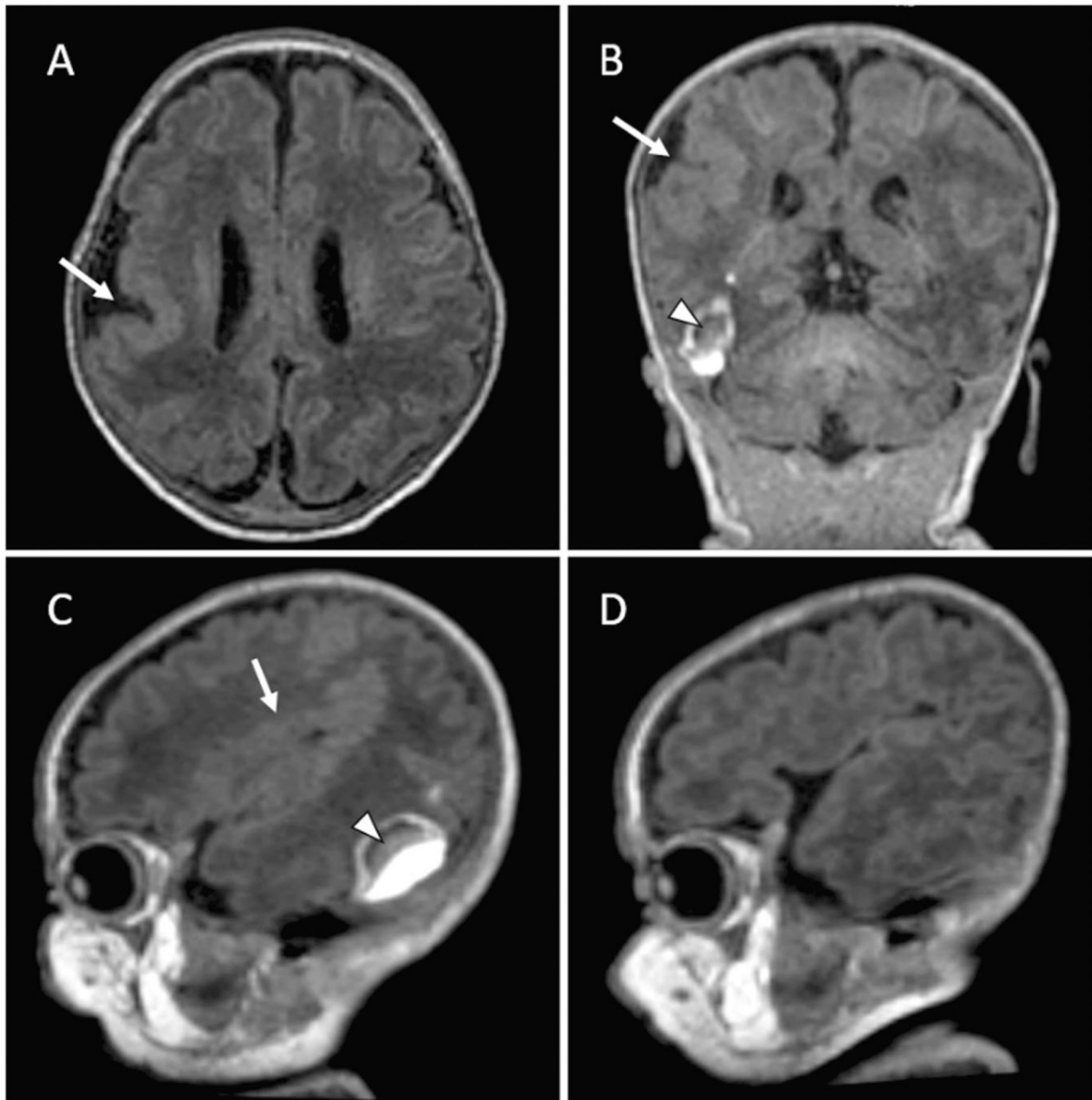
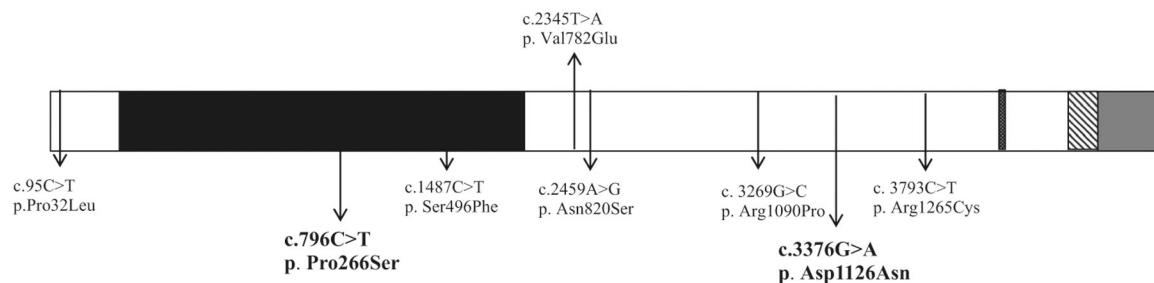


Fig. 2.

T1 weighted axial images, patient 2: axial (**A**) and coronal (**B**) demonstrate right perisylvian polymicrogyria (arrow), sagittal image (**C**) shows perisylvian polymicrogyria of the right hemisphere, and sagittal image (**D**) demonstrates normal cortex of the left hemisphere (arrows); coronal (**B**) and sagittal (**C**) images demonstrate a right temporal lobe parenchymal hematoma due to an accidental maternal abdominal trauma during pregnancy (arrow head)

Schematic representation of *BCORL1***Fig. 3.**

The figure demonstrates six variants reported so far and two novel variants described here (in bold): c.796 C > T; p.Pro266Ser and c.3376 G > A; p. Asp1126Asn. Protein domain structure of BCORL1 (1711 Amino Acids): 198–649-Proline rich region (black); 1328–1336-Nuclear localization signal (dots); 1455–1549-ANK 1–3 repeats (diagonal bars); 1594–1711-PCGF Ub-like fold domain (PUFD), that is required for the interaction with KDM2B-SKP1 heterodimeric complex (gray)

Table 1.

Clinical characteristics of patients with *BCORL1* variants

Features	Family 1		Family 2		Family 3		Family 4		Family 5		Family 6		Family 7		Family 8		Family 13	
	Patient 1	Patient 2	Patient 3	Patient 4	Patient 5	Patient 6	Patient 7	Patient 8	Patient 9	Patient 10	Patient 11	Patient 12	Patient 13					
BCORL1 variant	c.796C>T; p. Pro266Ser	c.796C>T; p. Pro266Ser	c.3376G>A p. Asp1126Asn	c.2345T>A p. Val782Glu	c.1487C>T p. Ser496Phe	c.95C>T p. Pro32Leu	c.95C>T p. Pro32Leu	c.95C>T p. Pro32Leu	c.2459A>G p. Asn820Ser	c.2459A>G p. Asn820Ser	c.3269G>C P. Arg1090Pro	c.3793C>T p. Arg1265Cys	c.3793C>T p. Arg1265Cys					
Zygosity	Hemizygous	Hemizygous	Hemizygous	Hemizygous	Hemizygous	Hemizygous	Hemizygous	Hemizygous	Hemizygous	Hemizygous	NR	Hemizygous	Hemizygous					
Sex	Male	Male	Male	Male	Male	Male	Male	Male	Male	Male	Male	Male	Male					
Inheritance	Maternally inherited	Maternally inherited	Maternally inherited	Maternally inherited	Maternally inherited	Maternally inherited	Maternally inherited	Maternally inherited	NR	NR	NR	Maternally inherited	Maternally inherited					
Length of gestation	Term	Term	NR	32 weeks	Term	Term	Term	Term	Term	Term	NR	Term	Term					
Age at time of examination	3 years	6 months	7 years	15 years 3 months	7 years	15 years	4 years	3 years 4 months	NR	NR	NR	35 years	24 years					
Current head circumference (±1.5SD)	44 cm (-0.03 SD)	44 cm (-0.03 SD)	NR	56 cm (+0.71 SD)	53 cm (+0.74SD)	52 cm (-1.9 SD)	47.5 cm (-2 SD)	45 cm (-3.4SD)	NR	NR	NR	NR	NR					
Intellectual disability	Yes (profound)	Yes (profound)	Yes (profound)	Yes (mild)	No	Yes (severe)	Yes (severe)	Yes (severe)	Yes (severe)	Yes (severe)	Yes (severe)	Yes (severe)	Moderate (IQ = 47)					
Gross motor delay	Yes	Yes	Yes Cerebral palsy	Yes (mild)	Yes (mild)	Yes	Yes	Yes	NR	NR	NR	Yes	Yes					
Hypotonia	Yes	Yes	Yes	Yes	Yes	No	No	No	Yes	Yes	NR	NR	NR					
Seizures	Yes	Yes	Yes	No	No	Yes	Yes	Yes	NR	NR	NR	No	Yes					
Communicative and behavioral difficulties	No communicative skills, no motor oactivity	No communicative skills, no motor oactivity	No communicative skills, no motor oactivity	Autism spectrum Disorder impulsive behavior, attention deficit hyperactivity disorder	Autism spectrum disorder, impulsive and aggressive behavior, attention deficit hyperactivity disorder	Autism spectrum disorder	Autism spectrum disorder	Autism spectrum disorder	NR	NR	Autism spectrum disorder	NR	NR					
EEG findings	Multifocal epileptic activity and polyspikes	Polyspikes, Multifocal bilateral epileptic activity, amplified in	Epileptic activity	Not done	Abnormal findings	Bilateral centro-temporal spike and wave complexes	Not done	Right centro-temporal spikes	NR	NR	NR	NR	NR					

Features	Family 1		Family 2		Family 3		Family 4		Family 5		Family 6		Family 7		Family 8		Family 13		
	Patient 1	Patient 2	Patient 3	Patient 4	Patient 5	Patient 6	Patient 7	Patient 8	Patient 9	Patient 10	Patient 11	Patient 12	Patient 13	Patient 14	Patient 15	Patient 16	Patient 17	Patient 18	
Brain MRI findings	Absent septum pellucidum Hypoplastic CC	Unilateral perisylvian PMG	Agensis CC	No	No	Cerebellar atrophy	Not done	Cerebellar atrophy	NR	NR	NR	NR	NR	NR	NR	NR	NR	NR	
Dysmorphic features	Tall broad forehead, bushy eyebrows, hypertelorism, thick vermilion	Tall broad forehead, bushy eyebrows, hypertelorism, thick vermilion	NR	Tall forehead hypertelorism, palpebral fissures, long fingers	Hypertelorism, Downslanting palpebral fissures, bilateral exotropia, pectus excavatum	Tall forehead, Dysmorphic ears, long fingers, and toes	Tall forehead, Dysmorphic ears, long fingers	Tall forehead, dysmorphic hands and feet	Coarse face	Coarse face	Coarse face	NR	Broad forehead, bushy eyebrows with synophrys, long fingers, and clinodactyly-kyphoscoliosis.	NR	NR	Broad forehead, bushy eyebrows, synophrys, beaked nose, dysmorphic ears, long fingers, clinodactyly, kyphoscoliosis	NR	Low hairline, bushy eyebrows, synophrys, beaked nose, dysmorphic ears, long fingers, clinodactyly, kyphoscoliosis	NR
Other tests				Normal Fragile X testing	Normal Fragile X testing, Chromosomal microarray showed duplication of cytoband 2p22.3, which was inherited from healthy father	Normal male karyotype 46, XY	Not done	Normal male karyotype 46, XY	NR	NR	NR	NR	Normal male karyotype 46, XY	NR	NR	Normal male karyotype 46, XY	NR	Normal male karyotype 46, XY	NR
Reference				Shukla et al. [2]	Shukla et al. [2]	Shukla et al. [2]	Shukla et al. [2]	Shukla et al. [2]	Schuurs-Hoeijmakers et al. [1]	Schuurs-Hoeijmakers et al. [1]	Schuurs-Hoeijmakers et al. [1]	Jiang et al. [3]	Muthusamy et al. [4]	Muthusamy et al. [4]	Muthusamy et al. [4]	Muthusamy et al. [4]	Muthusamy et al. [4]	Muthusamy et al. [4]	Muthusamy et al. [4]

NR not reported