

TECHNIQUE

Balloon dilatation of complete obstruction of the superior vena cava after Mustard operation for transposition of great arteries

Jassim M Abdulhamed, Saad Al Yousef, Mohamed A Ali Khan, Charles Mullins

Abstract

Balloon dilatation was successfully performed in two patients with complete obstruction of the superior vena cava baffle junction after a Mustard operation for transposition of the great arteries. Evidence for complete relief of obstruction in the first patient, aged 4 years, was obtained by angiography, which showed improved calibre at the site of obstruction and improved haemodynamic pressure measurement after the balloon dilatation. In the second patient, aged 14 years, the relief was incomplete; in this patient a 3 cm long 3 mm diameter Palmaz stent was successfully implanted.

(Br Heart J 1994;72:482-485)

For many years the Mustard operation was the preferred operation for physiological repair of transposition of the great arteries. Complications of this operation include obstruction of both systemic and pulmonary venous pathways.^{1,2} Reoperation is recommended for obstructions of the pulmonary vein inferior vena cava, and superior vena cava if symptomatic.³ Successful balloon dilatation of incomplete systemic venous obstruction has been reported.^{2,4,5}

Balloon dilatation was successfully performed in two patients with complete obstruction of the superior vena cava after the Mustard procedure for transposition of the great arteries. The obstructed end was pierced with a super stiff guidewire in case 1, and a transeptal needle in case 2.

Case reports

CASE 1

A 4 year old boy had undergone a Mustard repair of a transposition of the great arteries at 10 months of age. Soon after surgery he developed signs of obstruction of the vena cava. At the age of 3 years cardiac catheterisation showed total obstruction of the superior vena caval baffle junction with considerable azygos run off into the inferior vena cava but also with noticeable obstruction of the inferior vena caval arm of the baffle. That arm of the baffle was dilated by a balloon catheter

with immediate and considerable relief of symptoms, ascites, and fluid retention. Over the ensuing year the signs of fluid retention recurred, with pronounced abdominal distension and associated hepatomegaly, together with jugular venous distension.

Under sedation of pethidine and promethazine, and supplemented by ketamine, a 6 French (F) sheath was introduced percutaneously into the right femoral vein with leader catheters introduced percutaneously into the left femoral vein and the right femoral artery. A 6 F NIH catheter was introduced through the venous sheath into the inferior vena cava, into the systemic venous atrium, and into the left ventricle. Pressures and oxygen saturations were recorded and the tip of the catheter was then withdrawn into the systemic venous atrium.

A 6 F sheath dilator set was introduced percutaneously into the right internal jugular vein. A 6 F NIH catheter was then passed through this sheath into the superior vena cava and down to the superior limb of the baffle. A selective cineangiogram was recorded here. This showed total obstruction of the superior limb of the baffle with dilatation of the superior vena cava and considerable run off into the azygos system towards the inferior vena cava (fig 1(A)). The area of obstruction seemed to be discrete with the tip of the catheter coming from the jugular approach lying within 1 mm of the tip of the catheter from the inferior vena caval approach.

The jugular NIH catheter was replaced with a 6 F Goodale Lubin catheter and the tip (distal end) was positioned in the superior limb of the baffle adjacent to the tip of the catheter coming from the inferior limb. A slight (10°-15°) smooth curve was formed on the stiff end of an 035 Meditech super stiff wire. This stiff end of the wire was passed through the previously positioned jugular Goodale Lubin catheter to protrude just beyond the tip. Firm pressure was applied to the catheter and stiff wire causing the wire to pop through the area of obstruction into the systemic venous atrium. The catheter was then easily advanced over the wire into this area (Fig 1(B)).

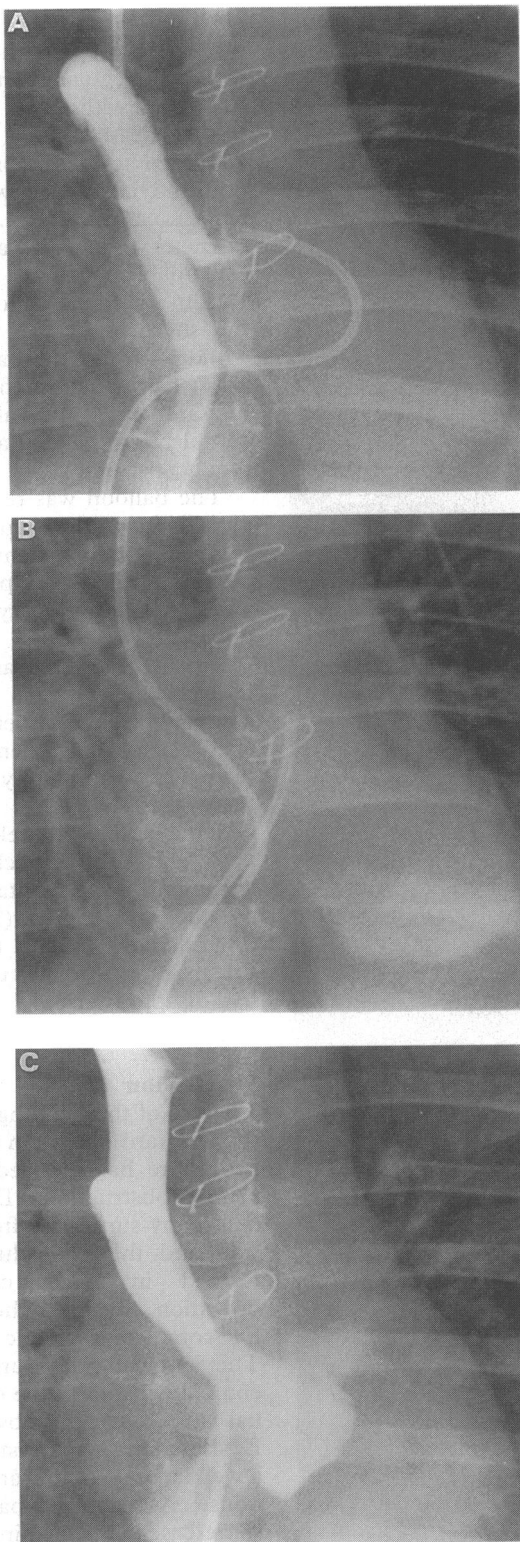
The super stiff wire was then removed and reversed introducing the soft end of the wire into the systemic venous atrium and from

Department of
Paediatric Cardiology,
Armed Forces
Cardiac Centre,
Riyadh, Kingdom of
Saudi Arabia
J M Abdulhamed
S Al Yousef
M A Ali Khan
C Mullins

Correspondence to:
Dr Jassim M Abdulhamed,
PO Box 7897, Riyadh
11159, Kingdom of Saudi
Arabia.

Accepted for publication
15 February 1994

Figure 1 (Case 1)
 Superior vena cava cineangiogram in posteroanterior projection showing (A) total obstruction of the superior limb of the baffle with considerable dilatation of the superior vena cava and run off into the azygos system toward the inferior vena cava; (B) the 6GL catheter passing through the area of obstruction into the new right atrium; (C) after balloon dilatation, showing the widely open superior limb of the baffle with minimal run off through the azygos system.



there to the left ventricle. Over the wire in this position, a 10 mm diameter Meditech balloon on a 5 F shaft was introduced and advanced through the area of obstruction, so that the balloon was centred at that area. With the balloon inflated to the full 10 mm diameter the waist on the balloon completely disappeared. A cineangiogram showed considerable improvement in the flow directly into the systemic venous atrium from the superior vena cava, with a pronounced decrease in the azygos flow, but some obstruction remained. After this a guidewire

was advanced through a Goodale Lubin catheter from the right femoral vein through the inferior limb of the baffle and up into the superior limb and turned into the superior vena cava. The dilatation was repeated with a 15 mm Meditech balloon on a 7 F shaft over this wire in the same area.

The leader catheter in the left femoral vein was replaced with a 6 F sheath. A guidewire was advanced through a Goodale Lubin catheter from the left femoral vein through the inferior limb of the baffle, up into the superior limb, and turned into the superior vena cava. A 10 mm Meditech balloon was introduced over the wire in the left femoral vein and positioned in the superior vena cava at the level of the obstruction. Both balloons were inflated simultaneously. The balloons were then withdrawn and positioned in the area of the inferior limb of the baffle; the simultaneous dilatation was repeated. In both locations the waist disappeared in both balloons on full inflation. Once the dilatations had been completed, pressures were recorded both simultaneously in the superior vena cava and the new right atrium and simultaneously in the inferior vena cava, superior vena cava, and in the femoral artery. A cineangiogram was obtained with simultaneous injection in the superior and inferior vena cavae.

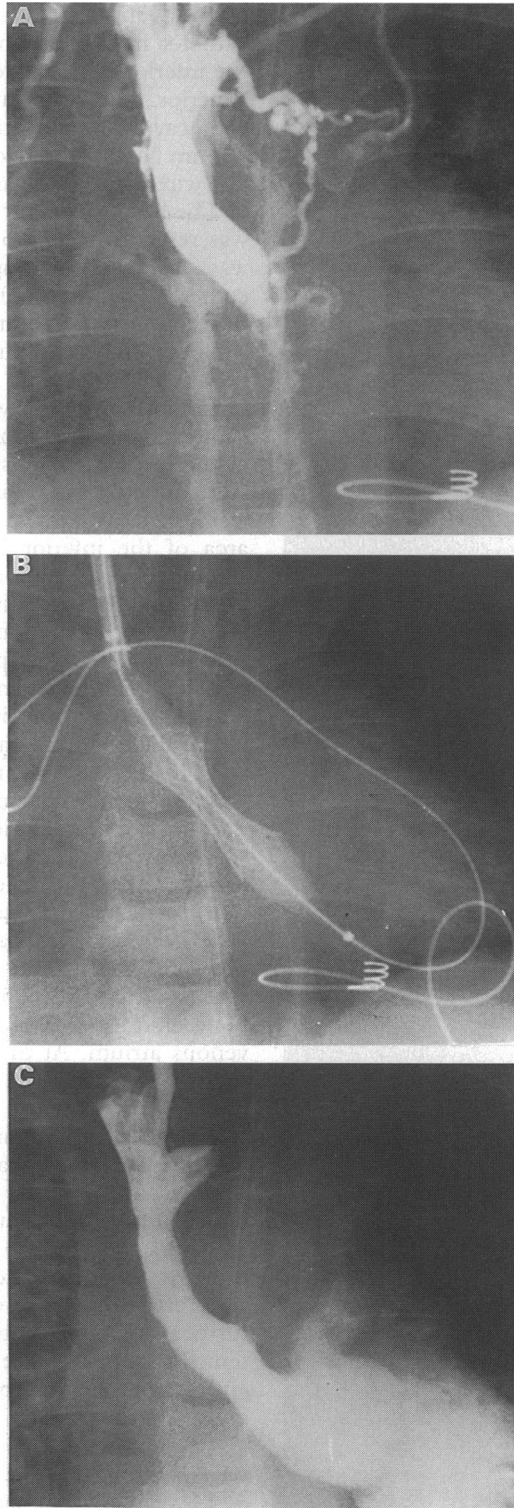
There was a large increase in systemic pressure after the relief of the caval obstruction. At the onset of catheterisation there was an 18 mm Hg mean pressure gradient between the superior limb and the systemic venous atrium and a 5 mm Hg mean gradient between the inferior limb and the systemic venous atrium. At the end of the procedure, there was a 3 mm Hg residual gradient between the superior vena cava and the systemic venous atrium and no gradient between the inferior vena cava and the systemic venous atrium. Both systolic and mean systemic pressure also increased by 30 mm Hg. Angiography after the procedure showed that both the superior and inferior limbs of the vena cava were wide open and there was no further run off flow through the azygos system (fig 1(C)). The patient tolerated the entire, complicated, procedure without difficulty.

CASE 2

A 14 year old boy with transposition of the great arteries had undergone a Mustard repair as a young child. He developed complete heart block that needed insertion of a permanent epicardial pacemaker. Subsequently he was recurrently admitted to hospital for pleural effusions, ascites, oedema, and distention of the head and neck veins. Because of these signs of superior vena caval obstruction, cardiac catheterisation was performed. Catheterisation showed that both femoral veins were obstructed, and there was no reconstitution of the caval system distal to the renal veins. The femoral venous approach was therefore abandoned and the right internal jugular vein entered percutaneously.

A 6 F sheath set was passed into the right

Figure 2 (Case 2)
 Superior vena cava cineangiogram in posteroanterior projection showing (A) total obstruction of the superior limb of the Mustard baffle; (B) the stent in the obstructed area of the Mustard baffle, partially expanded by a 15 mm, 3 cm long balloon dilatation catheter. The double exchange wire was advanced through a 6 French trans-septal sheath in the superior vena cava; (C) after stent implantation showing excellent flow through the widely patent stent.



internal jugular vein; an angiogram showed total obstruction of the superior limb of the Mustard baffle quite low down within the cardiac silhouette (fig 2(A)). The 6 F standard sheath was replaced with a 6 F trans-septal set; using the trans-septal needle a puncture was performed from the superior limb of the baffle into the systemic venous atrium. The dilator was removed and replaced with an exchange guidewire. A 10 mm diameter, 3 cm long Meditech balloon catheter on a 5 F shaft was then introduced over this wire, positioned at the area of the

obstruction, and the balloon inflated several times. This opened the superior limb slightly, with an irregular tract. The balloon catheter was then withdrawn and replaced with an 11 F sheath dilator set. The sheath was advanced across the previous area of obstruction and positioned with the tip in the systemic venous atrium. A 3 cm long, 3 mm diameter Johnson and Johnson balloon expandable Palmaz stent mounted on a 15 mm Meditech balloon was passed through the sheath over the wire. The sheath was withdrawn and the balloon expanded in the area of obstruction (fig 2(B)). This successfully implanted the Palmaz stent in an almost completely expanded area that was previously totally obstructed.

The balloon was removed. A catheter was passed from the jugular vein through the stent and the left ventricle to the main pulmonary artery where pressures were recorded and a right pulmonary artery angiogram was obtained.

Finally, a selective angiogram was obtained in the superior vena cava. This showed a completely open superior limb of the baffle (fig 2(C)). The patient tolerated the procedure without difficulty. By the next morning there was already a dramatic decrease in oedema and the swelling of the head and neck and of the neck distension. Diuretic treatment was maintained with frusemide, together with aspirin (75 mg once daily) and dipyridamole (25 mg three times daily). At the six month follow up the pleural effusion had disappeared.

Discussion

The use of the Senning operation rather than the Mustard operation as an atrial redirection procedure has reduced the risk of systemic venous obstruction.⁶ Despite this, there are still many survivors after the Mustard operation and this procedure is still being performed in many centres.^{3,4,6} A repeat operation has been the treatment of choice for complete systemic venous obstructions. The surgical procedure may not, however, completely abolish the obstruction, and residual and recurrent obstruction may occur.³ Dysfunction of the systemic right ventricle is a well known complication of Mustard operations.⁴ A second bypass procedure and in some cases even a third procedure may well contribute to further deterioration of the systemic right ventricle.

Both of our patients had symptoms of obstruction of the superior vena cava. Cardiac catheterisation confirmed complete occlusion of the superior vena cava in both. We attempted to traverse this occlusion with the hope of then performing balloon dilatation. In the first patient, the obstruction seemed very thin; the stiff end of a super stiff wire easily penetrated the obstruction and allowed a catheter to be advanced into the systemic venous atrium. In the second patient, the area of obstruction (obliteration) of the superior limb of the baffle was very

long and a long segment of scar or fibrotic tissue had to be perforated to establish any communication between the proximal superior vena cava and the new systemic venous atrium. The use of the trans-septal needle permitted a purposeful directional puncture to traverse this long segment and allowed intermittent tiny injections of contrast through the needle into the tissues (or chambers) entered to identify the exact location of the needle tip. A puncture or perforation into the adjacent chamber with only the tip of a 22 gauge needle carries little or no risk as long as the undesired area (chamber) is recognised and the needle is not followed with the sheath and dilator. Once the needle tip entered the desired distal chamber, the trans-septal needle shaft added the necessary directional support to follow the tip with the sheath and dilator.

In an effort to avoid complications, manipulation of the wire, needle, and catheter was performed carefully with biplane fluoroscopy and cineangiography. In both cases the perforating wire or needle was advanced toward the systemic venous atrium that had been previously outlined with contrast (case 2) or toward a catheter tip against the obstruction in the systemic venous atrium (case 1). We prefer to aim toward a catheter in the systemic venous atrium, but it was not possible in case 2 because of occluded femoral veins. Although this technique requires additional time and manipulation of the catheter, it minimises the possibility of perforation of the vessel. With the increased venous pressure, perforation of the superior vena cava could have resulted in severe haemorrhage with

subsequent haemodynamic collapse.

In case 2 balloon dilatation resulted in prograde flow from the superior vena cava to the systemic venous atrium. There was, however, residual stenosis. Implantation of a Palmaz stent resulted in complete resolution of the obstruction.

Our immediate and short-term results in these two patients show that complete occlusion of an obstructed atrial baffle after the Mustard procedure can be traversed and then dilated safely and effectively with a balloon catheter. Special precautions must be taken to avoid cardiac perforation. In some patients implantation of an intravascular stent may eliminate the residual stenosis.

We thank Dr William Sawyer for his advice and review and Maureen Meek for typing the paper.

- 1 Stark J, Tynan MJ, Ashcroft KW, Aberdeen E, Waterston DJ. Obstruction of pulmonary veins and superior vena cava after the Mustard operation for transposition of the great arteries. *Circulation* 1972;45(suppl 1):1-116-20.
- 2 Benson LN, Yeatman L, Laks H. Balloon dilation for superior vena caval obstruction after the Senning procedure. *Cardiovasc Diagn* 1985;11:63-8.
- 3 Cooper SG, Sullivan ID, Bull C, Tylar J. Balloon dilation of pulmonary venous pathway obstruction after Mustard repair for transposition of the great arteries. *J Am Coll Cardiol* 1989;14:94-8.
- 4 Lock JE, Bass JL, Castaneda-Zumiga W, Fuhrman BP, Rashkind WJ, Lucas RV Jr. Dilation angioplasty of congenital or operative narrowing of venous channel. *Circulation* 1984;70:457-64.
- 5 Pascal Chatelain, Bonnahard Meier, Beat Friedle. Stenting of superior vena cava and inferior vena cava for symptomatic narrowing after repeated atrial surgery for D-transposition of the great vessels. *Br Heart J* 1991; 66:466-8.
- 6 Smallhorn JF, Gow R, Freedom RM, et al. Pulsed Doppler echocardiographic assessment of pulmonary venous pathway after the Mustard or Senning procedure for transposition of great arteries. *Circulation* 1986;73: 765-74.