


The efficacy of hemiepiphysiodesis for idiopathic knee coronal angular deformity by reconstruction plate and screw: A pilot study

Arash Maleki¹ | Mohamad Qoreishi¹ | Amir Bisadi¹ | Farshad Safdari¹ |
Amin Daei Sorkhabi²  | Ali Fotouhi³ | Mohammad A. Tahririan⁴

¹Department of Orthopedic Surgery, Akhtar Hospital, Shahid Beheshti University of Medical Sciences, Tehran, Iran

²Student Research Committee, Tabriz University of Medical Sciences, Tabriz, Iran

³Department of Orthopedic Surgery, Faculty of Medicine, Tabriz University of Medical Sciences, Tabriz, Iran

⁴Department of Orthopedic Surgery, Faculty of Medicine, Isfahan University of Medical Sciences, Isfahan, Iran

Correspondence

Ali Fotouhi.

Email: ali.fotouhi1351@gmail.com

Abstract

Background: Angular deformities of the lower extremities are among the most common findings in pediatric orthopedics. Alteration of the mechanical axis in the lower extremity affects the cosmetic appearance and may lead to gait disturbances, knee discomfort, patellar maltracking with or without pain, and early joint osteoarthritis. In the current study, we aimed to investigate the efficacy of 3-hole 3.5 mm reconstruction plates in tension-band temporary hemiepiphysiodesis for correcting idiopathic knee coronal angular deformities.

Methods: The surgical procedure was performed using an extraperiosteal tension band plate (a 3-hole reconstruction plate) and two 3.5 mm cortical screws to treat idiopathic knee coronal angular deformity in children. The location of the hemiepiphysiodesis was determined based on the type of angular deformity present. Postoperative follow-ups were conducted through x-rays to measure the medial proximal tibial angle and lateral distal femoral angle of the limbs. Statistical analysis was then performed to evaluate the efficacy of the surgical treatment based on the rate of alignment change exhibited.

Results: The study included 14 patients (25 limbs) with genu valgum deformity who underwent temporary hemiepiphysiodesis on both the distal femur and proximal tibia, with 16 proximal tibias and 15 distal femurs being corrected. The correction rate for genu valgum was found to be 0.59° per month for both proximal tibial and distal femoral hemiepiphysiodesis. Six patients (12 limbs) were also identified with genu varum deformity, and the correction rates for proximal tibial lateral hemiepiphysiodesis and distal femoral lateral hemiepiphysiodesis were 0.85° and 0.15° per month, respectively. During a mean follow-up duration of 11 ± 5.7 months, only one case of physeal plate closure was observed, and there were no other significant complications.

This is an open access article under the terms of the Creative Commons Attribution-NonCommercial-NoDerivs License, which permits use and distribution in any medium, provided the original work is properly cited, the use is non-commercial and no modifications or adaptations are made.

© 2023 The Authors. *Health Science Reports* published by Wiley Periodicals LLC.

Conclusion: Temporary hemiepiphysiodesis with a 3-hole R-plate and two cortical screws takes advantage of physiological physal growth to successfully treat idiopathic angular deformities with low complication rates.

KEYWORDS

3-hole R-plate, angular deformity, genu valgum, genu varum, hemiepiphysiodesis

1 | INTRODUCTION

Angular deformities of the lower extremities are among the most common findings in pediatric orthopedics.^{1,2} Alteration of the mechanical axis in the lower extremity affects the cosmetic appearance and may lead to gait disturbances, knee discomfort, patellar maltracking with or without pain, and early joint osteoarthritis.³ Several procedures have been described to attain normal alignment in pediatric patients.

Acute corrective osteotomy is the most common operation used in limb angular deformities, but it is a highly invasive intervention with some complications such as compartment syndrome, neurovascular injury, and over- or under-correction.^{4,5} Hemiepiphysiodesis is an alternate technique that can correct angular deformities by inducing asymmetric growth arrest in the physal plate, thus allowing gradual correction of the deformity with limb growth over time. However, permanent hemiepiphysiodesis, the Phemister method and its modifications, is an irreversible method that requires an exact calculation of the remaining growth and is exclusively applicable to adolescents.^{6,7}

Several techniques are utilized for hemiepiphysiodesis. Stapling is one of these techniques used for temporary hemiepiphysiodesis, first introduced by Dr. Walter P. Blount in the 1940s.⁸ It is a minimally invasive procedure for children with genu varum and genu valgum, who are as young as 2 years old. This technique has been found to be well-tolerated, with few complications and a quick recovery time.⁹ Despite its apparent simplicity, it is not used routinely due to unpredictable complications, including the risk of residual deformity or over-correction of the affected limb, premature physal closure, or iatrogenic physal arrest.¹⁰ Furthermore, stapling carries the potential risk of implant breakage or migration.^{8,11} Likewise, Metaizeau et al.¹² introduced a trans-physal screw for hemiepiphysiodesis that involves crossing the physal plate from the metaphysis to the epiphysis direction. This technique may also be associated with some complications such as screw breakage and physal bar formation. Further, Stevens et al.¹³ described the concept of guided growth using a nonlocking 8-plate and two screws. This technique has gained popularity and is well-established for correcting angular deformities around the knee.^{2,4} While it has been associated with lower postoperative complications, the cost of the plate used is higher than that of other techniques.^{1,14}

The use of a 3-hole R-plate for temporary hemiepiphysiodesis is a novel and promising technique for the correction of idiopathic

coronal plane knee angular deformities. To establish a tension band across the physis, a plate and screw construct is positioned on the medial side of the proximal tibia and on the lateral side of the medial femoral condyle. As growth proceeds, the tension band-induced growth arrest enables the deformity to gradually be corrected.¹⁵ The R-plate technique for temporary hemiepiphysiodesis, in contrast to other techniques that use pins or staples, provides a more cost-effective alternative to conventional methods by lowering the need for subsequent surgical intervention since the R-plate does not need to be removed, using fewer materials, and minimizing hospital stays.¹⁶

Given the above reflection, we aimed to investigate the use of 3-hole 3.5 mm reconstruction plates for tension-band temporary hemiepiphysiodesis around the knee joint to correct idiopathic angular deformities. Our assessment focused on the efficacy of the hemiepiphysal procedure in achieving limb angular correction at the distal femur and proximal tibia.

2 | MATERIALS AND METHODS

2.1 | Study design

This pilot study was conducted on patients with coronal deformities (genu varum or genu valgum) of the lower limb who underwent hemiepiphysiodesis using an extraperiosteal reconstruction plate and screws between 2017 and 2019 in Akhtar Hospital (a university-affiliated hospital in Tehran, Iran). The protocol of this study was reviewed and approved by the Ethics Committee of Shahid Beheshti University of Medical Sciences, and all patients' parents or legal guardians were fully informed and provided written consent.

2.2 | Study subjects

The study enrolled patients between the ages of 11 and 15 who had coronal angular knee deformities, specifically genu varum or genu valgum, and had active physal plates in the distal femur and proximal tibia. However, patients with a history of previous tibial and/or femoral fractures and musculoskeletal dysplasia were excluded from participation.

Before treatment, patients were assessed for a variety of factors including limb length discrepancies, ligamentous laxity,

patellar tracking, and angular and rotational deformities. To determine the alignment of the lower extremity, weight-bearing long-leg x-rays were taken in both anteroposterior (AP) and lateral views with the patella facing forward. In particular, the mechanical axis of the lower limb was assessed in the AP view. Patients with excessive ligament laxity causing knee thrust, clinical limb length discrepancy >1 cm, rotational deformities, or patellar maltracking were excluded from the study. The subjects' mechanical axis (femur and tibia) deviations from the normal value of 87 ± 2 degrees determined the location of the deformity and plate position, whether medial or lateral in the distal femur or proximal tibia or both.

2.3 | Surgical technique

During the hemiepiphyodesis procedure for children with idiopathic coronal angular knee deformities, an extraperiosteal tension band plate (3-hole reconstruction plate) and two cortical screws (3.5 mm) were implanted (Figure 1). The location of the hemiepiphyodesis was determined by the type of deformity present, with the plate being implanted medially for genu valgum and laterally for genu varum, either unilaterally or bilaterally. The surgical technique involved the initial implantation of an epiphyseal screw in the proximal tibia or distal femur under fluoroscopy to avoid physeal injury. Another screw was then located in the metaphysis, and each deformity was treated using a single plate per physis during the procedure, following Stevens' technique.¹⁷ After the hemiepiphyodesis procedure, patients did not require any brace or splint and weight-bearing was allowed as tolerated on the first postoperative day. Range-of-motion exercises for the knees were initiated on the second day following the surgery, and patients were not routinely referred for physiotherapy except in cases where they were uncooperative.

2.4 | Outcomes

The main objective of our study was to evaluate the rate of alignment correction and associated complications. To this end, two weeks after

the hemiepiphyodesis procedure, patients were revisited to assess knee range of motion and soft tissue healing. At the 4-week follow-up visit, AP and lateral x-rays of the knee were taken to examine the status and position of the implants. Six months following the surgery, long-leg radiographs were performed on the lower limbs to measure the medial proximal tibial angle and lateral distal femoral angle of the operated limbs. The timing of subsequent visits depended on the rate of limb alignment correction. Implants were removed if follow-up revealed mechanical axis correction in the limbs. We also documented any complications that arose from the surgical procedures during follow-up visits.

2.5 | Statistical analysis

Statistical analysis was performed using SPSS statistical software version 23 (SPSS Inc.). The normal distribution of the data was assessed with either a Kolmogorov-Smirnov or Shapiro test. Comparisons between pre- and postoperative measurements were made using either a nonparametric Wilcoxon test or a paired *t*-test. Additionally, the rate of alignment change was calculated by dividing the sum of changes in degrees by the time spent. Statistical significance was determined by a *p* value < 0.05 .

3 | RESULTS

A total of 39 patients aged between 11 and 15 with a coronal plane knee deformity (genu varum or genu valgum) underwent surgery at our hospital between July 2017 and December 2019. All surgeries were performed by the same surgical team. Nineteen cases were excluded from the study due to different reasons. Specifically, one case had a rheumatic disease, six cases had prior fractures, one case had multiple epiphyseal dysplasia, one case was associated with blunt trauma, seven cases underwent permanent hemiepiphyodesis, and three cases had insufficient follow-up data.

In the study, a total of 20 cases were examined, which included 37 limbs. Of the 20 cases, 12 were male and 8 were female. The patients' mean age during implantation was 12 years and 4 months. On a gender basis, the females had an average age of 11 years and 10

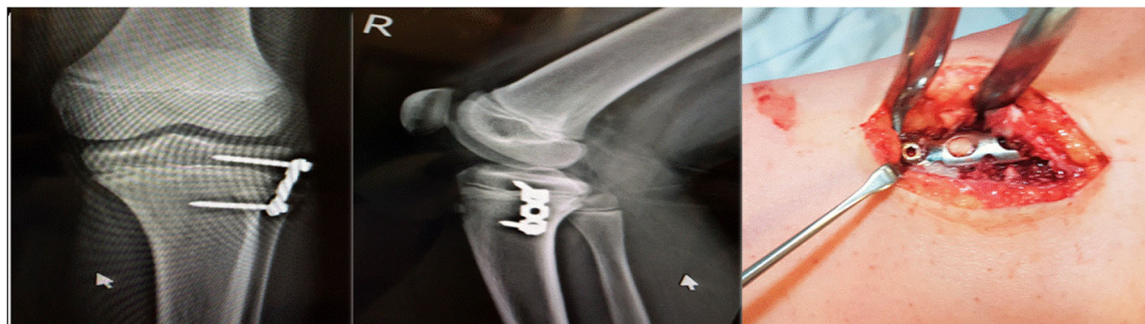

FIGURE 1 Hemiepiphyodesis using a 3-hole tension band plate and two cortical screws.

TABLE 1 Pre- and postoperative characteristics of patients.

Patient	Sex	Age at surgery (year + month)	Deformity	R-LDF	L-LDF	R-MPT	L-MPT	Surgery	R-LDF-p	L-LDF-p	R-MPT-p	L-MPT-p	Follow up (Month)	Complications
1	M	14 + 3	Varum	94	94	83	82	bi-T&F	92	92	92	94	23	None
2	F	12 + 1	Varum	88	90	81	83	bi-T	88	89	88	89	13	None
3	F	11 + 7	Valgum	77	75	86	88	bi-F	80	79	85	83	6	Closure of physes
4	F	12 + 5	Varum	91	89	89	88	bi-F	86	87	88	87	6	None
5	F	12 + 3	Valgum	86	85	91	92	bi-T	87	87	89	89	6	None
6	M	12 + 2	Varum	88	87	85	82	bi-T	87	89	88	87	6	ROM restriction
7	M	12	Valgum	83	82	87	89	bi-F	87	87	88	88	9	Superficial infection
8	M	15 + 1	Valgum	82	84	93	93	bi-T&F	88	87	89	88	14	None
9	M	12 + 3	Varum	88	87	85	82	bi-T	88	87	88	88	9	None
10	M	11 + 5	Valgum	84	84	91	93	bi-T&F	88	88	87	85	7	None
11	M	11 + 6	Valgum	89	87	87	91	uni-T	88	87	87	87	6	None
12	F	12 + 2	Valgum	82	82	88	90	bi-F	89	89	88	90	9	None
13	M	11 + 10	Valgum	87	88	96	98	bi-T	87	88	85	86	11	None
14	M	11 + 10	Valgum	89	86	88	92	uni-T	89	86	87	86	9	None
15	F	11 + 8	Valgum	89	86	88	91	uni-T	89	87	88	87	21	None
16	F	11 + 8	Valgum	87	89	95	92	bi-T	87	89	85	88	21	None
17	M	12 + 5	Valgum	84	83	87	88	bi-f + uni-T	88	86	88	89	10	ROM restriction
18	M	12 + 8	Valgum	77	76	83	80	bi-F	85	85	85	85		None
19	F	10 + 6	Valgum	87	82	93	91	bi-T + uni F	83	85	88	89	10	None
20	M	12 + 7	Varum	83	86	79	84	bi-T	87	88	84	87	12	None

Abbreviations: F, female; L-LDF, left lateral distal femoral; L-MPT, left medial proximal tibial; M, male; R-LDF, right lateral distal femoral; R-MPT, right medial proximal tibial; ROM, range of motion.

TABLE 2 Location of deformities corrected with hemiepiphysodesis.

Deformity	Distal femur		Proximal tibia		Both		Bilateral distal femur + unilateral proximal tibia	Unilateral distal femur + bilateral proximal tibia
	Unilateral	Bilateral	Unilateral	Bilateral	Unilateral	Bilateral		
Genu valgum	0	4	3	3	0	2	1	1
Genu varum	0	1	0	4	0	1	0	0

TABLE 3 Changes in LDFA and MPTA in genu valgum group.

		Preoperative	Postoperative	p Value
LDFA	LDFA in total limbs (n = 28)	84 ± 4	86.6 ± 2.5	0.001
	LDFA in operated limbs (n = 15)	81.1 ± 3.2	86.1 ± 3	0.001
	LDFA in nonoperated limbs (n = 13)	87.3 ± 1.4	87.2 ± 1.6	0.891
MPTA	MPTA in total limbs (n = 28)	90 ± 3.8	87.1 ± 1.7	0.001
	MPTA in operated limbs (n = 16)	92.5 ± 2.3	87.3 ± 1.5	0.001
	MPTA in nonoperated limbs (n = 12)	86.7 ± 2.7	86.8 ± 1.9	0.829

Note: Bold values were considered statistically significant.

Abbreviations: LDFA, lateral distal femoral angle; MPTA, medial proximal tibial angle.

TABLE 4 Changes in LDFA and MPTA in genu varum group.

		Preoperative	Postoperative	p Value
LDFA	LDFA in total limbs (n = 12)	88.7 ± 3.1	88.3 ± 1.9	0.587 (Wilcoxon)
	LDFA in operated limbs (n = 4)	92 ± 2.4	89.2 ± 3.2	0.059 (Wilcoxon)
	LDFA in nonoperated limbs (n = 8)	87.1 ± 2	87.9 ± 0.8	0.221 (Wilcoxon)
MPTA	MPTA in total limbs (n = 12)	83.5 ± 2.8	88.3 ± 2.5	0.005
	MPTA in operated limbs (n = 10)	82.6 ± 1.8	88.5 ± 2.7	0.005
	MPTA in nonoperated limbs (n = 2)	88.5 ± 0.7	87.5 ± 0.7	0.157

Note: Bold values were considered statistically significant.

Abbreviations: LDFA, lateral distal femoral angle; MPTA, medial proximal tibial angle.

months, while the males had an average age of 12 years and 5 months. Out of all the cases, 14 patients (25 limbs) had genu valgum, while six patients (12 limbs) had genu varum. The mean follow-up time was 11 ± 5.7 months. The data collected during the study, such as age, follow-up time, and pre- and postoperative angles for each case, are presented in Table 1.

To detect the location of angular deformities, the mechanical lateral distal femoral angle (mLDFA) and the mechanical medial proximal tibial angle (mMPTA) were used. A reference point of 87 ± 2 degrees was established as the normal value for these angles by comparing them to the location of hemiepiphysodesis. Table 2 presents the details of the deformities that were examined in the study.

A group of 14 patients (25 limbs) with genu valgum deformity underwent hemiepiphysodesis procedures, with a nearly equal number of surgeries performed on either the distal femur or proximal tibia (16 proximal tibias and 15 distal femurs, as indicated in Table 2).

The mean follow-up time for the genu valgum group was 10.7 ± 5.1 months, calculated from the date of implantation to the date of removal. Both the distal femoral and proximal tibial hemiepiphysodesis procedures had a similar rate of correction for genu valgum, specifically 0.59° per month (Table 3).

Among the six patients (12 limbs) with genu varum deformity, the proximal tibia was the most frequently affected site (Table 2). The mean follow-up time for this group, from the time of implantation to removal, was 11.5 ± 6.3 months. In proximal tibia lateral hemiepiphysodesis, the rate of correction for genu varum was 0.85° per month, while in distal femoral lateral hemiepiphysodesis, it was 0.15° per month (Table 4).

Only one case (No. 3 in Table 1) of under-correction was identified in the study, and it was found to be caused by the early closure of the physal plate. This particular patient was implanted before the age of 12, which resulted in the cessation of physal growth and ultimately led to incomplete correction of the deformity.

4 | DISCUSSION

The most important finding of the current study was that utilizing a 3-hole tension band plate and two cortical screws for hemiepiphysiodesis is a safe and efficient method for correcting the coronal alignment of the lower extremities.

The peri-genicular physeal plates are responsible for approximately 75% of lower limb growth, and any intervention that interferes with their function can lead to significant changes in both limb alignment and length. Hemiepiphysiodesis procedures have been implemented using different techniques, including stapling, tension-band plating,^{6,7,17-19} and transphyseal screws.^{18,20,21} All of these techniques have proven to be effective in inducing temporary growth arrest, and normal growth will resume once the implant is removed. The extraperiosteal positioning of the tension band plate offers the advantage of facilitating implantation and removal without causing damage to the physeal plate. As a result, there is no need for precise calculation of remaining growth, which enables the device to be used for any age before maturation.^{2,4,22} With the increasing popularity of hemiepiphysiodesis techniques, there has been a corresponding rise in the variety of plates used for the procedure. According to research, using 8-plates with two holes is associated with a lower complication rate than R-plates. However, it does come at a higher cost compared to the latter option.^{1,6,19}

Stevens et al. conducted a study to evaluate the efficacy of using a 2-hole extraperiosteal plate and two nonlocking screws for treating knee angular deformities in 34 patients. It was found that only one out of the two recalcitrant Blount's disease patients required revision of fixation due to screw loosening, whereas none of the idiopathic patients experienced any complications related to screw loosening.¹⁷ Another study evaluated the outcomes of temporary hemiepiphysiodesis in 21 patients with bilateral angular deformities around the knee using a 2-hole R-plate and two 4 mm solid cancellous screws. The results showed that six screws failed and had to be replaced with solid 4.5 or 3.5 mm cortical screws.¹⁴

In our study, the 3.5 mm cortical screw with a 2.7 mm core diameter (standard screw) and a 3.5 mm, 3-hole reconstruction plate were utilized, and we were fortunate enough not to encounter any instances of screw failure during the procedure. The fatigue strength of a screw is greatly influenced by its core diameter, which has a direct impact on the stress and strains the screw can endure over time. This relationship follows the fourth power rule, highlighting the essential nature of carefully selecting the appropriate screw size to ensure the long-term success and stability of hemiepiphysiodesis procedures.^{23,24} Consistently, a fatigue life analysis of small fragment screws verified that 4 mm cancellous screws with a 2.8 mm core diameter had a longer fatigue life than 4 mm cancellous screws, with a core diameter of 1.9 mm.²³ Aside from core diameter, improper tightening of the screw and insufficient contouring or contact of the plate near the bone can also contribute to screw failure in hemiepiphysiodesis procedures.²⁵ Thus, to avoid any potential loosening, we needed to focus intently and make sure all screws were tightened fully.

Danino et al.²² retrospectively examined 537 patients (967 limbs) with knee coronal deformities of different origins in a multicenter study. The rate of correction for mMPTA and mL DFA was found to be 0.79° per month and 0.77° per month, respectively. There was no statistically significant difference between the femoral and tibial changes. Tibial and femoral deformities were corrected to normal alignment in 80% and 70% of cases, respectively. Also, according to a study by Burghardt and Herzenberg,⁷ hemiepiphysiodesis using an 8-plate successfully corrected varus or valgus knee deformities in 90% of 43 patients. A total of 54 physes from 51 limbs underwent this procedure, and all 8-plates were removed without complications. The study also reported that the monthly correction rate for mL DFA was 0.65°, while it was 0.58° for mMPTA. In the current study, we found that genu valgum hemiepiphysiodesis, medial distal femur hemiepiphysiodesis, and medial proximal tibial hemiepiphysiodesis had similar corrective effects with an average correction rate of 0.59° per month. However, in genu varum hemiepiphysiodesis, lateral proximal tibial hemiepiphysiodesis was more effective than lateral distal femur hemiepiphysiodesis, with an average correction rate of 0.85° and 0.15° per month, respectively. Additionally, it is worth noting that the plate used in the distal femoral growth has a slower growth rate of only 6 mm per year compared to the proximal tibia despite the faster growth rate of the distal femur (9 mm/year).²⁶

It is important to note that our study did not investigate the relationship between body mass index (BMI) and screw failure rates after hemiepiphysiodesis. However, prior research has yielded conflicting results on this topic. For example, Aslani et al.¹⁴ found no significant differences in screw failure rates among patients with varying BMIs who underwent medial distal femoral hemiepiphysiodesis using a screw. In contrast, other studies have suggested that higher BMIs may increase the risk of screw failure after hemiepiphysiodesis using screws.¹⁶

Our study utilized a 3-hole R-plate with two 3.5 mm cortical screws for temporary hemiepiphysiodesis and found no implant failure or screw loosening. In valgus knees, there was an average correction rate of approximately 0.59° per month for both mL DFA and mMPTA, while in varus knees, the average correction rates were approximately 0.15° and 0.85° per month, respectively. However, further studies with larger sample sizes are needed to validate these findings and determine their generalizability across different patient populations, particularly those involving idiopathic deformities. Future research should investigate the long-term outcomes of using 3-hole R-plates for hemiepiphysiodesis to correct lower limb alignment and compare its efficacy with other methods.

It is important to acknowledge the limitations of this study when interpreting our findings. The sample size in the genu varum group was relatively small, which may limit the applicability of our conclusions. Additionally, our follow-up duration only assessed complications until plate removal, and, therefore, may not capture the full long-term outcomes of the procedure. Furthermore, we did not compare the outcomes of hemiepiphysiodesis using a 3-hole plate with other devices, such as the 8-plate.

5 | CONCLUSION

Temporary hemiepiphyodesis with a 3-hole R-plate and two cortical screws takes advantage of physiological physeal growth to successfully treat idiopathic angular deformities with low complication rates. It seems that proximal tibial hemiepiphyodesis in varus knees results in a higher correction rate compared to distal femoral or proximal tibial hemiepiphyodesis in valgus knees. Based on these findings, the authors recommend temporary hemiepiphyodesis with a 3-hole R-plate and two cortical screws as a safe and effective treatment option for immature patients with idiopathic angular deformities who are still undergoing bone growth.

AUTHOR CONTRIBUTIONS

Arash Maleki: Conceptualization; investigation; methodology. **Mohamad Qoreishi:** Data curation; investigation; methodology. **Amir Bisadi:** Writing—review and editing. **Farshad Safdari:** Investigation; writing—original draft. **Amin Daei Sorkhabi:** Formal analysis; investigation; writing—original draft; writing—review and editing. **Ali Fotouhi:** Conceptualization; formal analysis; investigation; supervision; validation. **Mohammad A. Tahririan:** Data curation; investigation; validation.

CONFLICT OF INTEREST STATEMENT

The authors declare no conflict of interest.

DATA AVAILABILITY STATEMENT

The data sets used and/or analyzed during the present study are available from the corresponding author on reasonable request.

ETHICS STATEMENT

The local ethical committee of the Shahid Beheshti University of Medical Sciences approved the study for Children's Orthopedics and Trauma Surgery.

TRANSPARENCY STATEMENT

The lead author Ali Fotouhi affirms that this manuscript is an honest, accurate, and transparent account of the study being reported; that no important aspects of the study have been omitted; and that any discrepancies from the study as planned (and, if relevant, registered) have been explained.

ORCID

Amin Daei Sorkhabi  <http://orcid.org/0000-0001-6975-0748>

REFERENCES

- Kumar A, Gaba S, Sud A, Mandlecha P, Goel L, Nayak M. Comparative study between staples and eight plate in the management of coronal plane deformities of the knee in skeletally immature children. *J Child Orthop*. 2016;10(5):429-437.
- Goyeneche RA, Primomo CE, Lambert N, Miscione H. Correction of bone angular deformities: experimental analysis of staples versus 8-plate. *J Pediatr Orthop*. 2009;29(7):736-740.
- Tahririan MA, Mohammadsharifi G. Correction of the knee coronal plane deformity using the screws plus reconstruction plate versus cannulated screws. *Orthop Traumatol, Surg Res*. 2020;106(7):1345-1351.
- Wiemann JMT, Tryon C, Szalay EA. Physeal stapling versus 8-plate hemiepiphyodesis for guided correction of angular deformity about the knee. *J Pediatr Orthop*. 2009;29(5):481-485.
- Kumar S, Sonanis SV. Growth modulation for coronal deformity correction by using eight plates-systematic review. *J Orthop*. 2018;15(1):168-172.
- Schroerlucke S, Bertrand S, Clapp J, Bundy J, Gregg FO. Failure of orthofix eight-plate for the treatment of Blount disease. *J Pediatr Orthop*. 2009;29(1):57-60.
- Burghardt RD, Herzenberg JE. Temporary hemiepiphyodesis with the eight-plate for angular deformities: mid-term results. *J Orthop Sci*. 2010;15:699-704.
- Boero S, Michelis MB, Riganti S. Use of the eight-plate for angular correction of knee deformities due to idiopathic and pathologic physis: initiating treatment according to etiology. *J Child Orthop*. 2011;5(3):209-216.
- Wiemann JM, Tryon C, Szalay EA. Physeal stapling versus 8-plate hemiepiphyodesis for guided correction of angular deformity about the knee. *J Pediatr Orthop*. 2009;29:481-485.
- Bylski-Austrow DI, Wall EJ, Rupert MP, Roy DR, Crawford AH. Growth plate forces in the adolescent human knee: a radiographic and mechanical study of epiphyseal staples. *J Pediatr Orthop*. 2001;21(6):817-823.
- Stevens PM, Maguire M, Dales MD, Robins AJ. Physeal stapling for idiopathic genu valgum. *J Pediatr Orthop*. 1999;19(5):645-649.
- Métaizeau JP, Wong-Chung J, Bertrand H, Pasquier P. Percutaneous epiphyseodesis using transphyseal screws (PETS). *J Pediatr Orthop*. 1998;18(3):363-369.
- Stevens PM, Klatt JB. Guided growth for pathological physes: radiographic improvement during realignment. *J Pediatr Orthop*. 2008;28(6):632-639.
- Aslani H, Panjavy B, Bashy R, Tabrizi A, Nazari B. The efficacy and complications of 2-Hole 3.5 mm reconstruction plates and 4 mm noncannulated cancellous screws for temporary hemiepiphyodesis around the knee. *J Pediatr Orthop*. 2014;34(4):462-466. doi:10.1097/BPO.0000000000000115
- Park KH, Oh CW, Kim JW, Park IH, Kim HJ, Choi YS. Angular deformity correction by guided growth in growing children: eight-plate versus 3.5-mm reconstruction plate. *J Orthop Sci*. 2017;22(5):919-923.
- Burghardt RD, Specht SC, Herzenberg JE. Mechanical failures of eight-plate-guided growth system for temporary hemiepiphyodesis. *J Pediatr Orthop*. 2010;30(6):594-597.
- Stevens PM. Guided growth for angular correction: a preliminary series using a tension band plate. *J Pediatr Orthop*. 2007;27(3):253-259.
- Shin SJ, Cho TJ, Park MS, et al. Angular deformity correction by asymmetrical physeal suppression in growing children: stapling versus percutaneous transphyseal screw. *J Pediatr Orthop*. 2010;30(6):588-593.
- Sahoo P, Das S, Pradhan S, Mohanty R. Our experience with correction of angular deformities of knee by flexible figure of 8-plate hemiepiphyodesis. *Indian J Physic Med Rehab*. 2012;23:68-73.
- Goldman V, Green DW. Advances in growth plate modulation for lower extremity malalignment (knock knees and bow legs). *Curr Opin Pediatr*. 2010;22(1):47-53.
- Khoury JG, Tavares JO, McConnell S, Zeiders G, Sanders JO. Results of screw epiphyseodesis for the treatment of limb length discrepancy and angular deformity. *J Pediatr Orthop*. 2007;27:623-628.

22. Danino B, Rödl R, Herzenberg J, et al. Guided growth: preliminary results of a multinational study of 967 physes in 537 patients. *J Child Orthop*. 2017;12:1-6.
23. Merk BR, Stern SH, Cordes S, Lautenschlager EP. A fatigue life analysis of small fragment screws. *J Orthop Trauma*. 2001;15:494-499.
24. Brown GA, McCarthy T, Bourgeault CA, Callahan DJ. Mechanical performance of standard and cannulated 4.0-mm cancellous bone screws. *J Orthop Res*. 2000;18(2):307-312.
25. Morrison SG, Shah SA, Garg S, Bruce CE. Screw failure in hemiepiphysiodesis: a systematic review. *J Child Orthop*. 2017;11(5):325-331.
26. Menelaus MB. Correction of leg length discrepancy by epiphysial arrest. *J Bone Joint Surg Br*. 1966;48(2):336-339.

How to cite this article: Maleki A, Qoreishi M, Bisadi A, et al. The efficacy of hemiepiphysiodesis for idiopathic knee coronal angular deformity by reconstruction plate and screw: A pilot study. *Health Sci Rep*. 2023;6:e1302.
[doi:10.1002/hsr2.1302](https://doi.org/10.1002/hsr2.1302)