

Case Reports

IUD Appendicitis During Pregnancy

DAVID I. McLAUGHLIN, MD
WILLIAM BEVINS, MD
BENJAMIN K. KARAS, MD
LARRY SONNENBERG, MD
Red Lodge, Montana

AN INTRA-ABDOMINAL INTRAUTERINE DEVICE (IUD) was found during an appendectomy in a 29-year-old woman who was 20 weeks pregnant. The IUD had apparently been lost about seven years previously, when she became pregnant shortly after it was inserted. Abdominal and pelvic x-ray films during the third trimester of that pregnancy were interpreted as normal, and she went on to have a normal vaginal delivery. Appendicitis developed at 20 weeks' estimated gestational age with the next pregnancy seven years later.

Report of a Case

The patient, a 29-year-old woman—gravida 4, para 3, living children 3—whose last menstrual period was October 20, 1986, had an ultrasound study done in mid-April 1987 because of poor size-dates correlation; from the results, the expected date of confinement was determined to be August 29, 1987. On the morning of admission, right lower quadrant pain developed that became progressively worse and was associated with nausea, anorexia, and fever and chills. On abdominal examination she had good bowel sounds. She had pain referred from all areas of her right lower quadrant, centered just above McBurney's point. She had minimal guarding but dramatic rebound tenderness and a positive right psoas sign. The uterine fundus was at the umbilicus, and the fetal heart tones were 150 beats per minute. On rectal examination she was tender along the right posterior pelvic wall. A pelvic examination showed no abnormalities. Her leukocyte count on admission was 16,400 per μl .

At laparotomy, the cecum and appendix were both noted to be bound down inferior and posterior to an inflammatory mass that also involved the inferior portion of the broad ligament and the sigmoid colon. The right tube and ovary were free of involvement. The tip of the appendix was gently freed from the mass, and an appendectomy was done. A small whitish blue string was noted protruding superiorly out of the mass, and, with gentle traction, the string was partially exposed and identified as the tail of an IUD. The IUD was then removed with blunt dissection and gentle traction, and it was noted to be copper-coated. A culture of the IUD eventually grew *Escherichia coli*, but peritoneal cultures failed to grow any bacteria. A Penrose drain was left in the pelvic gutter, and the abdomen was closed. The patient had an uneventful recovery on a regimen of intravenous cefoxitin (Mefoxin).

Discussion with the patient after the operation revealed

that she had an IUD placed about eight years before admission, at which time she had had moderate right lower quadrant pain. The pain quickly resolved, but she continued to have intermittent, low-grade right lower quadrant pain. About five months after placement, she had an episode of severe right lower quadrant pain; she went to an emergency department and was found to be pregnant. The results of a vaginal examination at the time and abdominal and pelvic x-ray films at nine months of gestation were thought to be consistent with an expelled IUD (Figure 1). That pregnancy resulted in an uncomplicated vaginal delivery in March of 1980. During the past seven years, she had continued to have episodic right lower quadrant pain of mild to moderate severity.

After the appendectomy, she went on to have a normal prenatal course, but after induction for postconfinement dates failed, she required a primary, low-transverse cesarean section. At cesarean section, dense adhesions were noted between the right posterior side of the uterus and the posterior pelvic wall. Dense adhesions also involved the right broad ligament, right ovary, and the right fallopian tube. The previous inflammatory mass was not palpable at this time. Recovery from the cesarean section was uneventful.

Pathologic Findings

On microscopic examination of the appendix, the full thickness of the wall was infiltrated with sheets of neutrophils. No fecaliths were noted in the appendix.

Discussion

The disappearance of an IUD may be due to either tail retraction, expulsion, or perforation. Any missing IUD should be aggressively sought, even if lost within the first year. It is estimated that the rate of expulsion is 2% to 20% within the first year and especially the first three months.¹ Expulsion and perforation seem to be more common after either an abortion or delivery.¹ The basic workup for a missing IUD includes abdominal radiographs, ultrasonography, or contrast hystero-graphy.

The incidence of uterine perforation has been reported as somewhere in the range of 1 per 350 to 1 per 2,500.² The cause of perforation is probably a combination of traumatic insertion and erosion of the device through the uterine wall. Complications of perforation include either chronic or acute inflammation or penetration of a hollow viscus, such as the bladder with subsequent stone formation, the small intestine with the development of small bowel obstruction, and the large intestine. The estimated incidence of these types of complications after perforation is as high as 15%.³

The penetration of hollow viscera is facilitated by at least one of three mechanisms: primary penetration, migration, or inflammation.⁴ Primary penetration may occur when the IUD is traumatically inserted through the uterine wall into an organ juxtaposed to the uterus. Migration to an adjacent organ may occur through facilitation by the omentum or by an enlarging pregnant uterus. Inflammation plays an important role in the pathogenesis of penetration because most documented cases involved devices that contained copper, which is inflammatory.⁴⁻⁸

The present case illustrates several interesting points con-

(McLaughlin DI, Bevins W, Karas BK, et al: IUD appendicitis during pregnancy. *West J Med* 1988 Nov; 149:601-602)

From the Billings Clinic, Red Lodge, Montana.
Reprints are not available.

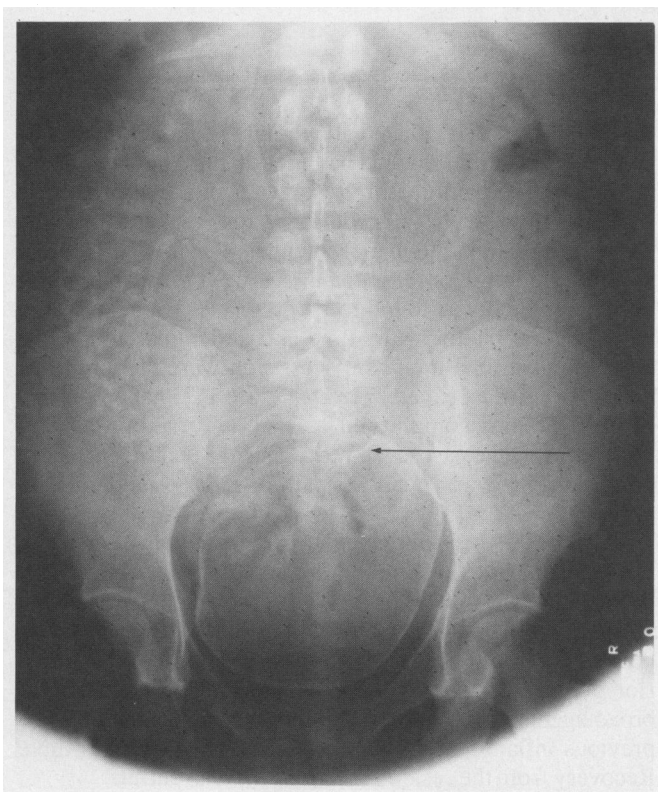


Figure 1.—A pelvic x-ray film taken in March 1980 shows a gravid uterus at term and an intrauterine device in the right pelvic area.

cerning uterine penetration by an IUD. First, an initial workup with a plain film of the abdomen was misinterpreted and the intra-abdominal position of the IUD missed. This was probably due to a near-term gravid uterus. Second, the point when complete uterine perforation occurred is unknown, but it was presumably before her third child was conceived. Her uterus was most likely partially perforated with insertion of the device, and over the following two to three months complete perforation occurred. The periodic pain she experienced after that pregnancy was probably related to episodic exacerbation of chronic, low-grade inflammation in the mass surrounding the IUD. Third, as the gravid uterus grew, the inflammation surrounding the IUD eventually involved the appendix, and acute appendicitis developed. Finally, reexamination of the pelvis at cesarean section showed that the inflammatory mass had been replaced with dense adhesions that now included the right adnexa, which had previously been free of the pathologic process.

Summary

This case shows that abdominal and pelvic x-ray examinations may not adequately show a misplaced IUD in a gravid woman, and further workup is necessary after delivery if the IUD is not clearly visible on the initial x-ray films. It also shows that chronic inflammation may develop in the area of a misplaced IUD, producing chronic abdominal pain and complications, even after several years have transpired. Finally, patients may still be at risk for complications after an IUD has been removed because of the dense adhesions that develop due to the chronic inflammatory response elicited by the IUD.

REFERENCES

1. Gorsline JC, Osborne NG: Management of the missing intrauterine contraceptive device: Report of a case. *Am J Obstet Gynecol* 1985; 153:228-229

2. Moodley TR: Unusual displacement of an intra-uterine contraceptive device—A case report. *S Afr Med J* 1984; 66:110
3. Zakin D, Stern WZ, Rosenblatt R: Complete and partial uterine perforation and embedding following insertion of intra-uterine devices—I. Classification, complications, mechanism, incidence, and missing string. II. Diagnostic methods, prevention, and management. *Obstet Gynecol Surv* 1981; 36:335-353, 401-417
4. Serra I: Appendicitis caused by an intrauterine contraceptive device. *Br J Surg* 1986; 73:927-928
5. McWhinney NA, Jarrett R: Uterine perforation by a Copper 7 intrauterine contraceptive device with subsequent penetration of the appendix—Case report. *Br J Obstet Gynecol* 1983; 90:774-776
6. Goldman JA, Peleg D, Feldberg D, et al: IUD appendicitis. *Eur J Obstet Gynecol Reprod Biol* 1983; 15:181-183
7. Rubinoff ML: IUD appendicitis. *JAMA* 1975; 231:67-68
8. Carson SA, Gatlin A, Mazur M: Appendiceal perforation by Copper-7 intra-uterine contraceptive device. *Am J Obstet Gynecol* 1981; 141:586-587

Diabetic Ketoacidosis Following Pentamidine Therapy in a Patient With the Acquired Immunodeficiency Syndrome

MARK W. LAMBERTUS, MD
ARUNA R. MURTHY, MD
PAMELA NAGAMI, MD
MATTHEW BIDWELL GOETZ, MD
Sepulveda, California

GLUCOSE INTOLERANCE and insulin-requiring diabetes mellitus are well-described complications of pentamidine therapy that often follow episodes of hypoglycemia occurring during the use of the drug. These disorders are due to a direct cytotoxic effect of pentamidine on insulin-producing pancreatic β -cells. Searching the literature, we found only one reported case, appearing as an abstract, of ketoacidosis associated with pentamidine-induced diabetes mellitus, despite its now frequent use to treat *Pneumocystis carinii* pneumonia in patients with the acquired immunodeficiency syndrome (AIDS). Herein we report the case of a patient with insulin-requiring diabetes mellitus due to pentamidine therapy in whom increased insulin requirements developed and who had diabetic ketoacidosis following treatment with pentamidine of a second episode of *P carinii* pneumonia.

Report of a Case

The patient, a 42-year-old male homosexual, was admitted in October 1986 with fever, dyspnea, and interstitial infiltrates on chest films. The patient had no history of diabetes mellitus, and his fasting serum glucose level on admission was 5.7 mmol per liter (102 mg per dl). Bronchoscopy showed *P carinii*, confirming the clinical suspicion of AIDS, and a regimen of trimethoprim-sulfamethoxazole was started. The patient responded to therapy, but a pruritic drug eruption developed, and his therapy was switched to pentamidine isethionate, 4 mg per kg body weight for 15 days. On day 5 of pentamidine treatment, hypoglycemia developed, with serum glucose values between 2.2 and 2.8 mmol per liter (40 and 50 mg per dl). The patient subsequently had

(Lambertus MW, Murthy AR, Nagami P, et al: Diabetic ketoacidosis following pentamidine therapy in a patient with the acquired immunodeficiency syndrome. *West J Med* 1988 Nov; 149:602-604)

From the Department of Medicine, Division of Infectious Diseases, Veterans Administration Medical Center, Sepulveda, California, and the University of California, Los Angeles, School of Medicine.

Reprint requests to Matthew Bidwell Goetz, MD, Infectious Diseases Section, 111-D, Sepulveda VA Medical Center, 16111 Plummer St, Sepulveda, CA 91343.