

# Case Reports

## Acute Oleander Poisoning A Suicide Attempt in a Geriatric Patient

DAVID A. DRIGGERS, MD  
RONALD SOLBRIG, MD  
JOSEPH F. STEINER, PharmD  
JAY SWEDBERG, MD  
GARY S. JEWELL, MD  
Casper, Wyoming

THE COMMON OLEANDER PLANT is one of several families of plants that have been shown to contain nondigitalis cardiac glycosides. Oleander is an idiom for plants of the *Nerium oleander* L, *Nerium indicum*, and *Nerium odorum* species. Common names include soland, lorier bol, rosebay, and rose laurel. These plants are widely distributed throughout the tropical to the subtemperate zones of the world and in the United States are frequently found from South Carolina west to California and points south. Their decorative flowers and prolific growth make them popular shrubs for landscaping. They also may be found growing wild.<sup>1</sup>

The oleander's widespread prevalence and alluring flowers make it a particular hazard for accidental ingestion by small children, and most documented cases of human poisoning by this plant have occurred in the pediatric population.<sup>1</sup> The plant also has shown toxicologic importance for accidents when used in folk medicines when adults unknowingly eat parts of the plant or food that has come into contact with the plant, such as hot-dog sticks, and in homicides or suicides. Also, as our case illustrates, toxicities are not limited to temperate climates.<sup>2</sup>

All parts of the plant contain cardiac glycosides, including the roots and the smoke produced from burning, as heat does not inactivate the glycosides. The major toxic effects are similar to those of a digitalis overdose. This includes direct glycoside poisoning of the sodium-potassium pump of the heart and increased vagotonia. Most symptoms from oleander poisoning are cardiac and gastrointestinal in nature. Central nervous system disturbances and death may follow.<sup>1-4</sup>

We report a case of intentional oleander ingestion by a nursing home patient after she allegedly received the oleander plant from a mail-order service she located through an advertisement in a periodical.

### Report of a Case

The patient, an 83-year-old resident of a nursing home, was discovered on the morning of admission to be combative and semilucid. A mug with a small amount of brownish material was found at the patient's bedside, and an ingestion of some type was suspected. On arrival in the emergency department, the patient reported that she had drunk oleander tea the night before. Her medical history included severe

osteoporosis, degenerative osteoarthritis, arteriosclerotic heart disease, and overflow incontinence of the bladder, for which she was taking naproxen sodium 500 mg twice a day, trazodone hydrochloride 50 mg at bedtime, triazolam 0.125 mg at bedtime, calcium carbonate, and conjugated estrogen daily. She had experienced no decline in her mental faculties, and her admission to the nursing home was purely on the basis of her physical debility. She had no known allergies.

On initial examination, the patient's blood pressure was 102/50 mm of mercury, with a pulse rate of 40 per minute. Her mental status alternated between periods of combativeness and semilucidity. Examination of her head, eyes, ears, nose, and throat revealed pupils that were equal and reactive to light and accommodation. Her extraocular motor muscles were intact. Her chest and lungs were clear to auscultation and percussion. Cardiovascular examination showed an irregular rhythm, with a grade 3/6 holosystolic murmur heard over the left sternal border. On abdominal examination there was no hepatosplenomegaly, and bowel sounds were active. Deep tendon reflexes were 2+ and equal.

In the emergency department, a cardiac monitor strip revealed no apparent atrial activity, with a ventricular rate of 35 to 45. The QRS interval was 0.138 seconds. The patient was given 0.5 mg of intravenous atropine sulfate, which resolved her bradycardia. Atropine at the same dosage was given twice during the first several hours of her hospital stay because her bradycardia recurred. Her mental status did not improve with the resolution of her bradycardia. A 12-lead electrocardiogram after atropine had been given showed atrial fibrillation with nonspecific ST segment changes and intraventricular conduction delay. The patient was given activated charcoal in a 70% sorbitol slurry and appropriate intravenous fluids and was admitted to the intensive care unit. Initial laboratory studies revealed a serum sodium level of 121 mmol per liter (mEq per liter), a potassium of 6.1 mmol per liter (mEq per liter), and a digoxin concentration of 7.1 ng per ml.

For the next 36 hours, the patient's condition remained stable, and she had a gradual resolution of her hyponatremia, hyperkalemia, and elevated digoxin levels (Table 1). On the third day of her hospital stay, she was transferred to the psychiatric unit, where she gradually became more conversant, calmer, and was able to address her concerns about autonomy and dignity during the waning years of her life. She was then discharged from the hospital to a different nursing home.

### Discussion

Several families of plants, including foxglove and oleander, have been identified as containing cardiac glycosides. These glycosides may include oleandrin, oleandroside, nerioside, digitoxigenin, thevetin, and thevetoxin.<sup>2-4</sup> Although some of these glycosides have therapeutic properties—William Withering, in his classic account from 1795, described treating dropsy with foxglove—exposure to these plants in toxic amounts may induce cardiotoxic effects as well as gastrointestinal symptoms. The cardiac glycosides in oleander produce more gastrointestinal effects than those in digoxin, and the symptoms range from nausea and vomiting to cramping and bloody diarrhea. In addition, oleander may

(Driggers DA, Solbrig R, Steiner JF, et al: Acute oleander poisoning—A suicide attempt in a geriatric patient. *West J Med* 1989 Dec; 151:660-662)

From the Family Practice Residency Program at Casper, Department of Clinical Pharmacy (Dr Steiner), University of Wyoming School of Human Medicine.

Reprint requests to Gary S. Jewell, MD, University of Wyoming Family Practice Residency Program at Casper, 1522 East A St, Casper, WY 82601.

TABLE 1.—Laboratory Values in an 83-Year-Old Woman With Possible Oleander Poisoning

Laboratory Measurements	Day 1				Day 2	Day 3		Day 6
					Time			
	0810	1355	1605	2015	0535	0650	2040	0650
Sodium, mmol/liter	121.0	124.0	119.0	123.0	123.0	126.0	130.0	136.0
Potassium, mmol/liter	6.1	5.6	4.4	4.3	3.4	3.9	3.5	4.1
Digoxin, ng/ml	>7.1	4.6	.....	3.5	1.8	0.8	1.1	Not drawn

cause irritation to the mucosal membranes, resulting in burning around the mouth and increased salivation. Confusion, dizziness, drowsiness, weakness, visual disturbances, and mydriasis are central nervous system manifestations of toxicity.<sup>2,3,5,6</sup>

The most serious side effects of oleander poisoning are cardiac. Various ventricular dysrhythmias and tachyarrhythmias have been described. Bradycardia and heart block are the most frequently reported cardiac abnormalities.<sup>1,3-5,7-9</sup> Electrocardiography often reveals an increased PR interval, a decreased QRS-T interval, and T wave flattening or inversion.<sup>4</sup> One investigator described anterolateral wall ischemic changes in a 22-year-old.<sup>8</sup> It is thought that these clinical manifestations are the result of both increased vagotonia and direct cardiac glycoside toxicity.<sup>2,6</sup> An interesting primary effect of the digitalis is the disruption of the normal sodium-potassium adenosine triphosphatase (ATPase) activity within the cell membrane.<sup>2,3,6</sup> If we assume a similar phenomenon with glycosides found in oleander leaves, this toxicity should manifest itself by an elevation in the serum potassium level and a depression in the serum sodium level, as noted in our patient. Insulin and glucose infusion to correct the hyperkalemia may be less effective because of the disruption of the ATPase-dependent pump.<sup>4</sup>

The treatment of oleander poisoning is empirically based on the treatment of digitalis-glycoside toxicity and consists of supporting the patient hemodynamically. This may include administering atropine for severe bradycardia; using phenytoin or lidocaine hydrochloride to control dysrhythmias; placing a temporary venous pacemaker; or electrical countershock.<sup>4,6,10</sup> Although not tested in humans, dipotassium edetate, a calcium chelating agent, has been shown to be successful in treating oleander overdose in cats.<sup>11</sup>

Administering digoxin-specific Fab antibody fragments (Digibind) also has been advocated.<sup>3</sup> In our patient, Digibind therapy was held in reserve because of her rapid recovery and our lack of adequate clinical experience using this substance. The only report on the use of digoxin-specific Fab antibody for oleander poisoning was in a patient with a digoxin level of 1.5 ng per ml and irregular bradycardia.<sup>3</sup> It must be remembered that the digoxin level indicates an unknown portion of the total glycosides<sup>2,9</sup> and that Digibind binds with an unknown portion of the total glycosides. The use of digoxin-specific antibodies prevents further monitoring with digoxin levels.<sup>3</sup>

Other treatment methods are aimed at removing the toxic substance from the stomach by emesis. Special concern must be given to a patient with bradycardia before emesis is induced because of the possibility of a vagal reaction and worsening of the bradycardia.

Unabsorbed glycosides may be bound to some extent, depending on the particular glycoside, by various binding agents in the gut. These agents theoretically should be more

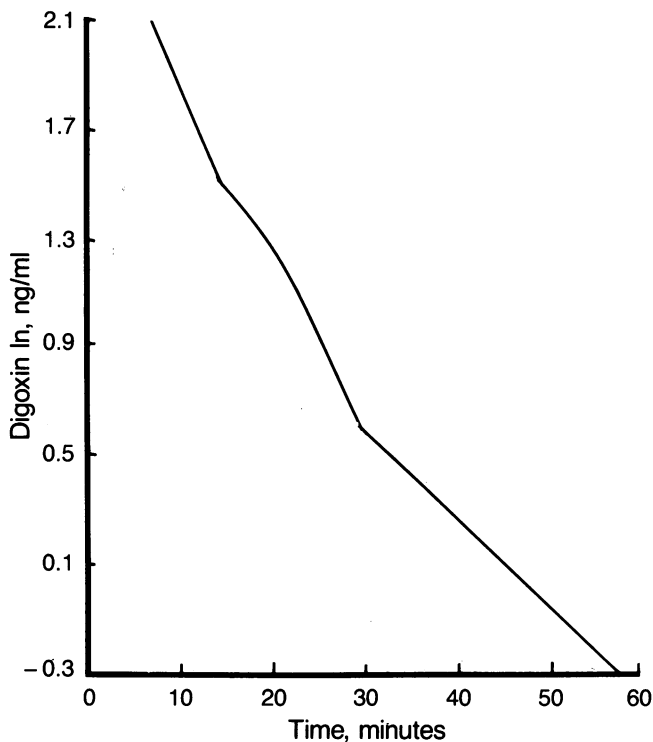
effective in absorbing less polar glycosides, such as digoxin, than the more polar glycosides like digoxin (for example, cholestyramine resin and colestipol). The use of these agents is not thought to have substantial value in the treatment of advanced toxicity, and they were not used in our patient.<sup>12</sup> Dialysis has also been shown to be of little benefit in ameliorating digitalis toxicity.<sup>9,10</sup>

Activated charcoal has been shown to be useful in preventing further absorption of the cardiac glycosides and was used. In these circumstances, activated charcoal is most effective when used soon after ingestion of the toxin; however, it also may be of therapeutic benefit by its interruption of the enterohepatic circulation of the glycoside. Unfortunately, not all glycosides are involved in the enterohepatic circulation sufficiently to be affected by intermittent charcoal therapy.<sup>12</sup> It is unknown if the glycosides of oleander have enterohepatic circulation, but administering activated charcoal is usually without risk and may be beneficial.

The cross-reactivity seen between digoxin radioimmunoassays and the glycosides of oleander is well known.<sup>2</sup> This cross-reactivity can at least identify the presence of a cardioactive glycoside in the case of an unknown poisoning. Beyond its qualitative usefulness in oleander toxicity, however, the digoxin serum level's clinical significance is unknown. The digoxin radioimmunoassay is not specific for all of the glycosides that may be present in the oleander plant. Cheung and co-workers report radioimmunoassay results on known aliquots of *N oleander* (white, pink oleander) and *N thevetia peruviana* (yellow oleander) mixed in pooled, drug-free human serum. These results indicate that relatively low serum concentrations—2 grams of leaf extract diluted 2,560- to 128,000-fold—give serum levels of 0.5 to 3 ng per ml.<sup>9</sup> This correlates with reports of death after ingestion of one or two leaves or one seed.<sup>1,3,6,9,13</sup>

In a previous report, a fatal case of oleander overdose was documented with an apparent digoxin level of 1.2 ng per ml and a postmortem level of 6.4 ng per ml.<sup>4</sup> The authors speculated that this may be because of postmortem redistribution of the drug and a difference in cross-reactivity with oleander for the two assays used. Our patient survived with a level of 7.1 ng per ml measured using the radioimmunoassay technique of the Mayo Clinic laboratory. There appears to be a linear relationship established for the digoxin serum level (natural log) and time, with a half-life of approximately 13 hours (Figure 1). It is unknown exactly what is being measured, however, and because the amount of cross-reactivity is unknown, the use of a digoxin radioimmunoassay in oleander toxicity will only indicate the presence of glycoside and may not indicate the degree of toxicity.

It is interesting that our patient's mental state did improve as the assayed digoxin serum level declined. A digitalis overdose can cause delirium, but whether this is due to serum hyponatremia and central nervous system intracellular hy-



**Figure 1.**—Digoxin serum concentration versus time, in minutes, is shown.

pernatremia is unknown. Using the crude cross-reactivity figures mentioned by Osterloh and colleagues, our patient had a serum level of approximately 700 ng per ml of cardenolides.<sup>2</sup> Their 96-year-old patient had a much lower level and succeeded in her suicide attempt. Her sodium level was high at 161 mmol per liter and her hyperkalemia worse at a potassium level of 8.3 mmol per liter. Why our patient survived is unknown. Differences in age, organ system health, oleander species, and in poison preparation are all possibilities.

The social aspects of this case are probably more important than the medical. Specifically, oleander is grown throughout the warm climates of the United States, with large sections of highway medians in California planted with it. Knowledgeable members of the geriatric population realize that oleander poisoning can be fatal with relatively small amounts ingested. Osterloh and associates calculated the lethal oleander leaf dose of their patient at approximately 4 grams.<sup>2</sup> Practicing physicians need to understand the potential lethal properties of oleander and its availability throughout the country. This is especially the case for geriatric patients because the suicide rate in those older than 65 years is higher than in any other age group and is projected to increase.<sup>14</sup>

#### REFERENCES

1. Ansford AJ, Morris H: Fatal oleander poisoning. *Med J Aust* 1981; 1:360-361
2. Osterloh J, Herold S, Pond S: Oleander interference in the digoxin radioimmunoassay in a fatal ingestion. *JAMA* 1982; 247:1596-1597
3. Shumaik GM, Wu AW, Ping AC: Oleander poisoning: Treatment with digoxin-specific Fab antibody fragments. *Ann Emerg Med* 1988; 17:732-735
4. Haynes BE, Bessen HA, Wightman WD: Oleander tea: Herbal draught of death. *Ann Emerg Med* 1985; 14:350-353
5. Shaw D, Pearn J: Oleander poisoning. *Med J Aust* 1979; 2:267-269
6. Mack RB: 'To see a world in a grain of sand and a heaven in a wild flower'—Oleander poisoning. *N C Med J* 1984; 45:729-730
7. Kaojarern S, Sukhupunarak S, Mookhavesa C: Oleander Yee tho poisoning. *J Med Assoc Thai* 1986; 69:108-111
8. Mallick BK: Cardiotoxicity in yellow oleander seed poisoning. *J Indian Med Assoc* 1984; 82:296-297
9. Cheung K, Hinds JA, Duffy P: Detection of poisoning by plant-origin cardiac glycoside with the Abbott TDX analyzer. *Clin Chem* 1989; 35:295-297

10. Rubenstein E, Federman DD: Cardiovascular medicine, congestive heart failure. *In* Scientific American Medicine. New York, Scientific American Inc, 1988, pp 11-12

11. Burton LE, Picchioni AL, Chin L: Dipotassium edetate as an antidote in poisoning from oleander and its chief glycoside, oleandrin. *Arch Int Pharmacodyn* 1965; 158:202-211

12. McEvoy GK, Litvak K, Mendham NA, et al (Eds): Drug Information 88. Bethesda, MD, American Hospital Formulary Service, American Society of Hospital Pharmacists, 1988, pp 764-771

13. Kakrani AL, Rajput CS, Khandare SK, et al: Yellow oleander seed poisoning with cardiotoxicity: A case report. *Indian Heart J* 1981; 33:31-33

14. Blazer DG, Bachar JR, Mantou KG: Suicide in late life—Review and commentary. *J Am Geriatr Soc* 1986; 34:519-525

## Cardiac Rupture in Blunt Trauma Without External Signs of Chest Injury

TODD P. CHAPMAN, MD  
Reno, Nevada

**SURVIVORS OF CARDIAC RUPTURE** due to blunt trauma are rare. There are often massive associated injuries, and diagnosis may be difficult. On the other hand, patients at first may have minimal or no signs of chest injury, yet suffer from cardiac rupture. Two such patients are described.

### Reports of Cases

#### Case 1

A 23-year-old woman lost control of her car and struck a tree. At the scene of the accident, she was hypotensive (blood pressure 80/50 mm of mercury), and this gradually progressed to a blood pressure of 60 mm of mercury palpable on arrival at the emergency department. Examination showed a mandibular fracture and notable soft tissue swelling in the neck. She had no bruises or other evidence of chest or abdominal trauma. A chest radiograph showed no rib fractures or other obvious signs of injury. Following nasotracheal intubation and crystalloid infusion, her hypotension persisted. On peritoneal lavage, no abnormalities were detected. Her urine output was minimal. Her neck veins showed progressive distention, and an emergency echocardiogram showed pericardial tamponade. A pericardiocentesis was done before a surgical procedure. Removing 100 ml of nonclotted blood from the pericardial sac improved the patient's systolic blood pressure to 80 mm of mercury. In the operating room, a median sternotomy was done, and a tense, blue, bulging pericardium was noted. This was incised, with immediate evacuation of blood, and the systolic blood pressure rose to 140 mm of mercury. A perforation of the right atrial appendage was found and controlled using a fingertip. This tear was then easily oversewn. No other associated injuries were identified. The patient had an uneventful convalescence and was dismissed on the sixth postoperative day to be admitted later for definitive oral surgery for the mandibular fracture.

#### Case 2

The patient, a 50-year-old woman, was involved in a single-vehicle car accident in which she was pinned under the

(Chapman TP: Cardiac rupture in blunt trauma without external signs of chest injury. *West J Med* 1989 Dec; 151:662-663)

From the Division of Thoracic and Cardiovascular Surgery, Mayo Clinic Scottsdale, Scottsdale, Arizona. Dr Chapman is currently with Reno Heart Surgeons, Reno, Nevada.

Reprint requests to Todd P. Chapman, MD, Reno Heart Surgeons, 75 Pringle Way, Reno, NV 89502.