

Clinical Medicine

Blastocystis hominis—A Potential Intestinal Pathogen

RICHARD R. BABB, MD, and SHIRLEY WAGENER, Palo Alto, California

The parasite Blastocystis hominis has been found in 10% to 18% of stool specimens submitted to microbiology laboratories. Controversy exists as to whether this organism can cause illness in humans. We have reviewed the records of 65 symptomatic patients with B hominis in their stool. We conclude that B hominis is a potential pathogen that may or may not require drug therapy depending on the overall clinical circumstances, the severity of symptoms, and the presence of other pathogenic organisms.

(Babb RR, Wagener S: *Blastocystis hominis*—A potential intestinal pathogen. West J Med 1989 Nov; 151:518-519)

As noted by Zierdt, the history of *Blastocystis hominis* "is one of beguiling contradiction."¹ After being named in 1912, this organism was considered a harmless yeast until being reclassified in 1976 as a protozoan on the basis of structural and physiologic characteristics.¹ Whether *B hominis* can cause disease in humans remains controversial. Most authors think it is potentially pathogenic when present in large numbers in the intestine and when other infectious organisms are absent.¹⁻⁹ Others suggest that *B hominis* is not the cause of clinical illness but rather a harmless parasite in patients with gastrointestinal symptoms from other causes.¹⁰

Because *B hominis* can be found in 10% to 18% of stool specimens submitted to microbiology laboratories,^{1,2,8} correlating its presence with patients' symptoms is important. We have therefore reviewed our experience at the Palo Alto Medical Clinic in an attempt to decide whether *B hominis* is pathogenic.

Methods

Over a 12-month period (August 1987 to August 1988) 2,700 patients submitted stool specimens for ova and parasite examination to the Palo Alto Medical Clinic microbiology laboratory. These unpurged specimens had been collected either at home or in a clinic office and were preserved in polyvinyl alcohol. They were subsequently centrifuged; the sediment was placed onto a slide, dried at room temperature overnight, and then stained with trichrome. All slides were examined under a microscope by licensed microbiology technologists. (The number of organisms present per microscopic field was not reported.) A total of 76 adult patients (3%) had slides positive for *B hominis* (Figure 1). The medical records of these 76 patients were then analyzed for clinical patterns associated with a stool specimen positive for *B hominis*.

Results

Of the 76 patients with a stool specimen positive for *B hominis*, the medical records of 11 did not contain relevant clinical information; thus, 65 records were available for review.

In all, 41 patients submitted at least three stool specimens. *B hominis* was found in all three specimens in 9 patients, in two of three specimens in 10 patients, and in only one in 20 patients. In one patient, the parasite was seen in four of six specimens, and in another, in one of five specimens. As shown in Table 1, other pathogenic parasites such as *Giardia lamblia*, *Entamoeba histolytica*, and *Dientamoeba fragilis* were seen in 19 patients, or about a third. Only two patients had cultures of stool specimens for pathogenic bacteria, and both were negative. Viral studies and stool smears for leukocytes were not done.

The records were scanty concerning possible predisposing factors for *B hominis* infection. A majority of patients (43) had traveled outside the United States, usually to Mexico, Africa, or Southeast Asia, within a few months of becoming ill. No one was identified as chronically ill or immunocompromised. One patient was noted as homosexual. Everyone was symptomatic, and most complained of diarrhea and abdominal pain. There was no mention of fever, chills, anorexia, nausea, or blood in the stool. None of our patients were evaluated with sigmoidoscopy or colonoscopy.

In all, 33 patients, including 4 with other parasites, were not treated. Subsequent clinic visits or phone calls indicated that 27 were well. The status of the other six could not be judged from available records. A total of 32 patients, including 16 with other parasites, were treated with metronidazole (Flagyl), and 28 became asymptomatic. Two patients felt no better when seen 12 months later. Two could not be traced. On the whole, those treated appeared more ill. One patient complained bitterly of long-standing diarrhea and rapidly responded to drug therapy. The follow-up was less than three months in most patients, and only seven had repeat stool examination for ova and parasites. Six patients (including three with other parasites) had been treated, and all six were negative for *B hominis*.

Discussion

Based on clinical experience in large medical centers and on isolated cases,¹⁻⁹ most authors think that *B hominis* can be pathogenic. Zierdt¹ and later Sheehan and co-workers² re-

From the Departments of Internal Medicine (Gastroenterology) (Dr Babb), and Microbiology (Ms Wagener), Health Care Division, Palo Alto Medical Clinic, Palo Alto, California.

Reprint requests to Richard R. Babb, MD, Department of Internal Medicine (Gastroenterology), Palo Alto Medical Clinic, 300 Homer Ave, Palo Alto, CA 94301-2794.

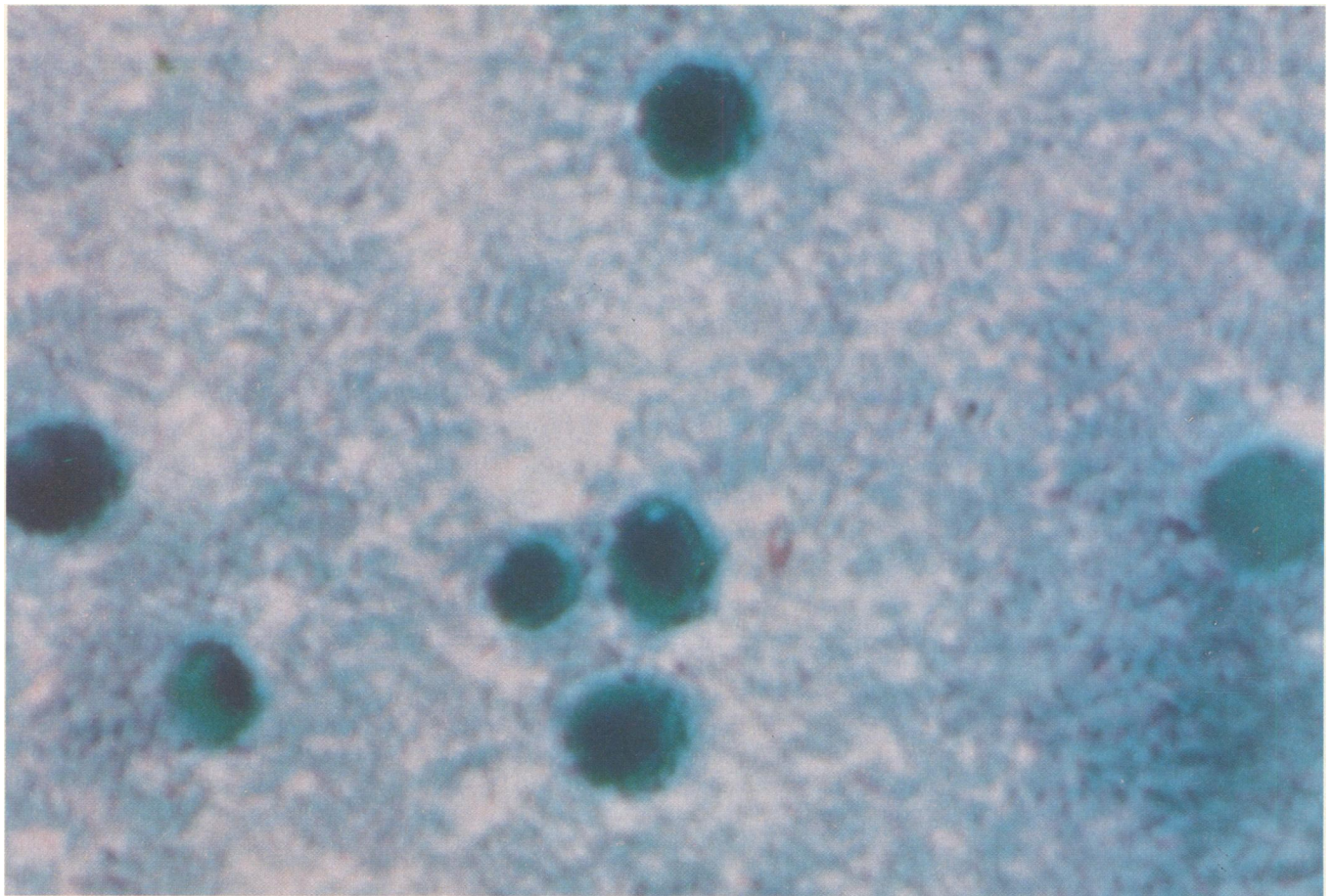


Figure 1.—The fecal smear shows *Blastocystis hominis* (trichrome stain × 1,000).

TABLE 1.—Intestinal Parasites in Association With <i>Blastocystis hominis</i>	
Parasites	No. of Patients
<i>Giardia lamblia</i>	9
<i>Dientamoeba fragilis</i>	6
<i>Entamoeba histolytica</i>	4

port that large numbers of this parasite (greater than five per 40 × phase objective or oil-immersion microscopic field) in the intestinal tract often lead to abdominal complaints that respond to treatment. In two abstracts, one reviewing 15 patients and the other 32, it was concluded that *B hominis* could cause gastrointestinal illness.^{8,9} Five recent case reports have described a total of six patients acutely ill with diarrhea.³⁻⁷ All had *B hominis* only in their stool specimens, and each patient eventually responded to treatment with metronidazole or, in one case, with ketoconazole (Nizoral).⁶

In contrast, Markell and Udkow¹⁰ have suggested that *B hominis* does not cause illness. They reviewed the clinical course of 148 patients with *B hominis* in their stool. A total of 116 had four or fewer stool examinations and were not studied further. Of the 148 patients, 32 had six stool examinations, all containing *B hominis*; in 27 patients, there were other pathogenic parasites as well. Appropriate drug therapy was given for the other parasites, and although these patients became asymptomatic, their stools continued to contain *B hominis*. Markell and Udkow think that successful treatment of a patient with *B hominis* represents the elimination of

another perhaps undetected parasite or the alleviation of functional bowel symptoms with time alone.

On the basis of our experience and the literature reviewed above, we think *B hominis* is a potential pathogen that can in some patients lead to diarrhea and abdominal pain. A patient's overall health and the number of parasites in the gastrointestinal tract determine whether symptoms develop. Often, *B hominis* is an innocent bystander and not responsible for the patient's symptoms. Almost half of our study group became asymptomatic without treatment.

Prudent physicians will review the entire clinical findings before advising specific drug therapy for symptomatic patients with *B hominis* in their stool.

REFERENCES

1. Zierdt CH: *Blastocystis hominis*, a protozoan parasite and intestinal pathogen of human beings. Clin Microbiol Newslett 1985; 5:56-59
2. Sheehan DJ, Raucher BG, McKittrick JC: Association of *Blastocystis hominis* with signs and symptoms of human disease. J Clin Microbiol 1986; 24:548-550
3. Ricci N, Toma P, Furlani M, et al: *Blastocystis hominis*: A neglected cause of diarrhea? (Letter). Lancet 1984; 1:966
4. Vannatta JB, Adamson D, Mullican K: *Blastocystis hominis* infection presenting as recurrent diarrhea. Ann Intern Med 1985; 102:495-496
5. LeBar WD, Larsen EC, Patel K: Afebrile diarrhea and *Blastocystis hominis* (Letter). Ann Intern Med 1985; 103:306
6. Cohen AN: Ketoconazole and resistant *Blastocystis hominis* infection (Letter). Ann Intern Med 1985; 103:480-481
7. Russo AR, Stone SL, Taplin ME, et al: Presumptive evidence for *Blastocystis hominis* as a cause of colitis. Arch Intern Med 1988; 148:1064
8. Ho H, Zuckerman MJ, Scoles B, et al: Clinic features of *Blastocystis hominis* infection. Gastroenterology 1987; 92:1437
9. Weg AL, Soave R, Jacobsen IM: The significance of intestinal *Blastocystis hominis* infection. Gastroenterology 1987; 92:1688
10. Markell EK, Udkow MP: *Blastocystis hominis*: Pathogen or fellow traveler? Am J Trop Med Hyg 1986; 35:1023-1026