

# Usefulness of somatostatin receptor scintigraphy in the management of patients with Zollinger-Ellison syndrome

G Cadiot, G Bonnaud, R Lebtahi, L Sarda, P Ruzsniowski, D Le Guludec, M Mignon, Groupe de Recherche et d'Etude du Syndrome de Zollinger-Ellison (GRESZE)

## Abstract

**Background**—Management of patients with Zollinger-Ellison syndrome (ZES) depends on the presence of multiple endocrine neoplasia type 1 (MEN 1) or liver metastases, or both. Somatostatin receptor scintigraphy (SRS) detects previously unknown endocrine tumours.

**Aim and methods**—To evaluate SRS findings susceptible to modifying the management of patients with ZES – that is, relevant findings, and the specificity of these findings. The latter were defined according to our current therapeutic strategy in three subgroups of patients (sporadic, MEN 1, and liver metastases).

**Patients**—85 consecutive patients without known extra-abdominal metastases were studied between September 1991 and March 1996.

**Results**—Relevant findings were found in 41% of 49 patients with sporadic disease but without liver metastases, in 22% of 18 patients with MEN 1 but without liver metastases, and in 17% of 18 patients with liver metastases. Follow up was available for 20 (74%) of 27 patients who had 23 relevant findings. Nineteen relevant findings (83%) were confirmed at a median of three (range 0.25–45) months of follow up; four (17%) were not confirmed at 30 (range 12–52) months ( $p=0.025$ ). Findings located in the duodenopancreatic area (90%), chest (100%), bone (100%), and liver (60%) were confirmed. Most findings for patients with MEN 1 involved the chest.

**Conclusion**—SRS detects many anomalies susceptible to modifying management of patients with ZES, especially in those with sporadic disease. The specificity of hot spots located outside the liver seems very high. By contrast, the specificity of hot spots located in the liver remains to be evaluated when conventional imaging is negative.

(Gut 1997; 41: 107–114)

**Keywords:** Zollinger-Ellison syndrome; multiple endocrine neoplasia type 1; liver metastases; somatostatin receptor scintigraphy; patient management

Among endocrine duodenopancreatic tumours, Zollinger-Ellison syndrome (ZES) has peculiarities that influence treatment mo-

dalities: the high incidence of liver metastases that occur in about 25% of patients<sup>1,2</sup>; the existence of multiple endocrine neoplasia type 1 (MEN 1) in 18–26% of patients<sup>1,3,4</sup>; and the presence of tumours commonly localised in the duodenal wall.<sup>1,5–9</sup> The primary gastrinoma in patients with ZES but without MEN is often solitary. Local lymph node involvement seems to have no adverse prognostic significance.<sup>1,2</sup> Surgery in about 30% of patients with sporadic ZES leads to long term cure and is considered mandatory when liver metastases are not present or are resectable.<sup>7</sup> By contrast, gastrinomas in patients with MEN 1 are often multiple and associated with other endocrine tumours diffusely located in the duodenum and pancreas.<sup>3,4,9–14</sup> Surgical treatment is rarely curative in these patients and, in our experience, does not seem to prevent liver metastases.<sup>3,4,14</sup> Therefore, many authorities think that surgery should be performed in only selected patients with ZES and MEN 1.<sup>10,14–16</sup> Furthermore, other MEN 1 related endocrinopathies may need specific surgical treatment. Cytoreductive surgery might be advisable when liver metastases are localised and resectable.<sup>17</sup> Treatment modalities vary in patients with diffuse liver metastases according to the existence of extra-abdominal metastases, mainly bone metastases which may be present in up to 23% of these patients.<sup>18</sup> Therefore, apart from the diagnosis of MEN 1, which currently relies on family history, and the biological and radiological diagnoses of other endocrinopathies,<sup>19</sup> the precise detection and localisation of all tumours is of the utmost importance.

Somatostatin receptor scintigraphy (SRS) dramatically improves the detection of primary and metastatic gastrinomas, as compared with that of conventional imaging techniques.<sup>5,20–25</sup> Other studies have suggested that SRS and endoscopic ultrasonography (EUS) are complementary first line imaging techniques for the localisation of tumours in patients with ZES.<sup>5,24</sup> In a recent study from the National Institutes of Health (NIH), the sensitivity of SRS was estimated to be 92% for liver metastases of gastrinomas and 58% for primary tumours.<sup>21</sup> In a prospective surgical study, we recently showed that the sensitivity of SRS for the detection of duodenal and lymph node gastrinomas was 58%, similar to that of EUS.<sup>5</sup> In that study, however, the detection rate for duodenal and lymph node gastrinomas increased to 90% when SRS and EUS were

Presented in part at the AGA meeting in San Francisco, USA, 1996, and published in abstract form as *Gastroenterology* 1996; 110: 380.

CHU Bichat-Claude-Bernard, 46, rue Henri-Huchard, F-75877 Paris Cedex 18, France:

Service d'Hépatogastro-entérologie  
G Cadiot  
G Bonnaud  
M Mignon  
GRESZE

Service de Médecine Nucléaire  
R Lebtahi  
L Sarda  
D Le Guludec

Service de Gastroentérologie, Hôpital Beaujon, 100, boulevard du Général-Leclerc, F-92118 Clichy Cedex, France  
P Ruzsniowski

Correspondence to: Dr G Cadiot.

Accepted for publication 20 February 1997

performed.<sup>5</sup> Finally, the sensitivity of SRS for the detection of pancreatic gastrinomas is probably close to 100%.<sup>24</sup>

Data from several series of patients with different endocrine tumours have suggested that SRS findings can impact on patient management and may facilitate therapeutic decisions.<sup>26-29</sup> Considering the peculiarities of the management of patients with ZES, we undertook an evaluation of the influence of SRS images on the therapeutic approach to these patients, whose management differs considerably according to their classification into three groups – that is, patients with sporadic disease but without liver metastases; patients with ZES-MEN 1 but without liver metastases; and patients with liver metastases but without extra-abdominal metastases. SRS findings that might lead to modification of our strategies were defined and evaluated within each group according to standardised management in our institution. Histological or radiological confirmation of the tumoral nature of these SRS findings was evaluated at follow up.

## Methods

### PATIENTS

SRS was performed in consecutive patients with ZES, including those who had previously undergone surgery but were not cured – that is, in whom a secretin test remained positive, between September 1991 and March 1996. Patients with extra-abdominal metastases before SRS were excluded.

ZES was diagnosed on the basis of clinical history and established by either our specific biological criteria or anatomical confirmation of endocrine tumours, as previously reported.<sup>2-30</sup>

MEN 1 was diagnosed as previously described when another MEN 1 related endocrinopathy was present, mainly primary hyperparathyroidism, pituitary adenoma, insulinoma, or adrenal gland involvement, or when relatives had ZES or another MEN 1 related endocrinopathy.<sup>19</sup>

Liver metastases were suspected on the basis of conventional imaging – that is, ultrasonography (US), computed tomography (CT) or magnetic resonance imaging (MRI). Liver biopsy (percutaneous or surgical) was performed when possible. Liver metastases were diagnosed on the basis of histological criteria. When biopsy was not possible and when the liver nodules were not visualised by previous liver imaging techniques (CT scan or MRI), liver metastases were diagnosed by conventional radiological images of liver nodules compatible with those of liver metastases of endocrine tumours during follow up.<sup>31-32</sup>

Patients were classified into three groups according to the results of conventional imaging techniques and MEN 1 screening, and before SRS: (1) sporadic ZES without liver metastases on images obtained using conventional techniques; (2) ZES associated with MEN 1 without liver metastases; and (3) liver

metastases without known extra-abdominal metastases (negative conventional bone scintigraphy and negative chest radiograph).

## METHODS

### *Conventional imaging techniques*

Tumoral spread was determined only from the results of the following conventional imaging techniques performed on all patients before SRS: chest radiograph, upper digestive tract endoscopy, abdominal US, and abdominal CT scan. EUS of the duodenopancreatic area was not performed systematically when MEN 1 or liver metastases were present, when a large tumour of the duodenopancreatic area was visible on a CT scan, when the patient had had a partial gastrectomy, or when the patient was in a poor general condition. Upper digestive tract endoscopy and EUS were not possible in patients with total gastrectomy or upper digestive tract stenosis. MRI of the liver was generally indicated when liver metastases were suggested but inconclusive on a CT scan or when liver metastases seemed to be surgically resectable (located in one part of the liver). Standard bone scintigraphy with technetium-99m-HMDP (hydroxydiphosphonate) was performed systematically when liver metastases were present.

### *Octreoscan scintigraphy*

Patients were given a low residue diet for three days before SRS and at least 1 litre polyethylene glycol 4000 six to 12 hours before and 12 hours after intravenous injection of [diethylenetriamine pentaacetic acid-D-Phe<sup>1</sup>] octreotide labelled with indium-111 (Octreoscan; Mallinckrodt Medical, Petten, The Netherlands), to minimise tracer accumulation in the bowel contents. The mean administered radioactivity of Octreoscan was 135 MBq.

Acquisitions were performed with a single headed circular large field of view rotating gammacamera (Apex Elscint System, Haifa, Israel) or a double headed camera (DST Sopa Medical Vision, Brie, France), fitted with a medium energy parallel hole collimator. The detection equipment was adjusted to both <sup>111</sup>In photo peaks (171 and 245 keV). Data from both windows were added to the acquisition frame.

Images were acquired using a 256×256 word matrix with a preset time of at least 10 minutes. Abdominal images were acquired four hours after injection in the anterior and posterior views. At 24 hours, anterior and posterior views of the head, chest and pelvis, and anterior, posterior, lateral and oblique views of the abdomen were systematically obtained. Additional lateral or oblique views of the chest or head were performed if necessary. Delayed images of the abdomen were systematically obtained in the anterior and posterior views 30–48 hours after injection. Time acquisition was increased to 15–20 minutes for negative or suggested but inconclusive images.

The minimal number of planar images of the abdomen per patient was 14. Abdominal single photon emission computed tomography (360° rotation, 64 projections, 60 seconds for each step, 64×64 word matrix) was performed systematically from December 1993. Slices were reconstructed after back projection using a Hann filter.

Scintigraphic images were analysed visually by two of us (RL and DLG) using different colour scales with adjustment of the display windows to the maximum uptake of each organ. The interpretation was discussed until agreement was achieved.

Pathological hot spots located in the usual tumoral sites of gastrinomas (duodeno-pancreatic area and liver) were exclusively considered for the determination of the global SRS positive rate, defined as the presence of at least one pathological hot spot. SRS images susceptible to modifying patient management were analysed as a function of their localisation in the lungs, mediastinum, head, pituitary area, liver, duodenopancreatic area, left hypochondrium, lower abdomen, adrenal area, and bone. The number of hot spots and their localisation within each area were recorded.

#### *Definition of SRS findings susceptible to modifying patient management*

Standardised management was established for the three groups according to the current therapeutic attitude in our department. SRS findings susceptible to modifying patient management (henceforth called 'relevant SRS findings') were defined according to the standardised management and retrospectively evaluated in each patient after appropriate assignment to one of the three groups dependent on the results of conventional imaging and screening for MEN 1. Individual clinical situations were not considered, for example, contraindication to surgery due to old age or poor general condition.

#### *Patients with sporadic ZES without liver metastases as assessed by conventional imaging techniques*

*Standard patient management* – Exploratory laparotomy is considered to be mandatory with the aim of removing the primary gastrinoma and local tumoral lymph nodes.

*Definition of relevant SRS findings* – Relevant images were those likely to modify a decision for laparotomy or help the surgeon to find all the tumours: pathological hot spots in an area considered to be non-tumoral with conventional imaging techniques or in an area not explored using conventional imaging techniques; pathological hot spots in an area for which the results of conventional imaging techniques were suggestive but inconclusive of a tumour – that is, the presence of a suspected tumour could not be substantiated; or more hot spots in the duodenopancreatic area than tumours visualised with conventional imaging techniques.

#### *Patients with ZES and MEN 1 but without liver metastases as assessed by conventional imaging techniques*

*Standard patient management* – Abdominal surgery to resect gastrinomas or other pancreatic endocrine tumours is not indicated in these patients. Chest surgery is mandatory for bronchial or thymic carcinoid tumour. Treatment of other endocrinopathies – that is, primary hyperparathyroidism, pituitary adenoma, adrenal tumours, or fundic carcinoid tumours, was not considered here.

*Definition of relevant SRS findings* – These images were those suggestive of liver or extra-abdominal metastases, or bronchial or thymic carcinoid tumours: pathological hot spots in the liver; or pathological hot spots in the chest in a site previously considered to be non-tumoral.

#### *Patients with liver metastases but without extra-abdominal metastases as assessed by conventional bone scintigraphy*

Two situations were considered in this group: non-resectable liver metastases (namely, diffuse) and resectable liver metastases (namely, localised to one liver lobe).

*Standard patient management* – The choice between general treatment (chemotherapy, alpha interferon, somatostatin analogues) and regional treatment (chemoembolisation, liver transplantation) for diffuse non-resectable liver metastases was dependent on the presence of extra-abdominal metastases.

Cytoreductive liver surgery was recommended for localised and resectable liver metastases but contraindicated when diffuse liver metastases or extra-abdominal metastases were present.

*Definition of relevant SRS findings* – These images in patients with liver metastases were extra-abdominal hot spots suggestive of extra-abdominal metastases.

Relevant SRS findings in patients with localised resectable liver metastases also included additional liver hot spots that would preclude cytoreductive liver surgery.

Information obtained during surgery or from other conventional imaging techniques was recorded after SRS. The length of follow up for those patients with relevant SRS findings, to allow verification or disproval of these results, was recorded.

#### STATISTICAL ANALYSIS

The Mann-Whitney U test was used to compare quantitative data. A p value <0.05 was considered significant.

#### Results

Between September 1991 and March 1996, SRS was performed in 88 consecutive patients with ZES including those who had not been cured by earlier surgery. Three patients with previously known extra-abdominal metastases (two with bone metastases and one with lung metastases) were excluded. Table 1 lists the

TABLE 1 Characteristics of the three groups of patients with Zollinger-Ellison syndrome (ZES)

	Sporadic ZES <sup>a</sup>	ZES and multiple endocrine neoplasia type 1 <sup>a</sup>	Liver metastases <sup>b</sup>
No of patients	49	18	18
Sex (F/M)	13/36	5/13	5/13
Age at diagnosis (mean (SD) years)	49.4 (12.0)	43.7 (11.0)	42.1 (10.8)
Histological diagnosis of ZES	30	10	17
No of patients with previous surgery <sup>c</sup>	14	8	13
Age at somatostatin receptor scintigraphy (mean (SD) years)	53.5 (12.5)	50.1 (11.0)	47.5 (12.0)

<sup>a</sup>Without liver metastases on images obtained using conventional techniques.

<sup>b</sup>Without extra-abdominal metastases on images obtained using conventional bone scintigram and chest radiograph.

<sup>c</sup>Relevant surgery – that is, tumoral indications, or partial or total gastrectomy.

TABLE 2 Somatostatin receptor scintigraphic (SRS) findings and confirmation of relevant SRS information in the three groups of patients with Zollinger-Ellison syndrome (ZES) (n=85)

	Sporadic ZES (n=49)	ZES and multiple endocrine neoplasia type 1 (n=18)	Liver metastases (n=18)
No of patients with positive SRS (%)	33 (67)	12 (67)	17 (94)
No of patients with relevant SRS findings (%) <sup>a</sup>	20 (41)	4 (22)	3 (17)
No of relevant SRS findings <sup>a</sup>	22	5	3
No of patients with available follow up <sup>b</sup>	13	4	3
No of relevant SRS findings in patients with available follow up <sup>b</sup>	15	5	3
No of confirmed relevant SRS findings in patients with available follow up (%) <sup>b</sup>	11 (73)	5 (100)	3 (100)

<sup>a</sup>Findings susceptible to modifying patient management as defined in Methods.

<sup>b</sup>Among patients with relevant SRS findings.

main characteristics of the three groups of patients. Table 2 indicates the global positive rates of SRS and the number of patients with relevant SRS findings.

#### RELEVANT SRS FINDINGS ACCORDING TO PATIENT GROUP

##### *Patients with sporadic ZES without liver metastases as assessed by conventional imaging techniques*

**Patient characteristics** – Forty nine patients were considered to have sporadic ZES without liver metastases before SRS. Fourteen patients had the following interventions before SRS: left splenopancreatectomy (n=2), left splenopancreatectomy and partial gastrectomy (n=1), partial gastrectomy (n=1), duodenal gastrinoma resection (n=1), pancreatic gastrinoma enucleation (n=1), tumoral lymph node resection (n=2), negative laparotomy (n=5), and total gastrectomy (n=1). None was cured (table 1).

The patients had undergone chest radiography, abdominal US, and CT. All patients except two (total gastrectomy in one and oesophageal stenosis in the other) underwent upper digestive tract endoscopy. EUS was performed in 42 (86%) patients. Patients who did not undergo EUS had had total gastrectomy (n=1), partial gastrectomy (n=2), big abdominal tumours (10 and 12 cm) (n=2), oesophageal stenosis (n=1), or poor general condition that precluded surgery (n=1).

**SRS results** – SRS findings were positive in 33 of the 49 patients (table 2). Twenty two relevant SRS images in 20 patients showed (tables 2 and 3): (1) at least one pathological hot spot in an area considered to be non-tumoral or not explored by conventional imaging techniques (16 findings in 14 patients); (2) a pathological hot spot corres-

ponding to a suggestive but inconclusive lesion as assessed by conventional imaging techniques (n=2); and (3) more hot spots in the duodenopancreatic area than tumours visualised with conventional imaging techniques (n=4).

##### *Patients with ZES and MEN 1 without liver metastases as assessed by conventional imaging techniques*

**Patient characteristics** – Eighteen patients were assigned to this group before SRS. Eight patients had surgery before SRS: left splenopancreatectomy (n=4), left splenopancreatectomy and partial gastrectomy (n=1), partial gastrectomy (n=2), and pneumonectomy for bronchial carcinoid (n=1) (table 1). None was cured.

The patients had undergone chest radiography, upper digestive tract endoscopy, and abdominal US and CT. Fourteen (78%) patients had EUS.

**SRS results** – SRS findings were positive in 12 of the 18 patients (table 2). Five relevant SRS images were seen in four of them: pathological hot spots in the liver and mediastinum (n=1), the mediastinum (n=1), and the lungs (n=2).

##### *Patients with liver metastases but without extra-abdominal metastases*

**Patient characteristics** – Eighteen patients were diagnosed as having liver metastases without extra-abdominal metastases before SRS (table 1). Thirteen patients had surgery before SRS: total pancreatectomy (n=1), left splenopancreatectomy (n=5), tumoral lymph node resection (n=1), duodenal gastrinoma resection (n=1), laparotomy with biopsy (n=4), and total gastrectomy (n=1).

The patients had had abdominal CT; one did not undergo abdominal US. Three (17%)

TABLE 3 Relevant somatostatin receptor scintigraphic findings in the 49 patients with sporadic Zollinger-Ellison syndrome (ZES)

Type	Localisation	No
Hot spot in an area considered non-tumoral	Duodenopancreatic area	10
	Liver	3
	Mediastinum	1
	Pituitary area	1
	Adrenals	1
Hot spot corresponding to a suggestive but inconclusive lesion on conventional images	Pancreatic head (computed tomography)	1
	Pancreatic corpus (endoscopic ultrasound)	1
More hot spots than the number of tumours on conventional images	Duodenopancreatic area	4

patients had theoretically resectable – that is, localised to one liver lobe, liver metastases as assessed by conventional imaging techniques (CT and MRI in one and CT only in two).

**SRS results** – SRS findings were positive in 17 of the 18 patients (table 2). Relevant SRS images were seen in three patients: nine hot spots were located in both lobes of the liver in one patient with liver metastases, which were initially deemed to be resectable based on conventional imaging techniques (US and CT), and bone hot spots in two patients with diffuse liver metastases. Liver US, CT, and MRI were negative in one patient who had been treated for diffuse liver metastases 10 years earlier, but SRS images showed diffuse liver hot spots. This observation was not considered to be relevant because diffuse liver metastases had previously been known. Although SRS detected breast cancer in another patient, this pathological accumulation of the tracer in the left breast was not considered to be relevant for the purpose of the study.

#### CONFIRMATION OF RELEVANT SRS FINDINGS

Follow up in 20 (74%) of the 27 patients with relevant SRS findings was sufficiently long to evaluate the tumoral nature of these images. There was no follow up in the remaining seven patients. Of the 20 patients who were followed, radiological or histological confirmation of the tumoral nature of 19 (83%) of the 23 relevant SRS findings was obtained after a median of three (range 0.25–45) months of follow up (table 4). By contrast, the tumoral nature of four relevant SRS findings had not been confirmed after a median of 30 (range 12–52) months of follow up ( $p=0.025$ ).

#### Confirmation according to the patient group

**Patients with sporadic ZES** – Follow up was available for 13 (65%) patients with 15 relevant

SRS findings (table 2) and was not available for seven patients with seven relevant SRS images, among which six were located in the duodenopancreatic area and the seventh in the pituitary area.

Two patients each had one confirmed and one unconfirmed relevant SRS finding during follow up. Eleven of the 15 relevant images in the 13 patients available for follow up were confirmed by surgery ( $n=8$ ) or conventional imaging ( $n=2$ ): tumours in the duodenopancreatic area ( $n=9$ ), liver ( $n=1$ ), and mediastinum ( $n=1$ ). Despite available follow up four relevant SRS findings in four patients were not confirmed: hot spots in the liver ( $n=2$ ), the duodenopancreatic area ( $n=1$ ) and the adrenals ( $n=1$ ).

**Patients with MEN 1** – Follow up was available for the four patients (100%) whose SRS showed five relevant SRS images. All were confirmed by conventional imaging (chest CT for four and liver MRI for the other) and further confirmed histologically by chest surgery in one patient and liver biopsy in another.

**Patients with liver metastases** – Follow up was available in the three patients with relevant SRS findings. Additional liver metastases were confirmed by CT in one and bone metastases by MRI in two, with one being further definitively confirmed at necropsy (bone metastases).

#### Confirmation according to localisation

As reported in table 4, only one SRS image (10%) of the duodenopancreatic area, corresponding to one hot spot in a patient who had previously undergone total gastrectomy and in whom EUS was not feasible, remained unconfirmed; abdominal CT was negative at 36 months. Adrenal CT remained normal in the patient with adrenal hot spots 12 months after follow up. Despite respective follow ups of 24 and 52 months the relevant SRS findings concerning the liver were not confirmed for patients 5 and 4 (40%) (table 5). Figures 1 and 2 show the liver hot spot in these two patients. Table 5 details follow up of the five patients with liver involvement.

#### Discussion

To the best of our knowledge, this is the first study that has specifically evaluated how and how often SRS findings can modify the management of patients with ZES – that is,

TABLE 4 Confirmation or not of the tumoral nature of the 23 relevant SRS findings according to their localisation in the 20 patients with available follow up

Localisation	Relevant SRS findings (n)	Confirmed relevant SRS findings		Non-confirmed relevant SRS findings	
		n (%)	Length of follow up* (months)	n (%)	Length of follow up* (months)
Duodenopancreatic area	10	9 (90)	4 (0.25–36) <sup>b</sup>	1 (10)	36
Liver	5	3 (60)	12 (3–45) <sup>b</sup>	2 (40)	24 and 52
Bone	2	2 (100)	0.25 and 0.50	0 (0)	—
Chest	5	5 (100)	3 (2–24) <sup>b</sup>	0 (0)	—
Adrenals	1	0 (0)	—	1 (100)	12

\*Leading to confirmation or non-confirmation of relevant SRS findings.

<sup>b</sup>Median (range).

TABLE 5 Relevant somatostatin receptor scintigraphic (SRS) findings concerning the liver in five patients with available follow up

Patient no	Group	Conventional liver imaging before SRS	Relevant hepatic SRS findings	Follow up	Confirmation during follow up
1	Multiple endocrine neoplasia type 1	Negative ultrasound (US), computed tomography (CT), and magnetic resonance imaging (MRI)	Hot spots in the left lobe	At 12 months: second SRS showed hot spots in both lobes; positive liver MRI At 48 months: positive liver biopsy	+
2	Liver metastases	Four localised liver metastases on CT (MRI not done)	Nine hot spots in both lobes	At three months: CT showed eight liver metastases in both lobes	+
3	Sporadic	Negative US and CT (MRI not done)	One hot spot in the left lobe	At 16 months: negative US, CT, and MRI; second SRS showed the same hot spot At 45 months: US and CT showed a liver nodule At 48 months: third SRS showed the same hot spot	+
4	Sporadic	Negative US, CT, and MRI	One large diffuse poorly delineated hot spot in the right lobe <sup>a</sup>	At 36 months: second SRS (including single photon emission computed tomography (SPECT)) showed the same hot spot; surgery (including US): normal liver, resection of one duodenal gastrinoma and one tumoral lymph node At 39 months: third SRS showed the same hot spot; negative secretin test At 52 months: normal liver with US and MRI	-
5	Sporadic	Negative US and CT (MRI not done)	One hot spot in the left lobe	At one month: negative MRI At five months: surgery (including US): normal liver, resection of one tumoral lymph node; positive postoperative secretin test At 24 months: second SRS (including SPECT): same liver hot spot and new hot spot in the duodenopancreatic area <sup>b</sup> ; negative CT; endoscopic ultrasound (US): pancreatic head tumour	-

Findings concerning tumours located in other sites are not given in the table (except relevant findings detected during follow up).

<sup>a</sup>Illustrated in fig 1. <sup>b</sup>Illustrated in fig 2.

clinical impact. Furthermore, considering the high number of patients with available follow up, this study has also attempted to determine the specificity of these relevant SRS findings. According to our criteria, the percentage of relevant SRS findings was very high in patients with sporadic ZES without liver metastases (41% of patients) and lower in those with ZES and MEN 1 (22%) and in those with liver metastases (17%).

Definitions of the relevant SRS findings within each group are open to discussion, because they depended on the current therapeutic approach applied in our department. Management of patients with ZES, especially when MEN 1 is present, is controversial.<sup>1 2 8-10 14-16</sup> We decided that exploratory laparotomy was not indicated for the purpose of this study and to simplify presentation of the data in the group of patients with MEN 1. This is our current recommen-

dation, except in rare situations such as insulinoma or other life threatening conditions.<sup>14</sup> This distinction partially explains the difference in SRS results between patients with sporadic ZES and those with MEN 1.

The high rate of relevant findings (41%) in patients with sporadic ZES was mainly the result of SRS images in the duodenopancreatic area, which represented 16 of the 22 relevant SRS findings (table 3). This clearly confirms our previous observation that, although EUS was performed when technically possible, SRS greatly enhances the detection rate of primary and lymph node gastrinomas.<sup>5</sup> Whether these SRS findings will lead to a better surgical cure rate, however, remains to be evaluated. Recent preliminary data from the NIH showed that short term cure of patients with sporadic ZES studied with SRS before surgery was very similar to that of their patients operated on before the availability of this technique.<sup>33</sup> A comparable cure rate was obtained in our series

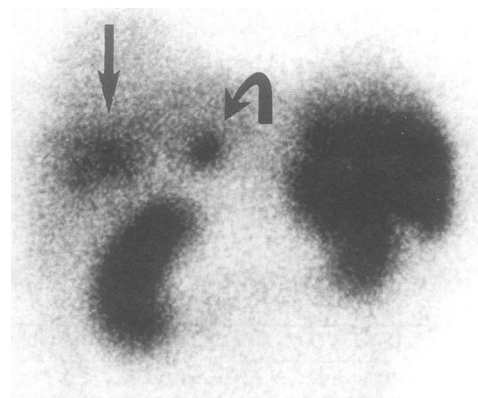


Figure 1: First SRS in patient 4 (table 5) showing a large, diffuse, and poorly delineated hot spot in the right liver lobe (arrow) and a smaller well delineated hot spot in the duodenopancreatic area (curved arrow). The smaller hot spot disappeared after surgical resection of a duodenal gastrinoma and tumoral lymph node. The liver remained normal with US and MRI after 52 months of follow up.

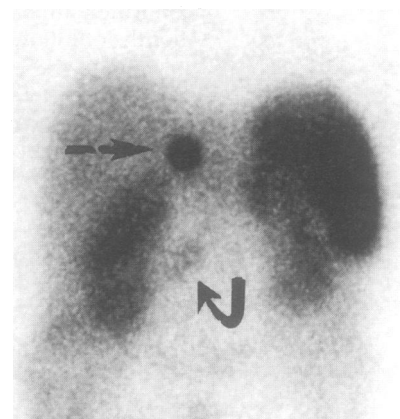


Figure 2: Second SRS in patient 5 (table 5) showing a well delineated hot spot in the left liver lobe (CT normal) (arrow) and another hot spot in the duodenopancreatic area (curved arrow) probably corresponding to a pancreatic head tumour.

of patients with sporadic ZES studied with SRS before surgery.<sup>5</sup> SRS showing several hot spots in the duodenopancreatic area may help the surgeon to discover as many tumours as the number of hot spots.<sup>5</sup> This achievement, however, does not seem to be sufficient to improve cure rates. It should not be concluded that SRS should not be performed before surgery, because data from the NIH<sup>33</sup> and our group<sup>5</sup> were obtained in patients who were selected on the basis of SRS results – that is, surgery was indicated when SRS did not detect unresectable extra-abdominal or liver tumour(s). The impact of SRS results on the usefulness of somatostatin analogue treatment was not examined in the present study, because these drugs are not commonly used in patients with ZES.<sup>34</sup>

An attempt was made to evaluate the specificity of relevant SRS findings in 74% of patients with such images in whom follow up was available. Absence of follow up in seven patients did not significantly modify the results for the following reasons: (1) six of the seven SRS findings were located in the duodenopancreatic area. Indeed, the specificity of SRS hot spots in the duodenopancreatic area seems to be very high, because nine (90%) of the 10 relevant SRS findings located in this area were subsequently confirmed in followed patients; (2) all patients with SRS findings located in the liver, chest, and bone were followed. In contrast to SRS sensitivity, which has now been thoroughly studied in ZES, the specificity of new SRS hot spots has not been clearly established.<sup>5 20–25</sup> Our study showed that, in the patients with available follow up, 19 (83%) of the 23 SRS relevant findings were subsequently confirmed. The median period of time elapsed until confirmation of these 19 SRS findings was short (three (range 0.25–45) months) and of shorter duration than the follow up period of patients with the four unconfirmed findings (30 (range 12–52) months) ( $p=0.025$ ). Ninety per cent of SRS findings involving the duodenopancreatic area and 100% of those affecting the bone and chest were subsequently confirmed (table 4), clearly showing that SRS is highly specific in these areas. In most patients with bone and chest tumours, the time lapse until confirmation was the delay in performing bone MRI or chest CT. The high percentage of chest tumours in patients with MEN 1 (22%) suggests that chest CT should be performed systematically. Whether SRS remains indicated in these patients if chest CT is performed systematically should be further investigated. However, chest CT after SRS has shown a pathological hot spot may be more efficient than systematic chest CT. Furthermore, SRS findings are not limited to chest tumours; SRS detected liver metastases in one (no 1 in table 5).

Relevant SRS findings concerning the liver were not confirmed in two (40%) patients despite surgery with preoperative US and long term follow up (24 and 52 months, respectively, in patients 5 and 4) (tables 4 and 5) (figs 1 and 2). In light of the very high sensitivity of SRS for detecting liver metastases of

gastrinomas (92%)<sup>21</sup> and its high specificity (100%)<sup>35</sup> in the NIH series, it is not possible to affirm that the liver hot spot of patient 5 is false positive (table 5) (fig 2). The high sensitivity is well illustrated by the patient with diffuse, histologically proven liver metastases treated 10 years earlier in whom liver US, CT, and MRI were negative and SRS was positive, and patients 1 and 3 (table 5) in whom liver imaging was positive only 12 and 45 months, respectively, after SRS. Nevertheless, for patient 4 (table 5) (fig 1), the liver hot spot should be considered false positive, because the secretin test became negative after surgical resection of a duodenal and a lymph node gastrinoma. This liver hot spot was large, diffuse, and poorly delineated. This is not the usual feature of hot spots corresponding to endocrine liver metastases, in contrast to the liver hot spot shown in fig 2.

One limitation of our study is that relevant SRS findings were defined retrospectively and theoretically within the three groups and did not take into consideration each patient's condition. Because of the heterogeneity of our patient population, adaptation of the definition of relevant SRS findings to the individual would have been very confusing. Nevertheless, this lack of adaptation mainly concerned patients in poor general condition in whom surgery is not recommended and those with MEN 1 and insulinoma in whom surgery is mandatory. This application of theoretically defined findings is not considered to have had a significant impact on the results. By contrast, it probably had an impact on follow up, because rigorous monitoring was not forced on patients in poor condition.

In conclusion, in this large series of patients with ZES, SRS visualises findings susceptible to modifying patient management, especially in those with sporadic disease for whom surgery is planned. The results also indicate that chest CT should be mandatory in patients with ZES and MEN 1. Prospective long term studies are needed to evaluate better the specificity of SRS for liver hot spots when other imaging methods (including MRI) are negative and to assess the impact of SRS derived information on curability and survival.

The authors thank the following doctors for referring their patients: P Baumer, R Bénomouzig, J F Bergmann, O Bouché, C Buffet, D Cattan, S Chaussade, M Cotinat, A Courillon-Mallet, E Danquechin-Dorval, J C Delchier, J P Etienne, C Florent, J P Gendre, D Goldfain, H Hagege, J Hostein, V Kerlan, P Mamou, C Matuchansky, R Modigliani, P Oberlin, J C Soulé, G Thiéfin, F Venezia, P Zeitoun, and B Ziélnski.

- 1 Weber HC, Venzon DJ, Lin J-T, Fishbein VA, Orbach M, Strader DB, *et al*. Determinants of metastatic rate and survival in patients with Zollinger-Ellison syndrome: a prospective long-term study. *Gastroenterology* 1995; **108**: 1637–49.
- 2 Mignon M, Bonfils S. Diagnosis and treatment of Zollinger-Ellison syndrome. In: Piper DW, ed. *Peptic ulceration. Baillères Clin Gastroenterol* 1988; **2**: 677–98.
- 3 Mignon M, Ruzsniowski P, Podevin P, Sabbagh L, Cadiot G, Rigaud D, *et al*. Current approach to the management of gastrinoma and insulinoma in adult patients with multiple endocrine neoplasia type 1 (MEN 1). *World J Surg* 1993; **17**: 489–97.
- 4 Ruzsniowski P, Podevin P, Cadiot G, Marmuse JP, Mignon M, Vissuzaine C, *et al*. Clinical, anatomical, and evolutive features of patients with the Zollinger-Ellison syndrome combined with type 1 multiple endocrine neoplasia. *Pancreas* 1993; **8**: 295–304.

- 5 Cadiot G, Lebtahi R, Sarda L, Bonnaud G, Marmuse JP, Vissuzaine C, *et al.* Preoperative detection of duodenal gastrinomas and peripancreatic lymph nodes by somatostatin receptor scintigraphy. *Gastroenterology* 1996; 111: 845-54.
- 6 Sugg SL, Norton JA, Fraker DL, Metz DC, Pisegna JR, Fishbeyn V, *et al.* A prospective study of intraoperative methods to diagnose and resect duodenal gastrinomas. *Ann Surg* 1993; 218: 138-44.
- 7 Norton JA, Doppman JL, Jensen RT. Curative resection in Zollinger-Ellison syndrome. Results of a 10-year prospective study. *Ann Surg* 1992; 215: 8-18.
- 8 Ellison EC. Forty year appraisal of gastrinoma. Back to the future. *Ann Surg* 1995; 222: 511-24.
- 9 Thompson NW. The surgical management of hyperparathyroidism and endocrine disease of the pancreas in the multiple endocrine neoplasia type 1 patient. *J Intern Med* 1995; 238: 269-80.
- 10 MacFarlane MP, Fraker DL, Alexander HR, Norton JA, Lubensky I, Jensen RT. Prospective study of surgical resection of duodenal and pancreatic gastrinomas in multiple endocrine neoplasia type 1. *Surgery* 1995; 118: 973-80.
- 11 Donow C, Pipeleers-Marichal M, Schröder S, Stamm B, Heitz PU, Klöppel G. Surgical pathology of gastrinoma. Site, size, multicentricity, association with multiple endocrine neoplasia type 1 and malignancy. *Cancer* 1991; 68: 1329-34.
- 12 Norton JA, Jensen RT. Unresolved surgical issues in the management of patients with Zollinger-Ellison syndrome. *World J Surg* 1991; 15: 151-9.
- 13 Klöppel G, Schröder S, Heitz PU. Histopathology and immunopathology of pancreatic endocrine tumors. In: Mignon M, Jensen RT, eds. Endocrine tumors of the pancreas: recent advances in research and management. Basel: Karger. *Front Gastrointest Res* 1995; 23: 99-120.
- 14 Mignon M, Cadiot G, Rigaud D, Ruzsniwski P, Jais P, Lehy T, *et al.* The management of islet cell tumors in patients with multiple endocrine neoplasia type 1 (MEN 1). In: Mignon M, Jensen RT, eds. Endocrine tumors of the pancreas: recent advances in research and management. Basel: Karger. *Front Gastrointest Res* 1995; 23: 342-59.
- 15 Hirschowitz BI. Clinical course of nonsurgically treated Zollinger-Ellison syndrome. In: Mignon M, Jensen RT, eds. Endocrine tumors of the pancreas: recent advances in research and management. Basel: Karger. *Front Gastrointest Res* 1995; 23: 360-71.
- 16 Melvin WS, Johnson JA, Sparks J, Innes JT, Ellison EC. Long-term prognosis of Zollinger-Ellison syndrome in multiple endocrine neoplasia. *Surgery* 1993; 114: 1183-8.
- 17 Nagorney DM, Que FG. Cytoreductive hepatic surgery for metastatic gastrointestinal neuroendocrine tumors. In: Mignon M, Jensen RT, eds. Endocrine tumors of the pancreas: recent advances in research and management. Basel: Karger. *Front Gastrointest Res* 1995; 23: 416-30.
- 18 Gibril F, Termanini B, Stewart CA, Sutliff VE, Jensen RT. Prospective study of the occurrence of metastases to bone in patients with Zollinger-Ellison syndrome (ZES) [abstract]. *Gastroenterology* 1996; 110: 1073.
- 19 Cadiot G, Houillier P, Allouch A, Paillard M, Mignon M, GRESZE. Oral calcium tolerance test in the early diagnosis of primary hyperparathyroidism and multiple endocrine neoplasia type 1 in patients with the Zollinger-Ellison syndrome. *Gut* 1996; 39: 273-8.
- 20 De Kerviler E, Cadiot G, Lebtahi R, Faraggi M, Le Guludec D, Mignon M, *et al.* Somatostatin receptor scintigraphy in forty-eight patients with the Zollinger-Ellison syndrome. *Eur J Nucl Med* 1994; 21: 1191-7.
- 21 Gibril F, Reynolds JC, Doppman JL, Chen CC, Venzon DJ, Termanini B, *et al.* Somatostatin receptor scintigraphy: its sensitivity compared with that of other imaging methods in detecting primary and metastatic gastrinomas. A prospective study. *Ann Intern Med* 1996; 125: 26-34.
- 22 Krenning EP, Kwekkeboom DJK, Pauwels S, Kvols LK, Reubi JC. Somatostatin receptor scintigraphy. In: Freeman LM, ed. *Nuclear medicine annual*. New York: Raven Press, 1995: 1-50.
- 23 Schirmer WJ, Melvin WS, Rush RM, O'Doriso TM, Pozderac RV, Olsen JO, *et al.* Indium-111-pentetreotide scanning versus conventional imaging techniques for the localization of gastrinoma. *Surgery* 1995; 118: 1105-14.
- 24 Zimmer T, Stötzel U, Bäder M, Koppenhagen K, Hamm B, Buhr H, *et al.* Endoscopic ultrasonography and somatostatin receptor scintigraphy in the preoperative localisation of insulinomas and gastrinomas. *Gut* 1996; 39: 562-8.
- 25 Krenning EP, Kwekkeboom DJ, Oei HY, de Jong RJB, Dop FJ, de Herder WW, *et al.* Somatostatin receptor scintigraphy in carcinoids, gastrinomas and Cushing's syndrome. *Digestion* 1994; 55 (suppl 3): 54-9.
- 26 Jamar F, Fiase R, Leners N, Pauwels S. Somatostatin receptor imaging with indium-111-pentetreotide in gastroenteropancreatic neuroendocrine tumors: safety, efficacy and impact on patient management. *J Nucl Med* 1995; 36: 542-9.
- 27 Reubi JC. Clinical relevance of somatostatin receptor imaging. *Eur J Endocrinol* 1994; 131: 575-6.
- 28 Lebtahi R, Cadiot G, Sarda L, Daou D, Faraggi M, Petegnief Y, *et al.* Clinical impact of somatostatin receptor scintigraphy on the management of patients with neuroendocrine gastroenteropancreatic tumors. *J Nucl Med*. In press.
- 29 Gibril F, Reynolds JC, Doppman JL, Chen CC, Termanini B, Stewart CA, *et al.* Does the use of octreoscan alter management in patients with Zollinger-Ellison syndrome: a prospective study? [abstract]. *Gastroenterology* 1995; 108: 194.
- 30 Mignon M, Jais P, Cadiot G, Ben Yedder D, Vatiar J. Clinical features and advances in biological diagnostic criteria for Zollinger-Ellison syndrome. In: Mignon M, Jensen RT, eds. Endocrine tumors of the pancreas: recent advances in research and management. Basel: Karger. *Front Gastrointest Res* 1995; 23: 223-39.
- 31 Orbuch M, Doppman JL, Strader DB, Fishbeyn VA, Benya RV, Metz DC, *et al.* Imaging for pancreatic endocrine tumor localization: recent advances. In: Mignon M, Jensen RT, eds. Endocrine tumors of the pancreas: recent advances in research and management. Basel: Karger. *Front Gastrointest Res* 1995; 23: 268-81.
- 32 Berger JF, Laissy JP, Limot O, Henry-Feugeas MC, Cadiot G, Mignon M, *et al.* Differentiation between multiple liver hemangiomas and liver metastases of gastrinomas: value of enhanced MRI. *J Comput Assist Tomogr* 1996; 20: 349-55.
- 33 Gibril F, Fraker DL, Alexander HR, Termanini B, Stewart CA, Sutliff VE, *et al.* Does the use of preoperative somatostatin receptor scintigraphy (SRS) have an impact in improving postoperative cure rate in patients undergoing surgery with Zollinger-Ellison syndrome (ZES): a prospective study [abstract]. *Gastroenterology* 1996; 110: 391.
- 34 Scarpignato C. Somatostatin analogues in the management of endocrine tumors of the pancreas. In: Mignon M, Jensen RT, eds. Endocrine tumors of the pancreas: recent advances in research and management. Basel: Karger. *Front Gastrointest Res* 1995; 23: 385-415.
- 35 Termanini B, Gibril F, Doppman JH, Stewart CA, Sutliff VE, Jensen RT. Somatostatin receptor scintigraphy (SRS), a new method to distinguish hepatic hemangiomas from vascular liver metastases in pancreatic endocrine tumors (PET) [abstract]. *Gastroenterology* 1996; 110: 437.