

# Hemispherectomy—a modification

CBT ADAMS

*From the Department of Neurosurgery, Radcliffe Infirmary, Oxford, UK*

**SUMMARY** Hemispherectomy is probably the best operation for treating epilepsy. It was abandoned because of the delayed haemorrhagic complications that developed some years after the operation. A hypothesis is described to account for the mechanism of such complications and modifications made to the operative technique to prevent such complications. This modified hemispherectomy has been carried out on four patients since 1980.

“It is a pity that such a beneficial operation should be abandoned”, wrote Northfield<sup>1</sup> who also stated that hemispherectomy has proved to be the most successful of all operations for the relief of epilepsy. The operation was abandoned because of delayed haemorrhagic complications leading to obstructive hydrocephalus, superficial siderosis, and intracranial haematoma. The incidence of such complications varied from 18% to 35%.<sup>2-5</sup> The essential features found at necropsy were: (1) A haemorrhagic subdural membrane lining the hemispherectomy cavity. The cavity may contain either xanthochromic or frankly bloodstained fluid or, on occasions, solid haematoma. The haemorrhagic membrane line not only the dura but the remaining basal nuclei and communicated with the third ventricle through the patent and enlarged foramen of Monro. (2) The remaining ventricular system was lined by granular ependymitis.<sup>5</sup> This consisted of a proliferative layer of fibro-glia covering the ependyma which itself covered a layer of subependymal gliosis. The lining contained phagocytes which contained iron and, particularly near vessels, haemosiderin: evidence of the liability of this membrane to bleed. The proliferative and granular ependymitis obstructed either the aqueduct or the exit foramina of the fourth ventricle. One reported case developed an encysted temporal horn due to obstruction of the lateral ventricle in the region of the trigone (case 4 Falconer and Wilson<sup>3</sup>). (3) In the subdural space there was superficial siderosis causing a brown staining in the region of the brain stem, cerebellum, and spinal cord. The subpial haemosiderin extended to a

depth of about 2 mm and the cerebellum and eighth cranial nerve seemed to be particularly susceptible. Despite these publications little consideration was given to elucidating the mechanism by which the haemorrhagic complications arose and hence could be prevented. It was accepted that bleeding into the operative cavity was the essential cause but how this then developed into obstructive hydrocephalus and superficial siderosis was not clearly enunciated. Wilson<sup>4</sup> recorded some important clinical facts. He noted that those patients afflicted invariably had bloodstained or xanthochromic cerebrospinal fluid and air encephalography showed communication between the ventricles and the operative cavity.

It would seem that a possible sequence of events is as follows: Following the operation of hemispherectomy, blood becomes deposited on the inner surface of the dura and the remaining stump of the hemisphere. A subdural membrane, or indeed a series of membranes, develop in the same way as with a chronic subdural haematoma. Such membranes bleed from time to time, sometimes spontaneously and at other times from minor trauma. However, unlike other subdural haematomas the cavity communicates with the ventricular system via an enlarged foramen of Monro, and so the ependyma and subarachnoid spaces are subjected to frequent minor bleeds with iron deposited in the phagocytes of the superficial layers of the ependyma and pia. This produces respectively granular ependymitis and superficial siderosis. This results in a complex, intermittent and varying clinical syndrome, which is an amalgam of chronic meningeal irritation from bleeding, raised intracranial pressure as a result of obstructive hydrocephalus, and cerebellar and cranial nerve abnormalities due to superficial siderosis.

It therefore follows that there should be two objectives. The first is to prevent, as far as possible, the formation of a subdural haematoma in the

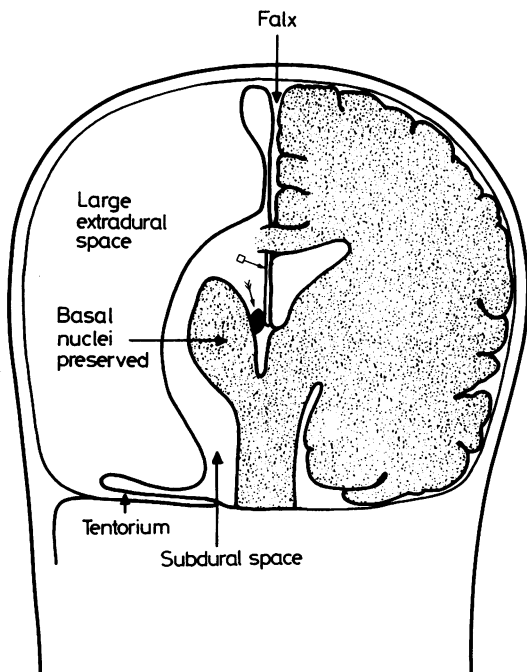
Address for reprint requests: Mr CBT Adams, The Radcliffe Infirmary, Oxford OX2 6HE, UK.

Received 3 July 1982 and in revised form 27 January 1983.

Accepted 10 February 1983.

operative cavity and secondly to impede communication between the cavity and ventricular system so as to prevent the perfusion of the ventricles and subarachnoid spaces with blood from the operative cavity.

To achieve these objectives the following technical principles are suggested: (1) Immaculate haemostasis at the time of the operation to reduce the likelihood of subdural haematoma formation. (2) Reduction in the subdural space, both in the surface area of the dura, as well as the volume of the subdural cavity, so as to discourage subdural haematoma formation. This can be achieved by creating an extradural space at the expense of the subdural space by mobilising the dura and suturing the dura down to the falx, tentorium, and the dura lining the floor of the middle and anterior cranial fossae (fig 1). (3) Insulation of the subdural cavity from the ventricular system. This is the most important objective of all and is achieved by obstructing the ipsilateral foramen of Monro by a plug of muscle (fig 1). It is also important to keep the septum pellucidum intact. The insulation of the subdural cavity from the ventricular system requires, of



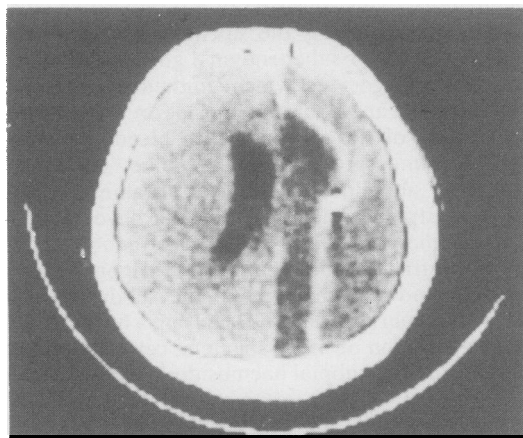
**Fig 1** Diagram illustrating the modification of hemispherectomy by creating a large extradural space. Boxed arrow emphasises the importance of preserving the septum pellucidum. Double arrow shows the foramen of Monro obstructed.

course, that the remaining choroid plexus on the operated side is completely destroyed.

Since February 1980 these principles and modifications have been used to perform hemispherectomies for patients with infantile hemiplegia and epilepsy. Four such operations have been done with cessation of epilepsy and improvement of behaviour in all four patients. The CT scans provided evidence of successful insulation of the subdural (operative) cavity from the remaining ventricles (fig 2). Further evidence is provided by the first patient who in the immediate post-operative period developed hydrocephalus. The scan at that time (fig 3) showed a marked shift of the midline structures from right to left suggesting successful obliteration of the foramen of Monro. If this foramen had been patent then the pressure in the subdural cavity would be equivalent and the development of hydrocephalus would not have been associated with any further shift of the midline structures. When a shunt was carried out the ventricular cerebrospinal fluid was clear and colourless, implying there had been no perfusion of blood from the operative cavity.

## Discussion

Wilson and Gibbs (personal communications) first had the idea of preventing late haemorrhagic complications by creating a large extradural space at the expense of the operative cavity. They carried out a hemispherectomy for a glioma and then sutured the vault dura down to the falx, tentorium, and dura lining the base of the skull. They did not publish this technique but Wilson referred to this particular



**Fig 2** CT scan showing different densities in the left lateral ventricle, the operative (subdural) cavity and the extradural cavity. The dura, with a Cushing clip, is highlighted because of a lining membrane of blood.

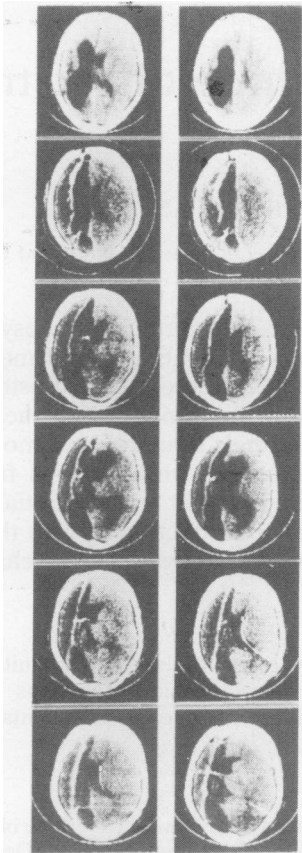


Fig 3 Serial CT scans to show the evolution of early post-operative hydrocephalus, the natural enlargement of the remaining hemisphere and the maintenance of the extradural cavity.

operation in his 1970 paper. Wilson and Ashley<sup>6</sup> recorded a hemispherectomy carried out in 1970 for a malignant glioma using the same technique of creating a large extradural space. In this important paper they referred to the importance of preventing blood from the operative cavity perfusing the ventricles and they advised against fenestrating the septum pellucidum but they did not recommend obstructing the foramen of Monro. Also they noted the absence of haemosiderosis and ependymitis at necropsy, one year after this operation. There is, therefore, reasonable evidence that such a technique does prevent the delayed complications of hemispherectomy and that the large extradural dead space does not give rise to complications. Wilson (personal communication) has carried out a similar procedure on a further patient with a glioma. As these patients all had tumours the follow up period was limited.

The Montreal group have approached the problem differently and Rasmussen described this in his Penfield Award Lecture given in Toronto in June 1982. Eleven of their 31 hemispherectomised patients developed late complications but none of their series of 40 patients undergoing subtotal hemispherectomy (that is leaving  $\frac{1}{4}$ – $\frac{1}{3}$  of the hemisphere) suffered late haemorrhagic complications, although the results in terms of relief of epilepsy were significantly less good after subtotal hemispherectomy. Because preservation of part of the hemisphere conferred protection from late complications Rasmussen suggested the remaining portions splinted the brain and so reduced its vulnerability to repeated bleeding. He did not consider in detail the causation of the delayed complications or how such splinting prevents them. But it is conceivable that the haemorrhagic membrane that lines the operative cavity is liable to bleed if jolted or distorted by movement of a remaining hemisphere and falx and if this hemisphere is splinted by a buttress of brain at the front or back of the operative cavity then bleeding will be less likely to occur. However, it would still seem possible, with this technique, for blood from a remaining operative cavity to perfuse the ventricles through the enlarged foramen of Munro and give rise to delayed complications.

The numbers of patients and follow up are insufficient with either technique to be certain that delayed complications have been avoided. However, there are reasonable grounds to believe that it is possible to prevent these complications by using the principles and modifications suggested in this paper. Only time will tell but the children who need this operation do not have time on their side. Children should still be offered a hemispherectomy, suitably modified, when the indications demand it.

#### References

- 1 Northfield DWC. *The Surgery of the Central Nervous System*. Oxford: Blackwell, 1973.
- 2 Oppenheimer DR, Griffith HB. Persistent intracranial bleeding as a complication of hemispherectomy. *J Neurol Neurosurg Psychiatry* 1966;**29**:229–40.
- 3 Falconer MA, Wilson PJE. Complications related to delayed haemorrhage after hemispherectomy. *J Neurosurg* 1969;**30**:413–26.
- 4 Wilson PJE. Cerebral hemispherectomy for infantile hemiplegia. *Brain* 1970;**93**:147–80.
- 5 Hughes JT, Oppenheimer DR. Superficial siderosis of the central nervous system. *Acta Neuropathol (Berl)* 1969;**13**:56–74.
- 6 Wilson PJE, Ashley DJB. Meningioma after contralateral hemispherectomy for malignant glioma: case report. *J Neurol Neurosurg Psychiatry* 1975;**38**:493–9.