

## Palatal myoclonus—its remote influence

MASANORI NAGAOKA, HIROTARO NARABAYASHI

*From the Department of Neurology, Juntendo University, School of Medicine, Tokyo, Japan*

**SUMMARY** Four patients with palatal myoclonus were examined electromyographically. Surface EMG was recorded simultaneously from several myoclonic muscles and the correlation between their rhythmic discharges was shown. The possible existence of a remote influence of palatal myoclonus was tested by recording soleus and anterior tibial H-reflexes and seeking a correlation of their amplitudes with the rhythm of palatal myoclonus. Two cases, both with additional severe spasticity in the legs, showed rhythmic variation of the soleus H-reflex amplitude corresponding with that of their palatal myoclonus. This suggests that the neural mechanism generating the visible myoclonus has much more extensive effects.

Palatal myoclonus is an important sign of a brain-stem lesion, particularly involving Guillain-Mollaret's triangle.<sup>1-6</sup> This rhythmic involuntary movement may extend to the branchial muscles, but most commonly is restricted to the oropharyngeal muscles. It continues during sleep and anaesthesia. These features distinguish it from Parkinsonian tremor.<sup>2</sup> A rhythm generator has been proposed as the cause of palatal myoclonus on the basis of polygraphic studies.<sup>7</sup> However, in spite of its well-defined pathology, its pathophysiological mechanism is still unknown. In this paper, electromyographic studies are reported which examined the rhythm generator hypothesis.

### Material and methods

Four patients with palatal myoclonus were studied. Their clinical features are described in detail below, and summarised in the table.

#### Case 1

A 46-year-old man had been healthy until the age of 44 years, when he began to tire easily. Two months later, his gait tended to veer to the left and he became dysarthric. He was emotionally unstable and cried easily. These symptoms gradually progressed, so he was admitted to hospital at the age of 46 years. He showed dementia and emotional incontinence. Dysarthria and dysphagia were interpreted as symptoms of pseudobulbar palsy. The tendon reflexes were generally increased, and both plantar responses were

extensor. There was bilateral ataxia. The motor signs were more dominant on the left side. No sensory disturbances were detected. He could hardly move the legs, and remained almost bedridden. On admission, rhythmic myoclonus was recognised in the soft palate, throat and diaphragm. In the next two months, this myoclonus extended to the muscles of the face, eyes, neck and shoulder girdles on both sides. No myoclonic contraction was observed in the other parts of the body. Behçet's disease was tentatively proposed, since pleocytosis of the cerebrospinal fluid and an intermittent aphthous stomatitis were present.

#### Case 2

A 50-year-old house-wife was admitted to hospital because of progressive neurological disturbances for five years. She complained of dysarthria, dysphagia and clumsiness of hand movements. Four years previously she had an episode of hypotension. Soon afterwards she became bedridden. Neurological examination revealed cerebellar ataxia, a spastic paraplegia and a pseudobulbar palsy. She was unable to move her legs. The soft palate showed symmetrical rhythmic myoclonus. Both eyes showed horizontal nystagmoid movements with little difference between the slow and quick phases. These rhythmic movements were not noticed in any other part of the body. Neuroradiological examination revealed marked atrophy of midbrain, pons and cerebellum. Based on the other negative laboratory findings and the slowly progressive course of her illness, a diagnosis of spinocerebellar degeneration with marked spasticity and palatal myoclonus was made. The interval between the occurrence of presumed lesions and the appearance of palatal myoclonus could not be determined.

#### Case 3

A 51-year-old woman had a thrombosis of the basilar artery two years previously. Thereafter she showed a right Horner's syndrome, a right peripheral facial palsy, a dis-

Address for reprint requests: Dr Masanori Nagaoka, Department of Neurology, Juntendo University, School of Medicine, 2-1-1 Hongo, Bunkyo-ku, Tokyo 113, Japan.

Received 28 March 1983 and in revised form 28 December 1983.  
Accepted 4 February 1984

Table Clinical features and results of EMG analysis

Case No.	Age (yr)	Sex	Diagnosis	Delay (mo)	Distribution of myoclonus	Rhythm (/min)	ADL	Muscle strength		Babinski sign (bilateral)	Ankle clonus	EMG analysis		
								T.A.	T. surae			Close interrelation of PM rhythm on several muscles	Remote influence of PM rhythm on T.A. Soleus	
1	46	M	Behçet's syndrome	? (< 24)	Soft palate, eyeball, face, neck, shoulder, diaphragm	140	bedridden	0	1	+	+	+	**	+
2	50	F	Cerebellar degeneration	?	Soft palate, eyeball	160	bedridden	1	2	+	+	+	-	+
3	51	F	Brain stem infarction	7	Soft palate, face, neck, diaphragm	140	ataxic gait	4	4	-	-	+	**	-
4	74	M	Brain stem infarction	5	Soft palate, eyeball, face, neck, diaphragm	190 (90)	akinetetic mutism	*	*	-	-	+	-	-

\*only withdrawal movements to painful stimuli

\*\*H-reflex not obtainable

TA = tibialis anterior muscle

PM = palatal myoclonus

ADL = activities of daily living

turbance of superficial sensation of the right side of the face and of the left side of the body. Deep tendon reflexes were slightly increased on the right side, but the plantar responses were flexor. Seven months after the stroke she noticed coarse tremor of the right arm and rhythmic myoclonus of the soft palate and the right corner of the mouth. After eleven months, a nucleus ventralis intermedius thalamotomy was performed on the left side for the relief of the coarse tremor of the right arm by one of the authors (HN). The tremor was markedly decreased. She could then write letters again; she could walk with some help, but was unstable. The interval between the thrombus and the appearance of palatal myoclonus was about seven months. The thalamotomy (Vim) was mainly effective in relieving the tremor of the arm, but had no effect on palatal myoclonus. The rhythmic myoclonus was observed also in the neck muscles, shoulder and diaphragm.

#### Case 4

A 74-year-old man was admitted to hospital with progressive disturbance of consciousness over several hours. After the acute stage lasting two or three days, he survived with akinetic mutism. He had bilateral oculomotor palsy, but several brain-stem reflexes (blink reflex and swallowing reflex) were preserved. Deep tendon reflexes were normal and the plantar response was flexor. Painful stimuli applied to any part of his body provoked non-stereotyped withdrawal responses. The main lesion was thought to be located in the midbrain. About two months later, the same stimuli evoked a tonic jaw opening response which persisted for the duration of applying the painful stimulus. This was thought to be the primitive reflex, the jaw opening reflex, described by Sherrington.<sup>8</sup> About five months later, palatal myoclonus appeared. In the following four months, the myoclonus extended to the eyes, neck, and respiratory muscles. At that time, the jaw opening

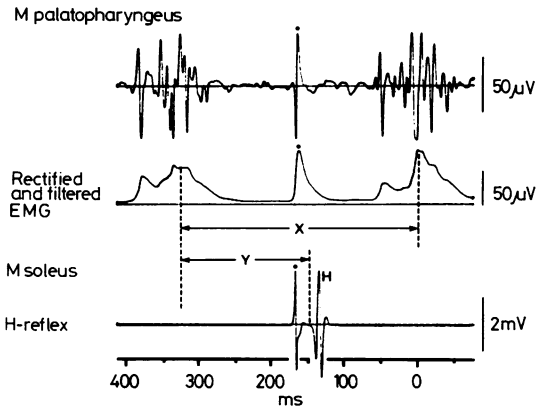
response changed from tonic to an intermittent pattern, resembling masticatory movements.

*Electromyograms (EMG)* were recorded routinely (LF:10Hz, HF:10KHz) by surface electrodes, except from deep muscles, into which fine wire electrodes were inserted. The excitability of soleus and tibialis anterior motoneurons was tested by recording H-reflexes from each muscle. The patient lay supine on a couch. Surface electrodes were used for both stimulation and recording. For the soleus muscle, single stimulating pulses (1 ms duration) were given percutaneously to the posterior tibial nerve in the popliteal fossa. For the tibialis anterior muscle, single or repetitive pulses (2-3 pulses, 300Hz) were given to the peroneal nerve at the head of the fibula at 3.5-5.0 s intervals. Stimulus intensity was adjusted to produce submaximal H-reflexes (about 70% of Hmax). About two hundred H-reflexes were recorded and their amplitude was correlated to that of the palatal myoclonus (fig 1). In order to compare the onset of EMG discharges between m palatopharyngeus and other myoclonic muscles, EMG activities were rectified and averaged by computer (ATAC 450, Nihon-kohden).

## Results

### (1) Analysis on the visible myoclonus

Rhythmic EMG discharges corresponding to visible palatal myoclonus were recorded from the m palatopharyngeus in all cases. The mean frequency is shown in the Table, but the frequency was not constant. For example, in case 1 the mean frequency was about 2.5Hz, varying between 1.9 and 3.7Hz (fig 2A). The frequency variation did not correspond to pain stimulation or voluntary movements

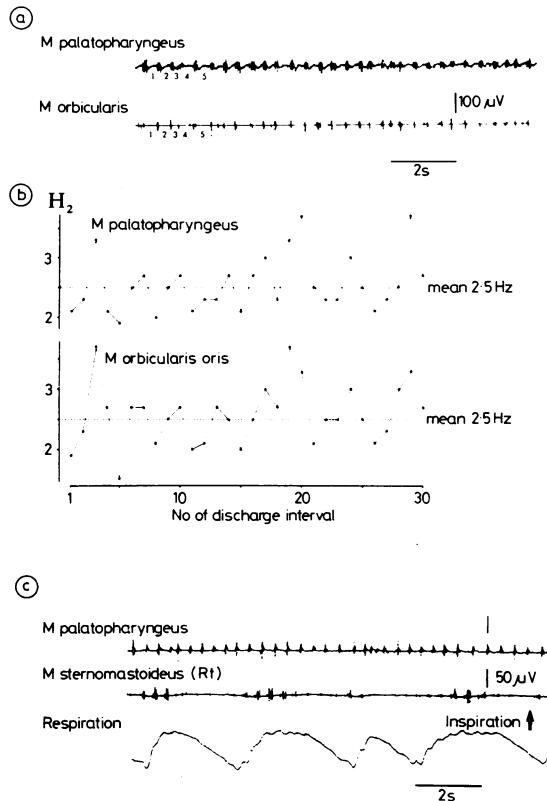


**Fig 1** Analysis of the remote influence of palatal myoclonus. The upper and middle traces are raw EMG and rectified and filtered EMG (TC 0-01) of *m palatopharyngeus*. The lowest trace is the evoked H-reflex of *m soleus*. The excitability of leg muscle motoneurons was measured by peak to peak amplitude of the H-reflex. The temporal relation of evoked H-reflex to the rhythm of soft palate myoclonus was represented as  $\%(Y/X) \times 100$ . "Y" was the interval between the peak of preceding myoclonus and the onset of H-reflex, and "X" was the interval between two successive discharges of soft palate myoclonus. The filled circle was the stimulus artifact.

of other parts of the body. The other myoclonic muscles also showed rhythmic EMG activities (fig 2A), and the frequency was the same as in the *m palatopharyngeus*. The firing probability of discharges in other muscles was highly correlated with that of *m palatopharyngeus* (fig 2B). Such close correlation of EMG discharges among these myoclonic muscles was observed in all cases.

Myoclonus did not necessarily persist in all muscles all the time. For example, in the *m sternomastoid*, rhythmic activity increased in amplitude during the inspiratory phase, when it was activated as an inspiratory accessory muscle (fig 2C). But, these effects disappeared, particularly in the relaxed condition (as in sleep). The augmentation of rhythmic activities by voluntary effort were seen on the shoulder muscles in case 3. The rhythmic myoclonic discharges were not exactly synchronous and the facio-cervical muscle group might be preceded by the *m palatopharyngeus* in some cases. The time of averaged peak in the EMG of *m sternomastoid* preceded (by about 20–30% of averaged myoclonus interval) that of soft palate in case 1 (fig 3A) and (by about 10%) in case 3 (fig 3B). But close synchronicity was observed in case 4. In case 2, this comparison was impossible because myoclonus was restricted to the eyes and soft palate muscles.

A striking feature of palatal myoclonus is that



**Fig 2** EMG activities of visible myoclonus (case 1). The EMG activities of *m palatopharyngeus* and *m orbicularis* are shown in A. The correlation of rhythmic discharges on these muscles are represented as the instantaneous frequency diagram in B. The abscissa is the serial number of discharge intervals shown under each trace in A. The ordinate is the frequency (Hz) of numbered intervals in each muscle. The augmentation of rhythmic discharge amplitudes are shown for *m sternomastoid*, which was used as an inspiratory accessory muscle in C. The lowest trace is the respiratory curve.

myoclonic discharges in various muscles, when apparent, all seem to have the same rhythm.<sup>7</sup>

### (2) Remote influence of palatal myoclonus

These observations suggest that the absence of myoclonus, for instance in leg muscles, might not necessarily mean that these muscles do not receive such rhythmic influence. So we analysed the change of excitability of the soleus and tibialis anterior motoneurons which are located away from the brain stem (fig 1). The amplitude of soleus H-reflexes showed some variations which related closely with palatal myoclonus in case 1 (fig 4). The H-reflexes tended to be small when evoked during the weaker myoclonic activities and larger during the stronger.

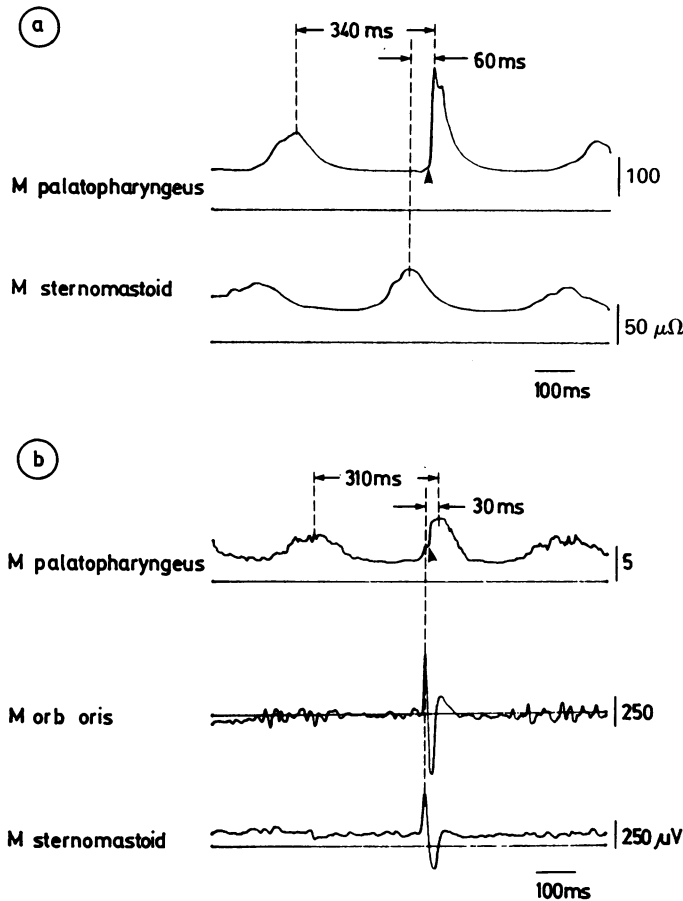


Fig 3 Comparison of peaks of rhythmic activity in several muscles. Rectified activity of *m palatopharyngeus* was triggered at the arrow head, and averaged 30 times. In A, rectified EMG of *m sternomastoid* of case 1 is simultaneously averaged; its peak precedes by about 20–30% of the myoclonus interval that of *m palatopharyngeus*. In B, raw EMG of *m orbicularis oris* and *m sternomastoid* of case 3 is simultaneously averaged. In this case, facio-cervical muscles leads by about 10% of the myoclonus interval.

In case 2, the same tendency was observed, but the change was less obvious (fig 5). This finding was observed on both sides, and persisted during repeated investigations in cases 1 and 2. The largest H-reflexes preceded the peak of myoclonic activities, about 20–30% of the palatal myoclonus interval in case 1, and if any, about 10% in case 2. This finding was not observed in cases 3 and 4 (fig 6). For the tibialis anterior muscle, we could obtain H-reflexes only in case 2 and case 4. Contrary to the results with the soleus, no such change of H-reflex amplitudes was observed.

### Discussion

The patients showed typical palatal myoclonus, as shown by the clinical and electromyographic features. It is well known that in palatal myoclonus the causative lesion lies in the brain stem and that destruction of the dentato-olivary connection through the superior cerebellar peduncle is crucial.<sup>5</sup> Myoc-

lonus appeared mainly in the oropharyngeal muscles whose nuclei are located in the medulla oblongata near the inferior olivary nucleus. From these anatomical findings, Trelles<sup>6</sup> postulated palatal myoclonus to be a result of release of the nucleus ambiguus from the normally inhibitory action of the dentato-olivary system. Based on the polygraphic analysis of the clearly visible myoclonus, Tahmouh *et al*<sup>7</sup> postulated the existence of a "common mechanism" exerting its rhythmic influence widely beyond the branchial muscles. The close correlation of rhythmic discharges among several myoclonic muscles in our cases supports the hypothesis of Tahmouh *et al*<sup>7</sup> that there is a rhythm generator. Moreover, the myoclonus-related change of excitability of soleus motoneurons, which showed no myoclonus, demonstrates the more extensive and subtle influence on the lower legs.

The rhythms may be organised centrally, because in each result its own frequency is insensitive to sensory stimulation and voluntary activity. In view of

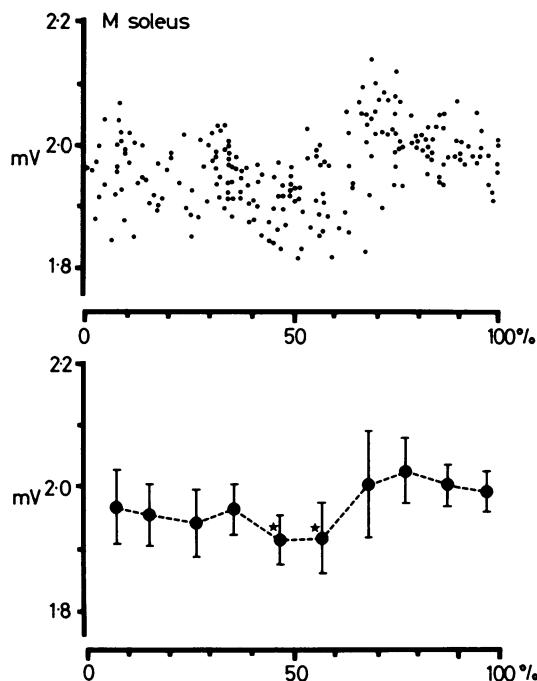


Fig 4 Change of H-reflex amplitude corresponding to soft palate myoclonus. Each point shows peak to peak values (mV) of each H-reflex of case 1. The abscissa is H-reflex amplitude and the ordinate is the temporal relation of evoked H-reflex to the rhythm of soft palate myoclonus. In lower half, the large filled circle show mean (SD) of each 10% interval. The largest H-reflexes preceded (by about 20–30% of the myoclonus interval) the EMG discharges of the soft palate myoclonus. The asterisks showed significant differences ( $p < 0.01$ ) compared with the largest group of H-reflex amplitudes.

the predominance of myoclonus in the oropharyngeal muscles, the rhythm generator should be located in the brainstem as postulated by Trelles.<sup>6</sup> By what pathway may the remote influence of a rhythm generator be conducted to the soleus motoneurons? As the controlling system of spinal motor mechanism, corticospinal and subcortical spinal tracts have been proposed.<sup>9</sup> For instance, these two mechanisms may exert some influence on the augmentation of myoclonic discharges of m sternomastoid in the inspiratory phase (fig 2C). The existence of a remote influence was not shown in all cases, but only in two cases with severe spasticity in the lower limbs. It may be that the same mechanisms underlying spasticity plays some part in the maintenance of the remote effect of palatal myoclonus.

Harmaline administration to cerebellectomised

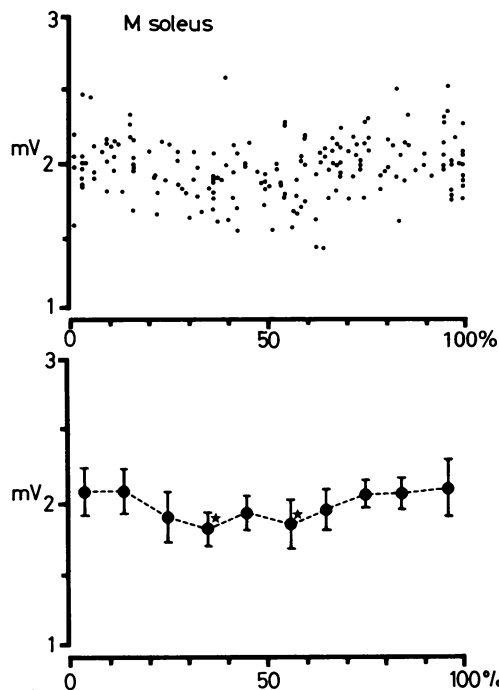


Fig 5 Change of H-reflex amplitude corresponding to soft palate myoclonus. The change of H-reflex amplitude in case 2 was less manifest than in case 1.

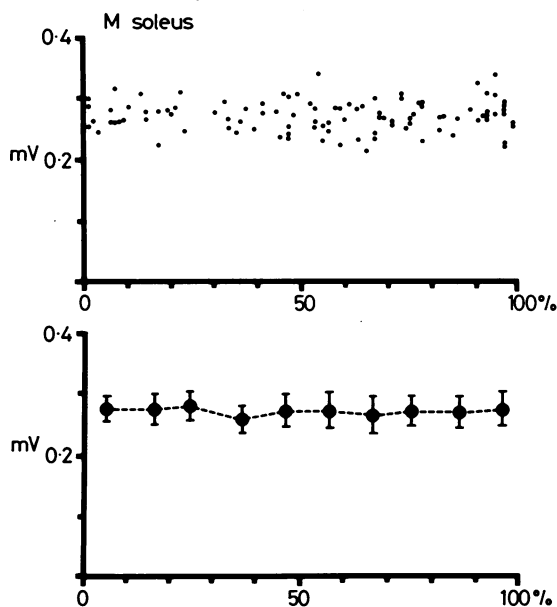


Fig 6 Change of H-reflex amplitude corresponding to soft palate myoclonus. In case 4, no apparent change was observed.

animal causes an experimental tremor, in which rhythmic discharges at 4–8 Hz are synchronous in antagonistic proximal muscles, in which the olivocerebellar system has been proposed as the rhythm generator.<sup>10</sup> These findings seem to be like those found in palatal myoclonus. Because of the persistence of tremor after the complete interruption of the direct corticospinal fibres, the bulbospinal pathway has been proposed as the conducting pathway of the rhythm in harmaline tremor.<sup>10</sup>

If a rhythm generator exists in the brainstem, one would expect the soleus, a muscle more distant from the brain stem, to be influenced later than the proximal muscles of the soft palate and face. However, the myoclonus in m palatopharyngeus (soft palate) did not necessarily precede that in other more distal muscles. This can be observed in figs 2C, 4A and 4B, and also in the previous report of Tahmouh *et al* (see fig 3 in reference 7). In case 1, the peak of EMG activity of m sternomastoid preceded that in m palatopharyngeus by about 20–30% of myoclonus interval, which roughly corresponded with the phase advance of the H-reflex change. Moreover, the face and neck muscles, the nuclei of which are located rostral and caudal respectively to nucleus ambiguus, were simultaneously activated slightly before the myoclonus of the soft palate in case 3. This phase advance can only be explained by assuming that the leg and facio-cervical muscles receive their rhythm in input prior to that of soft palate, and it has been reported that the orobranchio-respiratory and oculo-facio-cervical group may be influenced separately.<sup>2</sup>

The authors thank Dr R Tanaka, Department of Neurobiology, Tokyo Metropolitan Institute for Neurosciences, for his critical comments and

encouragement through this study. The assistance of Drs Y Sugita, H Takubo and K Nishi in our Department is also gratefully acknowledged.

#### References

- <sup>1</sup> Guillain G, Mollaret P. Deux cas de myoclonies synchrones et rythmées vélo-pharyngo-laryngo-oculo-diaphragmatiques. Le problème anatomique et physio-pathologique de ce syndrome. *Rev Neurol (Paris)* 1931;2:545–66.
- <sup>2</sup> Bonduelle M. The myoclonias. In: Vinken PJ, Bruyn GW, eds. *Handbook of Clinical Neurology*. Vol. 6. Amsterdam: Elsevier/North-Holland 1968:761–81.
- <sup>3</sup> Rondot P, Ben Hamida M. Myoclonies du voile et myoclonies squelettiques; étude clinique et anatomique. *Rev Neurol (Paris)* 1968;119:59–83.
- <sup>4</sup> Halliday AM. The neurophysiology of myoclonic jerking—a reappraisal. In: Charlton MH, ed. *Myoclonic Seizures*. Amsterdam: Excerpta Medica 1975:1–29.
- <sup>5</sup> Lapresle J. Rhythmic palatal myoclonus and the dentato-olivary pathway. *J Neurol* 1979;220:223–30.
- <sup>6</sup> Trelles JO. Les myoclonies vélo-palatines. Considerations anatomiques et physiologiques. *Rev Neurol (Paris)* 1968;119:165–71.
- <sup>7</sup> Tahmouh AJ, Brooks JE, Keltner JL. Palatal myoclonus associated with abnormal ocular and extremity movements. A polygraphic study. *Arch Neurol* 1972;27:431–40.
- <sup>8</sup> Sherrington C. *The Integrative Action of the Nervous System*. ed 2. Yale University Press, New Haven 1947:295.
- <sup>9</sup> Lawrence DG, Kuypers HGJM. The functional organisation of the motor system of the monkey. I. The effects of bilateral pyramidal lesions. II. The effects of lesions in the descending brain-stem pathways. *Brain* 1968;91:1–14, 15–36.
- <sup>10</sup> Lamarre Y. Cerebro-cerebellar mechanisms involved in experimental tremor. In: Massion J, Sasaki K, eds. *Cerebro-cerebellar Interaction*. Amsterdam: Elsevier/North-Holland Biomedical Press 1979:249–59.