

# Basal ganglia calcification in Down's syndrome

S TAKASHIMA, LE BECKER

From the Division of Neuropathology, Department of Pathology, University of Toronto, The Hospital for Sick Children, and Toronto General Hospital, Toronto, Ontario, Canada

**SUMMARY** The basal ganglia from 33 patients (all over one year of age) with Down's syndrome were examined pathologically. Forty-five per cent had calcification. Basal ganglia calcification was localised to a constant area of globus pallidus and became more prominent with increased age. Calcification and amyloid degeneration of the adjacent blood vessels were present. The proximity of abnormal blood vessels to basal ganglia calcification suggests a pathogenetic relationship.

Individual cases of basal ganglia calcification at necropsy in Down's syndrome have been noted<sup>1-3</sup> and recently, basal ganglia calcification in patients with Down's syndrome was correlated on computed tomography and neuropathological examination (unpublished data).<sup>4</sup> Basal ganglia calcification may be a manifestation of premature ageing; however, its pathogenesis in Down's syndrome is not known.

We reviewed the necropsies on patients with Down's syndrome and examined brain tissue by neuropathological techniques, comparing degree of basal ganglia calcification, vascular amyloidosis, astroglial proliferation and neurofibrillary degeneration.

## Patients and methods

We reviewed the necropsies on the 228 Down's syndrome patients done at The Hospital for Sick Children and Toronto General Hospital from 1963 to 1982. Of these, the 33 cases that were older than one year and had good representative sections of basal ganglia were selected and their neuropathology examined. They ranged in age from one year to 60 years. Clinical data were taken from clinical and/or necropsy records. The diagnosis of congenital heart disease was based on the necropsy observations.

In addition to routine pathological examination of brain tissue, Luxol fast blue, Bielschowsky, Van Gieson, Congo red and glial fibrillary acidic protein (GFAP) (immunoperoxidase reaction) stains of basal ganglia and Bielschowsky stain of hippocampus were done. Histological severity of basal ganglia calcification was graded as: negative (-), no basal ganglia calcification; borderline ( $\pm$ ), single

globules in some fields; mild (+), single globules in all fields; moderate (++) , numerous deposits; and severe (+++) , massive deposits. The severity of gliosis and neurofibrillary degeneration was also graded as negative (-), mild (+), moderate (++) and marked (+++).

## Results

### (1) Basal ganglia calcification

The relationship between age and grade of basal ganglia calcification is shown in fig 1. The five cases with severe basal ganglia calcification had massive clusters of branched and polycyclic calcium deposits in the basal ganglia, predominantly at the medial side of the lateral medullary lamina of globus pallidus.<sup>5</sup> Calcium deposits in putamen ranged from + to +++ (+ in three, ++ in one and +++ in one). Some cases had mild deposits in the capsula interna. The perivascular calcium droplets were of various sizes and mainly around small vessels. Vascular wall calcification was evident in the large vessels (fig 2), particularly in the media and adventitia of arteries. In the four patients

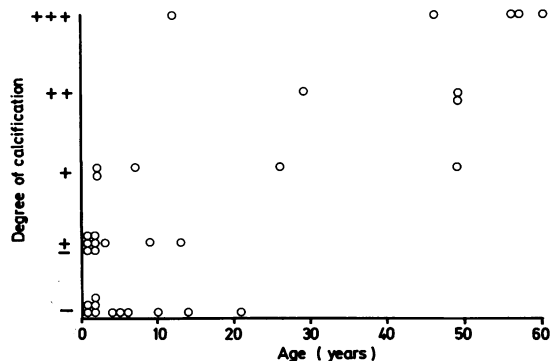


Fig 1 Relationship between basal ganglia calcification and age in Down's syndrome.

Address for reprint requests: Dr LE Becker, Department of Pathology, The Hospital for Sick Children, 555 University Avenue, Toronto, Ontario, Canada M5G 1X8.

Received 23 March 1984 and in revised form 20 June 1984.  
Accepted 25 June 1984

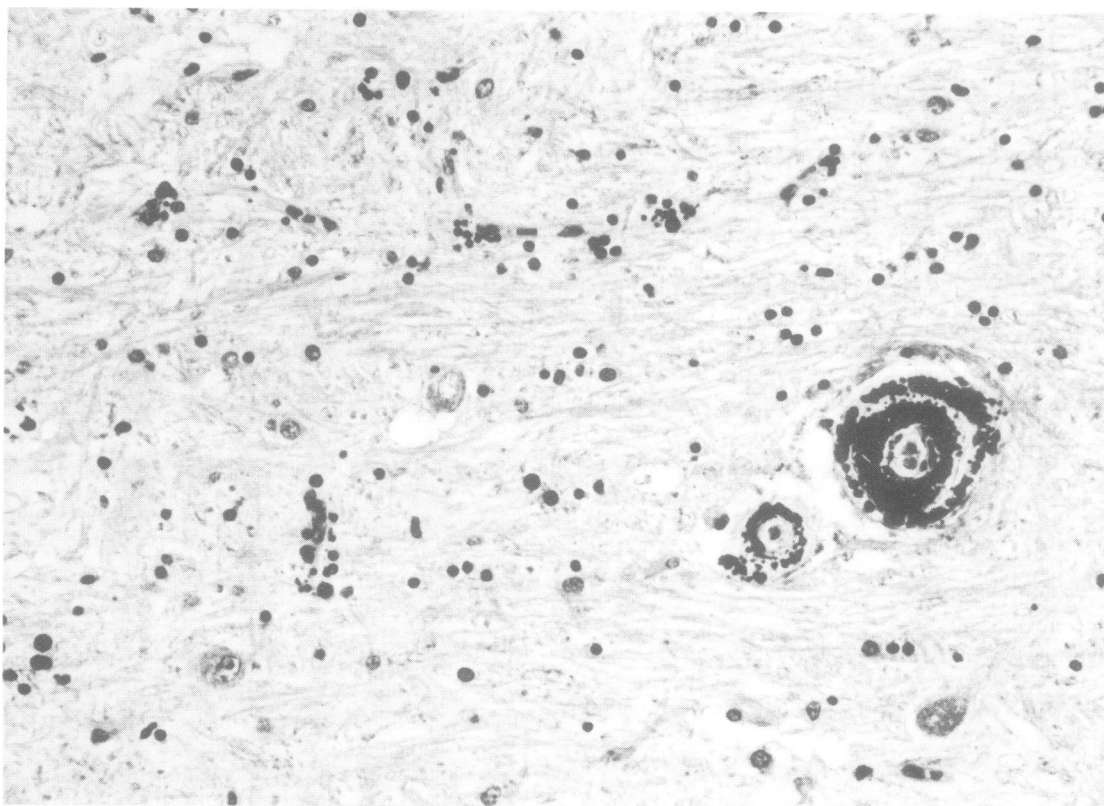


Fig 2 Perivascular calcium droplets around small vessels and vascular wall calcification of larger arteries in globus pallidus. H&E stain,  $\times 260$ .

between the ages of 45 and 60 years, there was intimal thickening and hyalinisation of the arterial wall. Two of these four cases had old infarction in other parts of the brain. The adolescent had partial or complete circumferential calcification of elastic lamina in these arteries.

The three patients with moderate basal ganglia calcification had numerous calcium deposits in the same areas as patients with severe basal ganglia calcification. In these cases there was borderline-to-moderate calcification in the putamen and calcification in the media of the arteries.

In the five cases with mild basal ganglia calcification, single calcium globules were seen around many small vessels of the globus pallidus and in one case there was calcification of the vascular walls. Calcium deposits in putamen showed borderline-to-mild calcification (— in one,  $\pm$  in three and + in one).

Nine cases had single globules surrounding some small vessels of globus pallidus or putamen (borderline) and another 11 were negative.

### (2) Congo red and GFAP stains

All patients with moderate or severe basal ganglia calcification had some vascular calcification and amyloid deposition in the vascular wall. In the patients with prominent calcified vessels, all 29 years or older, amyloid deposits were apparent and in those with uncalcified vessels slight to moderate deposits were usually seen in the media at the outside of the elastic lamina. A 26-year-old patient had mild amyloid angiopathy together with mild basal ganglia calcification. In three cases more than 49 years old the neuropathological diagnosis was cerebral amyloid angiopathy, due to widespread involvement.

GFAP stain showed focal reactive astrogliosis in areas of basal ganglia calcification (fig 3), but the degrees of astrogliosis and basal ganglia calcification were not related.

### (3) Bielschowsky stain of hippocampus

Neurofibrillary degeneration was related to the age of the patients rather than the grading of basal ganglia

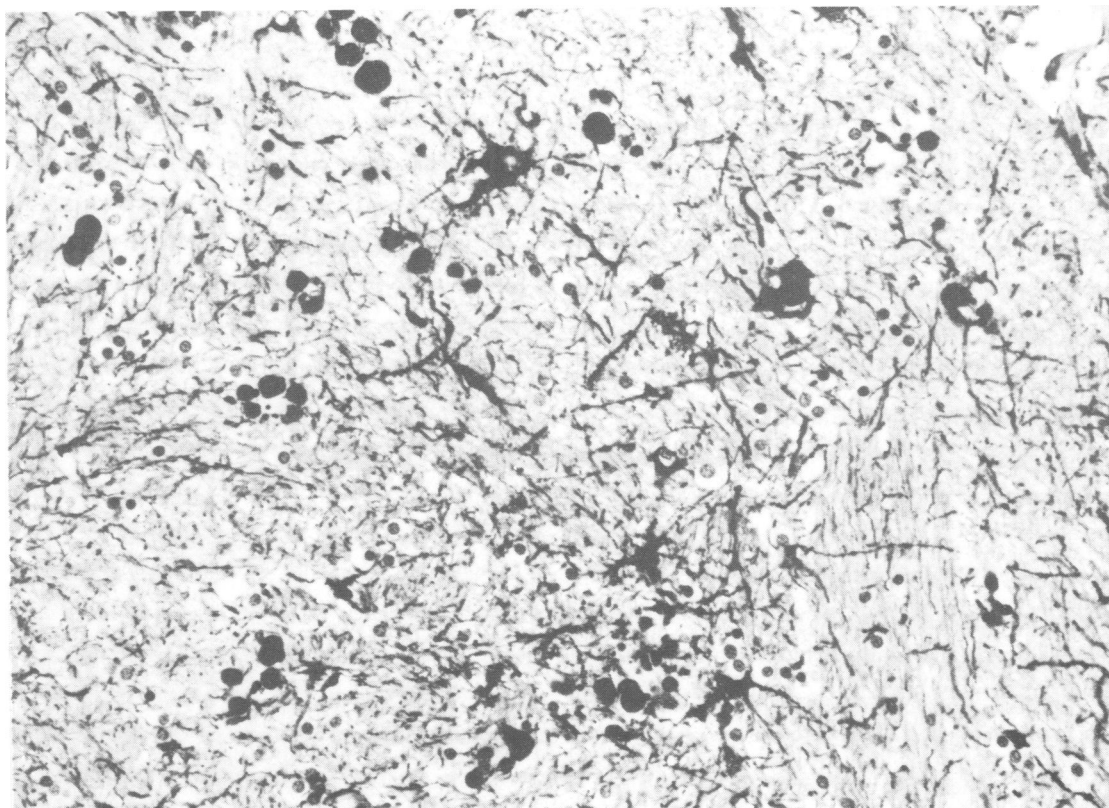


Fig 3 Focal reactive astrogliosis in area of calcification area of globus pallidus. GFAP stain,  $\times 150$ .

calcification. Neurofibrillary degeneration was marked in the patients older than 46 years and mild in those from 10 to 45 years old.

#### (4) Calcification of the cerebellum

Five cases had calcification in the wall of some vessels in the white matter and dentate nucleus of the cerebellum; three of them had severe basal ganglia calcification and two moderate calcification. Calcification was milder in the cerebellum than in basal ganglia.

#### Discussion

Recently, basal ganglia calcification has been seen on CT in 26.7% of cases (8 of 30 living Down's syndrome subjects aged 11 to 48 years)<sup>4</sup> and 10.7% of cases (6 of 56 living Down's syndrome subjects aged 0 to 37 years) (unpublished data). Basal ganglia calcification is detected in random populations by CT scanning in 0.3 to 0.6% of cases,<sup>5-10</sup> which indicates that it is more common in Down's syndrome than in the general population.

In comparison, Wisniewski *et al*<sup>4</sup> reported that basal ganglia calcification was detected histologically in 100% of cases (massive deposits in 33%, moderate in 15% and mild in 52%). In our study, definite basal ganglia calcification in Down's syndrome was present in 45% (15 of 33 brains). We found the degree increased with age but Wisniewski *et al*<sup>4</sup> reported more frequent basal ganglia calcification in the youngest and oldest Down's syndrome subjects.

Basal ganglia calcification in the normal population is occasionally observed in older patients (> 40 years). Slager and Wagner,<sup>7</sup> in their histological study of calcium deposits within basal ganglia in unselected necropsy patients, found an increased incidence with age. In Down's syndrome, basal ganglia calcification appears at a younger age; perhaps it is an indication of premature ageing.<sup>4</sup>

Histological and histochemical studies of basal ganglia calcification have shown that the calcification occurs in the pericapillary and the media of small arteries but the nerve cells generally remain unchanged. Slager and Wagner<sup>7</sup> assumed that the primary changes are compatible with pseudo-

calcification, which frequently involves the globus pallidus and dentate nucleus in old age and consists of a primary deposition of extravascular acid mucopolysaccharide-alkaline protein complex. Secondary precipitation of calcium and iron in the gel may be the high density seen on CT.<sup>11 12</sup>

The pathogenesis of basal ganglia calcification in Down's syndrome is unknown. According to Wisniewski *et al*<sup>4</sup> postmortem-detected basal ganglia calcification is more frequent in the youngest and oldest Down's syndrome subjects. They suggested that in youthful Down's syndrome subjects it may be secondary to cerebral ischaemia which may be due to congenital heart disease; Ieshima and colleagues also speculated that it may be related to vascular insufficiency in the globus pallidus or an undetected metabolic disorder (unpublished observations).

We found basal ganglia calcification was localised to a constant area of globus pallidus, calcification was increasingly severe with ageing and calcification and amyloid degeneration of the adjacent blood vessels were present. This angiopathy was found not only in calcified arteries of old subjects, but also in uncalcified arteries of some young subjects. Three cases showed cerebral amyloid angiopathy, which might be another example of premature ageing. Our findings suggest that progressive structural change occurs in vessel walls with advancing age. Moreover, GFAP stains showed reactive astrogliosis localised to the areas of calcification, which may be secondary to focal circulatory disturbance due to the angiopathy. No difference in the incidence of basal ganglia calcification between patients with and those without congenital heart disease was seen, suggesting that focal lesions associated with the angiopathy may occur because of a vascular structural abnormality such as a vascular permeability disturbance rather than by systemic hypoxic-ischaemic events.

This paper was prepared with the assistance of the Medical Publications Department, The Hospital for Sick Children.

## References

- <sup>1</sup> Murofushi K. Symmetrischer Pseudokalk in Stammganglien und Grosshirnmark mit diskreter Leukencephalopathie bei Down'schem Syndrom. *Neuropaediatrie* 1974;5:103-8.
- <sup>2</sup> Jakab I. Basal ganglia calcification and psychosis in mongolism. *Eur Neurol* 1978;17:300-14.
- <sup>3</sup> Merikangas JR, Marasco JAJ, Feczka WA. Basal ganglia calcification in Down's syndrome. *Comput Tomogr* 1979;3:111-13.
- <sup>4</sup> Wisniewski KE, French JH, Rosen JF, Kozlowski PB, Tenner M, Wisniewski HM. Basal ganglia calcification (BGC) in Down's syndrome (DS)—another manifestation of premature aging. *Ann New York Acad Sci* 1982;396:179-89.
- <sup>5</sup> Barr ML, Kiernan JA. *The Human Nervous System: an Anatomical Viewpoint*. 4th edition, Philadelphia: Harper & Row, 1983.
- <sup>6</sup> Murphy MJ. Clinical correlations of CT scan-detected calcifications of the basal ganglia. *Ann Neurol* 1979;6:507-11.
- <sup>7</sup> Slager UT, Wagner JA. The incidence, composition, and pathological significance of intracerebral vascular deposits in the basal ganglia. *J Neuropath Exp Neurol* 1956;15:417-31.
- <sup>8</sup> Koller WC, Cochran JW, Klawans HL. Calcification of the basal ganglia: computerized tomography and clinical correlation. *Neurology (Minneapolis)* 1979;29:328-33.
- <sup>9</sup> Brannan TS, Burger AA, Chaudhary MY. Bilateral basal ganglia calcifications visualised on CT scan. *J Neurol Neurosurg Psychiatry* 1980;43:403-6.
- <sup>10</sup> Cohen CR, Duchesneau PM, Weinstein MA. Calcification of the basal ganglia as visualized by computed tomography. *Radiology* 1980;134:97-9.
- <sup>11</sup> Adachi M, Wellman KF, Volk BW. Histochemical studies on the pathogenesis of idiopathic non-arteriosclerotic cerebral calcification. *J Neuropath Exp Neurol* 1968;27:483-99.
- <sup>12</sup> Löwenthal A, Bruyn GW. Calcification of the striopallidodentate system. In Vinken PJ, Bruyn GW, eds. *Handbook of clinical neurology*, vol. 6, Amsterdam: North-Holland Publishing Co, 1968:703-29.