



Adjuvant atezolizumab-bevacizumab after curative therapy for hepatocellular carcinoma

Masatoshi Kudo

Department of Gastroenterology and Hepatology, Kindai University Faculty of Medicine, Osaka-Sayama, Japan

Correspondence to: Masatoshi Kudo, MD, PhD. Department of Gastroenterology and Hepatology, Kindai University Faculty of Medicine, 337-2 Ohno-Higashi, Osaka-Sayama, Osaka 589-8511, Japan. Email: m-kudo@med.kindai.ac.jp.

Keywords: Hepatocellular carcinoma; atezolizumab plus bevacizumab; adjuvant therapy; resection; ablation

Submitted Apr 19, 2023. Accepted for publication May 10, 2023. Published online May 22, 2023.

doi: 10.21037/hbsn-23-203

View this article at: <https://dx.doi.org/10.21037/hbsn-23-203>

Hepatectomy and radiofrequency ablation (RFA) are established curative methods for hepatocellular carcinoma (HCC). However, the recurrence rate of HCC is high even in patients who undergo these curative therapies, with HCC recurrence observed in approximately 80% of patients five years after curative therapy with RFA or resection (1). Pathological studies have identified microscopic intrahepatic metastases of a single lesion measuring <2 cm after resection of HCC in approximately 10% of patients and microvascular invasion in approximately 27% of cases (2), highlighting the risk of intrahepatic metastatic recurrence even for single small HCCs measuring <2 cm. For HCCs ≥ 2 cm, the risk of intrahepatic metastasis and microvascular invasion increases with tumor size and number, concurrently increasing the risk of intrahepatic metastatic recurrence (3).

Suppression of HCC recurrence after curative therapy could dramatically improve the prognosis of this disease. However, although numerous clinical trials have evaluated adjuvant therapies to suppress recurrence, all have concluded with negative results (4-6).

The results of the IMbrave050 trial presented at the American Association for Cancer Research (AACR) on April 16, 2023 are the first positive results from an adjuvant trial and represent a groundbreaking achievement (7).

Figure 1 shows the IMbrave050 trial design. The patients in the IMbrave050 trial had undergone curative resection or ablation of primary HCC. Complete resection or ablation was documented by imaging, and the patients had ECOG performance status (PS) 0 or 1, Child-Pugh

class A hepatic functional reserve, and a high risk of recurrence. Patients with extrahepatic metastasis or major macrovascular invasion (MVI) (Vp3 or Vp4) were excluded. The participants were randomized 1:1 to undergo active surveillance or to receive atezolizumab (1,200 mg once every 3 weeks) plus bevacizumab (15 mg/mL once every 3 weeks) starting 4 to 12 weeks after curative therapy and continuing for 12 months. The atezo/bev therapy was continued until recurrence or serious toxicity occurred, and the subsequent outcome was tracked. Patients in the control arm were permitted to cross over to atezo/bev therapy after recurrence. The primary endpoint of this RCT in this population was recurrence-free survival (RFS), which was determined by an independent review facility (IRF), and the secondary endpoints were RFS determined by an investigator (INV) (RESICT version 1.1), time to recurrence (TTR) determined by an IRF, overall survival (OS), and safety.

A total of 668 patients were enrolled, including 334 each in the atezo/bev and control arms. In the atezo/bev arm, the median patient age was approximately 60 years; 83% of the patients were men, 83% were Asians, and 71% were from the Asia-Pacific region excluding Japan. PS was 0 in 77% of the patients and 1 in 23%; 63% of the patients were positive for hepatitis B, 10% were positive for hepatitis C, and 14% were non-viral; and 86% showed Barcelona Clinic Liver Cancer (BCLC) stage A disease. In this patient population, 88% underwent resection and 12% ablation. In the resection group, the longest tumor diameter was 5.3 cm; 91% had a single tumor and 7% had two tumors; 52% had a tumor

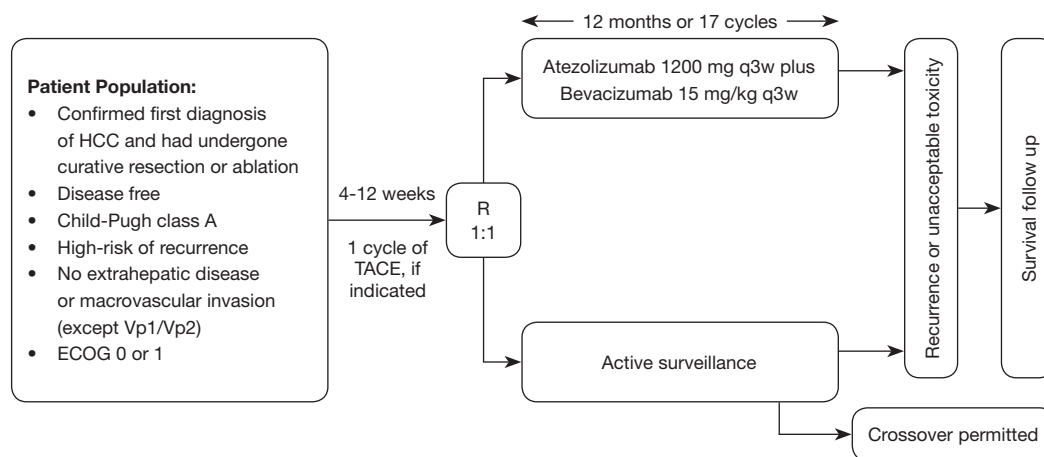


Figure 1 IMbrave050 study design. HCC, hepatocellular carcinoma; ECOG, Eastern Cooperative Oncology Group; TACE, transarterial chemoembolization.

Table 1 IMbrave050 efficacy outcome

Item	Atezo + bev (m=334)	Active surveillance (n=334)
Primary endpoint: IRF-assessed RFS		
Patients with events, n (%)	110 (32.9)	133 (39.8)
Median RFS, months (95% CI)	NE (22.1, NE)	NE (21.4, NE)
HR (95% CI)		0.72 (0.56, 0.93)
P value		0.012
Secondary endpoint: INV-assessed RFS results		
HR (95% CI)		0.70 (0.54, 0.91)
P value		0.007
Secondary endpoint: IRF-assessed time to recurrence		
HR (95% CI)		0.67 (0.52, 0.88)
P value		0.003

IRF, independent review facility; RFS, recurrence-free survival; CI, confidence interval; HR, hazard ratio; INV, investigator; NE, not estimable.

measuring ≥ 5 cm; 61% showed microvascular invasion and 8% showed minor MVI (Vp1/Vp2); and 42% showed poorly differentiated HCC (grade 3 or 4). In the ablation group, the median longest tumor diameter was 2.5 cm, and all the patients had ≤ 3 tumors (71% had single tumors). In this patient population, the HR for IRF-assessed RFS, the primary endpoint, was 0.72 [95% confidence interval (CI): 0.56–0.93, $P=0.012$], an extremely good result (Table 1). This is a groundbreaking result from the first-ever study to demonstrate the efficacy of adjuvant therapy for HCC. The HR of 0.70 for INV-assessed RFS (95% CI: 0.54–0.91, $P=0.007$) was very similar to the HR for IRF-assessed RFS

(Table 1). The IRF-assessed TTR in the atezo/bev arm was also superior to that in the control arm, with an HR of 0.67 (95% CI: 0.52–0.88, $P=0.003$; Table 1). Subgroup analyses results almost favored the atezo/bev arm. The HRs for the resection group ($n=585$) and the ablation group ($n=83$) were particularly notable, since the HR for RFS in the ablation arm was 0.61 (95% CI: 0.26–1.41), which was better than the HR for RFS of 0.75 (95% CI: 0.58–0.98) among high-risk patients who underwent resection; almost all patients in the ablation arm were actually at a high risk of recurrence despite the somewhat looser recurrence risk criteria in this arm (including patients at intermediate risk of recurrence)

Table 2 IMbrave050 safety summary

Events	Atezo + bev (n=332)	Active surveillance (n=330)
Treatment duration, median, months	Atezo: 11.1, Bev: 11.0	NA
Treatment AE (%)	88.3	NA
Grade 3/4 AE (%)	41.0	13.3
Serious AE (%)	24.1	10.3
Grade 5 AE (%)	1.8	0.3
AE leading to dose interruption of any study treatment (%)	46.7	NA
AE leading to withdrawal from any study treatment (%)	19.0	NA

AE, adverse event, NA, not applicable.

than those for resection. Patients with tumor size ≥ 5 cm and more than one tumor had a better HR for RFS than those with smaller and fewer tumors, and the HR remained good even in patients with MVI or poorly differentiated tumors, which was a somewhat unexpected result. In conclusion, the results showed that in terms of RFS, recurrence was well suppressed by atezo/bev in patients showing a high or a relatively low risk of recurrence. An analysis of the HR for RFS by BCLC stage showed that atezo/bev was effective at all stages, but that this was particularly true at stage B (HR =0.44, 95% CI: 0.18–1.48). In the resection group, patients with one high-risk feature and those with two or more high-risk features had similar HRs (HR, 0.74 *vs.* 0.77).

In the safety summary, treatment-related adverse events occurred in 88% of the patients in the atezo/bev arm (Grade 3/4 events in 35%), and only 9% of the adverse events necessitated treatment discontinuation, a relatively low rate (Table 2). Thus, the efficacy and safety results of the IMbrav050 trial are extremely good and provide the first-ever demonstration of the efficacy of atezo/bev as recurrence-suppressing therapy following curative therapy by resection or ablation (7).

A tumor antigen-specific immune reaction is known to be induced by local therapy with radiofrequency or microwaves or by other therapies such as resection (8). Ablation, in particular, causes the release of tumor-related antigens presented on antigen-presenting cells and the activation of tumor antigen-recognizing CD8-positive cells, which reach microsatellite lesions and other cancer locations and attack the cancer. The administration of PD-1/PD-L1 antibodies to cut off antigenic escape via the PD-1/PD-L1 axis at this time can induce necrosis of residual microsatellite lesions in the liver, forming the basis for suppression of recurrence by immune checkpoint inhibitors (ICIs). This is a reasonable

rationale for a previous finding showing that treatment of advanced liver cancer by ICI administration after ablation or TACE of only some HCC nodules induces CD8⁺ T cell infiltration in other nodules that did not undergo locoregional treatment, resulting in tumor regression (8).

Currently, there are many ongoing adjuvant trials of ICI monotherapy or combination therapy. Two phase III trials of ICI monotherapy are currently underway: the CheckMate 9DX trial using nivolumab and the KEYNOTE-937 trial using pembrolizumab. At the ASCO-GI 2022, the results of a single-arm Phase II trial using nivolumab, have been presented (9). In that study, an assessment of biomarkers restricted to patients who underwent resection found that copy number gains of the Wnt/ β -catenin-related genes and immunohistostaining findings showing abnormal β -catenin activation, low PD-L1 expression, few tumor-infiltrating CD8-positive cells, and FOXP3 staining positivity [increased intratumoral regulatory T cells (Tregs)] were significantly associated with the risk of recurrence (9,10). Even in patients who have undergone resection for small HCCs, if the main HCC nodule has a suppressive tumor microenvironment or carries genetic mutations that confer resistance to immune monotherapy (CTNNB1 mutations) (11), then tiny intrahepatic metastases (microsatellites) will have a similar tumor microenvironment and genetic mutations, indicating the limitations of ICI monotherapy (9).

Previous studies of the association between HCC recurrence after curative therapy and tumor immune factors have shown that immunocompetent cells, particularly CD8-positive and natural killer T cells, and IFN- γ infiltration inhibit recurrence, whereas infiltration by immunosuppressive cells such as Tregs and myeloid-derived suppressor cells is associated with increased recurrence and poor prognosis, and the expression of the checkpoint

molecule PD-L1 is similarly associated with post-resection recurrence (12).

The higher recurrence rate for tumors infiltrated by Tregs also indicated that the microsatellite lesions of resected or ablated primary tumors had a similar inhibitory immune microenvironment as advanced HCC, potentially limiting the effectiveness of ICI monotherapy. The NIVOLVE trial also demonstrated that activation of the WNT/ β -catenin signaling pathway may result in the loss of effectiveness of ICIs as a result of the suppression of intratumoral infiltration by CD8-positive T cells, precluding the suppression of recurrence (9-15).

In a trial of adjuvant therapy after curative therapy, the addition of an anti-VEGF antibody was considered to suppress recurrence at a higher rate than ICI monotherapy, as demonstrated in the Phase III IMbrave050 trial. In adjuvant trials, RFS is the primary endpoint such that even ICI monotherapy may well succeed in clinical trials in comparison with placebo.

Acknowledgments

Funding: None.

Footnote

Provenance and Peer Review: This article was commissioned by the editorial office, *Hepatobiliary Surgery and Nutrition*. The article did not undergo external peer review.

Conflicts of Interest: The author has completed the ICMJE uniform disclosure form (available at <https://hbsn.amegroups.com/article/view/10.21037/hbsn-23-203/coif>). The author reports consulting fees from Chugai, Roshe, Eisai, and AstraZeneca, honoraria from Chugai, Eisai, Eli Lilly, and Takeda, and research funding from Otsuka, Taiho, Chugai, GE Healthcare, Eisai, AbbVie, and EA Pharma. The author has no other conflicts of interest to declare.

Ethical Statement: The author is accountable for all aspects of the work in ensuring that questions related to the accuracy or integrity of any part of the work are appropriately investigated and resolved.

Open Access Statement: This is an Open Access article distributed in accordance with the Creative Commons Attribution-NonCommercial-NoDerivs 4.0 International License (CC BY-NC-ND 4.0), which permits the non-

commercial replication and distribution of the article with the strict proviso that no changes or edits are made and the original work is properly cited (including links to both the formal publication through the relevant DOI and the license). See: <https://creativecommons.org/licenses/by-nc-nd/4.0/>.

References

1. Imamura H, Matsuyama Y, Tanaka E, et al. Risk factors contributing to early and late phase intrahepatic recurrence of hepatocellular carcinoma after hepatectomy. *J Hepatol* 2003;38:200-7.
2. Nakashima O, Sugihara S, Kage M, et al. Pathomorphologic characteristics of small hepatocellular carcinoma: a special reference to small hepatocellular carcinoma with indistinct margins. *Hepatology* 1995;22:101-5.
3. Kudo M, Izumi N, Kokudo N, et al. Report of the 22nd nationwide follow-up Survey of Primary Liver Cancer in Japan (2012-2013). *Hepatol Res* 2022;52:5-66.
4. Yoshida H, Shiratori Y, Kudo M, et al. Effect of vitamin K2 on the recurrence of hepatocellular carcinoma. *Hepatology* 2011;54:532-40.
5. Okita K, Izumi N, Matsui O, et al. Peretinoin after curative therapy of hepatitis C-related hepatocellular carcinoma: a randomized double-blind placebo-controlled study. *J Gastroenterol* 2015;50:191-202.
6. Bruix J, Takayama T, Mazzaferro V, et al. Adjuvant sorafenib for hepatocellular carcinoma after resection or ablation (STORM): a phase 3, randomised, double-blind, placebo-controlled trial. *Lancet Oncol* 2015;16:1344-54.
7. Chow P, Chen M, Cheng AL, et al. IMbrave050: Phase 3 study of adjuvant atezolizumab + bevacizumab versus active surveillance in patients with hepatocellular carcinoma (HCC) at high risk of disease recurrence following resection or ablation. *AACR Annual Meeting 2023*, April 14-19, 2023, abstr #CT003.
8. Duffy AG, Ulahannan SV, Makorova-Rusher O, et al. Tremelimumab in combination with ablation in patients with advanced hepatocellular carcinoma. *J Hepatol* 2017;66:545-51.
9. Kudo M, Ueshima K, Nakahira S, et al. Adjuvant nivolumab for hepatocellular carcinoma (HCC) after surgical resection (SR) or radiofrequency ablation (RFA) (NIVOLVE): A phase 2 prospective multicenter single-arm trial and exploratory biomarker analysis 2021. *ASCO Annual Meeting*, 2021, Abstr 4070.

10. Kudo M. Adjuvant Immunotherapy after Curative Treatment for Hepatocellular Carcinoma. *Liver Cancer* 2021;10:399-403.
11. Morita M, Nishida N, Sakai K, et al. Immunological Microenvironment Predicts the Survival of the Patients with Hepatocellular Carcinoma Treated with Anti-PD-1 Antibody. *Liver Cancer* 2021;10:380-93.
12. Hack SP, Spahn J, Chen M, et al. IMbrave 050: a Phase III trial of atezolizumab plus bevacizumab in high-risk hepatocellular carcinoma after curative resection or ablation. *Future Oncol* 2020;16:975-89.
13. Sia D, Jiao Y, Martinez-Quetglas I, et al. Identification of an Immune-specific Class of Hepatocellular Carcinoma, Based on Molecular Features. *Gastroenterology* 2017;153:812-26.
14. Lee M, Ryoo BY, Hsu CH, et al. Randomised efficacy and safety results for atezolizumab (Atezo) + bevacizumab (Bev) in patients (pts) with previously untreated, unresectable hepatocellular carcinoma (HCC). *Ann Oncol* 2019;30:v875.
15. Finn RS, Qin S, Ikeda M, et al. Atezolizumab plus Bevacizumab in Unresectable Hepatocellular Carcinoma. *N Engl J Med* 2020;382:1894-905.

Cite this article as: Kudo M. Adjuvant atezolizumab-bevacizumab after curative therapy for hepatocellular carcinoma. *HepatoBiliary Surg Nutr* 2023;12(3):435-439. doi: 10.21037/hbsn-23-203