

Rhino-orbital zygomycosis

CJK ELLIS, SE DANIEL,* PG KENNEDY, SM OPPENHEIMER, F SCARAVILLI*

From The National Hospital and Department of Neuropathology, Institute of Neurology, Queen Square, London, UK*

SUMMARY A 63-year-old diabetic man presented with sinusitis with orbital and intracranial signs progressing over one week, due to zygomycosis. Despite control of the diabetes, surgical excision of infected tissue and antifungal therapy he died in the fifth week of illness. Pathological study showed extensive fungal infiltration of periorbital structures and mycotic thrombosis of many blood vessels with associated necrosis and infarction of fat and extraocular muscles.

The term zygomycosis is used to describe infections by the fungi of the order *Mucorales* that includes *Mucor*, *Absidia* and *Rhizopus*.¹ These fungi cause opportunistic infection in man that may be localised to the primary site of entry (including the nasal sinuses,^{2,3} lungs,⁴ gut⁵ and skin⁶) or widely disseminated.⁴ Zygomycosis most commonly occurs in patients with underlying disease and only rarely in otherwise normal patients.¹ Diabetes mellitus with ketoacidosis is the most common predisposing illness,⁷ but cases have been described in association with immunosuppressant therapy,⁸ leukaemia,⁴ lymphoma,⁴ burns,⁹ glomerulonephritis and gastroenteritis.¹

The clinical features of rhino-orbital zygomycosis reflect the tendency for infection to arise in the paranasal sinuses or palate, spread to the ipsilateral orbit and thence to the retro-orbital⁹ and intracranial compartments.¹⁰ The diagnosis is confirmed by the demonstration of broad, predominantly non-septate, irregularly branching fungal hyphae in biopsy material from sites of infection.¹ Untreated this disease may be rapidly fatal and mortality rates of 90% have been reported.¹¹ In recent years, however, management based on radical surgical excision of infected, necrotic tissue, control of underlying disease, and anti-fungal therapy with amphotericin-B has improved the prognosis.³

The majority of cases of rhino-orbital zygomycosis reported have occurred in North America, and few patients are described in the neurological literature. The acute orbital signs with

evidence of intracranial involvement may however result in early neurological referral. We report the clinical and pathological features of a diabetic with rhino-orbital zygomycosis, intracranial extension and meningitis. There was also mycobacterial cervical lymphadenitis.

Case history

The patient, an Indian man aged 63 years who had lived in England since 1972, had a previous history of diabetes mellitus well controlled on chlorpropamide and monitored by daily urine testing. He was otherwise well until one week prior to admission when he began to complain of increasing pain around his left eye and in the left cheek. This was diagnosed as sinusitis and he was treated with ampicillin. However, the pain continued to get worse and was exacerbated by chewing. On the fifth day of his illness he noticed that the left eyelid began to droop and the following day sudden blindness developed in his left eye. He was admitted to another hospital and transferred to the National Hospital on the seventh day of his illness.

On admission he was alert, not dehydrated or clinically acidotic. He was generally wasted and his speech was slurred. There was marked oedema of the left periorbital tissues and the conjunctivae of the left eye were injected and oedematous. There was 5 mm of left axial proptosis with tense resistance to retropulsion of the globe. The left side of the hard palate showed black discoloration with a sharp midline delineation. No nasal discharge was seen but there was black material in the nose. There was tenderness over the left maxilla. The visual acuity was 6/36 on the right, and there was no perception of light in the left eye. There were bilateral cataracts. The visual field of the right eye was full to an 8 mm white target. The right optic disc was normal, and the left pale with a large soft exudate adjacent to the temporal margin of the disc. The maculae were normal and there was no evidence of diabetic retinopathy. The right pupil was normal, the left mid-dilated and fixed to light stimulation. There was total external ophthalmoplegia in the left eye, movements of the right being normal.

Address for reprint requests: Dr CJK Ellis, Poole General Hospital, Poole, Dorset BH15 2JB, UK.

Received 6 July 1984 and in revised form 27 September 1984.
Accepted 27 September 1984

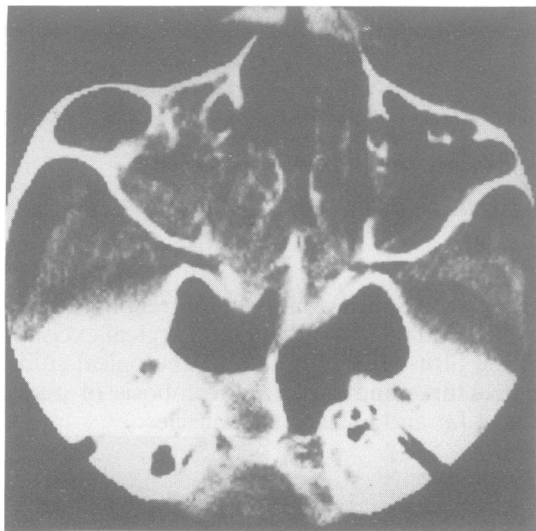


Fig 1 Enhanced CT scan showing soft tissue within the left antrum, erosion of the medial border of the antrum and soft tissue extending medially into the nasal cavity.

The left corneal reflex was absent and there was impaired superficial sensation in all divisions of the left trigeminal nerve. There was a left lower motor neuron facial weakness. The cranial nerves were otherwise normal. Examination of the limbs showed no weakness or sensory deficit but the tendon reflexes were absent and the plantar responses flexor. General examination was normal.

Investigations on admission showed a neutrophil leucocytosis of $13,000 \times 10^9/l$ with left shift and toxic granulation. The ESR was 122 mm/h and the blood glucose 14.3 mmol/l. Serum albumin 26 g/l. Protein electrophoresis showed an increase in alpha 2 globulin and serum immunoglobulins were all normal. Liver function tests, electrolytes and urea were normal. Blood cultures were negative, swabs from the nose and palate showed no growth. There was no ketonuria. Chest radiograph was normal and skull radiographs showed opacification of the left maxillary sinus. Computed tomographic (CT) head scan showed no abnormality but orbital CT scan showed erosion of the medial wall of the left maxillary antrum with soft tissue extending into the nasopharynx (fig 1). Further investigation showed cerebrospinal fluid (CSF) protein of 0.33 g/l with 168 white cells (57% polymorphs, 36% lymphocytes) with CSF glucose of 3.3 mmol/l (blood glucose 8.4 mmol/l). No organisms or fungi were seen or subsequently cultured from the CSF. Immunoelectrophoresis showed frank transudation of all serum proteins across a damaged blood-CSF barrier. Serum antibodies to *Mucor* (1:1), *Rhizopus* (1:1) and *Absidia* (1:16) were detected using an immunoprecipitation assay but no antibodies were detected in the CSF.

The clinical diagnosis of rhino-orbital zygomycosis was made on admission and confirmed by biopsy; on the eighth day of his illness biopsies of the palatal and nasal mucosae were taken and showed characteristic fungal hyphae with

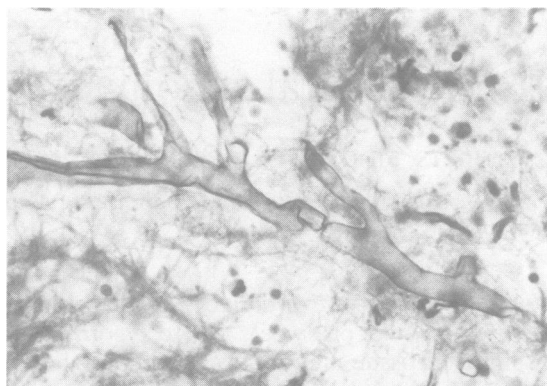


Fig 2 Branching fungal hyphae (haematoxylin-eosin $\times 77$).

acute inflammatory changes. A Caldwell-Luc operation was performed (Mr H Ludman) and the antral mucosa was found to be oedematous with no frank necrosis. Biopsy of antral mucosa showed infiltration by broad non-septate hyphae. The patient was treated with intravenous amphotericin-B 50 mg daily and intrathecally 0.2 mg twice weekly. On the eleventh day of his illness a left orbital exenteration with maxillectomy and removal of hard palate was performed (Mr A Cheesman, Mr J Wright).

His diabetes became more difficult to control and he developed atrial fibrillation. His neurological condition remained stable with no evidence of extension of his deficit over the next three weeks. In the fifth week of illness he developed a *Proteus mirabilis* septicaemia secondary to urinary tract infection and died.

Pathology

Necropsy was performed 36 hours after death; septicaemia from a urinary tract infection was considered the immediate cause of death; general examination revealed a diffused spleen, haemorrhagic cystitis and cervical lymphadenopathy. At the site of the left orbital exenteration and within the frontal and maxillary sinuses and oropharynx there was brown necrotic material. In the nervous system the leptomeninges were thickened and slightly opaque. The brain weighed 1115 g and showed no macroscopic abnormality. The spinal cord was normal. Histological examination of the cervical lymph nodes showed caseating granulomas and Langhans' type giant cells containing acid-fast bacilli. The epithelium of the soft palate, pharynx and paranasal sinuses was focally replaced by a fibrinopurulent exudate and underlying severe inflammation with numerous non-septate irregularly branching fungal hyphae measuring 6–25 μm in diameter. The hyphae were basophilic with haematoxylin-eosin stain and typical of the *Mucorales* (fig 2). Many of the fungal tubes were collapsed and irregular, presumably no longer viable. The inflammatory response comprised abundant multinucleate giant cells, some containing phagocytosed fungal hyphae, macrophages and microabscesses with polymorphonuclear leucocytes and occasional eosinophils. The right and left periorbital structures were widely infiltrated by numerous fungal hyphae and surrounding

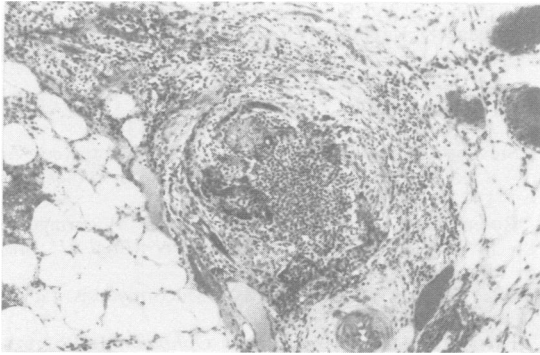


Fig 3 Mixed purulent and granulomatous inflammation with multi-nucleate giant cells in the peri-orbital adipose tissue (haematoxylin-eosin $\times 12$).

mixed purulent and granulomatous inflammation (fig 3). Many arteries and veins of varying size were occluded by mycotic thrombi and fungal hyphae extended through vessel walls into the adventitia and surrounding tissues (fig 4). There was associated fat necrosis and ischaemic infarction of orbital muscles. The intra-orbital nerves showed epineurial granulomatous inflammation with fungal hyphae, which focally breached the epineurium and perineurium. The base of the skull including the sphenoid, temporal and basilar part of the occipital bone showed widespread bilateral fungal infection of bony trabeculae and marrow spaces. In the middle cranial fossa the left trigeminal nerve was infiltrated with fungal hyphae which did not extend to involve the sensory ganglion. The left cavernous sinus was occluded by fungal hyphae and a mixed granulomatous and acute inflammatory cell infiltrate which also surrounded the intracavernous course of the cranial nerves. The right and left internal carotid arteries were patent, fungal hyphae invaded the adventitia and media, but did not extend to involve the intima. The brain showed a diffuse acute-on-chronic leptomeningitis. There were two foci of recent infarction in the left frontal lobe and in these areas small vessels were occluded by throm-

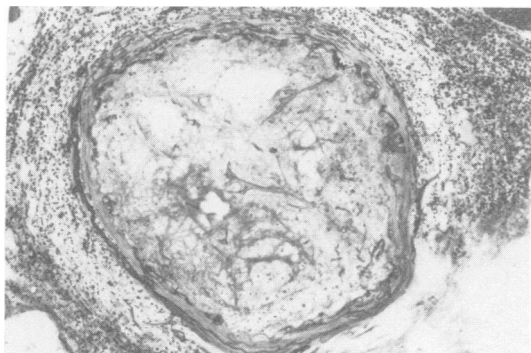


Fig 4 Orbital vein occluded by mycotic thrombus. Hyphae extend through the vessel wall (haematoxylin-eosin $\times 12$).

boemboli. No fungal hyphae were demonstrated in the leptomeninges or brain parenchyma.

Discussion

The clinical features of this case are typical of rhino-orbital zygomycosis and illustrate the rapid progression from nasal sinuses and palate to the ipsilateral orbit and intracranial compartment.^{9 10 12 13 18} The tendency for this fungus to invade and occlude blood vessels^{2 7} is well illustrated both clinically and pathologically in this case. The necrosis of the palatal mucosa with a sharp midline demarcation is thought to be due to occlusion of the sphenopalatine artery¹³ and the sudden monocular visual loss to occlusion of the central retinal artery.¹¹ Intracranial extension is common and in our patient was indicated by involvement of all divisions of the left trigeminal nerve and the facial weakness. The abnormal CSF though non-specific, also suggested intracranial infection but is not always a reliable indicator as cases with intracranial disease have been found to have normal CSF.^{1 20} Other reported intracranial complications in this disease include seizures,¹⁴ intracranial haemorrhage¹⁵ and occlusion of the intracavernous internal carotid artery.¹⁷

The orbital signs of proptosis, chemosis and external ophthalmoplegia associated with sinusitis often result in the diagnosis of pyogenic cavernous sinus thrombosis resulting in inappropriate antibiotic therapy. However, the clinically unilateral involvement, early visual loss and pupillary involvement are atypical features of pyogenic cavernous sinus thrombosis, in which extension to bilateral involvement with preservation of vision and pupillary reactions until a late stage are characteristic.¹⁶ Without treatment the disease usually runs a rapidly fatal course,¹¹ but correction of underlying disease, amphotericin-B and radical surgical excision of all necrotic, infected material have improved the prognosis. Survival rates of between 44%¹⁹ and 85%³ have been reported recently in treated patients.

The presence of intracranial extension before treatment is clearly an adverse prognostic factor. Review of reports of treated patients^{3 14 21} suggests that intracranial disease is associated with a worse prognosis. In one series of 13 cases³ the only two fatalities and two of the 11 survivors had evidence of intracranial extension. Due to the toxicity of amphotericin-B and the implications of radical facio-orbital surgery, the clinical diagnosis should be confirmed on biopsy material from sites of nasopharyngeal infection.

Pathologically there was far more widespread and bilateral disease than suggested by clinical assess-

ment. The histological appearances illustrate that rhino-orbital zygomycosis with intracranial extension may be characterised by a predominantly granulomatous response when survival is relatively prolonged. Previous reports^{7 21} emphasise the acute inflammatory nature of this disease in contrast to chronic cutaneous zygomycosis where the inflammation is frequency granulomatous in nature.²⁰

The occurrence of rhino-orbital zygomycosis almost always in association with diabetes mellitus¹¹ indicates that it should be considered in any diabetic who develops sinusitis with black nasal discharge or orbital signs. This case illustrates that ketoacidosis need not be present nor the diabetes poorly controlled.

The mycobacterial lymphadenitis, which was an unexpected post mortem finding, may have increased this patient's susceptibility to opportunistic infection.

We thank Professor WI McDonald for permission to report his patient and Professor D Mackenzie and Dr RJ Hay, Mycology Reference Laboratory, School of Tropical Medicine and Hygiene, for the serology studies.

References

- ¹ Lehrer RI, Howard DH, Sypherd PS, Edwards JE, Segal GP, Winston DJ. Mucormycosis. *Ann Int Med* 1980;**93**:93-108.
- ² Gregory JE, Golden A, Haymaker W. Cerebral Mucormycosis. *Bull Johns Hopkins Hosp* 1943;**73**:405-15.
- ³ Pillsbury HC, Fischer ND. Rhinocerebral Mucormycosis. *Arch Otolaryngol* 1977;**103**:600-4.
- ⁴ Meyer RD, Rosen P, Armstrong D. Phycomycosis complicating leukaemia and lymphoma. *Ann Int Med* 1972;**77**:871-9.
- ⁵ Khan LB. Gastric Mucormycosis. *S Afr Med J* 1963;**37**:1265-9.
- ⁶ Meyer RD, Kaplan MH, Ong M, Armstrong D. Cutaneous lesions in disseminated mucormycosis. *JAMA* 1973;**225**:737-8.
- ⁷ Straatsma BR, Zimmerman LE, Gass JDM. Phycomycosis. *Lab Invest* 1962;**11**:963-85.
- ⁸ Stevens KM, Newell RC, Bergstrom L. Mucormycosis in a patient receiving azathioprine. *Arch Otolaryngol* 1972;**96**:250-1.
- ⁹ Rabin ER, Lundberg CD, Mitchell GT. Mucormycosis in severely burned patients. *N Engl J Med* 1961;**264**:1286-9.
- ¹⁰ Eisenberg L, Wood T, Boles R. Mucormycosis. *Laryngoscope* 1977;**87**:347-56.
- ¹¹ Ferry AP. Mucormycosis. *Surv Ophthalmol* 1961;**6**:1-24.
- ¹² Case Record 38-1982. Mucormycosis. *N Engl J Med* 1982;**307**:806-14.
- ¹³ Tabachnick TT, Levine B. Mucormycosis of the craniofacial structures. *J Oral Surg* 1975;**33**:464-9.
- ¹⁴ Abramson E, Wilson D, Arky RA. Rhinocerebral phycomycosis in association with diabetes mellitus. *Ann Int Med* 1967;**66**:735-42.
- ¹⁵ Khang-Loon H. Acute subdural haematoma and intracerebral haemorrhage. *Arch Otolaryngol* 1979;**105**:279-81.
- ¹⁶ Clifford-Jones RE, Ellis CJK, Stevens J, Turner AM. Cavernous sinus thrombosis. *J Neurol Neurosurg Psychiatry* 1982;**45**:1092-7.
- ¹⁷ Lowe JT, Hudson WR. Rhinocerebral phycomycosis and internal carotid artery thrombosis. *Arch Otolaryngol* 1975;**101**:100-3.
- ¹⁸ Smith HW, Kirschner JA. Cerebral mucormycosis. *Arch Otolaryngol* 1958;**68**:715-26.
- ¹⁹ Meyers BR, Wormster G, Hirschman SZ, Blitzewr A. Rhinocerebral mucormycosis. *Arch Int Med* 1979;**139**:557-60.
- ²⁰ Lie Kian Joe, Njo-Injo Tjoeieng, Pohan A, Van der Meulen H. Basidiobolus ranarum as a cause of subcutaneous mycosis in Indonesia. *Arch Dermatol* 1956;**74**:378-83.
- ²¹ Neame P, Rayner D. Mucormycosis. A report on 22 cases. *Arch Pathol* 1960;**70**:261-8.