

The rigid spine syndrome—a myopathy of uncertain nosological position

W POEWE,* H WILLEIT,* E SLUGA,† U MAYR*

From the University Clinic for Neurology, Innsbruck, and the Neurological Institute of the University of Vienna, Vienna,† Austria*

SUMMARY Four patients meeting the clinical criteria of the rigid spine syndrome are presented; they are one girl with a positive family history and three boys. Clinical and histological findings are discussed in relation to the 14 cases of rigid spine syndrome reported in the literature. The delineations of the syndrome from other benign myopathies with early contractures are discussed suggesting that the rigid spine syndrome probably does not represent a single nosological entity.

In 1965 Dubowitz¹ drew attention to a muscular disorder resembling muscular dystrophy at the time of its onset in infancy but of benign and non progressive nature with the development of only mild weakness. The central clinical feature in this condition is marked limitation of flexion of the cervical and dorsolumbar spine with the development of scoliosis and associated contractures of other joints, particularly limited extension of the elbows. The condition was accordingly termed the rigid spine syndrome by Dubowitz. Following Dubowitz's description of four patients²⁻⁵ ten further cases have been reported in the literature.⁶⁻¹⁴ Apart from their common predominant clinical symptom of limited movement of the spine and other joints the reported cases show rather heterogeneous clinical and histologic features. Some authors have therefore questioned the nosological entity of the rigid spine syndrome and have suggested a relationship to some x-linked myopathies of benign course with associated contractures of the spine and other joints, particularly to the Emery-Dreifuss muscular dystrophy.^{12,14-16}

In view of these uncertainties and the rarity of the condition a report on another four cases of rigid spine syndrome with a discussion on the delineation of the syndrome seems justified.

Address for reprint requests: Dr W Poewe, University Clinic for Neurology, Anichstraße 35, A-6020 Innsbruck, Austria.

This paper is dedicated to Prof Dr Franz Gerstenbrand on the occasion of his 60th birthday.

Received 28 September 1984 and in revised form 5 December 1984.

Accepted 15 December 1984

Case reports

Since 1978 the authors have had the opportunity to examine clinically, electrophysiologically and by muscle biopsy four cases of a muscle disorder fulfilling the clinical criteria of rigid spine syndrome as described by Dubowitz.¹⁻⁵ The patients were three males and one female, whose sister is thought to suffer from the same disorder.

Patient 1: male, aged 21 yr

The family history was negative concerning neuromuscular disorders. The patient's birth and infantile development had reportedly been normal. At the age of 6 years he started to walk on his toes and his parents noticed slight scoliosis of the thoracolumbar spine together with a limitation of flexion of his trunk and neck. At the age of 16 years a tenotomy of the tendo Achilles was performed because of progressive bilateral pes equinus. Thoracolumbar scoliosis did not show progression nor was there any subjective muscle weakness. After the age 17 the patient complained of failure to develop a stronger muscle profile in his upper and lower extremities despite his attempts at body building procedures. At the time of his first neurologic examination the patient was aged 18 yr. The muscles of the shoulder girdle and the calves were slightly atrophic with mild to moderate pareses (power MRC 3 to 4) of the deltoid, biceps and tibialis anterior muscles. His gait was normal. There was moderate thoracolumbar scoliosis, with a hyperextended posture of his neck with limitation of flexion of the cervical and thoracolumbar spine (fig 1). He had 20° flexion contractures at his elbows. Deep tendon reflexes were generally diminished, and the rest of his neurological status was normal. CK serum levels were increased to 560 U/l (upper limit 80 U/l), serum levels of the other muscle enzymes (GOT, GPT, LDH, aldolase) were within normal limits as were all other laboratory findings. ECG and chest radiographs were normal. The electromyogram of the deltoid and biceps muscles showed

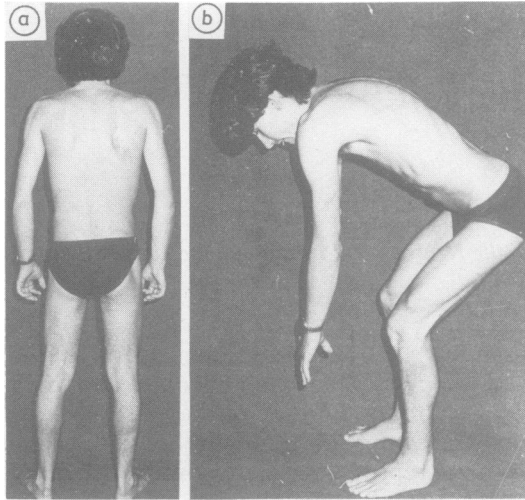


Fig 1 Patient 1, male, aged 18 yr. (a) posterior view; slight atrophy of shoulder girdle and calf-muscles is evident, together with slight thoraco-lumbar scoliosis and flexion contractures of elbows. (b) marked limitation of flexion of cervical and thoraco-lumbar spine.

moderate myopathic changes as did the myogram of the erector trunci with some "feeling of fibrosis" upon needle insertion. Conduction velocities of the median and peroneal nerves were within normal limits. Biopsy of the right biceps brachii muscle showed pathologic variation in fibre size with disseminated atrophies and degeneration of fibres, numerous central nuclei and marked increase of endomyseal and interstitial connective tissue (fig 2). Upon ATPase and NADH staining there was a normal mosaic structure without selective atrophy of one type of fibres. During a follow up of 3 years the patient's disorder has not been progressive except for subjective worsening of the hyperextended head posture, so that a surgical lengthening procedure of the neck extensors has been attempted upon the patient's request.

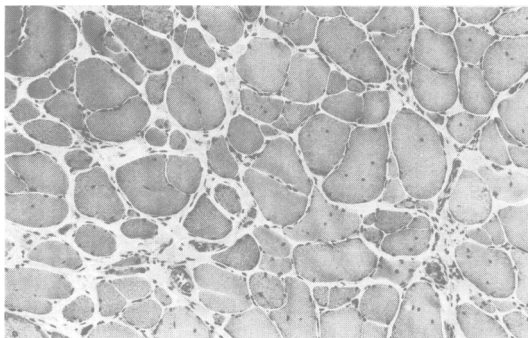


Fig 2 Light microscope view of biopsy specimen from the right biceps brachii muscle of patient 1 (HE stain; 6.3×16). Note variation in fibre size, numerous central nuclei and proliferation in fibrous tissue.

Patient 2, male, aged 14 yr

The family history and patient's birth were unremarkable. During the first years of life the parents had the impression of the child having difficulties in bending his head forward. From his 6th year the patient developed bilateral pes equinus, scoliosis and slightly progressive weakness of his arms and legs. There was no muscle pain. Upon neurological examination at age 14 the patient was ambulatory with a normal gait. He showed marked kyphoscoliosis with an extension contracture of his neck, 60° flexion contractures of both elbows and bilateral pes equinus (fig 3). His musculature was diffusely atrophic, there was mild winging of the scapulae and moderate weakness (power MRC 3) of the muscles of the shoulder girdle but no paresis of the pelvic girdle and lower extremities. Deep tendon reflexes were diminished throughout, the remaining neurological findings were normal. Serum CK level was 107 U/l and all other laboratory findings were normal as were the ECG and chest radiographs. The myograms of the deltoid, first dorsal interosseus, rectus femoris and tibialis anterior muscles all showed marked myopathic changes, conduction velocities of median and peroneal nerves were normal. Biopsy of the right biceps brachii revealed a marked decrease in muscle fibre density due to interstitial fibrosis (fig 4), variation in fibre size with disseminated fibre atrophies and central nuclei. There were no inflammatory

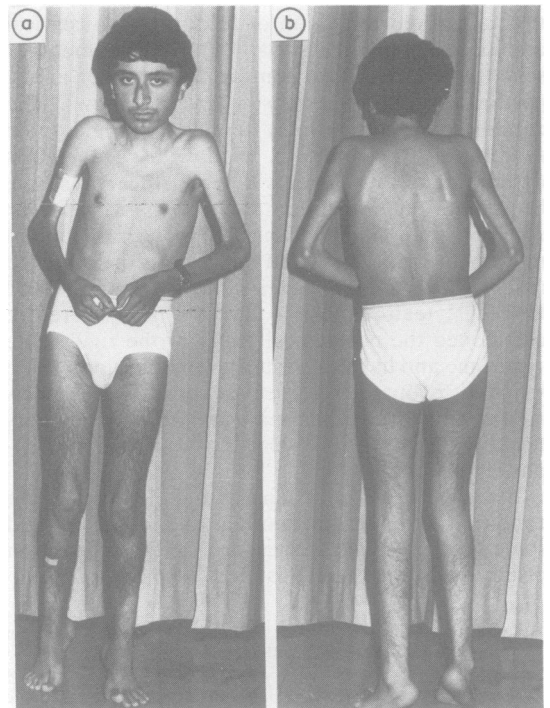

Fig 3 Patient 2, male, aged 14 yr. (a) anterior aspect; note flexion contractures of elbows and bilateral pes equinus; diffuse muscle atrophies present. (b) posterior aspect with slight winging of the scapulae.

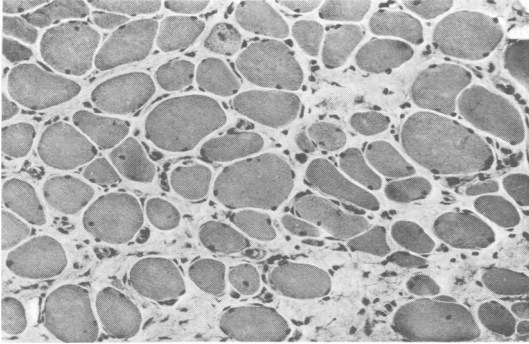


Fig 4 Light microscope view of biopsy specimen from biceps brachii muscle of patient 2. (HE stain; 6.3×16). Marked interstitial fibrosis as well as variation in fibre size, central nuclei are evident.

changes and no signs of glycogen or lipid storage. Upon ATPase and NADH staining no predominance or selective atrophy of one fibre type was evident.

Patient 3, female, aged 11 yr

The patient's mother is suffering from moderate scoliosis of the thoracolumbar spine, the patient's younger sister is reportedly suffering from a similar condition as the patient herself. When the patient was about 7 months old the

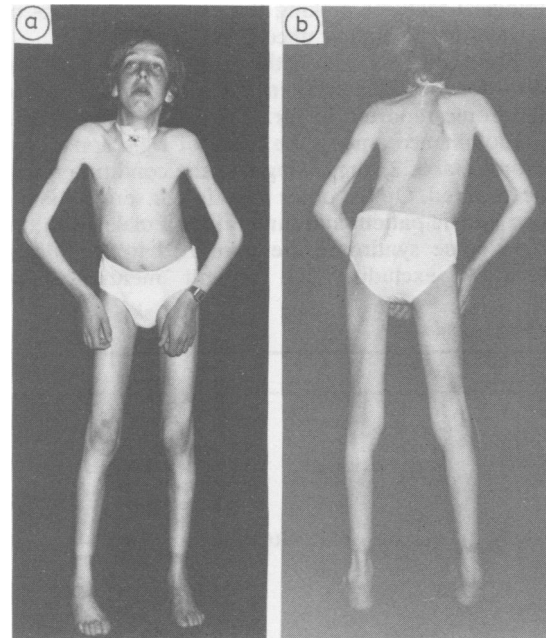


Fig 5 Patient 4, male, aged 19 yr. (a) anterior view showing diffuse muscular atrophy and marked flexion contractures of both elbows. Patient has a tracheal cannula because of respiratory insufficiency. (b) posterior aspect showing marked scoliosis.

parents noticed her inability to flex her head forward when being pulled into a seating position or when lying on her back. From her 4th year the patient developed progressive scoliosis and slight proximal weakness of her neck and lower extremities. Upon examination at age 11 yr the patient was ambulatory with a slightly waddling gait. She exhibited discrete facies myopathica, severe scoliosis and a marked extension contracture of her neck and thoracolumbar spine. There was slight atrophy of her shoulder girdle muscles with associated mild weakness (power MRC 4) while in the pelvic girdle and lower extremities no atrophy or weakness were present. Deep tendon jerks were absent throughout; the remaining neurological findings were normal. Serum CK levels and all other laboratory findings were normal. ECG showed signs of hypertrophy of the right ventricle; pulmonary function tests revealed a marked restrictive disturbance of ventilation. The myogram of the right deltoid muscle revealed only minor changes suggestive of a myopathy, conduction velocity studies were all within normal limits. Biopsy of the left deltoid muscle showed moderate variation in fibre size with only few atrophic fibres, and fibres with central nuclei,

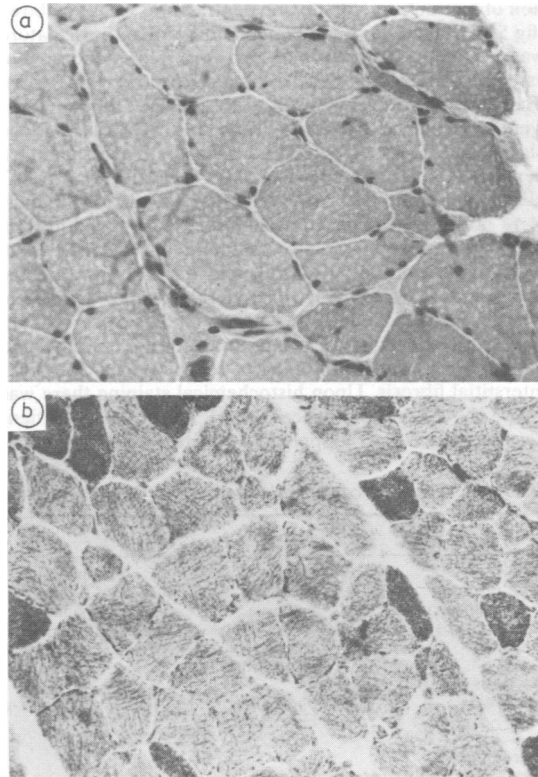


Fig 6 Muscle biopsy of right biceps brachii of patient 4. (a) light microscopic view (HE stain; 6.3×25) showing only slight myopathic changes with occasional central nuclei variation in fibre size and minimal increase in interstitial fibrous tissue. (b) NADH stain showing type II fibre predominance.

but no interstitial fibrosis. During the following two years the patient developed progressive respiratory failure with recurrent pneumonias and died from heart failure secondary to pulmonary hypertension at age 13. Necropsy was not performed.

Patient 4, male, aged 21 yr

Family history, birth and infantile development had reportedly been normal. The patient walked at the age of 14 months. At age 4 yr he started having difficulties in rising up from the floor after a fall. At age 6 the mother noticed that he had very thin muscles; 2 years later a lengthening operation of the left Achilles tendon had to be performed because of pes equinus. Six years later the same procedure became necessary on the right. A certain stiffness of the patient's neck had first been noticed by his mother at age 6, scoliosis developed after his tenth year, when he was seen by an orthopedist who suspected him to have Duchenne's muscular dystrophy. The patient was first seen by the authors when he was aged 17 yr. At this time he was freely ambulatory with a waddling gait. There was marked scoliosis of his thoracolumbar spine, severe limitation of flexion and to a lesser extent of rotation and lateral inclination of his neck and 30° flexion contractures of both elbows (fig 5). His face was slightly myopathic and his musculature was diffusely atrophic with proximal accentuation and associated moderate pareses of muscle power (MRC 3). There was slight winging of the scapulae, tendon jerks were markedly diminished. There were no fasciculations visible and no other associated neurologic abnormalities. Serum CK-level was raised to 180 U/l, LDH-level to 507 U/l (upper limit 240 U/l); all other laboratory findings were normal. ECG was normal, pulmonary function tests revealed a marked restrictive ventilation disturbance. Electromyograms of biceps brachii, rectus femoris and tibialis anterior muscles all showed moderate degree myopathic changes, nerve conduction velocity studies were normal. Biopsy of the right M biceps brachii (fig 6a) revealed pathologic variation in fibre size, central nuclei and slight interstitial fibrosis. Upon histochemical staining there was a type II fibre predominance (fig 6b). At age 19 the patient became increasingly dyspnoeic, and a tracheostomy had to

be performed. In the same year a right bundle branch block was first noted in his ECG and he had an episode of asystolia while being hospitalised for a left-sided pneumonia, but could be resuscitated successfully. During the following two years his respiratory insufficiency progressed steadily and he developed further cardiac conduction abnormalities with a nodal rhythm being intermittently present in his ECG. At age 21 he died from right-sided heart failure. Necropsy revealed moderate fibrosis of proximal muscles and there was also diffuse fibrosis of the diaphragm. The heart showed right ventricular hypertrophy and dilatation, but there was no unequivocal evidence of primary heart disease. There were no abnormalities of the brain, spinal cord or peripheral nerves.

Discussion

The four cases presented all showed a myopathic syndrome with mild associated weakness, marked limitation of flexion of the spine, especially in its cervical portion, and accompanying contractures of other joints as well as scoliosis. Onset was in early childhood with only minor progression of weakness (table 1). The cases thus meet the clinical criteria of the rigid spine syndrome as defined by Dubowitz.¹⁻⁵ Despite the common clinical findings in cases of the rigid spine syndrome reported in the literature so far there are some variable clinical, genetic and histological features making the exact delineations of the syndrome appear uncertain.

The findings regarding the possible genetics of this disorder are conflicting in the cases of rigid spine syndrome reported so far. There is a striking male predominance among the cases of rigid spine syndrome (table 2) suggesting that the condition might be x-linked. On the other hand in our series there is one female patient and three other females with the rigid spine syndrome are described in the literature¹⁰⁻¹³ excluding the patient mentioned by

Table 1 *Synopsis of clinical data of present four cases of rigid spine syndrome*

Patient	1	2	3	4
Sex	male	male	female	male
Age of onset	6 yr	2-3 yr	7 months	4 yr
Family history	negative	negative	positive	negative
Contractures	Spine extensors, Elbow flexors, Pes equinus	Spine extensors, Elbow flexors, Pes equinus	Spine extensors	Spine extensors, Elbow flexors, Pes equinus
Scoliosis	+	+	+++	+++
Weakness	Shoulder-girdle Foot extensors (MRC 3-4)	Shoulder-girdle (MRC 3)	Shoulder-girdle (MRC 4)	diffuse (MRC 3-4)
Cardiopathy	-	-	+	+
Restrictive Ventilatory disturbance	-	-	+	+
CK Level (N 80 U/l)	560 U/l	107 U/l	45 U/l	180 U/l
EMG	myopathic	myopathic	myopathic	myopathic
Biopsy	myopathic	myopathic	myopathic	myopathic
Fibrosis	++	++	-	(+)
Fibre type predominance	-	-	-	Type II
Progression	minor	minor	died age 13	died age 21

Dubowitz⁴ but not described further. The fact that the majority of the reported cases have had no family history at all strongly argues against the syndrome being a hereditary condition. In the present series, however, is a female patient (case 3) whose younger sister is said to suffer from an identical disorder. Similarly, Serratrice *et al*¹⁴ reported a 14-year-old boy with the rigid spine syndrome whose older brother had bilateral pes equinus, moderately increased serum CK levels and slight myopathic changes in the muscle biopsy specimen. Accordingly, this and the author's observation suggest that the rigid spine syndrome may have familial occurrence. Along this line Mussini *et al*¹² have proposed that the rigid spine syndrome might be an autosomal recessive disorder with variable penetrance and probably some sex-linkage of expression.

Further arguments for a possible heredity of the rigid spine syndrome can be drawn from the fact that there is a close resemblance of major clinical symptoms to those of some benign myopathies with recessive x-linked inheritance. Rotthauwe *et al*¹⁵ have described a large Bavarian family with an x-linked myopathic disorder with early contractures of the spine and the elbows with only mild progression of weakness and associated cardiopathy, which was often fatal in their cases owing to conduction defects. Their condition is probably identical to Emery-Dreifuss muscular dystrophy,^{16,17} an x-linked recessive disorder under which the rigid spine syndrome cases have occasionally been subsumed as sporadic variants without cardiopathy.¹⁸ There is, however, some evidence in the literature that cardiopathy might be an associated feature of the rigid spine syndrome, with abnormalities of cardiac rhythm having been repeatedly described.^{11,12,14} Colver *et al*¹³ have reported a case with fatal hypertrophic cardiomyopathy. In case 3 of this series there was right ventricular hypertrophy and death occurred from right-sided heart failure, but the cardiac changes most likely were secondary to pulmonary hypertension following the severe restrictive ventilatory disturbance in this patient. The same may apply to the cardiac problems encountered in case 4 of this group, and necropsy did indeed fail to demonstrate unequivocal evidence of a primary cardiopathy. Some clinical aspects of this patient's cardiac disorder, however, must be regarded as unusual for a cardiopathy merely secondary to pulmonary hypertension. They include both the reported episode of asystole 3 years before the patient's death as well as the intermittent presence of a nodal rhythm in his ECG thereafter. The possible presence of a primary cardiopathy on which secondary changes due to pulmonary hypertension were superimposed can, therefore, not be ruled out in this

Table 2 Frequency of occurrence of clinical findings in 18 cases of rigid spine syndrome reported in the literature (including the present four cases)

Clinical characteristics	Number of cases of rigid spine syndrome (N = 18) (present series: N = 4; literature: N = 14)
Sex	
Male	14
Female	4
Family History	2
Contractures	18
Spine	18
Elbow	14
Ankle	7
Knee	4
Hip	2
Scoliosis	14
Weakness	14
Cardiopathy	5
Restrictive ventilation disturbance	5
Increased CK	14
Myopathic EMG	15
Myopathic Biopsy	18
Fibrosis	12
Type I predominance	4
Died (7½ to 23 yr)	5

case.

Taking into account the possible occurrence of familial cases as well as of cardiomyopathy in the rigid spine syndrome its exact delineations from the Emery-Dreifuss muscular dystrophy as well as from other myopathies with cardiopathy and autosomal dominant inheritance like the one reported by Fenichel *et al*¹⁹ become difficult to define.

There is also no distinct histological pattern in the muscle biopsy specimens of the reported rigid spine syndrome cases and the histological findings show considerable heterogeneity and unspecificity. Dubowitz has suggested interstitial fibrosis to be a characteristic finding in muscle biopsies of rigid spine syndrome patients.¹⁻⁴ This has been partially confirmed in the cases of in the literature (table 2; refs 7-10) and interstitial fibrosis was also present in the muscle biopsy of patients 1 and 2 of this report (table 2). However, the two other patients of this series did not show significant interstitial fibrosis in their muscle biopsies nor did several cases in the literature.^{6,12,13,14} Interstitial muscular fibrosis in the rigid spine syndrome is probably dependent on the stage of disease and site of muscle biopsy, as is also documented by the findings in case 4 of this report in whom biopsy of the biceps revealed only minor fibrotic changes as opposed to the findings in the diaphragm at necropsy.

Several reports have claimed the rigid spine syndrome to be a type I fibre myopathy because of type I fibre predominance and atrophy in the muscle biopsies of rigid spine syndrome patients.^{6,7,10,12} In the present series of four patients histochemical

staining did not show selective atrophy of one fibre type in three cases (table 1). The same has also been reported for several cases in the literature.^{4,9,8,14} Case 4 in this series exhibited predominance of type II fibres with atrophy of some type I fibres (fig 6b) similar to the patient reported by Colver *et al.*¹³ Type I fibre predominance and atrophy thus does not appear to be specific for the rigid spine syndrome.

The rigid spine syndrome is generally viewed as a benign disorder with little or no progression apart from scoliosis.¹⁻¹⁰ From the present series, however, the grave prognostic implications of progressive scoliosis, restrictive ventilatory insufficiency and right-sided heart failure must be underlined. Two of our patients died from right-sided heart failure at age 13 and 21 yr respectively. They had developed a severe restrictive ventilatory disorder and pulmonary hypertension. The kyphoscoliosis present in both of them was considered an important pathogenetic factor in the development of ventilatory failure. It was not possible from the lung function tests employed (measurement of vital capacity and forced expiratory volume to assess separately the role that respiratory muscle weakness played in the evolution of respiratory insufficiency in these patients. That it may have been a major contributing factor is, however, suggested by the finding of fibrotic changes in the diaphragm of case 4 at necropsy.

Ventilatory insufficiency as a complication of the rigid spine syndrome should be recognised at the earliest possible stage by regular assessments of vital capacity and forced expiratory volume to allow for early precautions to be taken against rapid progression of ventilatory failure, including physiotherapy of respiratory muscles, prophylaxis of aspiration and pneumonia, avoidance of the use of sedatives and tranquillisers and also the intermittent application of mechanical ventilatory support. Whether this can influence the long-term prognosis of the rigid spine syndrome remains to be seen. An unfavourable prognosis of the rigid spine syndrome is also determined by the presence of primary cardiopathy, which was the cause of death in the patient of Colver *et al.*¹³ and probably a contributing factor to the heart failure of case 4 in this series. The rigid spine syndrome, thus, cannot be viewed as a principally benign condition with a normal life expectancy.

Despite the major symptoms of the rigid spine syndrome being well defined its exact nosological position remains uncertain. In view of the existence of sporadic as well as familial cases with an overall male predominance the mode of a possible genetic transmission of the syndrome can at present not be defined. Clinical findings, especially the degree and distribution of associated weakness and the presence

or absence of cardiopathy, seem to vary considerably in the reported cases, as do the histological findings upon muscle biopsy. Altogether it seems questionable whether the rigid spine syndrome as presented in this series and in the reports of the literature represents a single nosological entity.

References

- Dubowitz V. Pseudo-muscular dystrophy. In: *Research in Muscular Dystrophy. Proceedings of the Third Symposium. Research Committee of the Muscular Dystrophy Group of Great Britain*. London, Pitman Medical, 1965.
- Dubowitz V. Some unusual neuromuscular disorders. In: Walton JN, Canal N, Scarlato G, eds. *Muscle Diseases. Proceedings of an International Congress. Milan, 1969*. Amsterdam, Excerpta Medica, 1970:568-73.
- Dubowitz V. Recent advances in neuromuscular disorders. *Rheumatol Physic Med* 1971;II:126.
- Dubowitz V, *Muscle Disorders in Childhood*. London, Saunders, 1978.
- Dubowitz V, Brooke MH. Muscle Biopsy: a modern approach. In: *Major problems in Neurology*, Vol. 2, London, Saunders, 1973:368-70.
- Seay AR, Siter FA, Petajan JH. Rigid spine syndrome: a type I fiber myopathy. *Arch Neurol* 1977;34:119-22.
- Goebel HH, Lenard HG, Görke W, Kunze K. Fiber type disproportion in the rigid spine syndrome. *Neuropadiatrie*, 1977;8:467-77.
- Goto I, Nagasaka S, Nagara H, Kuroiwa Y. Rigid Spine Syndrome. *J Neurol Neurosurg Psychiatry* 1979;42:276-9.
- Goto I, Muraoka S, Fujii N, Ohta M, Kuroiwa Y. Rigid Spine Syndrome: Clinical and histological problems. *J Neurol* 1981;226:143-8.
- Vogel P, Goebel HH, Seitz D. Rigid Spine Syndrome in a girl. *J Neurol* 1982;228:259-65.
- Mussini JM, Gray F, Hauw JJ, Piette AM, Prost A. Rigid spine syndrome. Histological examination of male and female cases. *Acta Neuropathol (Berl.)*, 1981, **Suppl. VII**:331-3.
- Mussini JM, Mathé JF, Prost A, Gray F, Labat JJ, Féve JR. Le syndrome de la colome vertebrale raide. Un cas féminin. *Rev Neurol (Paris)* 1982;138:1, 25-37.
- Colver AF, Steer CR, Godman MJ, Uttley WS. Rigid Spine Syndrome and fatal cardiomyopathy. *Arch Dis Child* 1981;56:148-51.
- Serratrice G, Pellissier JF, Pouget J, Gastaut JL. Le syndrome de la colome vertebrale rigide et ses frontières neurologiques. *Presse Med* 1984;13:1129-32.
- Rotthauwe HW, Mortier W, Beyer H. New type of recessive x-linked muscular dystrophy: scapulo-humeral-distal muscular dystrophy with early contractures and cardiac arrhythmias. *Humangenetik*, 1972;16:181-220.
- Emery AEH, Dreifuss FE. Unusual type of benign x-linked muscular dystrophy. *J Neurol Neurosurg Psychiatry* 1966;29:338-42.
- Hopkins LC, Jackson JA, Elsas LJ. Emery-Dreifuss

humero-peroneal muscular dystrophy: An x-linked myopathy with unusual contractures and bradycardia. *Ann Neurol* 1981;**10**:230–7.

¹⁸ Rowland L-P, Fetell M, Olarte M, Hays A, Singh N, Wanat FE. Emery-Dreifuss muscular dystrophy. *Ann*

Neurol 1979:111–7.

¹⁹ Fenichel GM, Yi Chul Sul, Kilroy AW, Blouin R. An autosomal-dominant dystrophy with humero-pelvic distribution and cardiomyopathy. *Neurology (NY)* 1982;**32**:1399–401.