

Short report

Pachymeningitis cranialis hypertrophica

AP MOORE,* EB ROLFE,† EL JONES‡

From Glasgow University Department of Neurology, Institute of Neurological Sciences, Southern General Hospital, Glasgow, Queen Elizabeth Hospital, Edgbaston, Birmingham† and The Medical School, Birmingham,‡ UK*

SUMMARY A case of pachymeningitis cranialis hypertrophica is described and the CT appearances are presented. The likely cause was syphilis, though sarcoidosis and tuberculosis were not completely excluded.

Late syphilis is recognised as a cause of pachymeningitis spinalis hypertrophica and the pathology is described in the older literature. Modern reports are few, usually of the localised form, and have not included CT appearances. Our patient had extensive involvement which we have called pachymeningitis cranialis hypertrophica, but had surprisingly little clinical abnormality.

Case history

In 1965 the patient presented, aged 48 years, with a 3 month history of severe headache, vomiting, vertigo and ataxia. He had been deaf in the right ear for 20 years, with ipsilateral tinnitus for 4 years. At that time the fundi and pupillary responses were normal, but there was nystagmus on lateral gaze. There was bilateral perceptive deafness worse on the right. The left limbs were ataxic, and his gait unsteady with a positive Romberg's test. Blood count, ESR, serum and CSF WR and Kahn, CSF pressure, protein and cell count, plain skull radiographs and vertebral angiography were normal. Audiometry confirmed perceptive deafness and caloric studies showed labyrinthine paresis worse on the right.

He improved spontaneously, but 2 months later his symptoms recurred with mild pyrexia. CSF protein was 0.9 g/l, with a paretic Lange curve (4422222100), normal sugar and cell count and negative cultures. Mantoux 1:10,000 was positive and liver biopsy normal. Ventriculography suggested a left frontal mass and left carotid angiography a parietal subdural haematoma. Central, frontal and parietal burr holes each revealed dura mater grossly thickened by granulation tissue, but no underlying fluid.

Histology of the dura mater showed dense fibrotic thick-

ening with a heavy cellular infiltrate of lymphocytes and plasma cells. Scattered areas of necrosis were present with a few polymorphs and multinucleated giant cells (fig 1). The small arteries showed a reactive endarteritis. No epithelioid granulomas were seen, and stains and culture for fungi, tubercle bacilli and spirochaetes were negative. The appearance was considered consistent with a diffuse gummatous inflammatory reaction of the dura mater, with no evidence of haemorrhage. On penicillin and streptomycin his pyrexia settled. His headache diminished when prednisolone 20 mg daily was given, and after 2 months he was off all treatment.

In 1969 his headache recurred, with perioral paraesthesiae. His ESR was 83 mm/h, WR and Kahn negative, but serum treponemal fluorescent antibody (FTA) and treponema pallidum immobilisation (TI) tests were positive. Bilateral carotid angiography showed poor filling of the superior sagittal sinus. EEG and technetium brain scan were normal. His headache again responded to prednisolone.

In 1974 he developed left trigeminal neuralgia, controlled at various times by courses of prednisolone or carbamazepine. In 1978 a non-contrast CT scan was considered normal, but in retrospect did suggest thickened dura mater.

Trigeminal neuralgia recurred in 1982. On examination he had mild pallor of both optic discs, with normal pupillary and external ocular movements apart from fine nystagmus on left lateral gaze. There was patchy numbness over the left cheek, a mild left lower motor neurone facial weakness, and deafness as before. The limbs and reflexes and Romberg's test were normal, but his gait slightly ataxic. Serum and CSF VDRL, TPHA, and FTA were normal. CSF protein was 0.65 g/l, IgG/albumen ratio 95% (normal 30%) with 1 monocyte and 1 lymphocyte/mm³ and no organisms. Culture was negative and cytology normal. CT scans with enhancement showed a markedly increased uptake strikingly displaying the falx and tentorium cerebelli (fig 2) and were compatible with the vas-

Address for reprint requests: Dr AP Moore, Institute of Neurological Sciences, Southern General Hospital, Glasgow G51 4TF, UK.

Received 28 December 1984. Accepted 9 February 1985

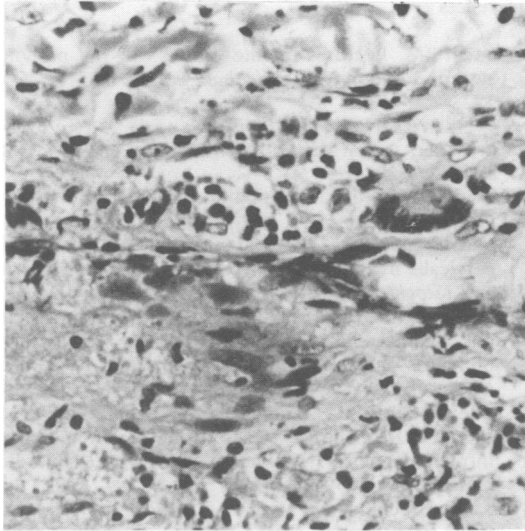


Fig 1 Thickened fibrotic dura showing an area of necrosis and a cellular infiltrate of lymphocytes, plasma cells and giant cells. (H & E. $\times 422$).

cular granulomatous process previously found involving the dura mater.

Discussion

In 1869 Charcot¹ described pachymeningitis spinalis hypertrophica, a diffuse granulomatous involvement of the cervical dura mater and occasionally other sites, usually caused by syphilis. Gowers² in 1893 described areas of localised thickening of dura mater, usually secondary to injury or adjacent disease. He divided them into purulent and haemorrhagic forms and considered syphilis, tuberculosis and possibly alcohol as common causes.

In 1940 Hassin and Zeitlin³ described a single case with involvement of the larger part of the cerebral dura mater and falx, extending to the tentorium, pons, medulla and upper spinal cord. The tentorium was 8 mm thick, dura mater over the cerebellum 2 to 4 mm, extending over the occipital and parietal lobes, gradually thinning in a cephalad direction. The optic chiasm and adjacent area including the cerebral peduncles, third nerves and blood vessels were normal. The pons was reduced to about one half normal size by compression and the medulla was also affected. Histology showed a similar granulomatous picture attributed to syphilis but spirochaetes were not found. As in our case there was no history of syphilis, the blood and CSF WR were negative and Lange curve paretic, although the CSF contained 89 lymphocytes/mm³.

Subsequent case reports are rare and generally

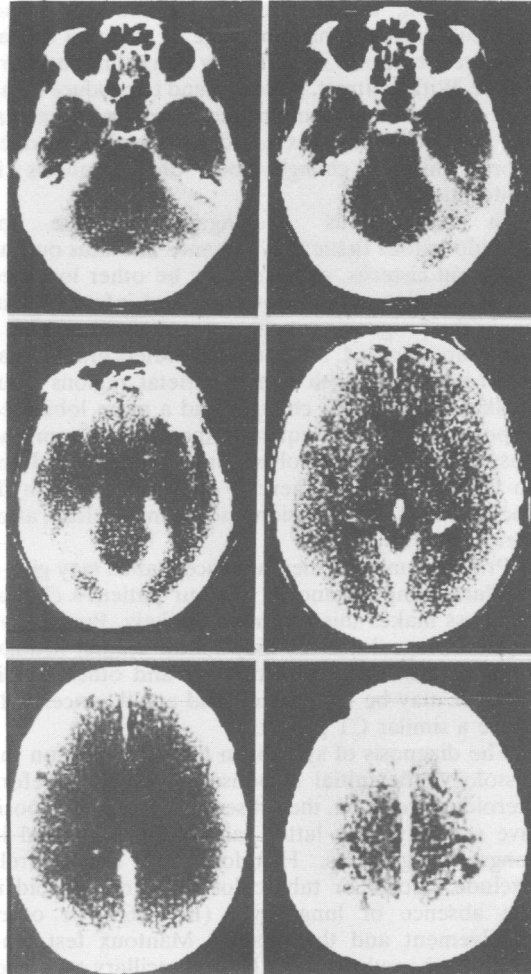


Fig 2 CT scan with contrast showing dural enhancement and hypertrophy particularly of the tentorium cerebelli and the falx.

only of the localised cervical form.⁴ Cranial pachymeningitis developed for unknown reasons in a dialysis patient⁵ in whom investigations for Wegener's granuloma were negative. Tuberculosis, sarcoid and cryptococcal meningitis may also cause hypertrophic pachymeningitis.⁶

CT changes occur in neurosyphilis:⁷ though mass lesions may regress after penicillin, infarction or diffuse cortical or cerebellar atrophy are non-specific. We could find no reports documenting generalised dural prominence as in this case.

The tentorium⁸ and the falx⁹ can be seen in 99% of normal enhanced CT scans though in only 4% of non-contrast pictures. Abnormality is thus a matter of judgement and experience of particular scanners.

Calcification, arteriovenous malformations, adjacent subarachnoid haemorrhage or cisternal dilatation creating pools of CSF may all outline the dura mater. With contrast, tumours tend to produce localised enhancement from thickening or hypervascularity. Diffuse metastases could conceivably produce more uniform changes but the prognosis is uniformly bad.¹⁰

In tuberculous meningitis, exudate or granulomatous tissue may enhance and thus outline the basal cisterns, or there may be other localised lesions, hydrocephalus, oedema and infarcts,¹¹ but again the prognosis is poor.

In sarcoidosis CT has demonstrated granulomas *en plaque* over both fronto-parietal regions¹² but unlike our case, the changes had a more lobulated appearance. More frequently the optic chiasm and basal meninges are involved, or granulomas coalesce to form a tumour. There is often associated hydrocephalus.¹³ The lesions sometimes clear after steroid therapy.

Primary amoebic meningoencephalitis may give a similar CT appearance,¹⁴ but our patient's clinical progress makes this diagnosis unlikely. Progressive leptomeningeal fibrosis may follow cranial irradiation, subarachnoid haemorrhage and other conditions or may be idiopathic¹⁵ and could conceivably cause a similar CT picture.

The diagnosis of syphilis in this case rests on the histology, the initial response to penicillin before steroids were given, the subsequent course and positive serology. The latter can return to normal in longstanding cases. Histology did not entirely exclude sarcoid or tuberculosis: against sarcoid is the absence of lung, liver (in 1965) or other involvement and the positive Mantoux test, and against tuberculosis is the lack of ancillary evidence, although the initial treatment did include streptomycin.

Syphilis is a notoriously indolent process which may not be halted by even extensive courses of antibiotics. Although syphilitic pachymeningitis is largely of historical interest, it and other unusual forms of syphilis can still occur, and are not excluded by normal serology. CT appearances of meningeal hypertrophy may be useful but biopsy may still be necessary to support the diagnosis.

References

- ¹ Charcot JM. Lectures on the diseases of the nervous system. London *New Sydenham Society* 1877;2:209-12.
- ² Gowers WR. *A Manual of Diseases of the Nervous System* 2nd ed. Hoffner-Davies. London: Churchill 1893;2:323-8.
- ³ Hassin GB, Zeitlin H. Syphilitic cerebral hypertrophic pachymeningitis. *Arch Neurol* 1940;43:362-71.
- ⁴ Agdal N, Hagdrup HK, Wartzin GL. Pachymeningitis cervicalis hypertrophica syphilitica. *Acta Derm Venereol (Stockholm)* 1980;60:184-6.
- ⁵ Ferringa ER, Wetherbee L. Hypertrophic granulomatous cranial pachymeningitis causing progressive blindness in a chronic dialysis patient. *J Neurol Neurosurg Psychiatry* 1975;38:1170-6.
- ⁶ Michel D, Girard P-F, Tommasi M, Masson R, Trillet M, Piccinali J-P. Les pachymeningites granulomateuses intracranienne a symptomatologie pseudo-tumorale. *J Med Lyon* 1969;50:545-77.
- ⁷ Godt P, Stoeppeler L, Wischer U, Schroeder HH. The value of computed tomography in cerebral syphilis. *Neuroradiology* 1979;18:197-200.
- ⁸ Naidich TP, Leeds NE, Kircheff II, Pudlowski RM, Naidich JB, Zimmerman RD. The tentorium in axial section. 1: Normal CT appearance and non-neoplastic pathology. *Radiology* 1977;123:631-8.
- ⁹ Osborne AG, Anderson RE, Douglas Wing S. The false falx sign. *Radiology* 1980;134:421-5.
- ¹⁰ Boyle R, Thomas M, Hume Adams J. Diffuse involvement of the leptomeninges by tumour—a clinical and pathological study of 63 cases. *Postgrad Med J* 1980;56:149-58.
- ¹¹ Bullock MRR, Welchman JM. Diagnostic and prognostic features of tuberculous meningitis on CT scanning. *J Neurol Neurosurg Psychiatry* 1982;45:1098-101.
- ¹² Moorhouse H, Danziger A. CT findings in intracranial neurosarcoid. *Computed Tomography* 1980;4(4):267-70.
- ¹³ Brooks BS, El Gammal T, Hungerford GD, Acker J, Trevor RP, Russell W. Radiologic evaluation of neurosarcoidosis: role of computed tomography. *Am J Neuroradiol* 1982;3(5):513-21.
- ¹⁴ Lam AH, de Silva M, Procopis P, Kan A. Primary amoebic (*Naegleria*) meningoencephalitis. *J Comput Assist Tomogr* 1982;6(3):620-3.
- ¹⁵ Chalif D, Duchon LW, Marshall J, Hayward R. Progressive leptomeningeal fibrosis: a clinico-pathological case report. *J Neurol Neurosurg Psychiatry* 1983;46:261-5.