










COVID-19-induced coagulopathy: Experience, achievements, prospects

Leonid Dubey¹, Olga Dorosh^{1, 2}, Nataliya Dubey¹, Svitlana Doan³,
Olena Kozishkurt⁴, Oleksandr Duzenko⁴, Olena Kozlova^{1, 2}, Veronika Ievtukh¹,
Jerzy R. Ladny^{5, 6}, Michal Pruc⁶, Lukasz Szarpak⁷, Julia Pukach¹

¹Danylo Halytsky Lviv National Medical University, Lviv, Ukraine

²ENT “Western Ukrainian Specialized Children’s Medical Center”, Lviv, Ukraine

³International European University, Kyiv, Ukraine

⁴National Medical University of Odessa, Ukraine

⁵Medical University of Bialystok, Poland

⁶Polish Society of Disaster Medicine, Warsaw, Poland

⁷Baylor College of Medicine, Houston, TX, United States

Abstract

The presence of coagulopathy as part of the systemic inflammatory response syndrome is a characteristic feature of severe coronavirus disease 2019 (COVID-19). Hematological changes (increased D-dimer [DD], prolonged activated partial thromboplastin clotting time [APTT] and prothrombin time [PT], high fibrinogen levels) have been observed in hospitalized patients with COVID-19, which characterize the risk of thrombotic events. Against the background of COVID-19 there is endothelial dysfunction, hypoxia and pulmonary congestion, mediated by thrombosis and microvascular occlusion. Up to 71.4% of patients who died from COVID-19 had disseminated intravascular coagulation syndrome, compared with only 0.6% of survivors. The main manifestation of COVID-19-associated coagulopathy is a significant increase in DD without a decrease in platelet count or prolongation of APTT and PT, indicating increased thrombin formation and the development of local fibrinolysis. An increase in DD levels of more than 3–4 times was associated with higher in-hospital mortality. Therefore, COVID-19 requires assessment of the severity of the disease for further tactics of thromboprophylaxis. The need for continued thromboprophylaxis, or therapeutic anticoagulation, in patients after inpatient treatment for two weeks using imaging techniques to assess of thrombosis assessment. (Cardiol J 2023; 30, 3: 453–461)

Key words: coronavirus disease 2019 (COVID-19) infection, COVID-19-induced coagulopathy, SARS-CoV-2

Introduction

Since 2019, the outbreak of the then new coronavirus disease 2019 (COVID-19), which first originated at Wuhan, located in the Chinese province of Hubei, has spread around the world, and on 11 March 2020, the World Health Organiza-

tion (WHO) announced the new COVID-19 as a pandemic [1, 2].

The number of confirmed cases and deaths from COVID-19 disease started to grow each day [3]. Mortality rates vary from country to country and depend on the capacity and effectiveness of the health care system. Since the beginning of

Address for correspondence: Lukasz Szarpak, Assoc. Prof., PhD, DPH, DBA, LL.D., Henry JN Taub Department of Emergency Medicine, Baylor College of Medicine, One Baylor Plaza – BCM285, Houston, TX 77030, United States, tel: +48500186225, e-mail: lukasz.szarpak@gmail.com

Received: 25.09.2022

Accepted: 9.10.2022

Early publication date: 29.12.2022

This article is available in open access under Creative Common Attribution-Non-Commercial-No Derivatives 4.0 International (CC BY-NC-ND 4.0) license, allowing to download articles and share them with others as long as they credit the authors and the publisher, but without permission to change them in any way or use them commercially.

the pandemic, Iran has been and is still considered a high-risk area with a much higher mortality rate than most cases in China [4–6].

The clinical spectrum of infection with the new severe acute respiratory syndrome coronavirus 2 (SARS-CoV-2) is different, ranging from the absence of any symptoms to lethal septic shock. 81% of all reported cases of COVID-19 by children and adults had a mild course of the disease, 14% — severe (eg, shortness of breath or oxygen saturation $\leq 93\%$) and 5% — critical condition (respiratory failure, septic shock, death) [7, 8].

The transition from mild to severe in patients with COVID-19 may be caused by cytokine storms and increased hypercoagulation with a significant risk of thromboembolic complications, affecting mainly venous, but are also registered in the arterial system [9–11].

The presence of comorbidities (cardiovascular, obesity, diabetes) that contribute to the development of coagulopathy, including those caused by sepsis, increased levels of D-dimer (DD), C-reactive protein (CRP), troponins and other markers of disseminated intravascular coagulation (DIC) in more than 6 times from the reference, is associated with a worse prognosis in hospitalized patients with severe coronavirus COVID-19, reaching 42% of in-hospital mortality [7].

A new term for COVID-induced coagulopathy (CIC) has been introduced to describe changes in blood clotting in patients with COVID-19 [12]. Characteristic laboratory data of CIC are observed, namely, elevated levels of DD and fibrin degradation products, which indicate an enhanced thrombotic state with high fibrin turnover. However, other CIC markers remain relatively unchanged.

Initial anticoagulant therapy, especially by direct injection, reduces mortality by 48% after 7 days and by 37% after 28 days and achieves a significant improvement in inhaled oxygen/ O_2 (PaO_2/FiO_2) by mitigating microthrombi and associated pulmonary coagulopathy [13].

Most protocols for the prevention of venous thromboembolism (VTE) with the use of therapeutic (full) doses of anticoagulants have been introduced in many countries [14–23], mainly for hospitalized adult patients. However, there are a limited number of publications on thromboprophylaxis in pediatric patients [23–26].

The present study offers a practical approach to CIC in patients with COVID-19, based on experience in the current literature and of our own experience in the treatment of patients hospitalized in local institutions.

Epidemiology

Since the outbreak of COVID-19 in December of 2019, which originated in the city of Wuhan, in the Chinese province of Hubei, this disease has spread around the world [7, 27]. On February 11, 2020, the International Coronavirus Taxonomy Study Group officially named the new coronavirus that causes COVID-19 “SARS-CoV-2”, and on March 11, 2020, the WHO announced a new COVID-19 pandemic [4–6, 8, 12, 14, 25, 28], which had its epicenter on the Asian continent (China), which later moved to the European (mainly to Italy and Spain), and then — to the Americas, first to the United States, and is now present in the United States and Latin America (Mexico and Brazil).

SARS-CoV-2 is a single-stranded RNA coronavirus that enters the cell mainly through binding to the type 2 angiotensin-converting enzyme (ACE-2) receptor, which is abundant in the alveolar clitoris, lungs, cardiac myocytes, vascular endothelium and other cells [29]. SARS-CoV-2 is transmitted mainly by inhalation of viral particles and entry into the respiratory tract. This virus can survive up to 24–72 hours on the surfaces of various objects indoors, which contributes to its spread [9, 19, 27, 30, 31].

Respiratory viral infection caused by COVID-19 is usually asymptomatic or with mild symptoms including fever, cough, fatigue, shortness of breath, diarrhea, headache and myalgia (up to 81.4% of patients). Severe cases are characterized by an increase in respiratory failure with a respiratory rate > 30 per minute, a decrease in saturation $< 93\%$ at rest, $PaO_2/FiO_2 < 300$ mmHg and infiltration $> 50\%$ of the lungs within 24–48 hours (up to 13.9% of patients) and may progress to the development of a critical condition (up to 4.7% of patients), demonstrating rapid deterioration and development of acute respiratory distress syndrome, septic shock, metabolic acidosis and coagulopathy, including cytokine storm [8, 12, 14–19, 32–36].

These clinical manifestations and paraclinical signs change with the further development of the pandemic worldwide, and also depend on the severity of the infection.

Coagulopathy

The most persistent hemostatic changes in COVID-19 are thrombocytopenia and increased DD [37], which are associated with the development of liver failure due to active inflammation in the lungs,

intestines, myocardium, resulting in frequent use of ventilation requiring intensive care. In some cases this disease leads to the death of patients. Elderly patients with comorbidities with higher levels of DD had a higher risk of nosocomial mortality [20–22]. Given the clinical consequences of elevated DD levels, even in the absence of other serious symptoms, inpatient treatment should be considered, as this indicates an increase in thrombin levels and a higher risk of COVID-induced complications.

Blood clotting profile studies should be performed in hospitalized patients with suspected or confirmed COVID-19, including DD, activated partial thromboplastin clotting time (APTT), prothrombin time (PT), platelet count (PLT), and fibrinogen levels (Fib). Changes in these parameters may occur 7–11 days after the onset of symptoms or 4–10 days after hospitalization. It is important to repeat the study of these indicators to detect coagulopathy (DD, APTT, PT, Fib, PLT) in patients with severe COVID-19 at least every 2–3 days [9, 21, 38–44].

The combination of thrombocytopenia, prolonged prolongation of APTT and PT, increased DD indicates the development of DIC, the manifestations of which differ from those observed in septic processes of other etiologies, where thrombocytopenia is more pronounced and does not reach DD values observed in COVID-19. Recent evidence suggests that COVID-19-associated coagulopathy is a combination of low-grade DIC and pulmonary thrombotic microangiopathy, which has a significant effect on organ dysfunction in patients with the most severe condition [20, 45].

The presence of coagulopathy as part of the systemic inflammatory response syndrome is a common sign of severe COVID-19. Importantly, hematological changes in coagulation tests (elevated DD-dimer, prolonged APTT and PT, thrombocytopenia, and/or low fibrinogen levels) were observed in hospitalized patients with COVID-19, characterizing thrombotic events rather than hemorrhagic events. That is, COVID discoagulopathy causes thrombotic complications, in particular, VTE). Against the background of CIC, and hence endothelial dysfunction, there is hypoxia and pulmonary congestion, mediated by thrombosis and microvascular occlusion (including cerebrovascular events, limb ischemia, etc.) [9, 16, 21, 23–25, 46].

In patients who died of COVID-19, fibrin and thrombin deposition occurred predominantly in the pulmonary microcirculatory tract, which contributed to the development of acute respiratory

distress syndrome and coagulopathy. In addition, hypoxia due to severe COVID-19 exacerbated thrombosis not only due to increased blood viscosity but also through a signaling pathway dependent on the transcription factor induced in the development of hypoxia [16, 23, 26, 47–52].

SARS-CoV-2 infection develops endothelial disease with profound microcirculatory changes, in which there is excessive thrombin formation and impaired fibrinolysis, similar to endothelial dysfunction in coagulopathy caused by sepsis (SIC). The receptor for viral adhesion is ACE-2 on endothelial cells, and virus replication causes inflammatory cell infiltration, endothelial apoptosis, and microvascular prothrombotic events. Viral inclusions in endothelial cells and infiltration by mononuclear and polymorphonuclear cells with evidence of endothelial apoptosis were observed in postmortem analysis of SARS-CoV-2 infection. Impaired microcirculation contributes to the development of severe clinical consequences in patients with COVID-19 [9, 16, 53, 54]. Other abnormalities that may be relevant in the context of coagulopathy are decreased fibrinogen levels, increased lactate dehydrogenase, and, in some patients, marked increases in serum ferritin levels [26, 55, 56].

Another important feature of COVID-19 infection is the development of an acute procoagulant response in elevated levels of FVIII, von Willebrand, and fibrinogen, which are associated with an increased risk of thrombosis. In severe stages of the disease there is an increase in inflammatory cytokines (tumor necrosis factor [FNO- α] and interleukins [IL]: 1 and 6). IL-6 induces the expression of tissue factor in macrophages, which initiates the activation of coagulation and thrombin formation [32]. FNO- α and IL-1 are major mediators of endogenous coagulation inhibition. Severely compromised patients with COVID-19 may experience a cytokine storm characterized by high concentrations of proinflammatory cytokines and chemokines [18, 20, 32].

The International Society for Thrombosis and Hemostasis (ISTH) has proposed a new category for the detection of early-stage DIC associated with sepsis, called SIC. This indicator can be used in patients with COVID-19, and in those who meet these criteria, it is optimal to use anticoagulants.

Up to 71.4% of patients who died from COVID-19 had an ICE, compared with only 0.6% of survivors. The main change in this coagulopathy is a marked increase in DD without a decrease in PLT, or a prolongation of APTT and PT, indicating

the process of thrombin formation and local rather than systemic fibrinolysis. The highest level of hospital mortality was found in patients with DD values more than 3–4 times [24, 26, 28, 38, 39].

Given the occurrence of signs of coagulation system dysfunction in COVID-19, it is proposed to assess the severity of the disease (COVID-19-associated hemostatic abnormalities — CAHA-score) [28, 30, 41, 57–59]:

- **Stage 1 CAHA:** The patient has mild symptoms and can be cared for at home or in hospital. At this stage, pulmonary microthrombi may be missed on computed tomography;
- **Stage 2 CAHA:** The patient may develop more severe symptoms and need resuscitation. Computed tomography scans of these patients may reveal lung filling defects due to blood clots or embolism. They may also have asymptomatic deep vein thrombosis in the lower extremities, which means significant activation of coagulation;
- **Stage 3 CAHA:** The patient's clinical condition is deteriorating, which requires the maintenance of a higher level of intensive care. Extensive pulmonary thrombi and systemic thrombosis, including DIC, have been reported.

Thus, there is a need to identify an increased risk of thrombotic events at an early stage and to prevent thrombotic events and organ damage as much as possible.

Deterioration of laboratory parameters associated with blood coagulation indicates the progression of the severity of COVID-19 infection and suggests the need for greater and more aggressive intensive care, while improvement in these parameters along with improvement or clinical stability indicates an adequate evolution [24].

Thromboprophylaxis

Hospitalized patients with COVID-19 have both internal and external risk factors for thrombosis, including old age, obesity, immobilization, neurological disease, cancer, intensive care, previous cases of thromboembolism or thrombophilia [42].

Pharmacological thromboprophylaxis should be considered in all hospitalized patients with COVID-19 if there are no contraindications (active bleeding or severe thrombocytopenia). Different scales (Padua, Caprini, IMPROVE) can be used to assess risk. The dose should be adjusted according to renal function. Although existing protocols should be followed when selecting the drug, the WHO recommends the use of unfractionated or

low molecular weight heparins (LMWH) and, if contraindicated, mechanical thromboprophylaxis should be considered. Pharmacological thromboprophylaxis is recommended once a day, as it reduces the risk of skipping additional doses and is associated with less impact on medical personnel during its use. If LMWH is not available, unfractionated heparin may be considered, keeping in mind that this requires more frequent injections. Patients with more severe infections may require higher doses of thromboprophylaxis due to their hypercoagulable state. The use of direct anticoagulants for thromboprophylaxis is not recommended in this context due to the possible interactions that may occur with the various drugs and treatments available and studied for the treatment of COVID-19 [5, 20, 21, 42].

Some of the non-anticoagulant properties of LMWH include the potential for binding to inflammatory cytokines, inhibition of neutrophil chemotaxis and leukocyte migration, neutralization of positively charged complement factor C5a, and sequestration of acute phase proteins [18, 44].

In view of the above it is suggested that LMWH, administered in the early stages of SARS-CoV-2 infection may have a positive effect not only in preventing thrombosis, but also in reducing systemic and pulmonary inflammation and limiting viral invasion [12, 19], among others. Non-anticoagulant properties of heparin: antiviral action (experimental models), reduction of collagen deposits and antiarrhythmic action (animal models), modulation of endothelial dysfunction, improvement of microvascular dysfunction and alleviation of pulmonary coagulopathy [33, 42].

Patients who remain fully immobilized may benefit from drug thromboprophylaxis due to periodic pneumatic compression. This therapy should also be considered if there is severe thrombocytopenia (platelets from 25 G/L to 50 G/L) [8, 34, 35, 42].

According to the authors [8, 27, 42], long-term outpatient thromboprophylaxis (14 to 45 days) should be considered in patients at high risk of deep vein thrombosis, regardless of COVID-19 infection, including reduced mobility, previous thromboembolic events, comorbidities (eg. active cancer) and elevated DD levels of more than 2 times). Thromboprophylaxis is not recommended for patients in quarantine due to a mild form of COVID-19 but with significant comorbidities, or patients without COVID-19 but functionally limited in quarantine. These patients should be advised to stay active at home.

Pharmacological thromboprophylaxis in adult patients with COVID-19

The results of studies on the prevention of deep vein thrombosis in adult patients in critical condition with COVID-19-associated pneumonia have been published [10, 35, 36].

Histopathological examinations revealed diffuse lesions of the alveoli with deep inflammation, thrombosis and thrombotic microangiopathy of small vessels and capillaries of the lungs. In extrapulmonary organs, endothelial cell damage and diffuse microvascular thrombosis have also been reported, indicating thrombotic microangiopathy, which may explain the acute onset of multiorgan failure [10, 35, 36].

According to current guidelines, patients with stage 1 CAHA should receive LMWH in the absence of contraindications [35, 41]. Several trials are currently underway for patients with treatment disorders corresponding to stage 2 CAHA to determine whether a full dose of anticoagulants compared to prophylactic can help prevent the development of coagulopathy and ischemia in the extrapulmonary circulation. After the detection of blood clots, the standard practice is to treat such patients with anticoagulants in a therapeutic dose [35, 41, 42]. Intensification of antithrombotic therapy (prevention of double-dose LMWH) in stage 2 CAHA can be performed in combination with several other experimental measures, such as thrombolysis, which may be effective in patients in stage 3 CAHA [41].

The developed guidelines provide guidance to physicians caring for both COVID-19 patients and patients with chronic thrombotic conditions requiring ongoing treatment. Recently, there has been published work focusing on anticoagulant strategies for the prevention and treatment of deep vein thrombosis in patients with proven SARS-CoV-2 infection who are in outpatient treatment and hospitalized for the prevention or treatment of thrombosis [35, 42].

Pharmacological thromboprophylaxis in pediatric and adolescent patients with COVID-19

Rare deaths of children from COVID-19 infection have been reported in worldwide [60]. Most often diagnosed with asymptomatic disease, or with mild or moderate severity [46, 61]. As in adults, the risk of serious illness and death in children is higher in people with comorbidities

[47, 62]. In general, the experience of monitoring infants and children with COVID-19 in hospitals is limited [63].

From the standpoint that a significant number of clinical issues deserve further study and clarification, we have prepared general recommendations for thromboprophylaxis childrens regimens.

Outpatients with mild COVID-19 should not be prescribed pharmacological thromboprophylaxis, but it is important to encourage increased mobility of the child and to control adequate hydration in the presence of fever or vomiting. Given the rapid deterioration reported in many adult patients with mild symptoms, regular monitoring of DD, Fib, PLT, PT and APTT every 48 hours for 5–7 days may be recommended. Patients with DD levels above 300 ng/mL have a high risk of thrombosis and should receive LMWH prophylaxis with continuous assessment of deep vein thrombosis.

Patients with moderate COVID-19 who require hospitalization should receive anticoagulant therapy [64] using prophylactic doses of LMWH.

Intensification of anticoagulant therapy is recommended in case of severe COVID-19 (DD > 500 ng/mL, serum ferritin > 500 ng/mL, worsening of clinical signs of disease). Especially when the patient is in critical condition (DD > 2500 ng/mL, PLT > 450 G/L and CRP > 100 mg/dL; Table 1).

Coagulation should be closely monitored during treatment to prevent excessive anticoagulant therapy and bleeding [65, 66]. Anti-Xa levels and ARTT ratios are good ways to determine the effectiveness of LMWH in patients with confirmed deep vein thrombosis. After reaching the desired level, the test can be repeated every 6–7 days. If an invasive procedure is required, it is recommended to skip two doses of LMWH before the procedure [26].

In patients with renal insufficiency, unfractionated heparins of 75 IU/kg intravenous infusion over 10 minutes (maximum 5000 IU) as the loading dose are the anticoagulants of choice. This should be followed by a continuous maintenance intravenous infusion (maximum initial rate of 1300 IU/h). The recommended infusion rate is 28 IU/kg/h in infants and children under 12 months of age, 20 IU/kg/h in children 1 to 15 years of age, and 18 IU/kg/h in children 16 years of age and older.

For patients already receiving anticoagulant therapy, the proposed algorithm approach is illustrated in Figure 1.

Transferring a patient from an inpatient setting to an outpatient setting is the next step, including reassessing anticoagulant therapy and ensuring

Table 1. Anticoagulant prophylaxis with Enoxaparin for patients with moderate, severe and critical form of COVID-19, which require hospitalization.

	Profile dose	Prophylactic intensified dose	Treatment dose
Target anti-Xa	0.2–0.4 U/mL	0.4–0.8 U/mL	0.6–1.1 U/mL
≤ 2 months	0.75 mg/kg, every 12 h	1.0 mg/kg, every 12 h	1.5 mg/kg, every 12 h
From 2 months till ≤ 18 years:			
< 40 kg	0.5 mg/kg, every 12 h	0.75 mg/kg, every 12 h	1.0 mg/kg, every 12 h
> 40 kg	40 mg, 1 time a day	60 mg, every 12 h	40 mg, every 12 h

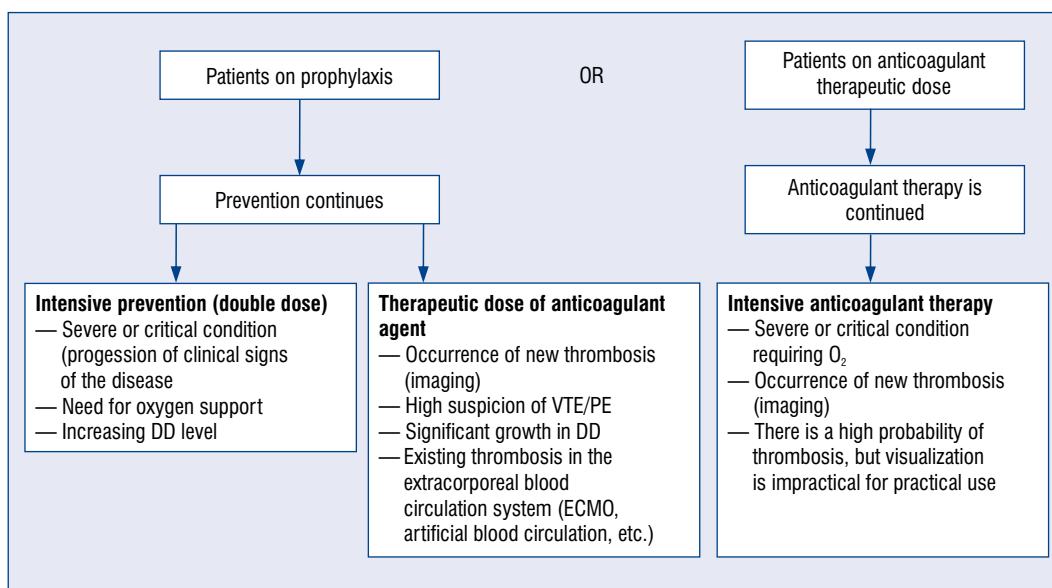


Figure 1. Algorithm for the use of anticoagulants in coronavirus disease 2019 (COVID-19) patients with ≤ 18 years who have already taken an anticoagulant. Heparin resistance in COVID-19: if the heparin dose is > 25 IU/kg/day and there is no activated partial thromboplastin clotting time prolongation anti-Xa monitoring at the level of 0.3–0.7 IU/mL; DD — D-dimer; ECMO — extracorporeal membrane oxygenation; PE — pulmonary embolism; VTE — venous thromboembolism.

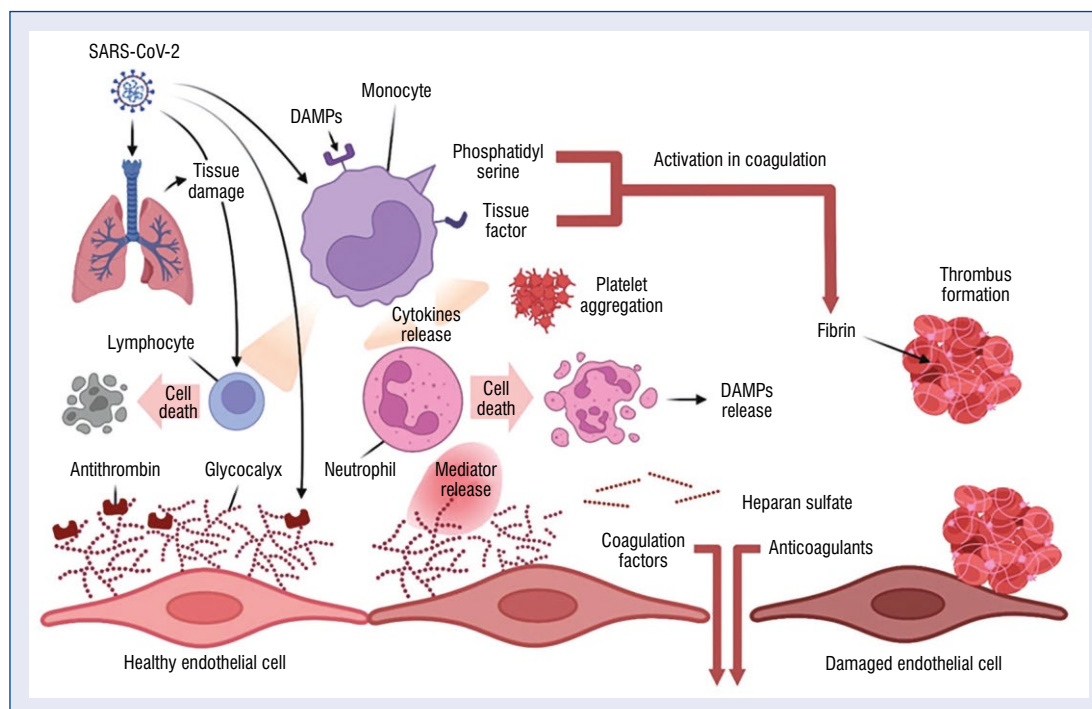
adequate communication between physicians, the patient, family members, or caregivers. The use of thromboprophylaxis in patients with COVID-19 after inpatient treatment should be considered if the stratification of deep vein thrombolism risk indicates a persistently increased risk of co-morbidity due to comorbidities, as well as a concentration twice or more above the upper control range. This is evidenced by studies suggesting thromboprophylaxis or therapeutic anticoagulation in patients after inpatient treatment. At least 2 weeks of anticoagulant therapy and imaging studies to assess thrombosis are recommended, as well as extended anticoagulant therapy [49].

Conclusions

Severe complications and a high number of deaths due to COVID-19 have once again drawn the attention of experts to the prevention and treatment of thrombotic and thromboembolic diseases.

The direct and indirect effects of COVID-19 are associated with the development of a cytokine storm, which accelerates the onset of systemic inflammatory response syndrome and promotes thrombotic events (Central illustration).

Antiviral and pathogenetic agents of COVID-19 (lopinavir/ritonavir, remdesivir, tocilizumab, sarylumab, fingolimod, chloroquine/hydroxychloroquine, interferon, azithromycin) may have



Central illustration. Mechanism of thrombus formation during COVID-19 infection; DAMP — danger/damage associated molecular patterns; SARS-CoV-2 — severe acute respiratory syndrome coronavirus 2.

drug interactions with antiplatelet agents and/or anticoagulants.

At the same time, recommendations for social distancing may adversely affect the treatment of patients without COVID-19 who have thrombotic events, and fear of developing COVID-19 or complications may result in some patients not receiving or discontinuing anticoagulant therapy.

Some clinical issues deserve further research and refinement to better understand the specific features, needs and concerns of critically ill children and adults with COVID-19 infection, especially those who already have comorbidities.

Protocols for thromboprophylaxis, in particular the use of anticoagulants or additional considerations for the treatment of covid-induced coagulopathy, should be used in accordance with the latest national and international guidelines.

Conflict of interest: None declared

References

- Ruetzler K, Szarpak L, Filipiak K, et al. The COVID-19 pandemic — a view of the current state of the problem. *Disaster Emerg Med J.* 2020; 5(2): 106–107, doi: [10.5603/demj.a2020.0015](https://doi.org/10.5603/demj.a2020.0015).
- Dzietekowski T, Szarpak L, Filipiak KJ, et al. COVID-19 challenge for modern medicine. *Cardiol J.* 2020; 27(2): 175–183, doi: [10.5603/CJ.a2020.0055](https://doi.org/10.5603/CJ.a2020.0055), indexed in Pubmed: [32286679](https://pubmed.ncbi.nlm.nih.gov/32286679/).
- Merajikhah A, Beigi-khoozani A, Soleimani M. Risk of spreading delta coronavirus to operating room personnel after COVID-19 vaccination. *Disaster Emerg Med J.* 2021; 6(4): 206–207, doi: [10.5603/demj.a2021.0026](https://doi.org/10.5603/demj.a2021.0026).
- Aguar D, Lobrinus JA, Schibler M, et al. Inside the lungs of COVID-19 disease. *Int J Legal Med.* 2020; 134(4): 1271–1274, doi: [10.1007/s00414-020-02318-9](https://doi.org/10.1007/s00414-020-02318-9), indexed in Pubmed: [32458044](https://pubmed.ncbi.nlm.nih.gov/32458044/).
- American Society of Hematology. <https://www.hematology.org/covid-19/covid-19-and-coagulopathy>. (Accessed May 5, 2020).
- Branchford BR, Betensky M, Goldenberg NA. Pediatric issues in thrombosis and hemostasis: The how and why of venous thromboembolism risk stratification in hospitalized children. *Thromb Res.* 2018; 172: 190–193, doi: [10.1016/j.thromres.2018.02.010](https://doi.org/10.1016/j.thromres.2018.02.010), indexed in Pubmed: [29472108](https://pubmed.ncbi.nlm.nih.gov/29472108/).
- Smereka J, Szarpak L, Filipiak K. Modern medicine in COVID-19 era. *Disaster Emerg Med J.* 2020, doi: [10.5603/demj.a2020.0012](https://doi.org/10.5603/demj.a2020.0012).
- Ackermann M, Verleden SE, Kuehnel M, et al. Pulmonary vascular endothelialitis, thrombosis, and angiogenesis in COVID-19. *N Engl J Med.* 2020; 383(2): 120–128, doi: [10.1056/NEJMoa2015432](https://doi.org/10.1056/NEJMoa2015432), indexed in Pubmed: [32437596](https://pubmed.ncbi.nlm.nih.gov/32437596/).
- Branchford BR, Mourani P, Bajaj L, et al. Risk factors for in-hospital venous thromboembolism in children: a case-control study employing diagnostic validation. *Haematologica.* 2012; 97(4): 509–515, doi: [10.3324/haematol.2011.054775](https://doi.org/10.3324/haematol.2011.054775), indexed in Pubmed: [22133768](https://pubmed.ncbi.nlm.nih.gov/22133768/).
- Thachil J, Tang N, Gando S, et al. ISTH interim guidance on recognition and management of coagulopathy in COVID-19. *J Thromb Haemost.* 2020; 18(5): 1023–1026, doi: [10.1111/jth.14810](https://doi.org/10.1111/jth.14810), indexed in Pubmed: [32338827](https://pubmed.ncbi.nlm.nih.gov/32338827/).
- Zhou Y, Hou Y, Shen J, et al. Network-based drug repurposing for novel coronavirus 2019-nCoV/SARS-CoV-2. *Cell Discov.* 2020; 6: 14, doi: [10.1038/s41421-020-0153-3](https://doi.org/10.1038/s41421-020-0153-3), indexed in Pubmed: [32194980](https://pubmed.ncbi.nlm.nih.gov/32194980/).

12. BSH Haemostatis and Thrombosis Task Force. https://b-s-h.org.uk/media/18206/dic-score-in-covid-19-pneumonia_01-04-2020.pdf (Accessed May 5, 2020).
13. Gómez-Mesa JE, Galindo-Coral S, Montes MC, et al. Thrombosis and Coagulopathy in COVID-19. *Curr Probl Cardiol.* 2021; 46(3): 100742, doi: [10.1016/j.cpcardiol.2020.100742](https://doi.org/10.1016/j.cpcardiol.2020.100742), indexed in Pubmed: [33243440](https://pubmed.ncbi.nlm.nih.gov/33243440/).
14. Cao X. COVID-19: immunopathology and its implications for therapy. *Nat Rev Immunol.* 2020; 20(5): 269–270, doi: [10.1038/s41577-020-0308-3](https://doi.org/10.1038/s41577-020-0308-3), indexed in Pubmed: [32273594](https://pubmed.ncbi.nlm.nih.gov/32273594/).
15. Fan E, Beitler J, Brochard L, et al. COVID-19-associated acute respiratory distress syndrome: is a different approach to management warranted? *Lancet Respir Med.* 2020; 8(8): 816–821, doi: [10.1016/s2213-2600\(20\)30304-0](https://doi.org/10.1016/s2213-2600(20)30304-0).
16. Faustino EV, Raffini LJ. Prevention of hospital-acquired venous thromboembolism in children: a review of published guidelines. *Front Pediatr.* 2017; 5: 9, doi: [10.3389/fped.2017.00009](https://doi.org/10.3389/fped.2017.00009), indexed in Pubmed: [28184368](https://pubmed.ncbi.nlm.nih.gov/28184368/).
17. Hoffmann M, Kleine-Weber H, Schroeder S, et al. SARS-CoV-2 cell entry depends on ACE2 and TMPRSS2 and is blocked by a clinically proven protease inhibitor. *Cell.* 2020; 181(2): 271–280.e8, doi: [10.1016/j.cell.2020.02.052](https://doi.org/10.1016/j.cell.2020.02.052), indexed in Pubmed: [32142651](https://pubmed.ncbi.nlm.nih.gov/32142651/).
18. Hou YJ, Okuda K, Edwards CE, et al. SARS-CoV-2 reverse genetics reveals a variable infection gradient in the respiratory tract. *Cell.* 2020; 182(2): 429–446.e14, doi: [10.1016/j.cell.2020.05.042](https://doi.org/10.1016/j.cell.2020.05.042), indexed in Pubmed: [32526206](https://pubmed.ncbi.nlm.nih.gov/32526206/).
19. Huang C, Wang Y, Li X, et al. Clinical features of patients infected with 2019 novel coronavirus in Wuhan, China. *Lancet.* 2020; 395(10223): 497–506, doi: [10.1016/s0140-6736\(20\)30183-5](https://doi.org/10.1016/s0140-6736(20)30183-5).
20. Jaffray J, Witmer C, O'Brien SH, et al. Peripherally inserted central catheters lead to a high risk of venous thromboembolism in children. *Blood.* 2020; 135(3): 220–226, doi: [10.1182/blood.2019002260](https://doi.org/10.1182/blood.2019002260), indexed in Pubmed: [31909784](https://pubmed.ncbi.nlm.nih.gov/31909784/).
21. Jaimes JA, Millet JK, Whittaker GR. Proteolytic cleavage of the SARS-CoV-2 spike protein and the role of the novel S1/S2 site. *iScience.* 2020; 23(6): 101212, doi: [10.1016/j.isci.2020.101212](https://doi.org/10.1016/j.isci.2020.101212), indexed in Pubmed: [32512386](https://pubmed.ncbi.nlm.nih.gov/32512386/).
22. Kirchdoerfer RN, Ward AB. Structure of the SARS-CoV nsp12 polymerase bound to nsp7 and nsp8 co-factors. *Nat Commun.* 2019; 10(1): 2342, doi: [10.1038/s41467-019-10280-3](https://doi.org/10.1038/s41467-019-10280-3), indexed in Pubmed: [31138817](https://pubmed.ncbi.nlm.nih.gov/31138817/).
23. Li Q, Guan X, Wu P, et al. Early transmission dynamics in Wuhan, china, of novel coronavirus-infected pneumonia. *N Engl J Med.* 2020; 382(13): 1199–1207, doi: [10.1056/NEJMoa2001316](https://doi.org/10.1056/NEJMoa2001316), indexed in Pubmed: [31995857](https://pubmed.ncbi.nlm.nih.gov/31995857/).
24. Li Yu, Zhang Z, Yang Li, et al. The MERS-CoV receptor DPP4 as a candidate binding target of the SARS-CoV-2 spike. *iScience.* 2020; 23(6): 101160, doi: [10.1016/j.isci.2020.101160](https://doi.org/10.1016/j.isci.2020.101160), indexed in Pubmed: [32405622](https://pubmed.ncbi.nlm.nih.gov/32405622/).
25. Mahajerin A, Branchford BR, Amankwah EK, et al. Hospital-associated venous thromboembolism in pediatrics: a systematic review and meta-analysis of risk factors and risk-assessment models. *Haematologica.* 2015; 100(8): 1045–1050, doi: [10.3324/haematol.2015.123455](https://doi.org/10.3324/haematol.2015.123455), indexed in Pubmed: [26001789](https://pubmed.ncbi.nlm.nih.gov/26001789/).
26. Marini JJ, Gattinoni L. Management of COVID-19 respiratory distress. *JAMA.* 2020; 323(22): 2329–2330, doi: [10.1001/jama.2020.6825](https://doi.org/10.1001/jama.2020.6825), indexed in Pubmed: [32329799](https://pubmed.ncbi.nlm.nih.gov/32329799/).
27. Andersen KG, Rambaut A, Lipkin WI, et al. The proximal origin of SARS-CoV-2. *Nat Med.* 2020; 26(4): 450–452, doi: [10.1038/s41591-020-0820-9](https://doi.org/10.1038/s41591-020-0820-9), indexed in Pubmed: [32284615](https://pubmed.ncbi.nlm.nih.gov/32284615/).
28. Xu Z, Shi L, Wang Y, et al. Pathological findings of COVID-19 associated with acute respiratory distress syndrome. *Lancet Respir Med.* 2020; 8(4): 420–422, doi: [10.1016/s2213-2600\(20\)30076-x](https://doi.org/10.1016/s2213-2600(20)30076-x).
29. Szarpak L, Pruc M, Filipiak KJ, et al. Myocarditis: A complication of COVID-19 and long-COVID-19 syndrome as a serious threat in modern cardiology. *Cardiol J.* 2022; 29(1): 178–179, doi: [10.5603/CJ.a2021.0155](https://doi.org/10.5603/CJ.a2021.0155), indexed in Pubmed: [34811716](https://pubmed.ncbi.nlm.nih.gov/34811716/).
30. Zhang YZ, Holmes EC. A genomic perspective on the origin and emergence of SARS-CoV-2. *Cell.* 2020; 181(2): 223–227, doi: [10.1016/j.cell.2020.03.035](https://doi.org/10.1016/j.cell.2020.03.035), indexed in Pubmed: [32220310](https://pubmed.ncbi.nlm.nih.gov/32220310/).
31. Nucera G, Chirico F, Rafique Z, et al. Need to update cardiologic guidelines to prevent COVID-19 related myocardial infarction and ischemic stroke. *Cardiol J.* 2022; 29(1): 174–175, doi: [10.5603/CJ.a2021.0120](https://doi.org/10.5603/CJ.a2021.0120), indexed in Pubmed: [34642925](https://pubmed.ncbi.nlm.nih.gov/34642925/).
32. Szarpak Ł, Nowak B, Kosior D, et al. Cytokines as predictors of COVID-19 severity: evidence from a meta-analysis. *Pol Arch Intern Med.* 2021; 131(1): 98–99, doi: [10.20452/pamw.15685](https://doi.org/10.20452/pamw.15685), indexed in Pubmed: [33219785](https://pubmed.ncbi.nlm.nih.gov/33219785/).
33. Song JC, Wang G, Zhang W, et al. Chinese expert consensus on diagnosis and treatment of coagulation dysfunction in COVID-19. *Mil Med Res.* 2020; 7(1): 19, doi: [10.1186/s40779-020-00247-7](https://doi.org/10.1186/s40779-020-00247-7), indexed in Pubmed: [32307014](https://pubmed.ncbi.nlm.nih.gov/32307014/).
34. Sungnak W, Huang Ni, Bécavin C, et al. SARS-CoV-2 entry factors are highly expressed in nasal epithelial cells together with innate immune genes. *Nat Med.* 2020; 26(5): 681–687, doi: [10.1038/s41591-020-0868-6](https://doi.org/10.1038/s41591-020-0868-6), indexed in Pubmed: [32327758](https://pubmed.ncbi.nlm.nih.gov/32327758/).
35. Tang N, Li D, Wang X, et al. Abnormal coagulation parameters are associated with poor prognosis in patients with novel coronavirus pneumonia. *J Thromb Haemost.* 2020; 18(4): 844–847, doi: [10.1111/jth.14768](https://doi.org/10.1111/jth.14768), indexed in Pubmed: [32073213](https://pubmed.ncbi.nlm.nih.gov/32073213/).
36. Taylor F, Toh CH, Hoots K, et al. Towards definition, clinical and laboratory criteria, and a scoring system for disseminated intravascular coagulation. *J Thromb Haemost.* 2017; 86(11): 1327–1330, doi: [10.1055/s-0037-1616068](https://doi.org/10.1055/s-0037-1616068).
37. Ruetzler K, Szarpak Ł, Ładny JR, et al. D-dimer levels predict COVID-19 severity and mortality. *Kardiol Pol.* 2021; 79(2): 217–218, doi: [10.33963/KP.15830](https://doi.org/10.33963/KP.15830), indexed in Pubmed: [33635034](https://pubmed.ncbi.nlm.nih.gov/33635034/).
38. Perico L, Benigni A, Remuzzi G. Should COVID-19 concern nephrologists? Why and to what extent? The emerging impasse of angiotensin blockade. *Nephron.* 2020; 144(5): 213–221, doi: [10.1159/000507305](https://doi.org/10.1159/000507305), indexed in Pubmed: [32203970](https://pubmed.ncbi.nlm.nih.gov/32203970/).
39. Pernazza A, Mancini M, Rullo E, et al. Early histologic findings of pulmonary SARS-CoV-2 infection detected in a surgical specimen. *Virchows Arch.* 2020; 477(5): 743–748, doi: [10.1007/s00428-020-02829-1](https://doi.org/10.1007/s00428-020-02829-1), indexed in Pubmed: [32356025](https://pubmed.ncbi.nlm.nih.gov/32356025/).
40. Ranucci M, Ballotta A, Di Dedda U, et al. The procoagulant pattern of patients with COVID-19 acute respiratory distress syndrome. *J Thromb Haemost.* 2020; 18(7): 1747–1751, doi: [10.1111/jth.14854](https://doi.org/10.1111/jth.14854), indexed in Pubmed: [32302448](https://pubmed.ncbi.nlm.nih.gov/32302448/).
41. Shang J, Wan Y, Luo C, et al. Cell entry mechanisms of SARS-CoV-2. *Proc Natl Acad Sci U S A.* 2020; 117(21): 11727–11734, doi: [10.1073/pnas.2003138117](https://doi.org/10.1073/pnas.2003138117), indexed in Pubmed: [32376634](https://pubmed.ncbi.nlm.nih.gov/32376634/).
42. Shi J, Wen Z, Zhong G, et al. Susceptibility of ferrets, cats, dogs, and other domesticated animals to SARS-coronavirus 2. *Science.* 2020; 368(6494): 1016–1020, doi: [10.1126/science.abb7015](https://doi.org/10.1126/science.abb7015), indexed in Pubmed: [32269068](https://pubmed.ncbi.nlm.nih.gov/32269068/).
43. Katipoğlu B, Sönmez LÖ, Vatansav H, et al. Can hematological and biochemical parameters fasten the diagnosis of COVID-19 in emergency departments? *Disaster Emerg Med J.* 2020, doi: [10.5603/demj.a2020.0039](https://doi.org/10.5603/demj.a2020.0039).

44. Shi Y, Wang Y, Shao C, et al. COVID-19 infection: the perspectives on immune responses. *Cell Death Differ.* 2020; 27(5): 1451–1454, doi: [10.1038/s41418-020-0530-3](https://doi.org/10.1038/s41418-020-0530-3), indexed in Pubmed: [32205856](https://pubmed.ncbi.nlm.nih.gov/32205856/).
45. Ziegler CGK, Allon SJ, Nyquist SK, et al. SARS-CoV-2 receptor ACE2 is an interferon-stimulated gene in human airway epithelial cells and is detected in specific cell subsets across tissues. *Cell.* 2020; 181(5): 1016–1035.e19, doi: [10.1016/j.cell.2020.04.035](https://doi.org/10.1016/j.cell.2020.04.035), indexed in Pubmed: [32413319](https://pubmed.ncbi.nlm.nih.gov/32413319/).
46. Toh CH, Hoots WK. The scoring system of the Scientific and Standardisation Committee on Disseminated Intravascular Coagulation of the International Society on Thrombosis and Haemostasis: a 5-year overview. *J Thromb Haemost.* 2007; 5(3): 604–606, doi: [10.1111/j.1538-7836.2007.02313.x](https://doi.org/10.1111/j.1538-7836.2007.02313.x), indexed in Pubmed: [17096704](https://pubmed.ncbi.nlm.nih.gov/17096704/).
47. Wan Y, Shang J, Graham R, et al. Receptor recognition by the novel coronavirus from Wuhan: an analysis based on decade-long structural studies of SARS coronavirus. *J Virol.* 2020; 94(7): e00127-20, doi: [10.1128/JVI.00127-20](https://doi.org/10.1128/JVI.00127-20), indexed in Pubmed: [31996437](https://pubmed.ncbi.nlm.nih.gov/31996437/).
48. Wang J, Hajizadeh N, Moore EE, et al. Tissue plasminogen activator (tPA) treatment for COVID-19 associated acute respiratory distress syndrome (ARDS): A case series. *J Thromb Haemost.* 2020; 18(7): 1752–1755, doi: [10.1111/jth.14828](https://doi.org/10.1111/jth.14828), indexed in Pubmed: [32267998](https://pubmed.ncbi.nlm.nih.gov/32267998/).
49. Wang Y, Zhu LQ. Pharmaceutical care recommendations for antiviral treatments in children with coronavirus disease 2019. *World J Pediatr.* 2020; 16(3): 271–274, doi: [10.1007/s12519-020-00353-5](https://doi.org/10.1007/s12519-020-00353-5), indexed in Pubmed: [32166483](https://pubmed.ncbi.nlm.nih.gov/32166483/).
50. Wölfel R, Corman VM, Guggemos W, et al. Virological assessment of hospitalized patients with COVID-2019. *Nature.* 2020; 581(7809): 465–469, doi: [10.1038/s41586-020-2196-x](https://doi.org/10.1038/s41586-020-2196-x), indexed in Pubmed: [32235945](https://pubmed.ncbi.nlm.nih.gov/32235945/).
51. Xiong Mi, Liang X, Wei YD. Changes in blood coagulation in patients with severe coronavirus disease 2019 (COVID-19): a meta-analysis. *Br J Haematol.* 2020; 189(6): 1050–1052, doi: [10.1111/bjh.16725](https://doi.org/10.1111/bjh.16725), indexed in Pubmed: [32304581](https://pubmed.ncbi.nlm.nih.gov/32304581/).
52. Adam I, Szarpak L, Filipiak K, et al. Interferon lambda with remdesivir as a potential treatment option in COVID-19. *Disaster Emerg Med J.* 2020, doi: [10.5603/demj.a2020.0027](https://doi.org/10.5603/demj.a2020.0027).
53. Xu H, Zhong L, Deng J, et al. High expression of ACE2 receptor of 2019-nCoV on the epithelial cells of oral mucosa. *Int J Oral Sci.* 2020; 12(1): 8, doi: [10.1038/s41368-020-0074-x](https://doi.org/10.1038/s41368-020-0074-x), indexed in Pubmed: [32094336](https://pubmed.ncbi.nlm.nih.gov/32094336/).
54. Zumla A, Chan JFW, Azhar EI, et al. Coronaviruses — drug discovery and therapeutic options. *Nat Rev Drug Discov.* 2016; 15(5): 327–347, doi: [10.1038/nrd.2015.37](https://doi.org/10.1038/nrd.2015.37), indexed in Pubmed: [26868298](https://pubmed.ncbi.nlm.nih.gov/26868298/).
55. Fialek B, Pruc M, Smereka J, et al. Diagnostic value of lactate dehydrogenase in COVID-19: A systematic review and meta-analysis. *Cardiol J.* 2022; 29(5): 751–758, doi: [10.5603/CJ.a2022.0056](https://doi.org/10.5603/CJ.a2022.0056), indexed in Pubmed: [35762075](https://pubmed.ncbi.nlm.nih.gov/35762075/).
56. Szarpak L, Zaczynski A, Kosior D, et al. Evidence of diagnostic value of ferritin in patients with COVID-19. *Cardiol J.* 2020; 27(6): 886–887, doi: [10.5603/CJ.a2020.0171](https://doi.org/10.5603/CJ.a2020.0171), indexed in Pubmed: [33346371](https://pubmed.ncbi.nlm.nih.gov/33346371/).
57. Zhang L, Yan X, Fan Q, et al. D-dimer levels on admission to predict in-hospital mortality in patients with COVID-19. *J Thromb Haemost.* 2020; 18(6): 1324–1329, doi: [10.1111/jth.14859](https://doi.org/10.1111/jth.14859), indexed in Pubmed: [32306492](https://pubmed.ncbi.nlm.nih.gov/32306492/).
58. Zhou H, Chen X, Hu T, et al. A novel bat coronavirus closely related to SARS-CoV-2 contains natural insertions at the S1/S2 cleavage site of the spike protein. *Curr Biol.* 2020; 30(11): 2196–2203.e3, doi: [10.1016/j.cub.2020.05.023](https://doi.org/10.1016/j.cub.2020.05.023), indexed in Pubmed: [32416074](https://pubmed.ncbi.nlm.nih.gov/32416074/).
59. Zhou P, Yang XL, Wang XG, et al. A pneumonia outbreak associated with a new coronavirus of probable bat origin. *Nature.* 2020; 579(7798): 270–273, doi: [10.1038/s41586-020-2012-7](https://doi.org/10.1038/s41586-020-2012-7), indexed in Pubmed: [32015507](https://pubmed.ncbi.nlm.nih.gov/32015507/).
60. Meyer-Szary J, Jaguszewski M, Smereka J, et al. Impact of COVID-19 on pediatric out-of-hospital cardiac arrest in the Masovian region. *Disaster Emerg Med J.* 2021; 6(4): 183–185, doi: [10.5603/demj.a2021.0028](https://doi.org/10.5603/demj.a2021.0028).
61. Yaman E, Demirel B, Yilmaz A, et al. Retrospective evaluation of laboratory findings of suspected paediatric COVID-19 patients with positive and negative RT-PCR. *Disaster Emerg Med J.* 2021; 6(3): 97–103, doi: [10.5603/demj.a2021.0023](https://doi.org/10.5603/demj.a2021.0023).
62. Pruc M, Smereka J, Dzieciatkowski T, et al. Kawasaki disease shock syndrome or toxic shock syndrome in children and the relationship with COVID-19. *Med Hypotheses.* 2020; 144: 109986, doi: [10.1016/j.mehy.2020.109986](https://doi.org/10.1016/j.mehy.2020.109986), indexed in Pubmed: [32562912](https://pubmed.ncbi.nlm.nih.gov/32562912/).
63. Yaman E, Demirel B, Yilmaz A, et al. Retrospective evaluation of laboratory findings of suspected paediatric COVID-19 patients with positive and negative RT-PCR. *Disaster Emerg Med J.* 2021; 6(3): 97–103, doi: [10.5603/demj.a2021.0023](https://doi.org/10.5603/demj.a2021.0023).
64. Szarpak L, Filipiak KJ, Skwarek A, et al. Outcomes and mortality associated with atrial arrhythmias among patients hospitalized with COVID-19: A systematic review and meta-analysis. *Cardiol J.* 2022; 29(1): 33–43, doi: [10.5603/CJ.a2021.0167](https://doi.org/10.5603/CJ.a2021.0167), indexed in Pubmed: [34897631](https://pubmed.ncbi.nlm.nih.gov/34897631/).
65. Domienik-Karłowicz J, Tronina O, Lisik W, et al. The use of anticoagulants in chronic kidney disease: Common point of view of cardiologists and nephrologists. *Cardiol J.* 2020; 27(6): 868–874, doi: [10.5603/CJ.a2019.0025](https://doi.org/10.5603/CJ.a2019.0025), indexed in Pubmed: [30912573](https://pubmed.ncbi.nlm.nih.gov/30912573/).
66. Tomaszuk-Kazberuk A, Koziański M, Domienik-Karłowicz J, et al. Pharmacotherapy of atrial fibrillation in COVID-19 patients. *Cardiol J.* 2021; 28(5): 758–766, doi: [10.5603/CJ.a2021.0088](https://doi.org/10.5603/CJ.a2021.0088), indexed in Pubmed: [34382204](https://pubmed.ncbi.nlm.nih.gov/34382204/).