

Letters

Triphasic waves in Mollaret's meningitis

Sir: Triphasic waves are recognised findings in EEGs of patients with metabolic encephalopathy and Alzheimer's disease;¹ they are also known to occur in cerebrovascular accidents,² acute hyperthyroidism³ and metrizamide encephalopathy.⁴ We now report a patient with Mollaret's meningitis whose EEG showed triphasic waves during exacerbations. This association has not previously been described.

A 72-year-old female presented with acute fever and vomiting. Neurological examination showed only neck stiffness. Cerebrospinal fluid was clear and revealed 103 white cells (62% polymorphonuclears, 20% lymphocytes and 18% monocytes/mm³), protein of 1.04 g/l (normal: 0.2 to 0.4) and glucose of 4.3 mmol/l (normal: 2.8 to 4.5); bacterial, fungal and viral studies were negative. There was no laboratory evidence of renal or hepatic dysfunction or hypoxia. Extensive work-up for any "hidden" septic focus was negative. EEG showed frontally prominent triphasic waves, occurring in short runs (fig). The patient's symptoms cleared spontaneously over the following week. Repeat EEGs during symptom-free period were normal. The patient had five subsequent admissions with the same features of aseptic meningitis over the next 5 months, each time spontaneously recovering within one week. EEGs during these bouts again showed triphasic waves.

Detailed reviews of Mollaret's meningitis do not mention EEG findings or occurrence of triphasic waves.^{5,6} This condition should

be included among various disorders associated with triphasic waves. The pathogenesis of the waves in these disorders is not known, although impairment of dopaminergic system⁵ and abnormal cerebral glucose metabolism⁴ have been proposed. In metrizamide encephalopathy, metrizamide in the cerebrospinal fluid is thought to interfere with the sodium-potassium ATPase cation pump and competitively inhibit glucose metabolism.⁴ Mere presence of inflammatory cells in the cerebrospinal fluid is not likely to be related to the appearance of triphasic waves because viral, bacterial and tuberculous meningitis are not associated with such waves. It appears that different aetiologic factors (including the "agent" responsible for Mollaret's meningitis) produce dysfunction of a final anatomical or neurochemical mechanism at subcortical level, resulting in triphasic waves.

Finally, we wish to emphasise that the presence of triphasic waves in the EEG of patients with acute encephalopathy does not necessarily indicate a metabolic aetiology.

MBM SUNDARAM
P SIEMENS

Department of Clinical Neurological
Sciences, University Hospital,
Saskatoon, Canada S7N 0X0

References

¹Sundaram MB, Blume WT. Triphasic waves revisited. *Electroencephalogr Clin Neurophysiol* 1984;58:51P.
²Cid A, Oliveros D, Giadenes D, et al. Triphasic waves in acute cerebral vascular accident. *Electroencephalogr Clin Neurophysiol* 1980;50:52P.

³Scherokman BJ. Triphasic delta waves in a patient with acute hyperthyroidism. *Arch Neurol* 1980;37:731.
⁴Drake ME, Erwin CW. Triphasic EEG discharges in metrizamide encephalopathy. *J Neurol Neurosurg Psychiatry* 1984;47:324-5.
⁵Hermans PE, Goldstein NP, Wellman WE. Mollaret's meningitis and differential diagnosis of recurrent meningitis. *Am J Med* 1972;52:128-40.
⁶Tyler KL, Adler D. Twenty-eight years of benign recurring Mollaret meningitis. *Arch Neurol* 1983;40:42-3.

Accepted 12 June 1985

Herpes simplex encephalitis presenting as the sick sinus syndrome

Sir: Infection of the nervous system by Herpes simplex virus type 1 (HSV1) characteristically involves the cerebral hemispheres, showing a particular predilection for the temporal and frontal lobes. Cases usually present as a diffuse meningo-encephalitis or may mimic a supra-tentorial space occupying lesion, with fits, speech disturbance and hemiparesis. However, over the past decade it has become apparent that the virus may be responsible for a wider spectrum of disorder: CT evidence of occipital involvement has been demonstrated,¹ Roman-Campos and Toro² have reviewed six cases of brainstem encephalitis attributed to HSV1 and reported a further case, confirmed at necropsy while Klapper *et al*³ have recently described a more benign form with a good prognosis. We report an additional mode of presentation in which both clinical and pathological features of diencephalic involvement were apparent.

On the day prior to admission, a previously well 60-year-old man developed a number of fainting attacks in which he became very pale but did not convulse nor become incontinent. During a similar attack in the casualty department, a 10 second period of complete asystole was observed on cardiac monitoring, a diagnosis of the sick sinus syndrome made and a cardiac pacemaker inserted the same day. Within 24 hours he had become febrile and drowsy without evidence of meningism and over the next three days lapsed into coma characterised by small reactive pupils, intact brain stem reflexes, normal respiration and withdrawal of all four limbs to painful stimuli. Routine blood tests were normal apart from a serum sodium concentration falling to 121 mmol/l. Two CT scans with contrast were

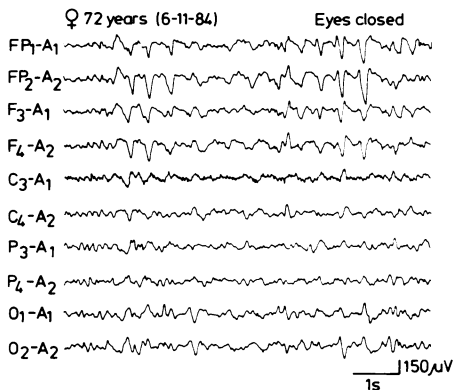


Fig EEG during first hospital admission, showing prominent frontal triphasic waves.

normal but electroencephalography revealed non-specific widespread slow-wave activity without focal features or triphasic complexes. The first CSF examination was acellular with an elevated protein of 0.93 g/l. A traumatic repeat lumbar puncture two days later, revealed 13,000 red blood cells, 280 white cells (90% polymorphs) and a protein of 2.7 g/l, the CSF/serum glucose ratio remaining normal. Bacteriological and viral cultures from a variety of sites were unhelpful and examination of paired serum and CSF revealed no rise in complement fixing antibodies to HSV1. He continued to deteriorate and developed right sided focal seizures. A further electroencephalogram 12 days after admission revealed sharp activity in the left temporal lobe while a CT scan showed a large area of low attenuation in the left frontal and temporal lobes with considerable mass effect. He was started on intravenous dexamethasone and acyclovir but died the same day.

At necropsy, the heart was unremarkable, the coronary and intracranial vessels were patent and histological examination of the sinus node, the AV node and bundle of His showed no abnormality. The brain was swollen with evidence of softening of both temporal lobes and superficial petechial haemorrhages were seen both over the inferior aspect of the temporal lobes and the diencephalon. Histological examination revealed neuronal loss, perivascular lymphocytic cuffing, necrosis and the presence of macrophages and reactive astrocytes. These changes, typical of a viral encephalitis, were most marked in the temporal lobes but were also present in the diencephalon, hypothalamus and to a lesser extent in the brainstem. Positive immunoperoxidase stains for HSV1 were obtained from both the temporal lobes and the pons, the causative agent being confirmed when the virus was isolated from the left temporal lobe.

This patient with proven herpes simplex encephalitis ultimately developed typical radiological and pathological evidence of temporal lobe involvement. The case is of interest, however, because of the unusual presentation and progression of the illness. The presence of coma with intact respiration and brain stem reflexes but small reactive pupils strongly suggests that the infection initially affected the diencephalon and mid-brain only. This may also be the explanation for the low serum sodium concentration since damage to the hypothalamus is a cause of inappropriate secretion of anti-diuretic hormone. Disturbance of cardiovascular control is a well recognised feature of diencephalic syndromes⁴ and there has been

a recent report of herpetic brainstem encephalitis with recovery⁵ in which labile hypertension, marked tachycardia, profuse sweating and mild hypothermia were attributed to diencephalic involvement. No primary cardiac cause for the arrhythmia could be demonstrated and in the absence of early temporal or brainstem involvement it seems probable that the attacks of asystole which precipitated admission were caused by herpetic encephalitis involving the diencephalon.

There is a further point of interest. The CSF cellular response to HSV1 though variable in size is predominantly lymphocytic for both supratentorial and brainstem presentations. The differential count seen in this case cannot be explained by traumatic tap and it would appear that the presence of a predominantly polymorphonuclear pleocytosis in the CSF does not exclude HSV encephalitis.

We thank Dr CL Bray and Dr RG Lascelles for permission to report this case and Claire Choueka for secretarial assistance.

S POLLOCK,
H REID,
P KLAPPER,
RA METCALFE,
N AHMED

*Departments of Neurology and Pathology,
Manchester Royal Infirmary,
Oxford Rd,
Manchester M13 9WL
Department of Cardiology,
Wythenshawe Hospital,
Manchester, UK*

References

- Bergey GK, Coyle PK, Krumholz A, Niedermeyer E. Herpes simplex encephalitis with occipital localization. *Arch Neurol* 1982; **39**:312-3
- Roman-Campos G, Toro G. Herpetic brainstem encephalitis. *Neurology (Minneapolis)* 1980; **30**:981-5.
- Klapper PE, Cleator GM, Longson M. Mild forms of herpes encephalitis. *J Neurol Neurosurg Psychiatry* 1984; **47**:1247-50.
- Boshes B. Syndromes of the Diencephalon. In: Vinken PJ, Bruyn GW, eds. *Handbook of Clinical Neurology*, vol. 2: 441. Amsterdam, Elsevier-North Holland, 1969.
- Jain S, Maheshwari MC. Herpetic Brainstem encephalitis with features of diencephalic epilepsy. *Acta Neurol Belg* 1984; **6**:1-4.

Aseptic meningitis due to trimethoprim-sulfamethoxazole

Sir: Aseptic meningitis has been described in association with the administration of anti-inflammatory drugs, including ibuprofen,

sulindac and tolmetin, and azathioprine.¹⁻⁴ We have recently seen a case of this adverse reaction caused by trimethoprim-sulfamethoxazole.

A 46-year-old woman was admitted because of chills, fever, headache and confusion. A diagnosis of systemic lupus erythematosus was made 12 years previously. Two days before her admission a urinary tract infection was detected and she was started on trimethoprim-sulfamethoxazole therapy. Half an hour after taking the first dose she began to experience chills, dizziness, fever, headache and confusion. On examination she was confused and had mild stiff neck. Her temperature was 40°C. Spinal fluid was turbid with 1070 leucocytes/mm³ (80% polynuclear, 20% lymphocytes). Spinal fluid protein was 1.38 g/l and glucose 3.7 mmol/l. Blood and spinal fluid cultures were negative. The patient was initially treated with intravenous cefotaxime and ampicillin. On the second day a dramatic improvement occurred; her temperature was 37°C. A second lumbar puncture revealed clear spinal fluid with 150 leucocytes/mm³ (32% polynuclear, 68% lymphocytes), protein concentration was 1.28 g/l and glucose 4.4 mmol/l. An adverse reaction to trimethoprim-sulfamethoxazole was suspected and antimicrobial drugs were withdrawn. A challenge test, after obtaining fully informed consent, was performed on the fifth day of admission. Thirty minutes after a dose of trimethoprim-sulfamethoxazole (80 and 400 mg respectively) was given by mouth she developed vomiting, chills, fever, dizziness, confusion, and combativeness. Confusion and nuchal rigidity was present. Three hours after the challenge test her spinal fluid leucocyte count was 284/mm³ (98% polynuclear, 2% lymphocytes) and protein concentration of 1.18 g/l. Mannitol and dexamethasone were given by vein and 5 days later she was discharged well.

There are two previous reports of aseptic meningitis due to trimethoprim-sulfamethoxazole^{5,6} and another case caused by trimethoprim alone.⁷ In our case, as in those reported previously, the spinal fluid glucose concentration was normal. The precise mechanism of this extremely rare adverse reaction remains unclear, although an immediate hypersensitivity reaction seems the most plausible. We believe that trimethoprim-sulfamethoxazole should be considered in the differential diagnosis of aseptic meningitis.

MERCEDES BIOSCA
MARIANO DE LA FIGUERA
FERNANDO GARCÍA-BRAGADO
GABRIEL SAMPOL