

LETTERS TO THE EDITOR

Liver cirrhosis in cystic fibrosis

EDITOR,—Feigelson *et al* report a relatively large series of 31 patients with cystic fibrosis and liver cirrhosis, emphasising its protracted course and reviewing their experience in the management of portal hypertension.¹ We too have observed that the development of uncomplicated cirrhosis often has little influence on the natural history of cystic fibrosis. However, we disagree with their conclusions about the management of alimentary bleeding from portal hypertension, which is a life threatening complication. In their study, five patients were treated by injection sclerotherapy, which was limited to two or three sessions. Not surprisingly, recurrent bleeding was common and this, combined with four deaths from variceal haemorrhage and the potential for ectopic variceal bleeding, prompted the authors to express doubts about this technique. Their single success with partial splenectomy led them to conclude that this is the procedure of choice.

Since 1979 we have regularly reviewed 19 patients with cystic fibrosis, cirrhosis, and portal hypertension (figure), 11 of whom were included in a previous analysis of the results of injection sclerotherapy in children with bleeding oesophageal varices.² Fifteen of these patients (eight boys, seven girls) have required injection sclerotherapy for variceal bleeding. The mean age at onset of bleeding was 11.5 (range 6–14.9) years. Variceal obliteration was achieved after a mean of 6 (range 3–9) injection sessions over a period of 0.8 (0.3–2.3) years; one boy is still undergoing treatment.

Five of the 15 died of respiratory failure without further gastrointestinal bleeding two months to nine years after variceal obliteration. Two patients have required surgery; one a splenectomy for symptomatic hypersplenism and the other a splenectomy and lienorenal shunt for gastric variceal bleeding. Excluding the boy still undergoing treatment, none of the survivors have significant residual oesophageal varices after a mean follow up of 4.3 years after completing treatment. Endoscopic injection sclerotherapy has proved effective in the control of oesophageal variceal bleeding and only one patient has required portosystemic shunt surgery for ectopic variceal haemorrhage.

Feigelson *et al* report no respiratory problems from sclerotherapy. We have a policy of intensive perioperative physiotherapy, bronchodilators, and prophylactic antibiotics to minimise the recognised deleterious effects of general anaesthesia and sclerosant injection on respiratory function.³

Sclerotherapy is an effective and safe modality for the control of bleeding from oesophageal varices in children with cystic fibrosis and the results appear to be better than those of portosystemic shunt surgery.⁴ Nevertheless, such surgery has an invaluable role in the management of some patients, such as those with ectopic variceal bleeding.⁵

M D STRINGER
J F PRICE
A P MOWAT
ER HOWARD

Departments of Paediatric Surgery, Hepatology and
Respirology,
King's College Hospital,
Denmark Hill,
London SE5 9RS

- 1 Feigelson J, Anagnostopoulos C, Poquet M, Pecau Y, Munck A, Navarro J. Liver cirrhosis in cystic fibrosis – therapeutic implications and long term follow up. *Arch Dis Child* 1993; 68: 653–7.
- 2 Howard ER, Stringer MD, Mowat AP. Assessment of injection sclerotherapy in the management of 152 children with oesophageal varices. *Br J Surg* 1988; 75: 404–8.
- 3 Richardson VF, Robertson CF, Mowat AP, Howard ER, Price JF. Deterioration in lung function after general anaesthesia in patients with cystic fibrosis. *Acta Paediatr Scand* 1984; 73: 75–9.
- 4 Schuster SR, Shwachman H, Toyama WM, Rubino A, Taik-Khaw K. The management of portal hypertension in cystic fibrosis. *J Pediatr Surg* 1977; 12: 201–6.
- 5 Heaton ND, Howard ER. Complications and limitations of injection sclerotherapy in portal hypertension. *Gut* 1993; 34: 7–10.

Drs Feigelson, Anagnostopoulos, Poquet, Pecau, Munck, Navarro comment:

Mr Stringer and his colleagues have demonstrated the efficacy of sclerotherapy in oesophageal varices in the course of cystic fibrosis and we do not intend to question the value of repeating this procedure whenever necessary.

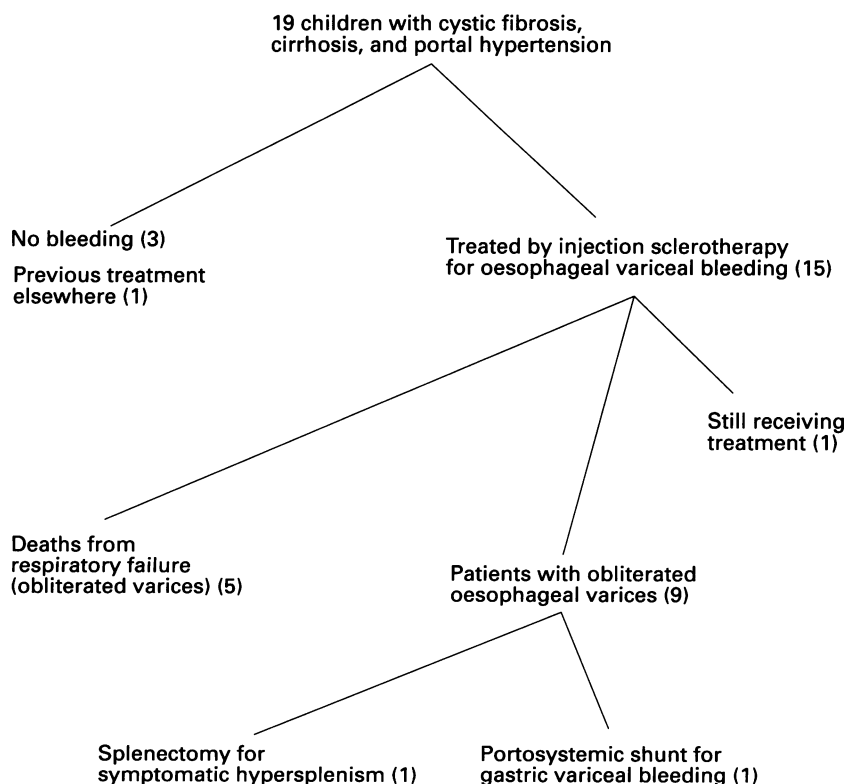
We none the less wish to point out the fact that even in expert hands, this technique does not offer complete safety.¹ Five of our patients underwent sclerosis of their varices: two of them had to be operated on later because of recurrences and a third patient died of haemorrhage two months after the second session of sclerotherapy. One patient was treated by sclerosis of oesophageal varices, but treatment was stopped as tomodesitometry showed important ectopic varices inaccessible to sclerosis.

On the other hand, sclerosis of oesophageal varices does not solve the problem of hypersplenism. Only one of our patients underwent partial splenectomy, however our surgical colleague, Dr Louis, has successfully performed this apparently simple procedure in eight other patients with no complications reported.² Anaesthesia was performed with every available precaution.³ Varices and haematological changes decreased in a few weeks, while the overall condition of the patients improved. In only one patient, varices had to be sclerosed after the operation. We are aware of the fact that partial splenectomy offers only temporary relief, but recurrences do not develop early after surgery.²

- 1 Tanner MS. Current management of hepatic problems in cystic fibrosis. *J R Soc Med* 1986; 79 (suppl 12): 38–43.
- 2 Louis D, Chazalotte J-P. Cystic fibrosis and portal hypertension; interest of partial splenectomy. *European Journal of Pediatric Surgery* 1993; 3: 22–4.
- 3 Doershuk CF, Reyes AL, Regan AG, *et al*. Anesthesia and surgery in cystic fibrosis. *Anesth Analg* 1972; 51: 413–21.

Hair loss in children

EDITOR,—We have read with interest the article by Verbov on hair loss in children.¹ Alopecia is a frequent manifestation of biotin dependent multicarboxylase deficiencies: while one of these disorders, holocarboxylase synthetase deficiency is very rare, that of biotinidase deficiency is more common with an estimated frequency of 1:84 000 world wide.² Biotinidase is responsible for the processing and recycling of biotin from biotinyl peptides. Development of symptoms in biotinidase deficiency is gradual, with episodes of remission perhaps modulated by the availability of free biotin in the diet. Neurological manifestations are the most frequent initial symptoms but patients have also presented with primarily respiratory symptoms. Alopecia frequently occurs, and is a hallmark of the disease, with discrete hair loss that in some cases becomes complete.



Patients reviewed since 1979.