

## Resolution of hepatic abscess after interferon gamma in chronic granulomatous disease

R A Hague, E J Eastham, R E J Lee, A J Cant

### Abstract

Recombinant interferon gamma has been used prophylactically in children with chronic granulomatous disease, but its role in the treatment of acute infective episodes has not been defined. A 3 year old boy presented with multiple candidal liver abscesses and was given intravenous antifungal treatment and he showed initial improvement. After six weeks his erythrocyte sedimentation rate and C reactive protein remained raised, and a computed tomogram showed a single abscess in the left lobe of the liver from which pus was drained and *Staphylococcus aureus* isolated. During the next eight months the abscess persisted despite appropriate intravenous antibiotics and percutaneous drainage. Subphrenic extension precluded definitive surgery. Nine months after initial presentation recombinant interferon gamma 0.05 mg/m<sup>2</sup> intravenously was commenced three times a week. Complete resolution occurred within two months. It is concluded that interferon gamma is useful in treating infective episodes, and further study of the use of prophylactic antimicrobial treatment and intermittent interferon gamma during acute episodes is now required.

(Arch Dis Child 1993; 69: 443-445)

Chronic granulomatous disease is an inherited disorder of neutrophil function, in which patients phagocytose bacteria normally, but cannot effectively kill ingested organisms. Bacterial killing is defective because of a failure of superoxide production, which requires the participation of both a membrane bound oxidase (NADPH) and cytosolic factors.<sup>1</sup> In approximately 60% of cases, cytochrome *b*<sub>558</sub> is absent, due to a defect on the X chromosome encoding the 91 kd subunit for the cytochrome. Most of the remaining cases are caused by the absence of either the 47 kd or the 67 kd cytosolic factors, and show an autosomal recessive pattern of inheritance.<sup>2</sup> Affected individuals are particularly susceptible to infection with catalase positive organisms such as *Staphylococcus aureus*, *Escherichia coli*, *Serratia marascens*, aspergillus and candida species, and typically present early in childhood with recurrent pyogenic abscesses and other infections that carry a high mortality and morbidity.<sup>3</sup>

Interferon gamma is a naturally occurring cytokine that activates phagocytic cells. In normal subjects administration of recombinant

interferon gamma enhances the activity of NADPH oxidase, and it increases bacterial killing both in vivo and in vitro.<sup>4,5</sup> In patients with chronic granulomatous disease early in vitro studies suggested that the defect in superoxide production could be partially corrected by adding interferon gamma to their phagocytes,<sup>6</sup> and in vivo, functional improvement after subcutaneous administration has also been described.<sup>7</sup> A recent controlled trial has reported a reduced risk of serious infection after regular subcutaneous administration of interferon gamma,<sup>8</sup> and there are a few anecdotal reports of clinical improvement of active infection with bacteria and fungi after this treatment.<sup>9-12</sup> However, its role, if any, in the management of acute infective episodes in children with chronic granulomatous disease has not been defined. We now describe its first reported use in the treatment of a hepatic abscess refractory to conventional treatment.

### Case report

A 3 year old white boy with a history of two staphylococcal submandibular abscesses presented with a month's history of abdominal pain, anorexia, vomiting, fever, and weight loss. Examination revealed a pale, thin lethargic child with a fever of 38°C and non-tender hepatosplenomegaly. The white cell count was 35.3 × 10<sup>9</sup>/l, erythrocyte sedimentation rate 120 mm/hour, C reactive protein 25 mg/l, and haemoglobin concentration 97 g/l. All bacterial and viral cultures were negative, including blood cultures for bacteria and fungi, and chest and plain abdominal radiographs were normal. He was treated empirically with intravenous ampicillin, gentamicin, and metronidazole for 10 days with no improvement. Ultrasound examination of the abdomen was then performed, which revealed multiple hepatic abscesses typical of those caused by candida

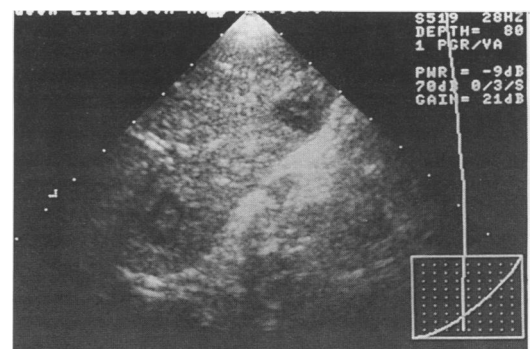


Figure 1 Initial hepatic ultrasound scan showing multiple abscesses.

Department of Paediatric Immunology, Newcastle General Hospital, Westgate Road, Newcastle upon Tyne NE4 6BE  
R A Hague  
A J Cant

Royal Victoria Infirmary, Newcastle upon Tyne, Department of Child Health  
E J Eastham

Department of Radiology  
R E J Lee

Correspondence to: Dr Cant.

Accepted 2 June 1993

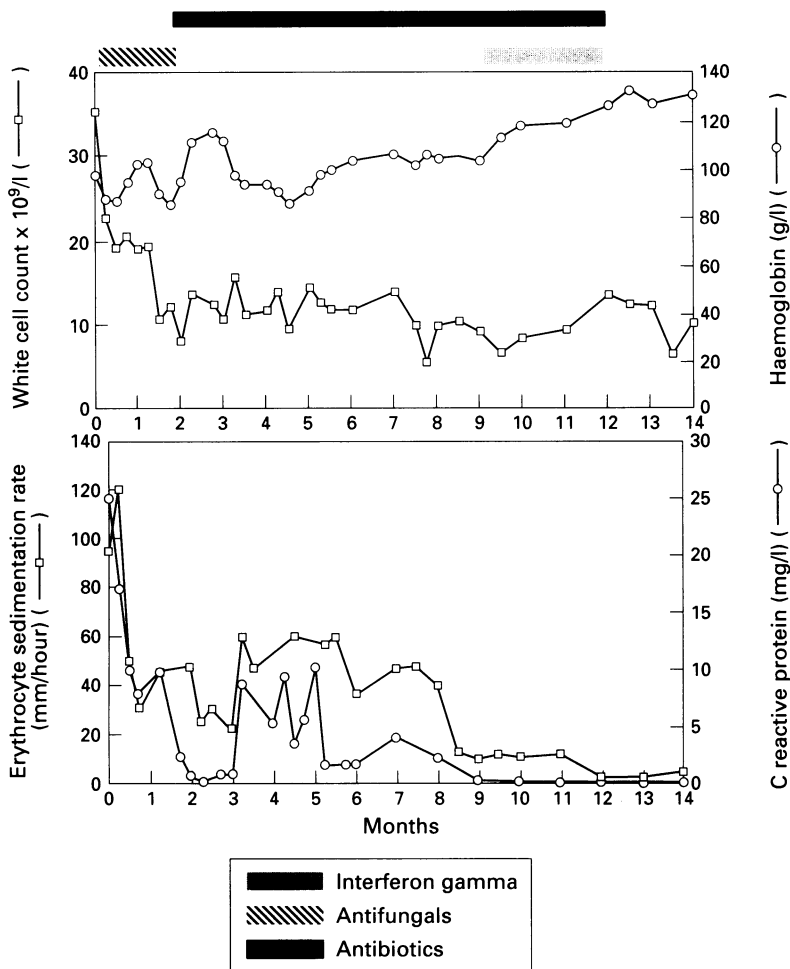


Figure 2 Serial values for white cell count, haemoglobin, erythrocyte sedimentation rate, and C reactive protein from time of presentation (time 0); the blocks indicate periods of time on intravenous treatment.

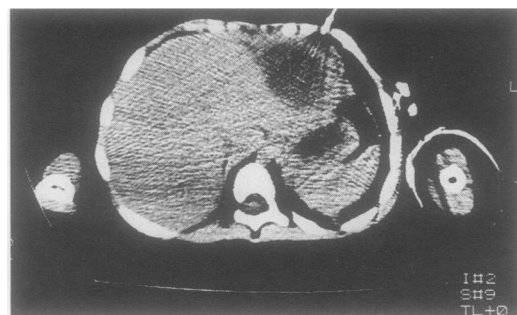


Figure 3 Computed tomogram showing single cavity in the left lobe of the liver.

(fig 1).<sup>13</sup> A nitroblue tetrazoleum test showed no dye reduction, and further investigation confirmed the diagnosis of X linked chronic granulomatous disease with complete absence of superoxide production.

A central venous catheter was placed, and he received intravenous flucytosine for four weeks and amphotericin for six weeks, followed by prophylaxis with oral itraconazole. Within 48 hours of commencing antifungal treatment his fever had resolved, and an ultrasound examination three weeks later was reported to be normal. However, his erythrocyte sedimentation rate and C reactive protein remained raised (fig 2). Six weeks later, he appeared septicaemic, with a fever of 40°C, rigors, vomiting, and abdominal pain. Again all

cultures were negative, but a computed tomogram showed a single abscess in the left lobe of the liver (fig 3). Aspiration revealed a pure growth of *S aureus*. His systemic symptoms responded to intravenous flucloxacillin and ceftazidime, but the abscess failed to resolve. A percutaneous drain was inserted, and pus discharged chronically, from which *S aureus*, *E coli*, *Pseudomonas aeruginosa*, and enterococcus species were isolated during the subsequent months when the abscess failed to resolve despite appropriate intravenous antibiotics. Eight months later a partial hepatectomy was planned, but at surgery a subphrenic extension was found, precluding a definitive surgical procedure, and drainage continued.

### Methods

Recombinant interferon gamma supplied by Boehringer Ingelheim was given three times a week via the central venous line at a dose of 0.05 mg/m<sup>2</sup> for three months. He was reviewed weekly throughout this period, and blood was taken for a full blood count, erythrocyte sedimentation rate, C reactive protein, lymphocyte subsets, and liver function tests on each visit.

### Results

No recurrence of systemic symptoms was observed from the start of interferon gamma, and he remained clinically well. Figure 2 shows the resulting rise in haemoglobin concentration and fall in erythrocyte sedimentation rate and C reactive protein to normal. No change in neutrophil, monocyte, or DR+ lymphocyte count was observed. A computed tomogram two months into treatment showed complete resolution of the abscess cavity, with a shrunken left lobe of the liver (fig 4). Interferon gamma was discontinued when his central venous catheter ceased to function after three months. Eighteen months later he remains totally asymptomatic on prophylactic cotrimoxazole and itraconazole.

### Discussion

Hepatic abscess occurs in 25%–40% of children with chronic granulomatous disease, and the mortality has been estimated at 27%.<sup>14</sup> Although aggressive surgical management and prolonged antibiotic treatment has been demonstrated to improve the prognosis, postoperative

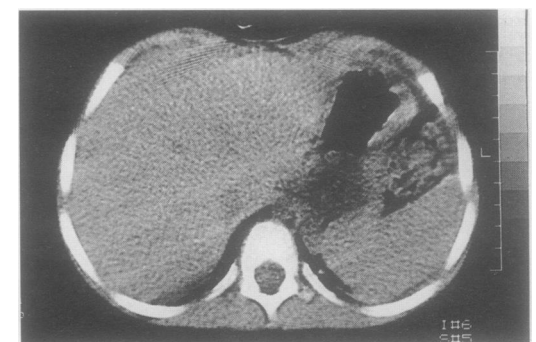

Figure 4 Computed tomogram after two months' interferon gamma showing resolution.

complications have been observed in 50% of cases and recurrence in 25%.<sup>15</sup> Percutaneous catheter drainage has been successful,<sup>16</sup> but failed in our case, and options for conventional methods of treatment had been exhausted.

The temporal relationship between the introduction of interferon gamma and resolution of the abscess is striking. Although a causal relationship is impossible to prove, and spontaneous resolution of such an abscess has been seen even after many months (A Fischer, personal communication), descriptions of improvement in other infectious complications of chronic granulomatous disease after interferon gamma treatment support this conclusion.<sup>9-12</sup> The mechanism, however, remains unclear. In vitro, interferon gamma substantially increases the level of phagocyte cytochrome *b* gene transcripts in normal polymorphonuclear leucocytes,<sup>17</sup> and it will increase NADPH oxidase activity in neutrophils from patients with a variant of chronic granulomatous disease who have suboptimal but not absent superoxide production.<sup>18</sup> Where there is a defect in the encoding gene that results in the absence of one of the essential subunit of the enzyme, however, no such increase can occur.<sup>18-20</sup> The multicentre trial of prophylactic interferon gamma failed to demonstrate any correlation between clinical benefit from interferon gamma and in vitro improvement in superoxide production.<sup>8</sup> Woodman *et al* have demonstrated that in some patients interferon gamma administration was associated with the appearance of a small population of circulating nitroblue tetrazoleum positive monocytes.<sup>19</sup> If this subpopulation were more predominant in tissue macrophages than in the circulation they could enhance bacterial killing in the tissues sufficiently to account for the observed effect of interferon gamma. Also, there are other respiratory burst independent mechanisms of bacterial killing, and neutrophils from patients with chronic granulomatous disease are capable of killing 80% of ingested *S aureus* in the absence of superoxide activity.<sup>21</sup> These mechanisms are poorly understood, and interferon gamma does not increase in non-oxidative antimicrobial proteins such as cathepsin G, azurocidine, p29b, and lactoferrin.<sup>20</sup> Possible mechanisms include stimulation of the enzymatic degradation of extracellular tryptophan, limiting the availability of iron, and enhancing nitrous oxide production, all of which appear to be interferon gamma dependent.<sup>4,22</sup>

In the controlled trial of the use of prophylactic subcutaneous interferon gamma, not all the cases enrolled were also receiving cotrimoxazole and/or itraconazole.<sup>8</sup> These oral antimicrobial agents are much cheaper and easier to administer, and it has been suggested that children already receiving these agents and who do not suffer frequent infections may get no further benefit from prophylactic interferon gamma.<sup>23</sup> Also, the long term sequelae of chronic stimulation of phagocyte cells with

interferon gamma are as yet unknown. Our case had added to the evidence that interferon gamma has a role in the treatment of acute infective episodes. A controlled trial to study the use of prophylactic antimicrobial treatment and intermittent interferon gamma during acute infection is now required.

We thank Boehringer Ingelheim for supplying recombinant interferon gamma and Mr Earnshaw, chief pharmacist, Newcastle General Hospital for arranging its supply.

- Curnette JT, Kuver R, Scott PG. Activation of neutrophil NADPH oxidase in a cell-free system: partial purification of components and characterisation of the activation process. *J Biol Chem* 1987; **262**: 563-9.
- Yang KD, Hill HR. Neutrophil function disorders: pathophysiology, prevention, and therapy. *J Pediatr* 1991; **119**: 343-54.
- Forrest CB, Forehand JR, Axtell RA, *et al*. Clinical features and current management of chronic granulomatous disease. *Hematol Oncol Clin North Am* 1988; **2**: 253-66.
- Murray HW. Interferon gamma, the activated macrophage, and host defence against bacterial challenge. *Ann Intern Med* 1988; **108**: 595-608.
- Nathan CF, Horowitz CR, de la Harpe J, *et al*. Administration of recombinant interferon gamma to cancer patients enhances monocyte secretion of hydrogen peroxide. *Proc Natl Acad Sci USA* 1985; **82**: 8686-90.
- Sechler JMG, Malech HL, White CJ, Gallin JJ. Recombinant interferon gamma reconstitutes defective phagocyte function in patients with chronic granulomatous disease of childhood. *Proc Natl Acad Sci USA* 1988; **85**: 4874-8.
- Ezekowitz RAB, Dinauer MC, Jaffe HS, *et al*. Partial correction of the phagocyte defect in patients with X-linked chronic granulomatous disease by subcutaneous interferon gamma. *N Engl J Med* 1988; **319**: 146-51.
- The International Chronic Granulomatous Disease Cooperative Study Group. A controlled trial of interferon gamma to prevent infection in chronic granulomatous disease. *N Engl J Med* 1991; **324**: 509-16.
- Johnston HC, Shigeoka AO, Hurlley DC, Fysher TJ. Nocardia pneumonia in a neonate with chronic granulomatous disease. *Pediatr Infect Dis J* 1989; **8**: 526-9.
- Goddard EA, Hughes EJ, Duys PJ, *et al*. Treatment of chronic granulomatous disease with recombinant gamma interferon. *S Afr Med J* 1992; **81**: 81-3.
- Phillips P, Forbes JC, Speert DP. Disseminated infection with *Pseudoallescheria boydii* in a patient with chronic granulomatous disease: response to gamma interferon plus antifungal therapy. *Pediatr Infect Dis J* 1991; **10**: 536-9.
- Bernhisel-Broadbent J, Camargo EE, Jaffe HS, Lederman HM. Recombinant human interferon gamma as adjunct therapy for aspergillus infection in a patient with chronic granulomatous disease. *J Infect Dis* 1991; **163**: 908-11.
- Pastakia B, Shawker TH, Thaler M, *et al*. Hepatosplenic candidiasis: wheels within wheels. *Radiology* 1988; **166**: 417-21.
- Chusid MJ. Pyogenic hepatic abscess in infancy and childhood. *Pediatrics* 1978; **62**: 554-9.
- Mulholland MW, Delaney JP, Simmons RL. Gastrointestinal complications of chronic granulomatous disease: surgical implications. *Surgery* 1983; **94**: 569-75.
- Skibber JM, Lotze MY, Garra B, Fauci A. Successful management of hepatic abscesses by percutaneous catheter drainage in chronic granulomatous disease. *Surgery* 1986; **99**: 626-9.
- Newburger PE, Ezekowitz AB, Whitney C, *et al*. Induction of phagocyte cytochrome b heavy chain gene expression by interferon gamma. *Proc Natl Acad Sci USA* 1988; **85**: 5215-9.
- Ezekowitz RAB, Orkin SH, Newburger PE. Recombinant interferon gamma augments phagocyte superoxide production and X-linked chronic granulomatous disease gene expression in X-linked variant chronic granulomatous disease. *J Clin Invest* 1987; **80**: 1009-16.
- Woodman RC, Erickson RW, Rae J, *et al*. Prolonged recombinant interferon gamma therapy in chronic granulomatous disease: evidence against enhanced neutrophil oxidase activity. *Blood* 1992; **79**: 1558-62.
- Muhlebach J, Gabay J, Nathan CF, *et al*. Treatment of patients with chronic granulomatous disease with recombinant human interferon gamma does not improve neutrophil oxidative metabolism, cytochrome *b<sub>558</sub>* content or levels of four antimicrobial proteins. *Clin Exp Immunol* 1992; **88**: 203-6.
- Segal AW, Harper AM, Garcia RC, Merzbach D. The action of cells from patients with chronic granulomatous disease on *Staphylococcus aureus*. *J Med Microbiol* 1982; **15**: 441-9.
- Kolb H, Kolb-Bachofen V. Nitric oxide: a pathogenetic factor in autoimmunity. *Immunol Today* 1992; **13**: 157-60.
- Mouy R, Seger R, Bourquin JP, *et al*. Interferon gamma for chronic granulomatous disease. *N Engl J Med* 1991; **325**: 1516.