

PERSONAL PRACTICE

Therapeutic bronchoscopy in ventilated neonates

Isi Dab, Anne Malfrout, Anita Goossens

In the past bronchial endoscopy needed rigid hollow bronchoscopes and until recently the technique was rarely used by paediatricians. Thin and ultrathin fibreoptic flexible bronchoscopes (FFBs) are now available and endoscopy is likely to be increasingly used. Despite the expected exponential expansion of endoscopies using FFB at any age for a growing number of indications, some conditions will continue to need rigid bronchoscopy.

Instruments available for babies and children**RIGID BRONCHOSCOPES**

Rigid bronchoscopes are rigid hollow stainless steel tubes. There are a variety of different lengths and widths in accordance with the children's age and size. The smallest one has an inner diameter of 2.5 mm and a length of 20 cm. The upper or proximal part is T shaped (fig 1A) with one central channel and two lateral channels. In the central channel one can insert various kinds of telescopes (fig 1B), either for a straightforward view, or for some more lateral views (30°, 70°, or 90° depending on how much the distal lens is tilted). The central channel allows various kinds of forceps (fig 1C) for biopsy or the removal of a foreign body. Unfortunately for the small baby rigid bronchoscope optical forceps are not available (small telescopes within the shaft of the forceps, the jaws of the latter being in front of the distal

lens). An aspiration catheter can also be inserted for the removal of secretions, tenacious mucus, or pus. One lateral channel is designed for ventilation and perhaps gas anaesthesia (fig 1D), the other for a prism (fig 1E) which projects light enabling inspection with the naked eye and without a telescope. To avoid burns the light source is at distance and light is transmitted through a Y shaped cable (fig 1F) consisting of large bundles of optical fibres: one proximal tip is connected to the lateral prism for proximal light projection and the other to the telescope for distal light projection.

The diameter of the telescope needs to be smaller than the inner diameter of the rigid bronchoscope used and they should never be shorter than the total length of the bronchoscope, though they may be longer. A large rigid bronchoscope will not pass through a small glottis and a small one will be too short to reach the bronchi in a larger child. Several bronchoscopes are thus needed and for each length at least two or three telescopes.

The only way to insert the rigid bronchoscope is through the mouth. The jaws need to be opened with a retractor or a laryngoscope. As this would be rather painful, even after local anaesthesia, narcosis is the rule. The bronchoscope progresses through the pharynx and the glottis, whether or not the telescope is connected. As stainless steel tubes are not flexible they can enter into the trachea, into the two main bronchi and into the lower lobe bronchi, and in general not into the upper orifices and only with difficulty into the middle lobe orifice. Another limitation is that the rigid bronchoscope cannot pass beyond the level where its outer diameter reaches that of the bronchial lumen, and this might be short after the carina in small premature babies. If, however, the telescope is some centimetres longer than the bronchoscope deeper inspection remains feasible. The lateral inaccessible large orifices can be partly inspected because of the relatively large field of vision of the straightforward telescopes and very clearly with telescopes with the more laterally tilted distal lenses.

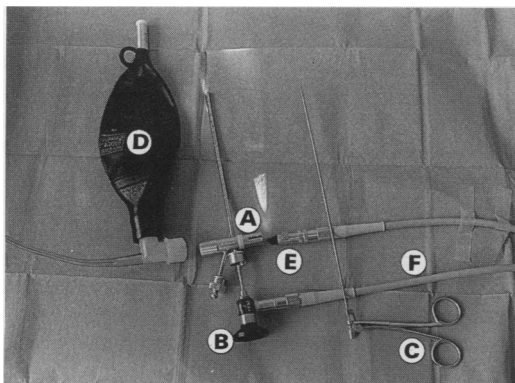


Figure 1 Rigid bronchoscope with the T shaped proximal part and a central channel and two lateral channels (A). Telescope in the central channel (B); forceps (C); one lateral channel for ventilation with a bag or with a mechanical ventilator and perhaps gas anaesthesia (D). The other lateral channel is aimed for the prism that projects the light into the airways through the lumen of the bronchoscope (E). Y shaped cable that conducts the light from an external source onto the prism and onto the telescope (F).

Academisch
Kinderziekenhuis,
Vrije Universiteit
Brussel, Brussels,
Belgium, Department
of Paediatrics,
Paediatric
Pulmonology, and
Cystic Fibrosis Clinic
Isi Dab
Anne Malfrout

Department of
Pathology
Anita Goossens

Correspondence and reprint requests to: Professor I Dab, Department of Paediatrics, Respiratory and Cystic Fibrosis Clinic, Academisch Kinderziekenhuis, Vrije Universiteit Brussel (VUB), Laabeeklaan 101, B-1090 Brussels, Belgium.

FIBREOPTIC FLEXIBLE BRONCHOSCOPES

FFBs became available at the end of the 1960s, however the size of the first ones were not suitable for paediatric use. Subsequently, smaller FFBs with a diameter of 3.5 mm and an aspiration channel of 1.2 mm were designed that could be used even in small children.

More recently ultrathin FFBs with a diameter of only 2.2 mm and provided with a dirigible distal tip became available. They are for very small premature babies or small children with very severe stenoses through which a standard FFB would not pass. They lack, however, an aspiration channel.

FFBs are closed tubes in contrast to hollow rigid bronchoscopes. The diameter of a paediatric FFB is smaller than the outer diameter of any rigid bronchoscope. FFBs can be inserted through the nose or mouth. Because the 3.5 mm FFB, except for a small aspiration channel, has no passage dyspnoea may occur in small babies when the size approaches the diameter of the glottis channel; time available for inspection is then rather restricted and oxygen saturation needs to be continuously monitored. Because of its flexibility and its dirigible tip, once in the airways, the FFB can be directed deep into many bronchi even in more laterally situated ones.

The 1.2 mm wide aspiration channel of the 3.5 FFB is enough for the removal of not too sticky secretions but insufficient for the insertion of forceps. When the distal lens is blotted with secretions and hinder inspection, simple aspiration through this channel, or rinsing first with a few instilled drops of saline, will restore the vision immediately. The channel can also be used for the instillation of drugs.

Another advantage of FFBs is that in expert hands narcosis is rarely needed. In older children bronchoscopy can be performed while the child is sitting and only local anaesthesia is needed after the procedure has been explained. Smaller children need to be recumbent and slight and short sedation together with local anaesthesia are enough.

With only one 3.5 mm sized and one 2.2 mm sized FFB, one can perform endoscopies at any age as their length is suitable even for adults. Thorough inspection of many deep and small orifices and even very lateral ones are feasible, but the removal of solid material remains impossible.

Proposal for bronchoscopy in ventilated neonates and methodology

(A) FLEXIBLE BRONCHOSCOPY

Small premature babies are prone to various kinds of severe respiratory complications such as, for example, large areas of consolidation sometimes associated with uncontrollable severe hypoxaemia. When this occurs one can easily first inspect the airways with the smallest 2.2 mm FFB, without interrupting the mechanical ventilation and without the infant leaving the incubator. For this purpose one has to connect the endotracheal tube with the distal part of the ventilation tube using a swivel Y connector (fig 2) for uninterrupted bronchoscopy (Vygon, Ecouen, France code 526.01). Inspection can then be made comfortably without a time limit and it will indicate whether sticky mucus or solid material occlude a large airway. When the inspection is hindered by secretions the FFB can be replaced momentarily with a suction catheter. If sticky dried secretions, tumoral

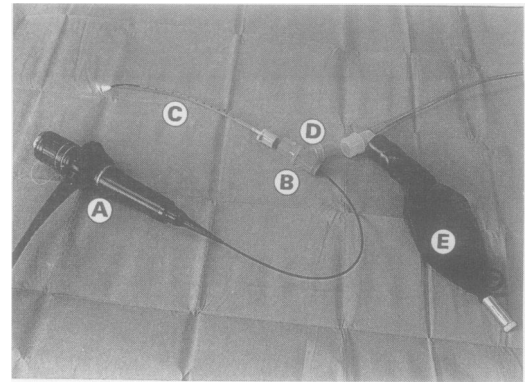


Figure 2 A 2.2 mm FFB (A) passing through a Y swivel (B) connected to an endotracheal tube size 3 (C). The oblique lateral orifice (D) is for the connection with either a ventilation bag (E) or a mechanical ventilator.

processes, or stenoses are present these need to be removed for the patency of the airways and this can only be achieved by rigid bronchoscopy with adapted forceps.

(B) RIGID BRONCHOSCOPY

Many ventilated premature infants will be sedated anyway to facilitate mechanical ventilation. This also meets the requirements for rigid bronchoscopy. In addition, and before starting rigid bronchoscopy, one can hyperventilate the infant for a while to improve oxygenation and to try to produce hypocapnia. In small premature babies or neonates rigid bronchoscopy can be performed without general anaesthesia in the neonatal unit itself, the baby being outside the incubator under a radiant heater. Artificial ventilation with selected concentrations of oxygen can easily be applied, either with a balloon or with the ventilator connected to one of the proximal lateral channels (fig 1D). Depending on the size of the baby you can select a 2.5 mm or a 3 mm bronchoscope and introduce it together with the telescope. As soon as the abnormality is encountered therapeutic manoeuvres are implemented.

Examples of rigid bronchoscopy in ventilated neonates

PATIENTS AND METHODS

Twenty neonates (18 premature and two nearly term babies) were selected for rigid bronchoscopy over a three year period. All 20 had severe bronchial abnormalities and seven of them suffered more than one abnormality in combination (table) that could not be removed by blind catheter suction. Gestational age varied from 27 to 40 weeks and their birth weight from 810 to 3000 g. Ventilation was still in progress and lasted for five to 43 days. All had suffered moderate or severe respiratory distress syndrome at birth. All procedures were performed because the babies had suddenly developed one or both of the following conditions: (i) uncontrollable blood gas deterioration despite 100% oxygen administration and high ventilator settings and/or (ii) suspicion of mechanical airway obstruction on radiography.

Endoscopic abnormalities and therapeutic procedures

Abnormality*	No	Procedure	No	Success	Failure
Sticky mucous plugs	10	Selective bronchial lavage with mesna	10	10	0
Tracheal masses	3	Total resection	2	2	0
		Local hydrocortisone	1	1	0
Bronchial masses	7	Resection	1	1	0
		Local hydrocortisone	6	2	4
Bronchial stenosis	7	Local hydrocortisone	7	3	4
		Dilatation	3	3	0

*Seven patients had more than one abnormality.

The babies were extubated and the rigid bronchoscope was inserted at once. The patency of the extubated endotracheal tube was examined by an assistant. Assisted ventilation with 100% oxygen was continued either manually with the bag or with the mechanical ventilator connected onto the lateral channel of the rigid bronchoscope. Heart rate and transcutaneous oxygen saturation were monitored during bronchoscopy. At the end of the bronchoscopy the patient was reintubated with a new sterile transnasal endotracheal tube. Rigid bronchoscopes size 3 or 2.5 mm were used (Karl Storz GmbH, Tuttlingen, Germany) together with the smallest Hopkins telescope. The following instruments were always within arm's reach: (1) Various Storz grasping forceps for cutting masses or granulation tissue. (2) Suction catheters (De Lee type, Vygon) to instil precisely either mesna (Mistabron, UCB-Pharma, Brussels, Belgium), a mucolytic substance that was diluted with the same amount of a saline solution, or 1 ml of a 5% solution of hydrocortisone. (3) Angioplasty balloon catheters (coronary dilation catheter with a balloon diameter of 3 mm, Monorail Bonzel, Schneider-Shiley AG European Division, Zurich, Switzerland) for dilating bronchial stenoses.

Manipulations of the forceps and the suction catheter was performed mainly with naked eye control with the light coming from the lateral prism (fig 1E). Occasionally the forceps and the telescope were introduced simultaneously for improved precision. This, however, produced occlusion of an important part of the lumen of the bronchoscope and hindered the ventilation. Instruments then needed to be repeatedly removed because of deteriorating transcutaneous blood gas measurements or because of falls in the heart rate. Manipulations with the balloon catheter were always performed by simultaneously inserting the optic telescope to steer the former with the tip of the latter and adjust it correctly.

RESULTS

Altogether 48 rigid bronchoscopies were performed and in each patient the procedure was achieved between one to 10 times with a median of two per patient. If more than one bronchoscopy was needed on the same day, they were counted as a single examination. Occasional oxygen desaturation during the manoeuvre was reduced by removing the telescope and other instruments until the condition improved by ventilating through the lumen of the bronchoscope. Oral bleeding

occurred rarely and never exceeded a few drops. No other adverse effects were noticed.

Therapeutic procedures

Methods were adapted to the observed abnormalities and to their location (table). Clinically and radiologically the immediate results of the different applied therapeutic procedures were fair to excellent in 15 of the 20 patients and had little or no desirable effect in five patients (table).

Bronchial lavage with mesna instilled selectively was successful in all 10 patients with mucus plugs or casts. The complete resection with forceps of an obstructive mass (fig 3) was possible in three patients and resulted in an immediate restoration of the blood gases. In the remaining seven patients the masses were not within the reach of the forceps, either because they were deep in the right main bronchus or lateral in the upper right bronchus, or because the jaws of the forceps could not be opened sufficiently in the narrow bronchial lumen. In the latter situation 50 mg of hydrocortisone was locally instilled through a catheter pointed on the obstructive mass. In three of these seven patients both the blood gases and the chest radiograph showed an improvement within 24 hours and on subsequent bronchoscopy the granulation tissue had disappeared. Altogether six of the 10 patients with an endobronchial mass improved after endoscopy. Of the remaining patients three

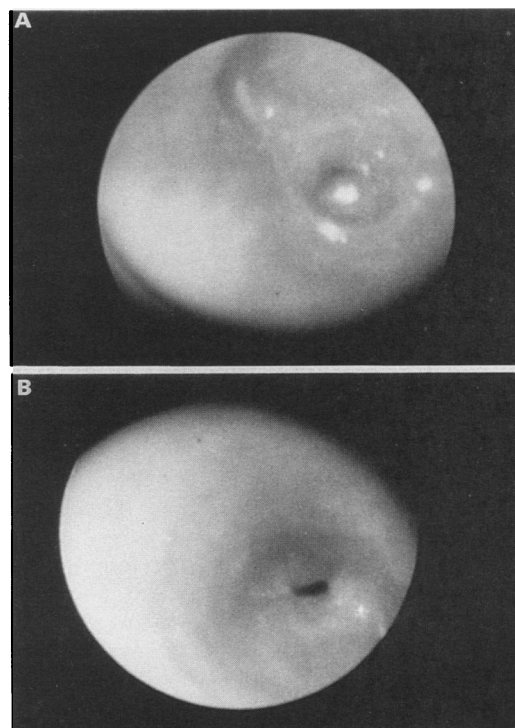


Figure 3 (A) Endoscopic view showing how severely intraluminal granulation tissue can hinder the ventilation. This lesion is located in the right main bronchus. (B) The same view immediately after partial resection of the granulation tissue showing a residual stenosis. Complete patency was ultimately restored after local instillation of hydrocortisone. (These pictures were taken under very uncomfortable conditions and the semilunar shadows obscuring a part of these are due to the lean of the camera levering the very thin shaft of the Hopkins rod transiently off centre.)

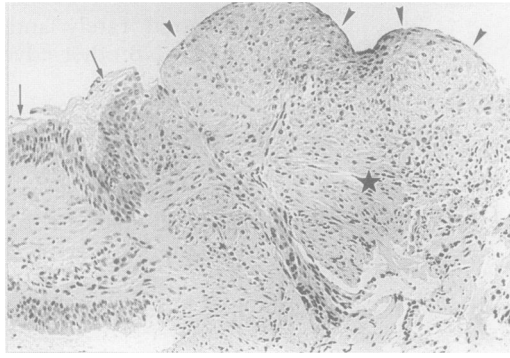


Figure 4 Resected specimen with preservation of the normal respiratory epithelium at the margins (arrows), formation of granulation tissue with absence of the epithelium (arrowheads), and a scar lesion in the depth of the specimen (star).

died between three and 40 days later and one survived with a persisting atelectasis of the right upper lobe one year later. The local instillation of hydrocortisone, as described above, was successful in three of the seven patients with bronchial stenosis.

Angioplasty balloon catheter dilation could be performed in three infants with a main stem stenosis (fig 3B). They underwent respectively three, seven, and 10 bronchoscopies on different days, that is, increasing the pressure of the balloon each time until the lumen of the orifice remained sufficiently patent. The chest radiograph and blood gases showed improvement in all three patients. Ultimately six of the seven stenoses were successfully and completely relieved. The complete stenosis of the right upper bronchus in the fourth patient was out of reach of the catheter because of its lateral localisation in an already small lumen. He survived with a complete and permanent atelectasis of the right upper lobe.

Pathology

Microscopic examination of the resected specimens showed granulation tissue without a covering respiratory epithelium (fig 4). This granulation tissue was already organised and contained many plump fibroblasts but few inflammatory cells. In the depth of the lesion, collagen was lying as bundles in a parallel arrangement, as a resolving scar lesion.

Postmortem examinations

Altogether eight of 20 patients died between three weeks and six months after birth and between three and 372 days after the last bronchoscopy. Postmortem findings were available for two boys and two girls. The weight at death varied from 1275 g to 2330 g and the age from 27 days to 3 months. In one patient in whom a granuloma was resected and who died 21 days after the endoscopy, a small scar was present at the resection site without ulceration. In none of the others could any sequelae be observed that could be attributed to the bronchoscopy. No residual material remained in any bronchus. The fatal outcomes could be explained by the following findings:

one had hepatised lungs and signs of severe cardiac failure with organ congestion, one had multiple malformations including cerebral abnormalities, and two had generalised haemorrhages with thrombosis of the vena cava and of the right atrium in one patient.

DISCUSSION

Rigid bronchoscopy has always been used in paediatrics for the removal of foreign bodies,¹⁻⁴ though it has rarely been performed by paediatricians themselves. In the future bronchoscopy will become one of the basic tools in paediatric pulmonology with an increasing spectrum of indications even in neonates.⁵⁻⁹ Our experience confirms that even in neonatology an FFB is an excellent and safe diagnostic tool. Ultrathin FFBs can pass through an endotracheal tube as small as 3 mm. They offer the possibility of rapid inspection of the airways thereby avoiding the risk of extubation and reintubation.⁵ Ultrathin FFBs may be routinely used in the future in all ventilated neonates as a part of the daily monitoring. It should help neonatologists to anticipate the occurrence of airway obstruction before it becomes too severe. On the other hand rigid bronchoscopy remains the method of choice for therapeutic manoeuvres even if it is preceded by an FFB for rapid diagnosis.

Obstructive tracheal injury and necrotising tracheobronchitis, the extreme form of this injury, have been described as potential complications of prolonged endotracheal intubation and ventilation.¹⁰⁻¹² Multiple aetiological factors have been incriminated such as high ambient oxygen concentrations, lack of adequate humidification, ventilatory frequency, and suction method.¹² Whatever the origin of the accumulation of necrotic debris or other forms of bronchial obstruction, they can be observed only by endoscopy, and airway patency must be achieved as soon as possible. If one does not succeed with blind suction rigid bronchoscopy will be mandatory.

Obstructive masses yield best results by resection at the time that they are within the reach of the forceps. One can try with some hope of success local and selective instillation of hydrocortisone in order to reduce inflammation and mucosal oedema of the inaccessible mass, as pathological examination shows that it can be due to a non-specific inflammatory reaction. Steroid treatment is not new as prolonged parenteral corticoid treatment has been used before in respirator dependent premature infants with acquired lobar emphysema¹³ and with other sequelae of bronchodysplasia.¹⁴ However, topical treatment might have fewer side effects.

For the most severe circular stenoses local hydrocortisone is less effective. In these circumstances frequent bronchoscopies are needed to perform stepwise balloon catheter dilations, that is increasing the pressure of the balloon during each new bronchoscopy to restore airway patency. No comparative studies have been performed to determine whether the same result could be achieved with

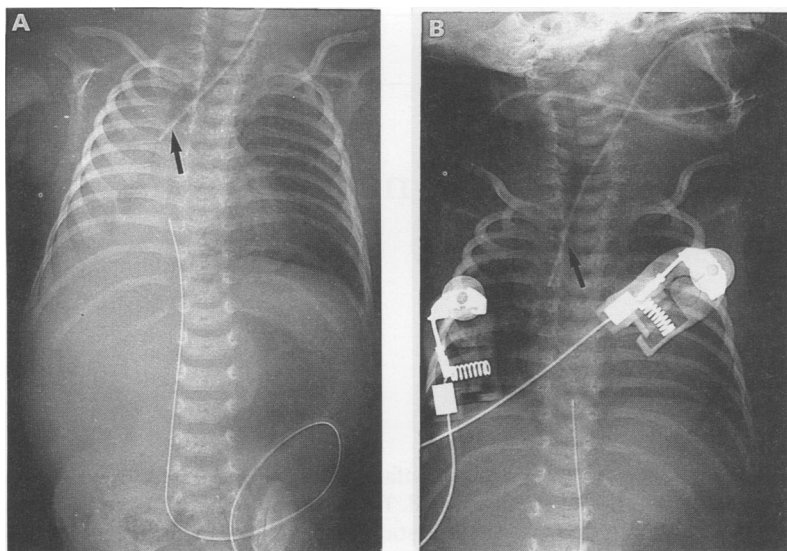


Figure 5 (A) Chest radiograph of the baby with the most severe stenosis of the right main bronchus. Stenosis reappeared immediately after each balloon catheter dilation, so that the inflated balloon catheter was left in place during 24 hours (arrow). Intermittent injection of oxygen or air through the central channel across the balloon prevented pulmonary collapse. (B) After 24 hours the ventilation of the right lung was permanently restored and the catheter could be removed.

maximal dilation during one session. Catheter balloon dilations are usually performed to dilate narrowing in arteries, in ureters or in the gastrointestinal tract, and were found by us to be also effective for the relief of bronchial stenoses. A major advantage of angioplasty catheters is that these have a central channel through which air or oxygen can enter and reinflate the collapsed lobe or lung while dilation is still in process (fig 5).

Cohen *et al*¹⁵ and Grylack and Anderson¹⁶ in 1984 and Groff and Allen¹⁷ in 1985 were the first to report single cases of tracheo-bronchial stenosis relieved successfully by balloon dilation. Cohen used fluoroscopy after injection of contrast to display the stenosis and did not use rigid bronchoscopy or an FFB. However, bronchography with contrast is not recommended in the very ill premature infant for safety reasons. Furthermore, in all three reported cases therapeutic manoeuvres needed to be postponed until the age of 3 to 6 months. Hautf *et al* in 1988 were the first to report tracheal stenosis in six premature babies and were also the first to use rigid bronchoscopy for its diagnosis shortly after birth.¹⁸ An attempt to dilate the acquired tracheal stenosis was made in three infants by forcing the rigid bronchoscope through the stenosis or by tracheoplasty in the other three. Only two of the six survived these aggressive procedures. The use of a

balloon is safer than rigid bronchoscopy alone for dilation, the former is less aggressive and more selective and can be applied immediately in the neonatal period.

Conclusion

This study corroborated the therapeutic advantages offered by rigid bronchoscopy in ventilated neonates and premature infants who developed sudden obstructive hypoxaemia. Immediate results of therapeutic procedures on blood gas values and on radiographs were very encouraging on 15 of 20 patients with abnormal endoscopic findings. Tolerance and safety are excellent, as confirmed by the post-mortem analyses.

Parts of this article were presented at the 1990 Meeting of the European Paediatric Respiratory Society (EPRS), September 1990, London.

- 1 Landa JF. Indications for bronchoscopy. *Chest* 1978; 73: 686-90.
- 2 Berci G. Flexible fiber and rigid pediatric bronchoscopic instrumentation and documentation. Quo vadis? *Chest* 1978; 73: 768-75.
- 3 Sherman JM. Rigid or flexible bronchoscopy in children. *Pediatr Pulmonol* 1987; 3: 141-2.
- 4 Godfrey S, Springer C, Maayan E, Avital A, Vatascky E, Belin B. Is there a place for rigid bronchoscopy in the management of pediatric lung disease. *Pediatr Pulmonol* 1987; 3: 179-84.
- 5 Wood RE. The diagnostic effectiveness of the flexible bronchoscope in children. *Pediatr Pulmonol* 1985; 1: 188-92.
- 6 Wood RE, Postma D. Endoscopy of the airway in infants and children. *J Pediatr* 1988; 112: 1-6.
- 7 Finer NM, Etches PC. Fiberoptic bronchoscopy in the neonate. *Pediatr Pulmonol* 1989; 7: 116-20.
- 8 Schelbase DE, Graham LM, Fix EJ, Sparks LM, Fan LL. Diagnosis of tracheal injury in mechanically ventilated premature infants by flexible bronchoscopy. *Chest* 1990; 98: 1219-25.
- 9 Cohn RC, Kerckmar C, Dearborn D. Safety and efficacy of flexible endoscopy in children with bronchopulmonary dysplasia. *Am J Dis Child* 1988; 142: 1225-8.
- 10 Clark RH, Wiswell TE, Null DM, Delemos RA, Coalson JJ. Tracheal and bronchial injury in high-frequency oscillatory ventilation compared with conventional positive pressure ventilation. *J Pediatr* 1987; 111: 114-8.
- 11 Boros SJ, Mammel MC, Lewallen PK, Coleman JM, Gordon MJ, Ophoven J. Necrotizing tracheobronchitis: a complication of high-frequency ventilation. *J Pediatr* 1986; 109: 95-100.
- 12 Wiswell TE, Turner BS, Bley JA, Fritz DL, Hunt RE. Determinants of tracheobronchial histologic alterations during conventional mechanical ventilation. *Pediatrics* 1989; 84: 304-11.
- 13 Mohsini K, Reid D, Transwell K. Resolution of acquired lobar emphysema with dexamethasone therapy. *J Pediatr* 1987; 111: 901-4.
- 14 Avery GB, Fletcher AB, Kaplan M, Brudno DS. Controlled trial of dexamethasone in respirator dependent infants with bronchopulmonary dysplasia. *Pediatrics* 1985; 75: 106-11.
- 15 Cohen MD, Weber TR, Rao CC. Balloon dilation of tracheal and bronchial stenosis. *AJR* 1984; 142: 477-8.
- 16 Grylack LJ, Anderson KD. Diagnosis and treatment of traumatic granuloma in tracheobronchial tree of newborn with history of chronic intubation. *J Pediatr Surgery* 1984; 19: 200-1.
- 17 Groff DB, Allen JK. Gruentzig balloon catheter dilation for acquired bronchial stenosis in an infant. *Ann Thorac Surg* 1985; 39: 379-81.
- 18 Hautf SM, Perlman JM, Siegel MG, Muntz HR. Tracheal stenosis in the sick premature infant. *Am J Dis Child* 1988; 142: 206-9.