

LETTERS TO THE EDITOR

- *The British Heart Journal welcomes letters commenting on papers that it has published within the past six months.*
- *All letters must be typed with double spacing and signed by all authors.*
- *No letter should be more than 600 words.*
- *In general, no letter should contain more than six references (also typed with double spacing).*

Limitations of transoesophageal echocardiography in patients with focal cerebral ischaemic events

SIR—In their study of patients with focal cerebral ischaemic events, de Belder and colleagues¹ showed that transoesophageal echocardiography confirmed the findings of transthoracic echocardiography and detected additional abnormalities. In each case the transthoracic echocardiography was performed before transoesophageal echocardiography. The echocardiograms were interpreted by someone who had not been involved with imaging and who was blind to clinical information. Was the person who reported the transoesophageal echocardiogram blinded to the result of the transthoracic echocardiogram? Was the transoesophageal operator also blinded to the transthoracic result? A lack of blinding might mean that the transoesophageal operator would try harder to demonstrate a lesion he knew to be present and the transoesophageal reporter would look harder to find a lesion he already knew to be present from the transthoracic echocardiogram. While this would mimic the clinical situation it does not tell us anything about the relative sensitivities of the two techniques which can only be determined if the results from each technique are obtained entirely blind to the results of the other.

The main difference between transoesophageal and transthoracic echocardiography in this study was that transoesophageal echocardiography picked up more right-to-left shunts (23% v 7%). Was this failure to demonstrate by transthoracic echocardiography two thirds of the shunts, which seem to be present, the result of their technique? Others using more aggressive protocols and transthoracic echocardiography have shown an incidence of shunts in healthy individuals similar to that found by de Belder *et al* with transoesophageal echocardiography.^{2,3} Alternatively could it be that the shunts found by de Belder *et al* by transthoracic echocardiography were larger (both anatomically and functionally) and therefore the ones most likely to have implications for aetiology of cerebral ischaemic events in their patients?

PETER WILMSHURST
Huddersfield Royal Infirmary,
Acre Street,
Lindley,
Huddersfield HD3 3EA

- 1 de Belder MA, Lovat LB, Tourikis L, Leech G, Camm AJ. Limitations of transoesophageal echocardiography in patients with focal cerebral ischaemic events. *Br Heart J* 1992;67:297-303.
- 2 Wilmshurst PT, Byrne JC, Webb-Peploe MM. Relation between interatrial shunts and decompression sickness in divers. *Lancet* 1989;ii:1302-6.
- 3 Cross SJ, Evans SA, Thomson LF, Lee HS, Jennings KP, Shields TG. Safety of sub-aqua diving with a patent foramen ovale. *BMJ* 1992;304:481-2.

SIR—de Belder *et al* make the point that transthoracic and transoesophageal echocardiography may have a limited role in the evaluation of patients with transient ischaemic attacks and stroke. Though their analysis of the echocardiographic findings referable to the heart was thorough, they did not rotate the transoesophageal echocardiography probe towards the thoracic aorta. So they did not identify raised plaques with superimposed thrombus in the aortic arch, which are an important factor in patients with neurological events. In 1990 we reported three patients who had emboli in whom such raised thrombotic plaques were seen on transoesophageal echocardiography,¹ and the following year we showed in a case-control study that these lesions are associated with cerebral and peripheral embolic disease.² Others have reported this association too.^{3,4} A large necropsy study has found ulcerated plaques in the aortic arch of patients dying from stroke, in the same area as that in which raised thrombotic plaques (which may have mobile components indicative of superimposed thrombi) are seen on transoesophageal echocardiography.⁵ In a recent analysis, we found that rather than being of limited use, the most important advantage that transoesophageal echocardiography has over transthoracic echocardiography in patients with embolic disease is the ability to diagnose raised thrombotic plaques in the thoracic aorta.⁶ Therefore we think that transoesophageal echocardiography is indicated in all patients with otherwise unexplained embolic disease, and it may even have a role in the evaluation of patients with strokes of other presumed aetiology.

PAUL A TUNICK
ITZHAK KRONZON
Non-invasive Cardiology Laboratory,
New York University Medical Center,
560 First Avenue,
New York, NY 10016, USA

- 1 Tunick PA, Kronzon I. Protruding atherosclerotic plaque in the aortic arch of patients with systemic embolization: a new finding seen by transoesophageal echocardiography. *Am Heart J* 1990;120:658-60.
- 2 Tunick PA, Perez JL, Kronzon I. Protruding Atheromas in the Thoracic Aorta and Systemic Embolization. *Ann Intern Med* 1991; 115:423-7.
- 3 Pop G, Sutherland GR, Koudstaal PJ, Sit TW, de Jong G, Roelandt JR. Transoesophageal echocardiography in the detection of intracardiac embolic sources in patients with transient ischaemic attacks. *Stroke* 1990;21:560-5.
- 4 Karalis DG, Chandrasekaran K, Victor MF, Ross JJ, Mintz GS. The recognition and embolic potential of intraaortic atherosclerotic debris. *J Am Coll Cardiol* 1991; 17:73-8.
- 5 Amarenco P, Duyckaerts C, Tzourino C, Héning D, Boussier M-G, Hauw J-J. Prevalence of ulcerated plaques in the aortic arch in patients with stroke. *N Engl Med J* 1992;326:221-5.
- 6 Tunick PA, Kronzon I. The improved yield of transoesophageal echocardiography over transthoracic echocardiography in patients with neurologic events is largely due to the detection of aortic arch protruding atheromas. *Echocardiography* 1992;9:491-5.

These letters were shown to the author, who replies as follows:

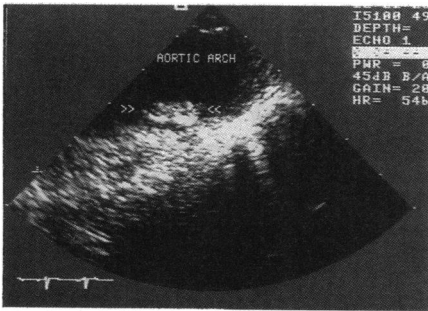
SIR—Peter Wilmshurst reminds us about the care needed in determining the relevant sensitivities of different echocardiographic techniques. Some of our patients underwent both precordial and transoesophageal echocardiography at the same visit. The studies were recorded on video tape and were thereafter reported by the individual who was blinded to the clinical details of the patients. In all instances, the precordial study was reported first. Dr Wilmshurst is correct in stating that the interpreter of the transoesophageal studies would not have been blinded to the interpretation of the transthoracic result in these cases. We do not believe, however, that the interpreter tried harder to detect abnormalities in those patients in whom the transthoracic study had already demonstrated them.

We do not believe that poor technique led to the low transthoracic pick-up of right-to-left shunts in these patients. Indeed, four to six precordial contrast studies were performed before a patient was defined as having no shunt. These were a mitral valve level M mode study and an apical four chamber or subcostal cross sectional study (and in many cases both), all of which were done before and during a Valsalva manoeuvre. We agree with the suggestion that the less common larger shunts, related to what Thompson and Evans referred to as “pencil” patency (as opposed to “probe” patency) of the foramen ovale¹ may be more likely to give rise to paradoxical embolic events. It may be that these are the shunts that are detectable from the precordium. These hypothetical thoughts are difficult to prove because there are no means of determining the size of a patent foramen ovale in vivo, nor of accurately determining the size of the associated (and variable) shunt.

The point of our paper, however, was not to give accurate data on the relative sensitivities of precordial and transoesophageal echocardiography in these patients. Given the drawbacks of precordial echocardiography that are overcome with the transoesophageal technique, it should be no surprise to anyone that the transoesophageal technique detects more abnormalities. This has now been demonstrated in numerous studies. Our point was that many of the abnormalities came as no surprise with the major exception of right-to-left shunts. Moreover, until we have some proven treatments to minimise recurrence rates when a patent foramen ovale or spontaneous contrast echoes are detected, we believe that the detection of such abnormalities may be of little value for the patient.

Paul Tunick and Itzhak Kronzon are wrong in assuming that we did not scan the aorta in our patients. We did—in all cases. We acknowledge their work on the possible relevance of raised thrombotic plaques in the aortic arch. However, in their initial series of three case reports,² case 1 was in atrial fibrillation and they cannot be sure that the cerebral event was related to the aortic lesion. In addition, the figure showing the lesion in case 1 was taken from the distal part of the arch; it is difficult to see how an embolus from this area would lodge in a cerebral vessel. Case 3 had severe carotid disease as well as the aortic lesion.

Tunick *et al* in a more detailed case-control study³ provided rather more convincing evidence that raised thrombotic plaques in the aortic arch are associated with embolic



A transverse plane transoesophageal echocardiogram showing a protruding mass consistent with an atheromatous plaque in the middle part of the aortic arch. This was the only abnormality detected that could explain a recent cerebrovascular event.

events. However, their study was limited by the inclusion of patients with peripheral embolic events, by the lack of data on the size, morphology, and exact position of the atheromatous plaques and because they compared their cases with controls with cardiac disease. In addition, the sensitivity of the transoesophageal technique for aortic arch disease is unknown. Their data were, however, suggestive of a genuine association between the aortic arch lesions and cerebral embolism, although they do not demonstrate cause and effect. We recently performed transoesophageal echocardiography on a 57 year old man with no obvious cause of a stroke, in whom the only abnormality was a protruding plaque in the middle part of the arch (fig). However, such a gross abnormality was not seen in the patients reported in our recent study. We did see evidence of much less dramatic aortic arch atheroma in a few of these patients, but not in enough of them to convince us of its pathogenic relevance, and usually the patient had clinical or carotid ultrasound evidence of diffuse atheromatous disease. We have seen other patients with a peripheral embolic event who had clear evidence of protruding and mobile thrombotic plaques in the descending aorta. We agree with Tunick and Kronzon that these abnormalities would not be detected by precordial echocardiography and are worth seeking. We still, however, have no data on optimum treatment for such patients. Although Tunick *et al* have, somewhat radically, removed a protruding plaque in one patient,⁴ this treatment cannot be recommended for all such patients.

Transoesophageal echocardiography did show interesting abnormalities in these patients that cannot be detected by conventional precordial echocardiography. However, it may not be possible to demonstrate anything more than an association of certain abnormalities with clinical events. The accumulating data on the patency of the foramen ovale, spontaneous contrast echoes, and atheromatous aortic disease do suggest a possible pathogenic role for these features in embolic events. We should now use this technique to evaluate treatments that might reduce the recurrence rate of embolic events in these patients.

MARK DE BELDER
Regional Cardiothoracic Unit,
St George's Hospital, Blackshaw Road,
London SW17 0QT

- 1 Thompson T, Evans W. Paradoxical embolism. *Q J Med* 1930;23:135-50.
- 2 Tunick PA, Kronzon I. Protruding atherosclerotic plaque in the aortic arch of patients with systemic embolization: A new finding seen by transoesophageal echocardiography.

Am Heart J 1990;120:658-60.

- 3 Tunick PA, Perez JL, Kronzon I. Protruding atheromas in the thoracic aorta and systemic embolization. *Ann Intern Med* 1991;115:423-7.
- 4 Tunick PA, Culliford AT, Lamparello PJ, Kronzon I. Atheromatosis of the aortic arch as an occult source of multiple systemic emboli. *Ann Intern Med* 1991;114:391-2.

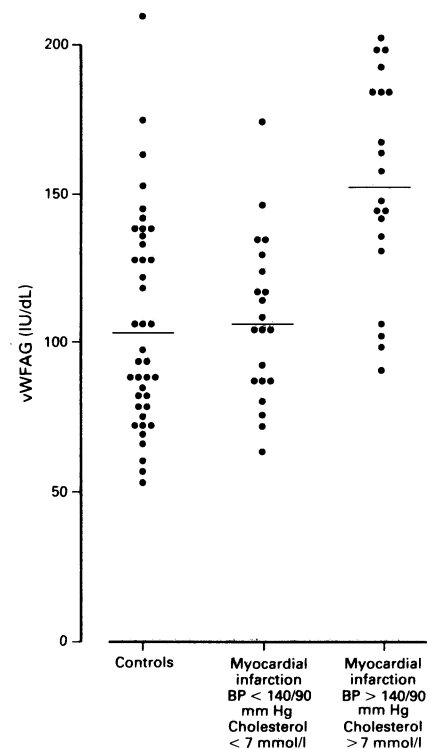
von Willebrand factor in plasma: a novel risk factor for recurrent myocardial infarction and death

SIR—Raised concentrations of von Willebrand factor antigen (vWFAg), a specific product of the endothelium) reflect damage to the endothelium. Jansson *et al* (*British Heart Journal* 1991;66:351-5) reported that high concentrations of vWFAg are present in ischaemic heart disease and predict reinfarction and mortality in survivors of myocardial infarction. Among the 123 survivors entering their study there were 88 cases of hypertension, diabetes mellitus, and smoking. Furthermore, the mean cholesterol concentration was 7 mmol/l, indicating hypocholesterolaemia in an unspecified number of patients.

Jansson *et al* point out that increased concentrations of vWFAg are found in diabetes mellitus. In the absence of symptomatic vascular disease, however, hypertension, hypercholesterolaemia,¹ and smoking² also act independently to increase vWFAg. We therefore asked whether vWFAg would still be increased in ischaemic heart disease once these risk factors for atherosclerosis were considered.

We studied 41 non-diabetic patients (mean age 59) six weeks after myocardial infarction (proven by a raised creatine kinase over 130 units/l with retrosternal chest pain typical or electrocardiographic changes or both. Twenty one of them said that they were current smokers, or smoking at the time of infarction, or had stopped in the year before infarction. Symptom free age and sex matched controls who were normotensive and normolipaeamic were recruited from individuals attending hospital for endoscopy or repair of varicose veins. Resting systolic and diastolic blood pressures (SBP, DBP) were recorded, and blood was taken for routine measurement of cholesterol and vWFAg (by ELISA). For statistical analysis we used the Mann-Whitney and Spearman's methods on Minitab. Both cholesterol (mean (SD)) 6.3 (0.9) mmol/l, $p = 0.0001$ and vWFAg (130 (39) IU/dl, $p = 0.0004$) were higher in patients than in controls (5.2 (0.9) mmol/l and 104 (37) IU/dl respectively), confirming the work of Jansson *et al*. SBP and DBP were not increased in the patients with ischaemic heart disease but the values did correlate with vWFAg (SBP $r = 0.34$, $p = 0.033$; DBP $r = 0.59$, $p = 0.0001$). vWFAg did not correlate with cholesterol.

A subgroup of 20 patients (12 smokers) with ischaemic heart disease also had hypertension ($n = 10$, blood pressure >140 and >90 mm Hg) or a raised cholesterol concentration ($n = 10$, >7 mmol/l) at re-examination six weeks after discharge from hospital. The remaining 21 patients (12 smokers) were free of these risks. When these two groups were compared we found that those with either of these risk factors had significantly raised blood pressure (136 (18)/84(10) mm Hg) and cholesterol (6.8 (0.8) mmol/l). vWFAg was also higher (153 (35) IU/dl) than in the patients without these risks (107 (28),



vWFAg concentrations in survivors of myocardial infarction and in controls. Mean values are indicated by bars.

$p = 0.0002$), which in turn was not higher than in the symptom free controls (figure).

Although vWFAg is generally raised six weeks after myocardial infarction, in many cases this may be because of hypertension or hypercholesterolaemia or both. The presence or absence of smoking did not influence vWFAg concentrations in any group. We suggest that survivors of myocardial infarction without risk factors for atherosclerosis may have minimal evidence of damage to their vasculature. Conversely, in those with risk factors the endothelial insult is maintained and such patients may be at risk of further cardiac events. It would be instructive to learn whether Jansson *et al* could confirm this by performing multivariate analysis in the patients in their study.

AD BLANN
*MARILYN PORTER
CN McCOLLUM
Departments of Surgery and Medicine,*
University Hospital of South Manchester,
Nell Lane,
Didsbury,
Manchester M20 8LR, UK

- 1 Blann AD, Miller JP, Waite M, McCollum CN. Endothelial cell injury in the risk factors of atherosclerosis. *Br J Surgery* 1992: (in press).
- 2 Blann AD. Increased circulating levels of von Willebrand factor antigen in smokers may be due to lipid peroxides. *Med Sci Res* 1991;19:535-6.

This letter was shown to the author, who replies as follows:

SIR—Blann *et al* report that in a case-control study they found higher concentrations of von Willebrand factor antigen (vWFAg) in survivors of myocardial infarction than in controls. Our study on survivors of myocardial infarction was prospective and showed that high concentrations of vWFAg predicted an increased risk of reinfarction and cardiovascular mortality in univariate Cox regression analysis.