

THE DIGITAL ARTERY LESION OF RHEUMATOID ARTHRITIS

AN IMMUNOFLUORESCENT STUDY

BY

WILLIAM DOUGLAS*

From the Department of Medicine, Postgraduate Medical School of London and the M.R.C. Rheumatism Research Unit, the Canadian Red Cross Memorial Hospital, Taplow

Obliterative endarteritis affecting digital and visceral vessels in rheumatoid arthritis was first described in detail by Bywaters (1957), although Kestler (1949) and Cruickshank (1954) had previously referred to a subacute endarteritis in this disease.

The relationship between this form of arterial lesion and the necrotizing arteritis sometimes occurring in rheumatoid disease (Ball, 1954) remains unexplained, although it has been noted by Bywaters (1957) and by Sokoloff and Bunim (1957) that both arterial lesions may occur in the same individual.

Histologically, the obliterative endarteritis of digital vessels in patients with rheumatoid arthritis is characterized by a more or less concentric increase of intimal fibrous tissue, largely free of inflammatory cells. The internal elastic lamina usually remains intact, although when intimal thickening is marked there may be splitting of elastic fibres and thrombosis with resultant occlusion of the artery.

Clinically, the condition is often asymptomatic, although cold digits, Raynaud's phenomenon, and ischaemic lesions in the form of nail-fold and finger-pulp thrombosis may be encountered.

Brachial angiography has been used to study the digital arteries of rheumatoid patients by Scott, Hourihane, Doyle, Steiner, Laws, Dixon, and Bywaters (1961) and by Laws, Lillie, and Scott (1963). These workers found that the digital vessels frequently showed narrowing or complete occlusion. They also pointed out that nearly all patients showing these lesions had positive serum titres for rheumatoid factor.

In the present study immunofluorescent methods have been used to determine whether rheumatoid factor is present within the intimal lesion of digital arteries from patients with rheumatoid arthritis.

Materials

Preparation of Conjugates

Protein reagents were conjugated with fluorescein isothiocyanate by the method of Marshall, Eveland, and Smith (1958), and free dye was removed by the procedure described by Johnson (1961).

Fluorescent Aggregated Human Gamma Globulin (A.H.G.G.)

Cohn fraction II* was used routinely. The absorbed conjugates were heated in a water bath for 10 min. at 63°C., rapidly cooled, and centrifuged in the cold at 15,000 r.p.m. before use.

Fluorescent Antihuman Globulin Antisera

(1) A potent antiserum to human 19S globulin was prepared from horse antihuman serum (Institut Pasteur). Cross reaction with 7S globulin was removed by absorption with the 7S fraction of human serum eluted from a DEAE-cellulose column.

(2) A second antiserum to human 19S globulin was prepared by immunizing rabbits with sheep cell stroma coated with Paul-Bunnell antibody.

(3) A small quantity of antiserum to rheumatoid factor prepared by Dr. J. N. McCormick was available for comparison with (1) and (2) and it gave similar staining of lymph nodes removed by biopsy from patients with rheumatoid arthritis.

(4) An antihuman 7S antiserum was prepared by hyperimmunization of rabbits with Cohn fraction II in complete adjuvant, removing cross-reaction with 19S by absorption with 7S B chains (Cohen, 1963).

Tissue Examined

(1) *Digital Artery Biopsies.*—Sections were cut from digital arteries removed by biopsy from seven patients with rheumatoid arthritis, six of whom had a positive differential agglutination test (D.A.T.) (Table). In all patients, brachial angiography had demonstrated abnormal digital vessels and a section of abnormal artery was selected for biopsy.

* Australian Arthritis and Rheumatism Council Fellow for 1963.

* Mann Research Laboratory, New York 6, N.Y.

TABLE
PARTICULARS OF SEVEN CASES

Case No.	Age (yrs)	Sex	Duration of Rheumatoid Arthritis (yrs)	Nodules	Neuropathy	Digital Ischaemic Lesions	D.A.T.	Steroid Treatment
1	59	M	14	+	+	+	1:64	+
2	37	M	6	+	—	—	1:512	—
3	44	F	8	—	—	—	1:64	—
4	49	M	12	+	—	+	1:512	+
5	72	M	40	+	+	+	1:256	+
6	57	M	30	+	—	+	1:128	—
7	73	F	11	—	—	—	1:2	—

(2) *Lymph Node Biopsies*.—Nine hyperplastic lymph nodes (six axillary, two cervical, and one inguinal) were removed by biopsy from five patients with rheumatoid arthritis and high titres in the D.A.T. A digital artery and a mesenteric artery were obtained at autopsy from two patients with rheumatoid arthritis and arteritis.

(3) *Control Material*.—Seven lymph nodes (four inguinal, two axillary, and one abdominal) were removed by biopsy from non-rheumatoid patients who were undergoing surgical procedures.

Methods

Tissues were quick-frozen in either liquid oxygen or a mixture of dry ice and absolute alcohol, and were stored at -20°C . until required. The digital arteries were cut transversely into two or three pieces, placed together, and frozen vertically on to a chuck. Cryostat sections of lymph nodes were cut at approximately 4μ thickness, but the arteries, because of their tough consistency, were serially sectioned at 7μ thickness.

The cold alcohol fixation and paraffin-embedding technique of Sainte-Marie (1962) was employed for:

- One digital artery from a patient with sero-positive rheumatoid arthritis (Case No. 6).
- An abdominal lymph node from a normal control subject.
- Two hyperplastic lymph nodes from sero-positive rheumatoid patients.

One half of one of these two hyperplastic nodes was prepared for cryostat sections for comparison of staining reactions.

Cryostat sections were dried on slides at room temperature, fixed in anhydrous acetone for 15 min., and washed in two changes of buffered saline for 15 min. They were then stained with one or two drops of the appropriate conjugate for 30 min. at room temperature, washed in buffered saline for one hour, and mounted in buffered glycerol. Sections prepared by the paraffin-embedding technique were similarly stained, washed, and mounted.

Specificity of staining patterns in lymph nodes was demonstrated with all conjugates by inhibition of reactions with the corresponding unlabelled protein solution (Mellors, Heimer, Corcos, and Korngold, 1959).

Serial sections of digital arteries were cut and stained with toluidine blue until satisfactory sections demonstrating the intimal thickening were obtained. Further sections were then cut and stained with all five fluorescein-labelled conjugates as described above.

Sections from one of the hyperplastic rheumatoid nodes, which was known to show strong specific staining for rheumatoid factor, were cut and stained for control purposes whenever sections of vessels were exposed to the conjugates.

Results

The lymph nodes from sero-positive rheumatoid patients stained with the five fluorescein-labelled anti-19S antisera, A.H.G.G. conjugate, and the anti-7S antiserum showed bright immunofluorescence of plasma cells and follicles corresponding in all details with that described by Mellors and others (1959), Mellors, Nowoslawski, Korngold, and Sengson (1961), and McCormick (1963). Lymph nodes from the controls showed no specific reaction with fluorescein-labelled A.H.G.G. or with the anti-19S antisera, although scanty plasma cell staining was encountered with the anti-7S conjugate.

All biopsied digital arteries displayed obliterative endarteritis. This was advanced to the stage of almost complete occlusion of the lumen in two (Fig. 1), was moderately severe in four (including the vessel processed by the paraffin embedding method), and mild in one. Serial sections of these vessels were stained with all conjugates and the areas of intimal thickening were examined for immunofluorescence. No specific staining was seen in any of the obliterative intimal lesions (Fig. 2), although frozen sections from one digital artery with advanced disease showed specific fluorescence of blood cells and fibrin within the lumen, and thin streaks of fluorescence on the surface of the intima. This fluorescence was strong with the anti-19S antisera, weak with the A.H.G.G. conjugate, and absent with the anti-7S

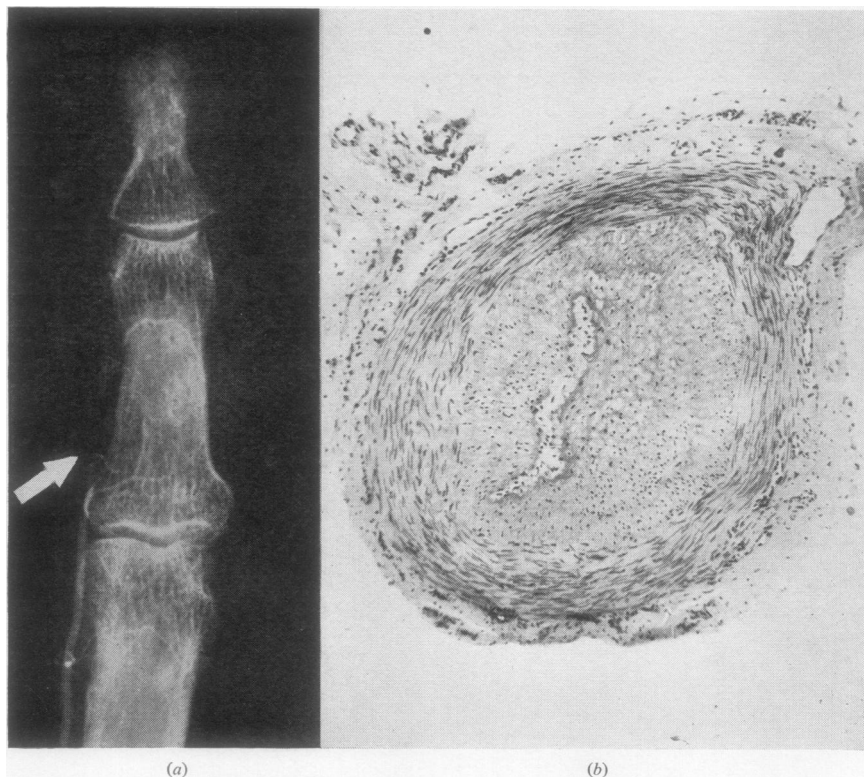


Fig. 1.—(a) Detail of arteriogram from Case 1. Arrow indicates the site from which the biopsy was taken. The vessel shows gross intimal thickening resulting in almost complete occlusion of the lumen. (b) Section of digital artery from Case 1. Haematoxylin and eosin. $\times 40$.

antisera. The vessels obtained at autopsy from rheumatoid subjects were also negative for rheumatoid factor when similarly tested.

The sinuses of over 100 frozen sections from the hyperplastic rheumatoid lymph nodes were examined for intravascular fluorescence. Although these nodes displayed bright staining for rheumatoid factor in the cells of cords and follicles, intravascular staining was infrequent. It was occasionally seen as streaks on the intima with the anti-19S conjugate but was absent with the fluorescein-conjugated A.H.G.G.

A completely different situation was discovered with the biopsied rheumatoid nodes that had been prepared by the paraffin-embedding technique. The half from which frozen sections were cut again gave virtually negative intravascular staining with all conjugates. However, the paraffin-embedded tissues showed marked specific vascular staining with all five conjugates, as well as the usual immunofluorescence in cords and follicles. The vascular staining was seen in all types of blood vessels and

took the form of fluorescent streaks on the endothelial cells, fluorescence in perivascular connective tissue, and numerous fluorescent dots and circles, each of approximately 7μ diameter, within the lumen of the vessels and occasionally between the endothelial cells (Fig. 3). However, as already mentioned, the intimal thickening in a digital artery examined by the paraffin-embedding method still failed to show fluorescence.

Discussion

The possibility of a relationship between rheumatoid obliterative endarteritis and rheumatoid factor is suggested by the almost constant correlation between the presence of digital obliterative lesions and a positive D.A.T. Thus Bywaters and Scott (1963) reported 35 patients with this condition, of whom 34 were sero-positive. They also drew attention to the rarity of this condition in patients with Still's disease, in whom the D.A.T. is usually negative.

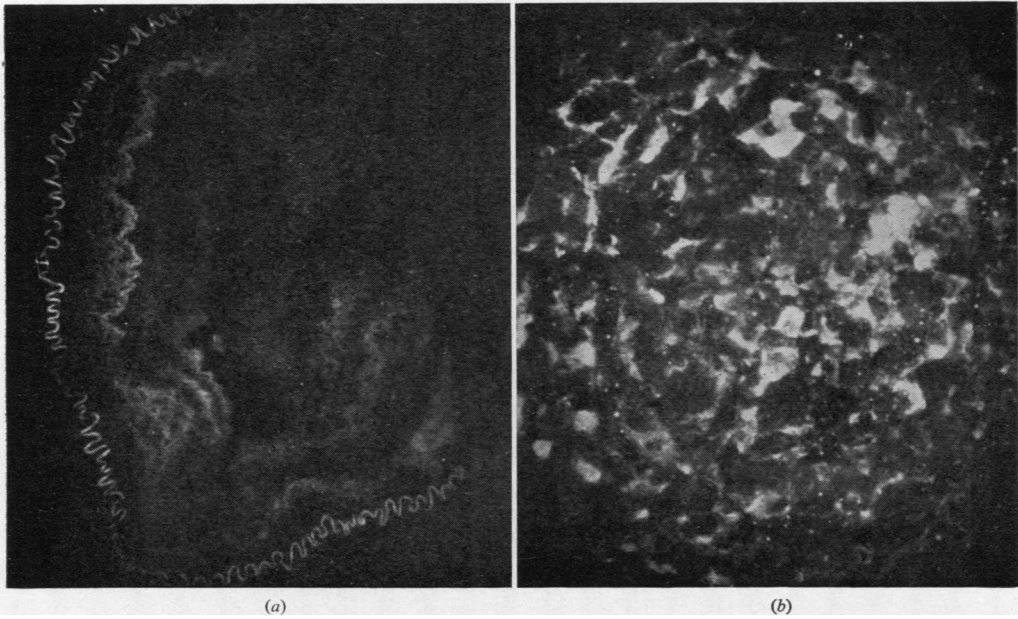


Fig. 2.—(a) Frozen section from vessel shown in Fig. 1 (b) stained with anti-19S conjugate. A little autofluorescence is seen in the elastica and thickened intima but no specific staining is present. U.V. $\times 80$. (b) Germinal centre from a biopsied rheumatoid lymph node, showing specific staining for rheumatoid factor with anti-19S conjugate. U.V. $\times 160$.

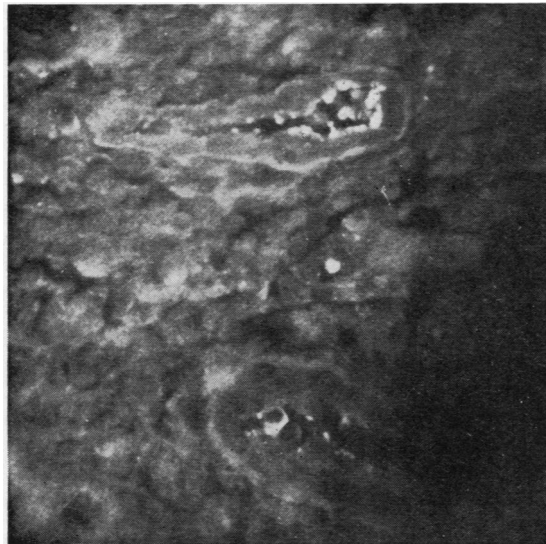


Fig. 3.—Intravascular fluorescence of rheumatoid factor. Small vessels of a biopsied rheumatoid lymph node prepared by the paraffin-embedding technique and stained with anti-19S conjugate. There is specific fluorescence of blood elements within the lumen and upon the surface of endothelial cells. U.V. $\times 80$.

Although rheumatoid obliterative endarteritis is frequently found in association with active arthritis, these two manifestations of rheumatoid disease may manifest themselves independently. Kellgren (1961) mentioned cases with this type of vascular disease, associated with positive serum titres for rheumatoid factor, in the absence of clinical arthritis, and Thompson and Bywaters (1962) reported brachial angiographic evidence of bilateral obliterative endarteritis occurring in a hemiplegic patient with sero-positive rheumatoid arthritis, the manifestations of which were limited to the unparalysed limbs. These observations are consistent with a humoral cause for the vascular changes.

Franklin, Kunkel, and Ward (1958) and Epstein and Engleman (1959) have suggested that intravascular deposition of rheumatoid factor may in some way be responsible for the arteritis of rheumatoid arthritis. This hypothesis has received support from the work of Hess and Ziff (1960), who demonstrated in animal experiments the binding of rheumatoid factor to vessel walls. Baum, Stastny, and Ziff (1962) suggested from infusion experiments upon rat mesentery that the vascular disease in rheumatoid arthritis may be the effect of the reaction between antigen-antibody complexes and rheumatoid euglobulin upon vascular endothelium.

It is, however, concluded from this study that the intimal thickening sometimes seen in the digital arteries of patients with rheumatoid arthritis does not contain rheumatoid factor, although rheumatoid factor is plentiful within the lumen of blood vessels, upon vascular endothelium and blood cells, and sometimes is distributed in perivascular tissue.

If simple deposition of rheumatoid factor were responsible for intimal thickening, one might expect to find numerous lesions in the veins and sinuses of lymph nodes and spleen, where a sluggish circulation would encourage sludging of the euglobulins on to the endothelium. This is not the case.

The paucity of extracellular rheumatoid factor found in frozen sections of rheumatoid lymph nodes, in contrast to the large amount seen when the tissue has been fixed in alcohol and embedded in paraffin, is almost certainly due to a loss by diffusion from these extracellular sites.

The possibility that digital intimal lesions are the end result of an acute arteritis has not been supported to date, for in this and in other reported series digital artery biopsies have failed to show evidence of acute arteritis, and angiograms performed on cases of polyarteritis nodosa are unlike those found in rheumatoid arthritis (Laws and others, 1963).

A further possibility is that the intimal lesion may, in some way as yet unexplained, be consequent upon

abnormal vasomotor tone in the digital arteries. This concept is supported by the work of Arab, Holden, and De Ramos (1964), who demonstrated a high vasoconstrictive tone in the digital circulation of patients with rheumatoid arthritis, and by the histological appearances of the digital arteries which are identical with those illustrated by Lewis (1938) from patients with primary Raynaud's phenomenon. Furthermore, Laws and others (1963) found that the angiograms of digital arteries in rheumatoid arthritis lacked any distinguishing radiological features from those found in primary Raynaud's phenomenon and in Raynaud's phenomenon complicating other disease processes. Clinically, ischaemic fingers are a frequent finding in rheumatoid arthritis (Short, Bauer, and Reynolds, 1957) and many patients develop vasomotor symptoms before the onset of arthritis (Empire Rheumatism Council Survey, 1950). Such a hypothesis does not account for the association between the intimal lesion and sero-positivity, but the influence of immunological reactions upon vascular tone is a field which is as yet unexplored.

Summary

Digital vessels removed by biopsy from seven patients with rheumatoid arthritis were examined for the presence of rheumatoid factor by immunofluorescent techniques. Rheumatoid factor was not found within the thickened intima of these vessels, although it was readily demonstrated in lymph nodes from sero-positive rheumatoid patients, where it was seen in plasma cells, in germinal centres, and upon the surface of vascular endothelium and blood elements.

I wish to express my gratitude to Dr. J. T. Scott of the Postgraduate Medical School, London, and to Dr. J. Holborow of the Rheumatism Research Unit, Canadian Red Cross Memorial Hospital, Taplow, for their generous help and advice in the preparation of this work. I am also indebted to Mr. G. D. Johnson of the Rheumatism Research Unit, Canadian Red Cross Memorial Hospital, Taplow, and to Dr. J. N. McCormick of the Oxford Regional Rheumatic Diseases Research Centre, Stoke Mandeville Hospital, Aylesbury, for valuable technical advice and for the opportunity to use some of their antisera in this experiment.

Mr. James Calnan of the Department of Experimental Surgery, the Postgraduate Medical School, London, kindly performed the digital artery biopsies.

REFERENCES

- Arab, M. M., Holden, G., and De Ramos, E. (1964). *Ann. rheum. Dis.*, **23**, 1.
 Ball, J. (1954). *Ibid.*, **13**, 277.

- Baum, J., Stastny, P., and Ziff, M. (1962). *Arthr. and Rheum.*, **5**, 101.
- Bywaters, E. G. L. (1957). *Ann. rheum. Dis.*, **16**, 84.
- and Scott, J. T. (1963). *J. chron. Dis.*, **16**, 905.
- Cohen, S. (1963). *Nature (Lond.)*, **197**, 253.
- Cruickshank, B. (1954). *Ann. rheum. Dis.*, **13**, 136.
- Empire Rheumatism Council (1950). *Ibid.*, **9**, Suppl.
- Epstein, W. V., and Engleman, E. P. (1959). *Arthr. and Rheum.*, **2**, 250.
- Franklin, E. C., Kunkel, H. G., and Ward, J. R. (1958). *Ibid.*, **1**, 400.
- Hess, E., and Ziff, M. (1960). *Ibid.*, **3**, 450.
- Johnson, G. D. (1961). *Nature (Lond.)*, **191**, 70.
- Kellgren, J. H. (1961). *Ann. rheum. Dis.*, **20**, 233.
- Kestler, O. C. (1949). *Ibid.*, **8**, 42.
- Laws, J. W., Lillie, J. G., and Scott, J. T. (1963). *Brit. J. Radiol.*, **36**, 477.
- Lewis, T. (1938). *Clin. Sci.*, **3**, 287.
- McCormick, J. N. (1963). *Ann. rheum. Dis.*, **22**, 1.
- Marshall, J. D., Eveland, W. C., and Smith, C. W. (1958). *Proc. Soc. exp. Biol. (N.Y.)*, **98**, 898.
- Mellors, R. C., Heimer, R., Corcos, J., and Korngold, L. (1959). *J. exp. Med.*, **110**, 875.
- , Nowoslawski, A., Korngold, L., and Sengson, B. L. (1961). *Ibid.*, **113**, 475.
- Sainte-Marie, G. (1962). *J. Histochem. Cytochem.*, **10**, 250.
- Scott, J. T., Hourihane, D. O., Doyle, F. H., Steiner, R. E., Laws, J. W., Dixon, A. St. J., and Bywaters, E. G. L. (1961). *Ann. rheum. Dis.*, **20**, 224.
- Short, C. L., Bauer, W., and Reynolds, W. E. (1957). "Rheumatoid Arthritis". Harvard University Press, Cambridge, Mass.
- Sokoloff, L., and Bunim, J. J. (1957). *J. chron. Dis.*, **5**, 668.
- Thompson, M., and Bywaters, E. G. L. (1962). *Ann. rheum. Dis.*, **21**, 370.

**La lésion artérielle digitale dans l'arthrite rhumatismale
Une étude immunofluorescente**

RÉSUMÉ

On rechercha le facteur rhumatoïde par des procédés immunofluorescents dans les vaisseaux obtenus à la biopsie digitale de sept malades atteints d'arthrite rhumatismale. Ce facteur ne fut pas trouvé dans l'intime épaissie des vaisseaux des doigts, bien que sa présence fût démontrée dans les ganglions lymphatiques des rhumatisants séropositifs, où on le vit dans les plasmocytes, les centres germinaux et à la surface de l'endothélium vasculaire et des éléments sanguins.

**La lesion arterial digital en la artritis reumatoide
Un estudio inmunofluorescente**

SUMARIO

Procedimientos de inmunofluorescencia fueron empleados para evidenciar el factor reumatoide en vasos obtenidos por biopsia digital de siete enfermos con artritis reumatoide. El factor reumatoide no fué encontrado en la íntima espesada de estos vasos, a pesar de hallarlo fácilmente en ganglios linfáticos de enfermos reumáticos seropositivos, donde se le vió en plasmocitos, en centros germinales y en la superficie del endotelio vascular y de los elementos sanguíneos.