

POLYMYALGIA RHEUMATICA

BIOPSY STUDIES

BY

IAN GORDON, A. M. RENNIE, AND A. W. BRANWOOD

Aberdeen Royal Infirmary and University of Aberdeen

Polymyalgia rheumatica is a clinical syndrome affecting middle-aged and elderly persons and is characterized by periartritic and muscular pain and stiffness particularly in the shoulder and hip girdles. Systemic symptoms are present, the erythrocyte sedimentation rate (E.S.R.) is greatly elevated, and the Waaler-Rose test is almost invariably negative. Suppression of symptoms with corticosteroid therapy is striking. The disease appears to run a benign course and in cases not treated with corticosteroids muscular and periartritic pains disappear spontaneously and completely in 2 to 4 years (Gordon, 1960).

The cause of the syndrome is not known. Some recent authors have suggested that the myalgia is a manifestation of giant cell arteritis. The myalgia and the less common arthralgia sometimes associated with giant cell arteritis certainly may resemble polymyalgia rheumatica and diagnosis may be difficult in the early stages. Significant differences, however, exist. Giant cell arteritis is now regarded as a widespread arterial disease which may spare, at least for a time, the commonly involved temporal, occipital, and retinal arteries. Rheumatic symptoms may precede, accompany, or follow the phase of temporal artery involvement and present as pain in the muscles of the limb girdles and trunk and as arthralgia of the larger joints. As in polymyalgia rheumatica, the disease occurs in the elderly, the erythrocyte sedimentation rate is considerably elevated, and the symptoms rapidly respond to corticosteroid therapy. In polymyalgia rheumatica, however, the pain in the shoulder and hip girdles is overshadowed by the stiffness of the shoulders with gross limitation of movement in the average case. Stiffness of the shoulder joints is not a prominent feature of giant cell arteritis. Severe pain and tenderness in the muscles of the limb girdles and trunk may occur in giant cell arteritis and,

in cases of long duration, these symptoms are associated with weakness and wasting of muscles, the latter being out of all proportion to the clinical and radiological involvement of the joints (Russell, 1959). Such wasting and weakness do not occur in polymyalgia rheumatica.

In reviewing 175 cases of temporal arteritis from the Mayo Clinic, Hollenhorst, Brown, Wagener, and Shick (1960) described diffuse aching in the muscles of the extremities, neck, and shoulders. Limitation of movement of the shoulder joints was not a feature, though extreme tenderness of the neck muscles often prevented the patient from bending or turning the head.

In some of the case histories of giant cell arteritis detailed by Paulley and Hughes (1960) severe widespread rheumatic pains were noted. Stiffness occurred in some but it is not clear how severe was this symptom.

Kogstad (1963) described twenty cases of "polymyalgia rheumatica", six of which had temporal arteritis confirmed by biopsy. Muscle pains were frequently located in the neck and shoulder regions, but there is no mention of any limitation of movements of the shoulder joints.

Alestig and Barr (1963) considered that polymyalgia rheumatica was due to an arteritis. They found changes of giant cell arteritis on biopsy of a temporal artery in seven patients with rheumatic symptoms none of whom had good clinical evidence of temporal arteritis. Stiffness is mentioned in only three cases and, in the case described as typical, the rheumatic symptoms are noted as pain, paraesthesiae, and weakness of the legs—symptoms which can hardly be accepted as those of polymyalgia rheumatica. Furthermore, evidence of giant cell arteritis has not been encountered in any of the recent descriptions of polymyalgia rheumatica (Barber, 1957; Gordon, 1960; Boyle and Beatty,

1961; Bagratuni, 1963). In contrast, Russell (1962) described a patient with temporal arteritis, confirmed histologically, who later exhibited gross wasting and weakness in the muscles of the shoulder girdle associated with aching in the arms and legs; biopsy of an artery in the deltoid muscle showed severe generalized inflammatory changes with giant cell formation. He suggested that muscular arteritis may be a cause of chronic myalgic symptoms in the elderly. With this we agree, but the gross wasting and weakness of the muscles and the absence of stiffness of the shoulder girdle are not compatible with polymyalgia rheumatica. There was no clinical or histological evidence of giant cell arteritis in our cases of polymyalgia rheumatica. Biopsy of a temporal artery was, however, not performed.

In summary, while rheumatic pains may be severe in both disorders, stiffness and gross limitation of movement, particularly of the shoulder joints, are features of polymyalgia rheumatica. In giant cell arteritis, muscle tenderness is more prominent and, in cases of some duration, weakness and wasting of muscle are found.

Although the predominant symptom in polymyalgia rheumatica is stiffness of the shoulder girdles and neck, tenderness of muscle is only slight and often absent. Examination of muscle obtained at biopsy, however, has failed to show any abnormality of the muscle fibres (Kersley, 1951; Gordon, 1960; Bagratuni, 1963). In muscular septa, perivascular collections of chronic inflammatory cells have been described and similar collections were found in fibro-connective tissue and fat (Gordon, 1960).

It was felt that further histological studies might throw some light on this interesting syndrome; therefore biopsy material was obtained from a shoulder joint in six patients with polymyalgia rheumatica (Table) and from two patients who

presented with symptoms resembling this syndrome but in whom rheumatoid arthritis was suspected. The latter disease was subsequently confirmed in these two patients. The biopsies were carried out between the second and the eighth month after the onset. With the exception of Case 7, who had been receiving dexamethasone in varying dosage for the previous 3 months, no patient had received corticosteroids before the biopsy. The operation, which was performed under local or light general anaesthesia, did not upset any of the patients and no complications occurred. The reasons for the biopsy were carefully explained to each patient, and all consented willingly.

Case Reports

Polymyalgia Rheumatica

Case 1, a female aged 78 years, was in good health till February, 1958, when there was a fairly sudden onset of pain and stiffness in the shoulder and hip girdles. Later, the knees became painful. The symptoms became progressively worse and she had difficulty in walking and in dressing. Fatigue and weight-loss were also noted.

Examination.—In May, 1958, she looked tired and had obviously lost some weight. There was gross limitation of movement of the shoulder joints and slight limitation of extension of the right elbow. There was only slight tenderness in the muscles. Both knees were slightly swollen and tenderness was elicited over the hamstring tendons and in the popliteal fossa. For a few days she had complained of slight transient aching in all her fingers in the morning but no objective signs were noted.

Investigations.—E.S.R. (Westergren) 55 mm./hr. Haemoglobin 78 per cent. Waaler-Rose test negative.

X-ray Examinations.—Cervical spine showed moderate spondylosis. Minor osteo-arthritic changes were present in the small joints of both hands and in the knee joints. Shoulder joints negative.

TABLE
CLINICAL PARTICULARS IN SIX CASES OF POLYMYALGIA RHEUMATICA

Case No.	Sex	Age (yrs)	Duration of Symptoms (yrs)	Period of Freedom from Symptoms (yrs)	Time of Biopsy (month)	Biopsy Material				Tendinous Septum	Muscle
						Synovium, Sub-synovium	Capsule	Bursa	Deep Fascia		
1	F	78	1½	4	4th	+					+
2	M	82	1½	3½	3rd		+			+	
3	M	77	2	3½	2nd	+		+		+	
4	M	60	4	1½	5th		+		+	+	
5	M	58	3½	½	8th	+	+	+	+		+
6	M	54	2½	—	8th		+				+

Biopsy.—Synovial membrane of the left shoulder joint showed slight hyperplasia of the synovial lining cells, scanty infiltration with lymphocytes and macrophages, and increased vascularity (Fig. 1).

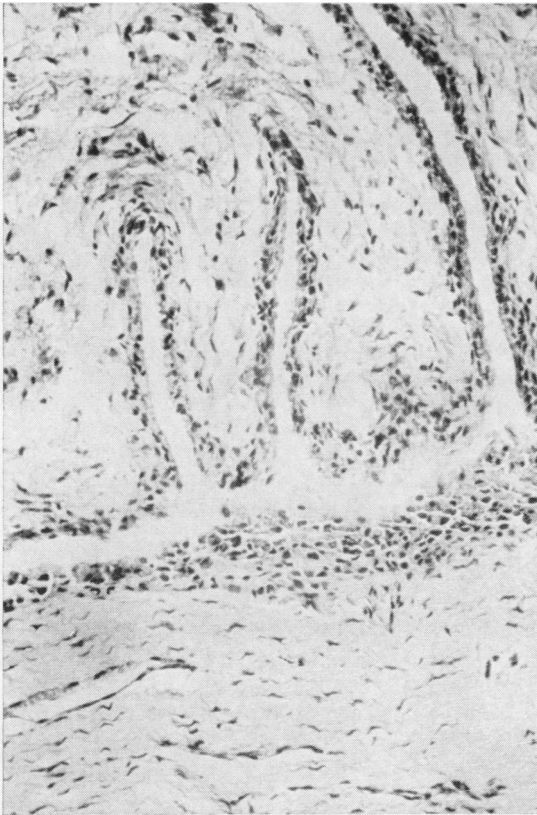


Fig. 1.—Case 1, synovium of shoulder joint, showing cell proliferation of the synovial lining and scanty infiltration with chronic inflammatory cells.

Deltoid muscle showed no abnormality.

Treatment.—After starting a 19-day course of triamcinolone (24 mg. daily) all pain and stiffness vanished and she was discharged home feeling very well. A month later her only complaint was of minor aching in fingers lasting less than an hour in the mornings. E.S.R. 11 mm./hr. Waaler-Rose test negative.

Follow-up.—During the following 12 months she noticed only minor aching in the fingers and sometimes in the right shoulder girdle. No signs in any joint were detected. The E.S.R. varied from 9 to 12 mm./hr.

In July, 1959, she suffered a minor cerebral thrombosis with weakness of the right arm which recovered in a few weeks. She was examined at intervals and has remained in good health and free from any rheumatic symptoms for 4 years.

Comment.—Polymyalgia rheumatica of moderate severity; excellent response to corticosteroids; duration

18 months. The patient had been asymptomatic for 4 years.

Biopsy showed non-specific changes.

Case 2, a male aged 82 years, was in excellent health until April, 1958, when he rapidly developed pain and stiffness of the shoulder girdles, and to a lesser extent in both knees and quadriceps muscles. The symptoms were so marked a month later that he was unable to sit up in bed unaided. He lost his appetite, felt weak, and became pale. He lost weight and could not sleep because of pain.

Examination.—On admission to hospital in June, 1958, he looked pale and thin. There had been less severe pain, but stiffness of the shoulders, neck, and thighs was still present to such a degree that he could not dress without assistance. No tenderness of muscles was elicited though some tenderness was present on palpating the right adductor tendon at the knee. There was gross limitation of movements of the neck and shoulders which could not be abducted to 90°. No swelling or tenderness of any joint was noted.

Investigations.—E.S.R. 92 mm./hr. Haemoglobin 66 per cent. Red cells showed hypochromia. Waaler-Rose test negative.

X-ray Examination.—Shoulder joints showed some decalcification of bone. Cervical spine—moderate spondylosis.

Biopsy.—Capsule of the left shoulder joint showed congested fibro-connective tissue, moderately infiltrated with chronic inflammatory cells which tended to be mainly perivascular in distribution.

Tendinous septa of deltoid muscle also showed areas of chronic inflammatory cell infiltration.

Treatment.—There was a poor response to salicylate therapy, but a few days after the start of a course of prednisone there was spectacular improvement and all pain and stiffness disappeared. The initial dose of prednisone was 30 mg. daily and the course in decreasing doses lasted 4 weeks. At the end of the course E.S.R. had fallen to 9 mm./hr and the haemoglobin had risen to 82 per cent.

Follow-up.—In September, 1958, a mild relapse occurred with aching in the shoulder girdle, biceps, and forearm muscles. There was some restriction of movement of the shoulders. E.S.R. 49 mm./hr.

During the next 14 months there was minor aching in the shoulder girdles but full movements were present. E.S.R. varied from 8 to 24 mm. In November, 1959, all aching disappeared and did not recur. He enjoyed good health to the time of his death in September, 1963 (urinary retention, cerebral thrombosis, and uraemia). During this period the E.S.R. on four occasions was normal.

Comment.—Moderately severe case of polymyalgia rheumatica with excellent response to corticosteroid therapy; duration 19 months; no further rheumatic symptoms for 3 years 10 months.

Biopsy showed non-specific changes.

Case 3, a male aged 77 years, was in excellent health until October, 1958, when there gradually appeared pain in the groins, anterior aspects of both thighs, and buttocks; 2 weeks later pain and stiffness spread to the shoulder girdles. The pain increased in severity and he was admitted to hospital a month after the onset so disabled that he was unable to dress himself and could move in bed only with the greatest difficulty. There was some anorexia and loss of weight and a low-grade fever to 99° F.

Examination.—He looked ill. Slight limitation of movement of the neck and gross limitation of movement of the shoulders were present. Abduction of the arms was very painful and limited to less than 90°. The hip joints could not be fully abducted. The pectoral and biceps muscles were slightly tender on palpation as also were the biceps tendons at the elbows and adductor tendons at the hips. There was no clinical evidence of joint involvement.

Investigations.—E.S.R. 60 mm./hr. Haemoglobin 104 per cent. Waler-Rose test negative.

X-ray Examination.—The appearances in the shoulder and hip joints were normal, and in the cervical spine they were those of mild spondylosis.

Biopsy.—Synovium of the shoulder joint was oedematous and revealed minor hyperplasia of the synovial endothelium with slight lymphocytic infiltration of the subsynovium.

Tendinous septum from the deltoid showed small collections of lymphocytes arranged in a perivascular manner.

Subdeltoid bursa showed mild hyperplasia of the synovium.

Treatment.—During the following 12 months, no less than eight courses of prednisone were necessary to relieve his symptoms; 24 hours after starting a course in a dose of 30 mg. daily, however, there occurred almost complete relief of pain and stiffness. Each course lasted 21 to 28 days and relapse appeared within a few days or weeks after the corticosteroid was stopped.

Follow-up.—In July, 1960, he complained of only minor aching in the adductor tendons at the hips and he was able to walk 4 miles every day. E.S.R. 8 mm./hr. Since October, 1960, he has had no aching whatsoever and the E.S.R. (on five occasions) has never been higher than 11 mm./hr.

Comment.—A severe case of polymyalgia rheumatica of 2 years' duration requiring eight courses of corticosteroids for the relief of symptoms; freedom from rheumatic symptoms for 3 years 5 months.

Biopsy showed non-specific changes.

Case 4, a male aged 60 years, was suddenly afflicted in March, 1958, with pain and stiffness in the neck, shoulders, arms, forearms, and thighs, and had to give up

work 2 weeks later. There were no systemic symptoms.

Examination.—On admission to hospital in July, 1958, stiffness was complained of in the neck and to a greater degree in the shoulder girdles. There was slight stiffness in the quadriceps muscles. Neck movements were slightly limited, but there was gross restriction of movement of the shoulders. A minor degree of tenderness was present in the biceps and trapezius muscles. Other muscles and joints appeared to be unaffected.

Investigations.—Highest E.S.R. 56 mm./hr. Haemoglobin 100 per cent. Waler-Rose test negative.

X-ray Examinations.—Cervical spine and shoulder joints showed no abnormality.

Biopsy.—Shoulder joint capsule revealed congested oedematous fibro-connective tissue with occasional small collections of macrophages and lymphocytes in proximity to vessels.

Muscular fascia and tendinous septum showed oedema and perivascular chronic inflammatory cell infiltration, many arterioles showing active intimal endothelial cell proliferation.

Treatment.—Four courses of prednisone were required for the suppression of symptoms and the Waler-Rose test was negative on four occasions.

Follow-up.—By April, 1962, all rheumatic symptoms had disappeared. When last seen in October, 1963, he had remained symptom-free. E.S.R. 6 mm./hr.

Comment.—Moderately severe case of polymyalgia rheumatica of 4 years' duration; freedom from rheumatic symptoms for 18 months.

Biopsy showed non-specific changes in joint capsule of shoulder, muscular fascia, and tendinous septum.

Case 5, a labourer aged 58 years, first noted the gradual onset of pain and stiffness in the right arm and shoulder girdle, later spreading to the neck in August, 1960. Within 4 months both shoulder girdles, buttocks, and thighs were involved. His general health was unimpaired.

Examination.—In February, 1960, when admitted to hospital, he looked tired. There was marked limitation of abduction of both shoulders especially the right and slight limitation of movement of the hip joints. The 1st right metacarpophalangeal joint ached on movement. Tenderness was elicited over the adductor tendons at the knees and in the popliteal fossa.

Investigations.—E.S.R. (highest) 45 mm./hr. Haemoglobin 93 per cent. Waler-Rose test twice negative.

X-ray Examinations.—Minor osteo-arthritis changes were present in both hip, knee, and shoulder joints, and the joints of the hands showed slight loss of cartilage.

Treatment.—Corticosteroids were not used initially because of symptoms of duodenal ulcer of 5 years' duration and paracetamol was prescribed. In May, 1960, he was readmitted to hospital, and there was little

change in his condition. E.S.R. 60 mm./hr.

Biopsy.—Specimen of deep fascia from left shoulder showed minimal chronic inflammatory cell infiltration around small vessels.

Deltoid muscle revealed scanty collections of lymphocytes between the bundles.

Subsynovium showed moderate infiltration with macrophages and lymphocytes together with minor proliferation of the synovial endothelial cells.

Similar changes were present in the subdeltoid bursa.

There was notable perivascular infiltration and hyperplasia of the capillary endothelium of the vessels in the joint capsule.

Progress.—In September, 1960, the pain and stiffness grew worse. There was, in addition, some aching in the fingers which lasted a few months. E.S.R. 26 mm./hr. Waaler-Rose test negative. An excellent remission followed the start of a month's course of enteric-coated prednisolone in a dose of 10 mg. daily.

Follow-up.—Minor aching and stiffness troubled him during the next 12 months, but he was able to return to his work as a labourer in September, 1961. All rheumatic symptoms had disappeared by July, 1963, and in November, 1963, he was still symptom free. E.S.R. 6 mm./hr. Waaler-Rose test negative.

Comment.—Polymyalgia rheumatica of 3 years 11 months' duration; symptom free for 4 months.

Biopsy showed non-specific inflammatory changes in deep fascia, subsynovium, and joint capsule, and scanty collections of lymphocytes between the muscle bundles of the deltoid.

Case 6, a male aged 54 years, reported that pain and stiffness of the neck came on fairly suddenly in March, 1961; 2 months later the shoulder girdles were affected, and dull aching was present in the lumbar region, both quadriceps, and occasionally in both wrists. Systemic symptoms included sweating, weakness, and loss of weight.

Examination.—When admitted to hospital in November, 1961, he looked well but had low-grade fever. There was much stiffness of the shoulders and gross limitation of abduction. There was no muscle tenderness and no evidence of joint involvement.

Investigations.—E.S.R. 49 mm./hr. Haemoglobin 81 per cent. Waaler-Rose test negative.

X-ray Examinations.—Some osteo-arthritic changes in the acromio-clavicular joints and a slight degree of cervical spondylosis.

Biopsy.—Deltoid muscle showed no abnormalities in muscle fibres. Two arterioles showed proliferation of intimal cells.

Capsule of shoulder joint showed collections of small numbers of lymphocytes and plasma cells present throughout the tissue, tending to be aggregated around small vessels which showed intimal proliferation (Fig. 2).

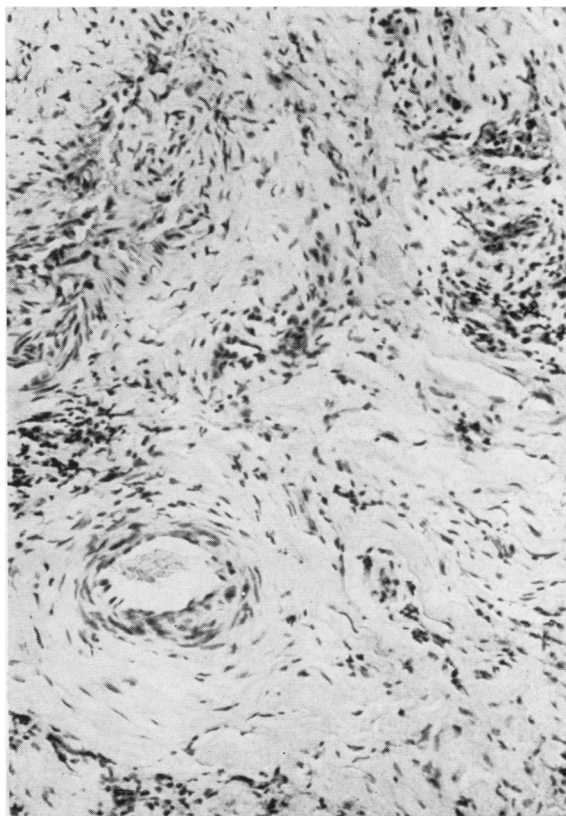


Fig. 2.—Case 6, capsule of shoulder joint, showing small foci of chronic inflammatory cells. Note tendency to aggregation around small vessels.

Specimens of capsule, muscle, and fibromuscular junction were also examined by the fluorescent antibody technique and showed no evidence of accumulation of rheumatoid factor or of excessive deposition of gamma globulin (Dr. R. C. Nairn).

Treatment.—Phenylbutazone suppositories were unsuccessful, but there was great relief on a course of prednisone 40 mg. daily for 6 weeks, and the E.S.R. fell to 40 mm./hr.

Follow-up.—In April, 1962, a relapse with stiffness of the shoulders had occurred. This again responded to a 7 weeks' course of prednisone, and 2 months later he returned to his work as a labourer. He has since complained only of odd episodes of aching in the shoulder girdles. The E.S.R. has varied from 6 to 17 mm./hr. Waaler-Rose test twice negative.

Comment.—Average case of polymyalgia rheumatica of 2 years 3 months' duration not yet completely recovered; good response to two courses of corticosteroids.

Biopsy showed non-specific changes in capsule of shoulder joint.

Rheumatoid Arthritis

The two following patients suffered from undoubted rheumatoid arthritis, bearing a superficial resemblance to polymyalgia rheumatica in the early stages; they are included to illustrate the diagnostic difficulties in the early stages. Interesting histological changes are recorded.

Case 7, a male aged 72, was admitted to hospital in May, 1959. His illness had started suddenly in December, 1958, with generalized stiffness, particularly in both shoulders and in the left hip. Later, stiffness of the fingers developed, followed by pain in the elbows, knees, and ankles. For 3 months dexamethasone in varying dosage had brought some relief.

Examination.—On admission to hospital he looked well. He complained of pain in the posterior muscles of the neck and in both shoulders, especially the left which was almost completely "frozen" with wasting of the muscles of the shoulder girdle. Almost full movements were present in the right shoulder. There was slight pain in and slight limitation of movement of the left elbow joint and left hip. There was no muscle tenderness. A small effusion was present in the right knee which was painful on movement.

The clinical features not found in polymyalgia rheumatica are the "frozen" shoulder with wasting of muscle and the complaint of ankle pain.

Investigations.—The highest E.S.R. recorded was 57 mm./hr. Haemoglobin 75 per cent. Waaler-Rose test twice negative (D.A.T. 1 : 16).

X-ray Examinations.—No significant changes.

Biopsy.—Specimens from the left shoulder showed the synovial membrane to be oedematous with focal collections of lymphocytes, plasma cells, and macrophages. These cells were mainly perivascular in distribution and the small arterioles showed intimal hyperplasia and medial fibrosis. Biopsy from the left knee revealed marked infiltration of synovium and subsynovium with lymphocytes, plasma cells, and macrophages. These cells were distributed diffusely in the congested synovium and were arranged in a perivascular manner in the subsynovium. The changes were compatible with rheumatoid arthritis.

Fluid aspirated from the knee showed polymorphonuclear leucocytes, lymphocytes, and plasma cells.

Treatment.—A month's course of prednisone in an initial dose of 40 mg. daily led to almost complete suppression of symptoms, and intensive physiotherapy was necessary to restore full movement of the left shoulder.

Follow-up.—Minor aching in the shoulders and knees continued until November, 1960, and from then until January, 1964, he remained entirely free from rheumatic symptoms.

Comment.—Sero-negative rheumatoid arthritis with a superficial resemblance to polymyalgia rheumatica of 2 years' duration. There was an excellent response to a course of prednisone and good remission for over 3 years.

Biopsy of synovial membrane from the left shoulder showed non-specific changes, but in the left knee the changes were those of rheumatoid arthritis.

Case 8, a male aged 56, complained of some stiffness in both calves in April, 1960. This disappeared within a month. In August, 1960, there occurred gradual pain and stiffness in the muscles of the left shoulder girdle, left groin, and calf, and a month later identical symptoms appeared on the right side. Stiffness of the fingers then appeared and he was admitted to hospital in October, 1960.

Examination.—There were no systemic symptoms. There was marked restriction of all movements of both shoulders, particularly the right, and the metacarpophalangeal joints of the right index and middle fingers were swollen. No muscle tenderness was elicited.

Investigations.—E.S.R. 38 mm./hr. Haemoglobin 98 per cent. Waaler-Rose test negative.

X-ray Examination.—Relevant joints showed no abnormality.

Biopsy.—Histological examination revealed oedema and increased vascularity of the fibroconnective tissue of the capsule of the shoulder joint with a moderate degree of chronic inflammatory cell infiltration and fibroblastic proliferation in focal areas. The subsynovial tissue of the capsule showed slight focal perivascular chronic inflammatory cell infiltration. No abnormalities were present in the muscle fibres or in tendinous septa.

Treatment.—In December, 1960, pain was present in both temporo-mandibular joints and stiffness of the shoulders persisted.

After a course of corticosteroid therapy, the R.A. latex test and the Waaler-Rose test became positive (D.A.T. 1 : 128). Pain and stiffness in the fingers, left elbow, and shoulder became troublesome and swelling was noted in finger joints during the ensuing 6 months.

Follow-up.—To allow him to continue his work as a trawl fisherman a small daily dose of prednisone has been necessary for the past 2 years.

Comment.—Early symptoms resembled those of polymyalgia rheumatica, but rheumatoid arthritis was suspected and later confirmed by a positive Waaler-Rose test and by the clinical course of the disease.

Biopsy of capsule and subsynovial tissue of the shoulder joint showed non-specific changes.

Discussion

The histological changes in biopsies of the shoulder joint in six patients with polymyalgia rheumatica (Cases 1 to 6) all conform to a constant

pattern. They comprise minor hyperplasia of the synovial endothelial cells, and oedema of the synovium and subsynovium, with slight or moderate, but never massive, infiltration of chronic inflammatory cells which tend to be arranged in a perivascular manner. Similar infiltration with chronic inflammatory cells is also found in the joint capsule, bursa, deep fascia, and the tendinous septa of the deltoid muscle. In addition, the smaller blood vessels invariably show endothelial proliferation and intimal thickening. These small vessels, although showing the changes of an inflammatory response in surrounding tissue, reveal no evidence of giant cell arteritis. The histological changes demonstrated are non-specific. They do not help in elucidating the cause of polymyalgia rheumatica, nor have they any diagnostic value. They do, however, indicate the diffuse nature of the pathological process. The pain and stiffness affecting the shoulder girdles are mainly located by the patient in the muscles, particularly in the deltoid, biceps, and trapezius, and it is likely that this "myalgia" is produced by inflammatory changes in synovium, capsule, bursae, and other periarticular structures. It is considered that the inflammatory lesions found in the tendinous septa of deltoid muscle also contribute to the production of pain. Tendons and their sheaths may also be implicated, since tenderness is often elicited on palpating the tendons of the biceps, quadriceps, and adductor muscles of the thigh (Gordon, 1960). The histological findings give some support to the experiments of Coomes and Sharp (1961) who injected 5 per cent. saline into certain joints, bursae, and ligaments and noted that the areas of pain produced were often in the region of muscle, though they do not quite conform to the usual sites of pain in polymyalgia rheumatica.

With regard to the aetiology of polymyalgia rheumatica, some authors have put forward the view that the syndrome is a benign form or variant of rheumatoid arthritis, but so far there has been no proof that this is so. An occasional patient with the clinical features of the syndrome of polymyalgia rheumatica has eventually developed undoubted rheumatoid arthritis. Boyle and Beatty (1961) described 21 cases of classical polymyalgia rheumatica of which one developed rheumatoid arthritis, and Bagratuni (1963) reported two in a series of fifty cases. It must be emphasized, however, that rheumatoid arthritis may present with clinical features showing some resemblance to polymyalgia rheumatica, and in some cases a firm diagnosis can be made only after many months of observation (see Cases 7 and 8).

The synovial and periarticular inflammatory lesions in polymyalgia rheumatica are here regarded as non-specific. They may be compatible with those of early rheumatoid arthritis, though there will be a clear distinction between the two diseases in their clinical course. It might appear that in Case 7, who was suffering from sero-negative rheumatoid arthritis which resembled polymyalgia rheumatica, the histological studies would support a rheumatoid aetiology in polymyalgia rheumatica. Synovial membrane and bursa from a shoulder joint showed non-specific inflammatory changes while synovial biopsy from the left knee showed *marked* infiltration typical of rheumatoid arthritis. There was complete remission of symptoms for 3 years, and this can hardly be regarded as the usual course of rheumatoid arthritis. In Case 8, non-specific inflammatory changes were demonstrated in the subsynovium and capsule of the shoulder, but the clinical course was that of classical rheumatoid arthritis.

It cannot be assumed, however, that the non-specific inflammatory changes shown in patients with polymyalgia rheumatica (Cases 1 to 6) are those of early rheumatoid arthritis. The clinical features and course of the two diseases certainly differ. In rheumatoid arthritis in the elderly, involvement of the shoulder joints and a very high erythrocyte sedimentation rate are frequent findings, but the clinical course of the disease is similar to that seen in younger persons (Cecil and Kammerer, 1951; Dordick, 1956). In contrast, in polymyalgia rheumatica, the differential sheep-cell agglutination test has been almost invariably found to be negative and complete recovery occurs in 2 to 4 years (Gordon, 1960) or even in 1 to 3 years (Boyle and Beatty, 1961).

It should also be noted that in Case 6, who was suffering from polymyalgia rheumatica, antinuclear factor was not demonstrated in the serum by the immunofluorescent technique nor was rheumatoid factor or excess accumulation of gamma globulin found in synovium of the shoulder.

With regard to nomenclature, the term "central arthritis" is hardly acceptable, since peripheral joints may be transiently affected. Many other names have been suggested, but since the cause of the disease is unknown it might be as well for the present to retain the name polymyalgia rheumatica, now in common use. At least, the pain and stiffness are considered by the patient to reside in the muscles.

Conclusions and Summary

(1) Histological examination of synovium and periarticular structures from the shoulder (joint capsule, bursa, and deep fascia) and of tendinous septum from deltoid muscle in six cases of polymyalgia rheumatica revealed non-specific infiltration with chronic inflammatory cells of a mild to moderate degree. Small blood vessels showed endothelial proliferation and intimal thickening.

(2) Two cases of rheumatoid arthritis showed similar non-specific inflammatory changes in the shoulder, but it is not considered that this is evidence of a rheumatoid aetiology for the polymyalgia seen in Cases 1 to 6.

(3) In the shoulder girdle, it is now considered that the muscular and periarticular pain and stiffness can be explained by the chronic inflammatory changes in the synovium, the periarticular structures, and the tendinous septa of muscle. The pain and stiffness in relation to other joints can probably be explained on the same basis.

(4) The cause of polymyalgia rheumatica is unknown. It is not considered that the syndrome is related to giant cell arteritis, since there are significant differences in the clinical features and no histological evidence of giant cell arteritis was found in the present series. The benign course, negative sheep cell agglutination test, and eventual complete recovery in polymyalgia rheumatica are emphasized.

(5) It is suggested that, for want of a better, the term polymyalgia rheumatica be retained for the present.

We wish to thank Dr. J. L. Christie for preparing the microphotographs.

REFERENCES

- Alestig, K., and Barr, J. (1963). *Lancet*, **1**, 1228.
 Bagratuni, L. (1963). *Brit. med. J.*, **1**, 513.
 Barber, H. S. (1957). *Ann. rheum. Dis.*, **16**, 230.
 Boyle, A. C., and Beatty, D. C. (1961). *Proc. roy. Soc. Med.*, **54**, 681.
 Cecil, R. L., and Kammerer, W. H. (1951). *Amer. J. Med.*, **10**, 439.
 Coomes, E. N., and Sharp, J. (1961). *Lancet*, **2**, 1328.
 Dordick, J. R. (1956). *J. Amer. geriat. Soc.*, **4**, 588.
 Gordon, I. (1960). *Quart. J. Med.*, **29**, 473.
 Hollenhorst, R. W., Brown, J. R., Wagener, H. P., and Shick, R. M. (1960). *Neurology*, **10**, 490.
 Kersley, G. D. (1951). "Proc. II Congr. Europ. Reum.", p. 388. Barcelona.
 Kogstad, O. (1963). *T. norske Laegeforen.*, **83**, 534.

Paulley, J. W., and Hughes, J. P. (1960). *Brit. med. J.*, **2**, 1562.

Russell, R. W. Ross (1959). *Quart. J. Med.*, n.s. **28**, 471.
 — (1962). *Ann. rheum. Dis.*, **21**, 171.

Polymyalgia rheumatica.—Études biopsiques

RÉSUMÉ

(1) L'examen histologique de la synoviale et des structures périarticulaires de l'épaule (capsule articulaire, bourse et aponévrose profonde) ainsi que des cloisons tendineuses du muscle deltoïde dans six cas de *polymyalgia rheumatica* révéla l'existence d'une infiltration non-spécifique, légère ou modérée, par des cellules inflammatoires chroniques. De petits vaisseaux sanguins accusaient une prolifération endothéliale et un épaississement de l'intime.

(2) Deux cas d'arthrite rhumatismale présentaient des altérations inflammatoires non-spécifiques similaires, mais on ne considère pas que cela prouve l'étiologie rhumatismale de la *polymyalgia* observée dans les cas No. 1 et No. 6.

(3) On considère maintenant qu'à l'épaule la douleur et l'enraidissement musculaires et périarticulaires peuvent être expliqués par des altérations inflammatoires chroniques de la synoviale, des structures périarticulaires et des gaines tendineuses des muscles. La douleur et l'enraidissement aux autres articulations pourraient s'expliquer de la même manière.

(4) La cause de la *polymyalgia rheumatica* n'est pas connue. On ne croit pas que ce syndrome soit lié à l'artérite aux cellules géantes, étant donné qu'il y a des différences appréciables entre les traits cliniques et que dans la série présente on ne trouve pas de signes histologiques d'artérite aux cellules géantes. On souligne les faits que la réaction de Waaler-Rose est négative, l'évolution bénigne et la guérison finale complète dans la *polymyalgia rheumatica*.

(5) On propose que, faute de mieux, le terme *polymyalgia rheumatica* soit retenu.

Polimialgia reumática.—Estudios de biopsias

SUMARIO

(1) El examen histológico de la sinovia y de las estructuras periarticulares del hombro (cápsula articular, bolsa y aponeuosis profunda) así como de las vainas tendinosas del músculo deltoide en seis casos de polimialgia reumática reveló la existencia de una infiltración poco específica, débil o moderada, por células inflamatorias crónicas. Los vasos sanguíneos pequeños acusaban proliferación endotelial y espesura de la íntima.

(2) Dos casos de artritis reumatoide presentaban alteraciones non-específicas similares, pero esto no se considera como prueba de etiología reumatoide de la polimialgia reumática vista en los casos No. 1 y No. 6.

(3) A la hora presente se considera que en el hombro el dolor y la rigidez musculares y periarticulares se pueden explicar por las alteraciones inflamatorias crónicas de la sinovia, de las estructuras periarticulares y de las vainas tendinosas de los músculos. Respecto a otras articulaciones, el dolor y la rigidez se puede probablemente explicar de la misma manera.

(4) La causa de la polimialgia reumática no es conocida. No se cree que este síndrome esté en relación con la arteritis a células gigantes, ya que hay diferencias apreciables en los rasgos clínicos y en la serie presente no se encontraron pruebas histológicas de arteritis a células

gigantes. Se subraya la evolución benigna, la reacción de Waaler-Rose negativa y, finalmente, el restablecimiento completo en la polimialgia reumática.

(5) Se sugiere que, por falta de mejor, se conserva el término polimialgia reumática.