

# CHRONIC DIFFUSE OEDEMA OF THE RHEUMATOID HAND

## A SIGN OF LOCAL LYMPHATIC INVOLVEMENT

BY

J. L. KALLIOMÄKI\* AND M. VASTAMÄKI

*From the Departments of Medicine and Clinical Chemistry, University of Turku, Finland*

Patients with rheumatoid arthritis sometimes develop chronic oedema of the hand, in no way related to the involvement of finger and wrist joints, and affecting the whole hand diffusely. This swelling, in our experience, is relatively resistant to therapy, though some result may be obtained by diuretics and corticoids. Since we have not found any reports of studies of the aetiological mechanism of this symptom, we have developed a scintigraphic technique to study the lymphatic drainage in such cases.

In lymphoscintigraphy the patient is given a subcutaneous injection of colloidal gold isotope Au<sup>198</sup>, with an average particle size of 5-10 m $\mu$ . Because of its colloidal metallic nature it enters the lymph ducts and is absorbed by the regional lymph nodes so that only a part passes into the blood circulation and liver (Sage, Sinha, Kizilay, and Toulon, 1964). This method was first used to examine the condition of the inguinal, iliacal, and paraaortic lymph nodes in gynaecological tumours, lymphomata (Weissleder, 1966), and Hodgkin's disease (Firuzian and Junge-Helsing, 1966) with varying results; the active dose was injected into the metatarsal spaces. The lymphatic drainage of the breast (Trivellini and Rossi, 1964) and stomach (Sielaff and Deininger, 1966) has also been studied by the scintigraphic technique.

### Present Study

#### Patients

Case 1 was a housewife aged 43, whose classical rheumatoid arthritis had begun 3 years previously. The disease had been continuously active and symmetrical, with symptoms in all joints of the limbs. Roentgenologically the development was identical in both hands. Rheumatoid serology was positive. At the time of

examination the ESR was 72 mm./hr and the Hb 9.7 g./100 ml. blood. The L.E.-cell test was negative.

For over a year the patient's right hand had been swollen and clumsy as far as to the wrist, while the forearm was not swollen. The swelling subsided slightly after the institution of corticosteroid therapy with diuretics at intervals, but never disappeared completely. The left hand showed no swelling, although its rheumatoid changes were equally severe. When conventional lymphography of the patient's swollen hand failed scintigraphy was indicated.

Case 2 was a housewife aged 53, who had had classical rheumatoid arthritis for 7 years. She had been treated with gold salts, corticosteroids, analgesics, and chloroquine. The rheumatoid serology was positive. Roentgenological changes, with erosions, were of identical degree in both hands. At the time of examination the ESR was 58 mm./hr and the Hb 10.5 g./100 ml. blood. The L.E.-cell test was negative.

For 2 years the patient's right hand had shown clumsiness and swelling as far as the forearm. From time to time the swelling subsided slightly with diuretics and corticosteroids, but it never disappeared completely. The left hand showed no swelling although the rheumatoid changes were of the same degree. The patient was admitted to hospital for scintigraphy.

#### Scintigraphic Technique

17  $\mu$ c. (microcuries), in a volume of 0.4 ml., were injected into the first and second metacarpal spaces of the swollen hand of each patient. The same injection (half the quantity) was made into the first metacarpal space of the unswollen hand. The total dose in each case was 51  $\mu$ c., a quarter of the activity usual for the feet. To facilitate subcutaneous spread, 150 IU hyaluronidase (Luronase<sup>R</sup>) was added to the dose in both hands. To provide the predetermined volume, ordinary sterile physiological saline was used. After the injection the patients were asked to move their hands actively. The first scanning was carried out after 18 hours and the second after 3 days, which is quite feasible since the half-life of Au<sup>198</sup> is 2.7 days. The scanner used was a Swedish Nukab with an 11-hole collimator, and the rate was kept constant at 5 mm. per second.

The scintigraphic technique causes the least possible strain to the patient, and the result is easy to reproduce.

\*Correspondence: J. L. Kalliomäki, M.D., Turku, Linnank, 5 C 51, Finland.

a drawback is that a reddish-brown spot often persists for a long time at the site of injection.

### Results

In both cases the results were identical. There was hardly any drainage of lymphatics from the

swollen hand, since no activity was recorded in the regional lymph nodes. In the non-swollen hand drainage was normal, since activity accumulated in the axillary lymph nodes. The results are indicated in Figs 1 and 2.

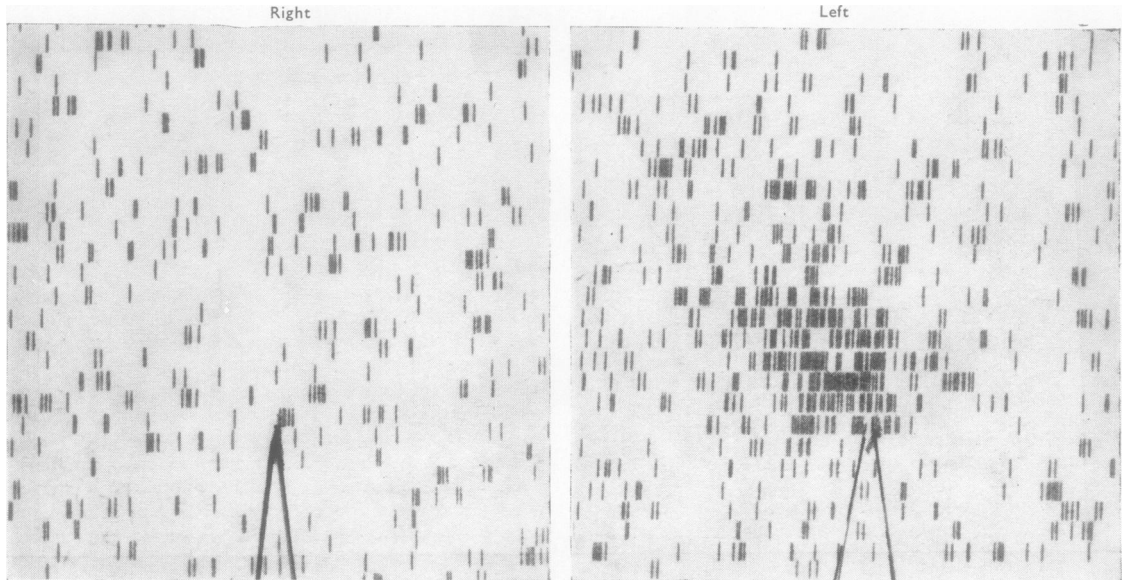


Fig. 1.—Scintigraphic appearance of right and left axillary regions in Case 1, 3 days after metacarpal injection of radio-gold. No activity is seen in the right axillary region.

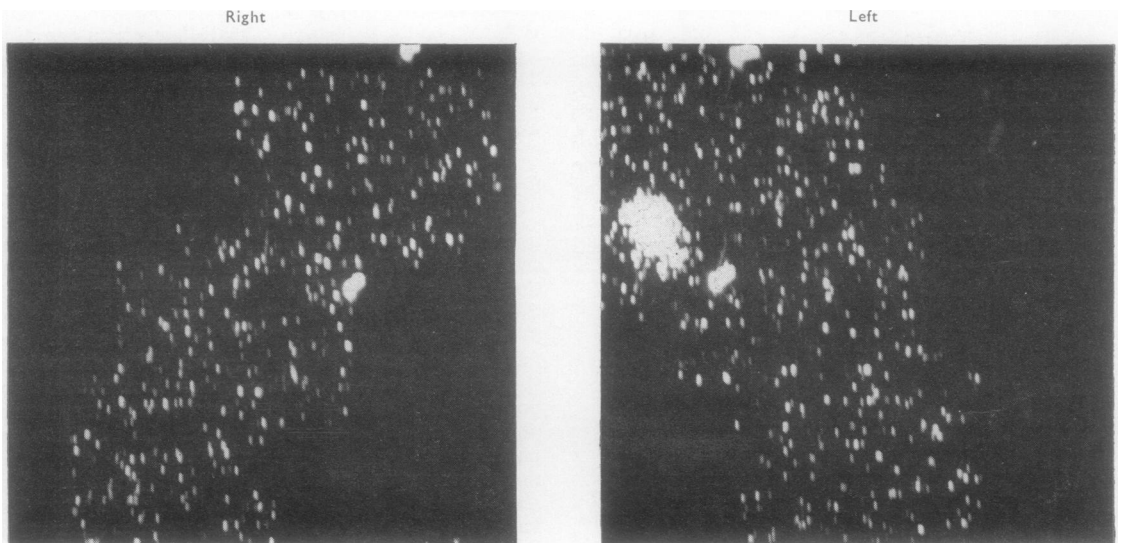


Fig. 2.—Scintigraphic appearance of right and left axillary regions in Case 2, 18 hours after metacarpal injection of radio-gold. No activity is seen in the right axillary region.

### Discussion

If lymphoscintigraphy is performed on the hands of normal subjects, activity accumulation is always seen in the axillary lymph nodes (Heilmann, 1966). as in the present cases in the non-swollen hands, Radio-gold suspension injected intra-articularly has also been found to cause activity in the regional glands (Virkkunen, Krusius, and Heiskanen, 1967). On the other hand, enlarged lymph nodes have been demonstrated by conventional lymphography in the drainage areas of the more severely afflicted joints (Wiljasalo, Julkunen, and Salvén, 1966). In the present cases radio-gold injected into the chronically swollen hand produced no activity in the ipsilateral axillary lymph nodes. It would seem natural, therefore, to attribute this swelling to a local lymphatic involvement; this is also suggested by the failure of conventional lymphography in one of the patients. It is not possible to state definitely whether there was a specific involvement of the

lymphatics, since histological verification is lacking. In both cases the pathological picture of rheumatoid arthritis was classical, and the disease had been continuously very active. The symptom in both cases was present in the right hand, and both patients were right-handed. Whether or not this is of importance for the aetiology cannot be estimated until more cases have been studied.

### Summary

Two female patients are described with classical rheumatoid arthritis and a clumsy oedema, resistant to therapy, for 1-2 years in the right hand. Lymphoscintigraphy on the swollen hands to evaluate the lymphatic drainage revealed no accumulated activity in the axillary lymph nodes, whereas the activity in the non-swollen hands was normal. The oedema is considered to be due to local lymphatic involvement.

### REFERENCES

- Firuzian, N., and Junge-Helsing, G. (1966). "Radioisotope in der Lokalisationsdiagnostik. Vierte Jahrestagung der Gesellschaft für Nuclearmedizin, Heidelberg, 6-8 Oktober, 1966", pp. 181-188 (Die szintigraphische Darstellung des Lymphsystems bei Morbus Hodgkin).
- Heilmann, H. P. (1966). *Ibid.*, pp. 197-199 (Lymphoszintigraphie der Axillarregion beim Mammakarzinom).
- Sage, H. H., Sinha, B. K., Kizilay, D., and Toulon, R. (1964). *J. nucl. Med.*, **5**, 626 (Radioactive colloidal gold measurements of lymph flow and functional patterns of lymphatics and lymph nodes in the extremities).
- Sielaff, H. J., and Dininger, H. (1966). "Radioisotope in der Lokalisationsdiagnostik. Vierte Jahrestagung der Gesellschaft für Nuclearmedizin, Heidelberg, 6-8 Oktober, 1966," pp. 207-212 (Die Lymphoszintigraphie des Magens nach intragastrales submuköser Injektion von <sup>198</sup>Au).
- Trivellini, A., and Rossi, R. (1964). *Acta Un. int. Cancr.*, **20**, 1834 (Scintigraphic technique to evaluate the lymphatic drainage of normal and neoplastic breast).
- Virkkunen, M., Krusius, F. E., and Heiskanen, T. (1967). *Acta rheum. scand.*, **13**, 81 (Experiences of intra-articular administration of radioactive gold).
- Weissleder, H. (1966). "Radioisotope in der Lokalisationsdiagnostik. Vierte Jahrestagung der Gesellschaft für Nuclearmedizin, Heidelberg, 6-8 Oktober, 1966", pp. 181-188 (Möglichkeiten und Grenzen der lymphographischen Lymphknotendiagnostik).
- Wiljasalo, M., Julkunen, H., and Salvén, I. (1966). *Ann. Med. intern. Fenn.*, **55**, 125 (Lymphography in rheumatic diseases).

Oedème diffus chronique de la main rhumatoïde—signe d'affection lymphatique locale ?

### RÉSUMÉ

On décrit les cas de deux patientes atteintes de polyarthrite rhumatoïde classique et d'un oedème in forme, résistant à tout traitement depuis 1 à 2 ans, de la main droite. Une lymphoscintigraphie des mains gonflées pour évaluer le drainage lymphatique ne révéla pas d'activité accumulée dans les ganglions lymphatiques axillaires, tandis que l'activité dans les mains non gonflées fut normale. On attribue l'oedème à l'affection lymphatique locale.

Edema difuso crónico de la mano reumatoïde—signo de afección linfática local ?

### SUMARIO

Se describen los casos de dos enfermas con poliartrosis reumatoïde clásica y con un disforme edema de la mano derecha, resistente desde uno a dos años a toda terapia. La linfosintografía de las manos hinchadas para valorar el drenaje linfático no reveló actividad acumulada en los ganglios linfáticos axilares, mientras que la actividad en las manos no hinchadas fué normal. Se atribuye el edema a la afección linfática local.