

Lymph node iron in rheumatoid arthritis

Histology, ultrastructure, and chemical concentration

K. D. MUIRDEN

The University of Melbourne Department of Medicine, The Royal Melbourne Hospital, Victoria, 3050, Australia

Lymph node enlargement occurs frequently in rheumatoid arthritis and a recent study has indicated that this is more marked in the area of drainage of actively inflamed joints (Robertson, Hart, White, Nuki, and Boardman, 1968). Our observations of iron deposits in the synovium in this disease (Muirden, 1966; Muirden and Senator, 1968) have led us to wonder whether the regional nodes are a possible further area of iron storage. Standard pathological descriptions do not mention the presence of iron pigmentation in rheumatoid lymph nodes (Motulsky, Weinberg, Saphir, and Rosenberg, 1952; Cruickshank, 1958; Gardner, 1965), although Gardner and Roy (1961) did find iron in patients who had received iron therapy or blood transfusions. In patients who had not been given iron there was no significant difference in concentration between rheumatoid and control nodes.

This study reports findings in eleven axillary lymph nodes including specimens from rheumatoid patients who had not received iron therapy and compares them with findings in thirty non-rheumatoid patients and in one patient with gouty arthritis.

Material

Axillary lymph nodes were obtained from eleven patients (6 female, 5 male) with rheumatoid arthritis. There were four biopsy specimens and the remainder were obtained *post mortem*. All satisfied standard diagnostic criteria for 'classical' or 'definite' rheumatoid arthritis (Ropes, Bennett, Cobb, Jacox, and Jassar, 1959). Their ages ranged from 21 to 72 years (mean 55).

Axillary nodes from thirty subjects with no significant joint disease were obtained *post mortem*. There were equal numbers of males and females and the mean age was 69 years. An additional node was obtained from a patient with chronic gouty arthritis with extensive hand involvement who had died from renal failure.

Methods

The lymph nodes were dissected free of surrounding fat and then divided into two portions. One part was fixed in neutral phosphate buffered 10 per cent. formalin and sections were stained with haematoxylin and eosin (H and E) and by the Prussian blue method for iron. Some additional sections were stained with Fontana's silver for melanin and with Zeihl-Neelson stain for lipofuscin. In each case at least three different areas of the same or separate nodes were examined.

A semi-quantitative grading of iron content was made on the Prussian blue stained histological sections, ranging from + denoting small and patchy up to ++++ signifying extensive deposits.

The second portion of the node was used for chemical estimation of iron concentration. The tissue was desiccated at 110°C. for 4 to 6 hrs and its dry mass determined. Melted fat was removed by light blotting before weighing. The sample was then placed in an iron-free fire-clay crucible and ashed in a muffle furnace at a temperature of 600 to 650°C. for 6 to 8 hrs. The material was allowed to cool gradually and sufficient concentrated hydrochloric acid was added to immerse the ash. The acid was later evaporated and 10 ml. iron-free distilled water were added. The iron concentration was measured in a spectrophotometer using a modified serum iron method (Wootton, 1964). Results were expressed as $\mu\text{g./g.}$ dry weight of tissue.

Portions of two rheumatoid biopsy specimens were processed for electron microscopy. The tissue was immediately fixed in ice-cold neutral buffered formaldehyde and later post-fixed with osmium. Staining was with phosphotungstic acid and sections from araldite-embedded blocks were examined in a Hitachi 11A electron microscope.

Clinical details of the rheumatoid patients were recorded. These included duration of disease, sheep cell agglutination titre, range of haemoglobin during the course of the disease, serum iron, and history of therapy with iron or blood transfusions. Patients were assessed as having anaemia related to rheumatoid arthritis when the haemoglobin had fallen below 11 mg. per cent. and where other causes such as gastrointestinal haemorrhage had

been excluded. Patients recorded as receiving iron had all had parenteral therapy.

Results

HISTOLOGY OF RHEUMATOID NODES

(a) Light microscopy

The nodes removed surgically were enlarged and all showed marked follicular hyperplasia (Fig. 1). Three

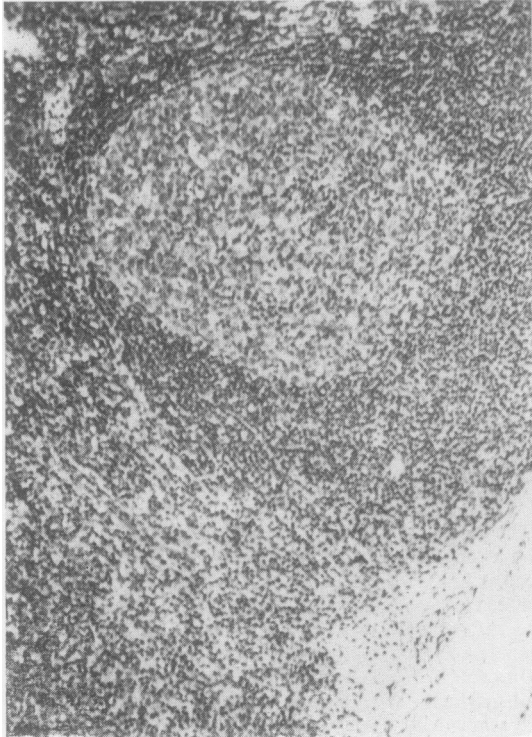


FIG. 1 Follicular hyperplasia with a germinal centre and some increase in sinus cells. H and E $\times 140$.

of seven *post mortem* nodes also showed this feature of large numbers of mature lymphocytes surrounding germinal centres containing paler cells. Plasmacytosis was never a striking feature. Hypertrophy of sinus cells occurred in all the biopsy specimens and was marked in three. Five of the autopsy nodes showed moderate sinus hypertrophy. Erythrophagocytosis was noted in the sinus regions in two biopsy and two *post mortem* nodes (Fig. 2), and in these cases the sinuses were congested with red cells. Neutrophils were also present in the sinuses and adjacent areas of the node in two biopsies (Fig. 3), and these occurred in the absence of apparent infection in the patients concerned.

In eight lymph nodes golden-brown pigment was clearly visible in large macrophages in H and E sections, and Prussian blue staining confirmed that the pigment was mainly iron (Fig. 4). In Case 5 much of the pigment was Prussian blue negative and proved to be melanin on appropriate staining. One

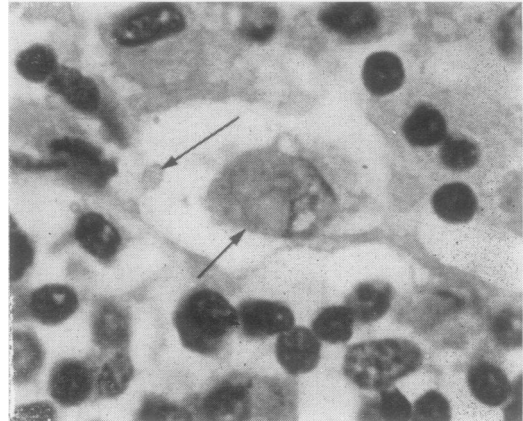


FIG. 2 Erythrophagocytosis. Arrows indicate erythrocytes, one at least within the phagocyte. H and E $\times 1,050$.

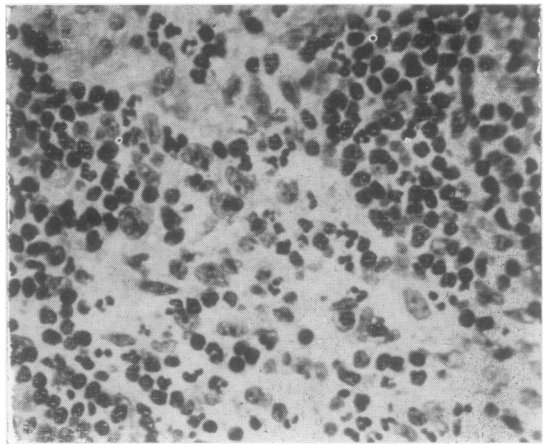


FIG. 3 Sinus region of a node infiltrated with neutrophils. H and E $\times 550$.

node contained no obvious pigment on H and E staining but showed definite Prussian blue-positive material. Iron was absent from only two nodes. It appeared as a faint even staining of some sinus lining cells and as dense granules in large macrophages in both sinus and lymphatic areas of the node including the germinal centre.

(b) Electron microscopy

Cortical areas of the two nodes examined comprised many mature lymphocytes separated by reticulum cells with very long processes and cytoplasm containing endoplasmic reticulum, mitochondria, and small dense bodies which were probably lysosomes (Fig. 5). Endothelial cells, mature plasma cells, and occasional neutrophils were also noted. Both biopsies showed prominent phagocytic reticulum cells containing vacuoles, myelin figures, lipid droplets, and very large lysosomal bodies. Fine electron dense granules were concentrated into these lysosomes and

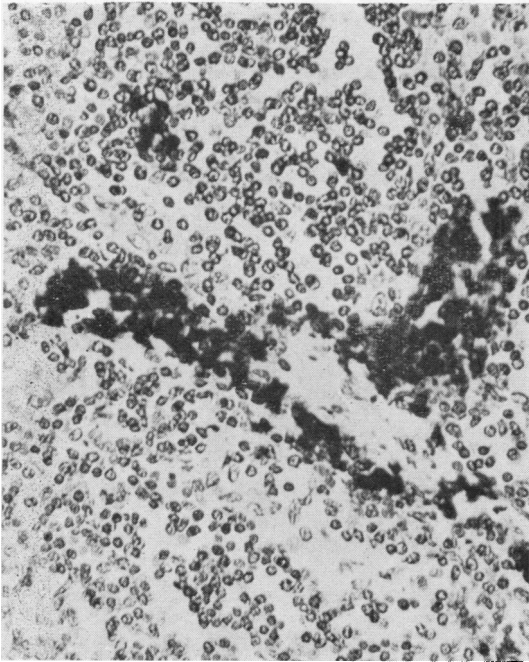


FIG. 4 Dense deposits of iron present within macrophages. Prussian blue. $\times 550$.

scattered throughout the rest of the cytoplasm (Fig. 6, overleaf). High resolution micrographs confirmed that these had the molecular structure of ferritin (Fig. 6, inset).

HISTOLOGY OF NON-RHEUMATOID NODES

In the thirty control axillary nodes, follicular hyperplasia was never seen and sinus cell hypertrophy occurred in only a minority. Pigment was noted in eight cases; in one this was largely melanin and in the others it was iron. Table I shows the grading of histological iron in both controls and

Table I Presence of iron in axillary nodes in 11 rheumatoid patients and 30 controls, by histological findings

Histological grade	Iron present in axillary nodes	
	Rheumatoid patients	Controls
0	2	23
+	3	4
++	3	3
+++	2	0
++++	1	0
Total cases	11	30

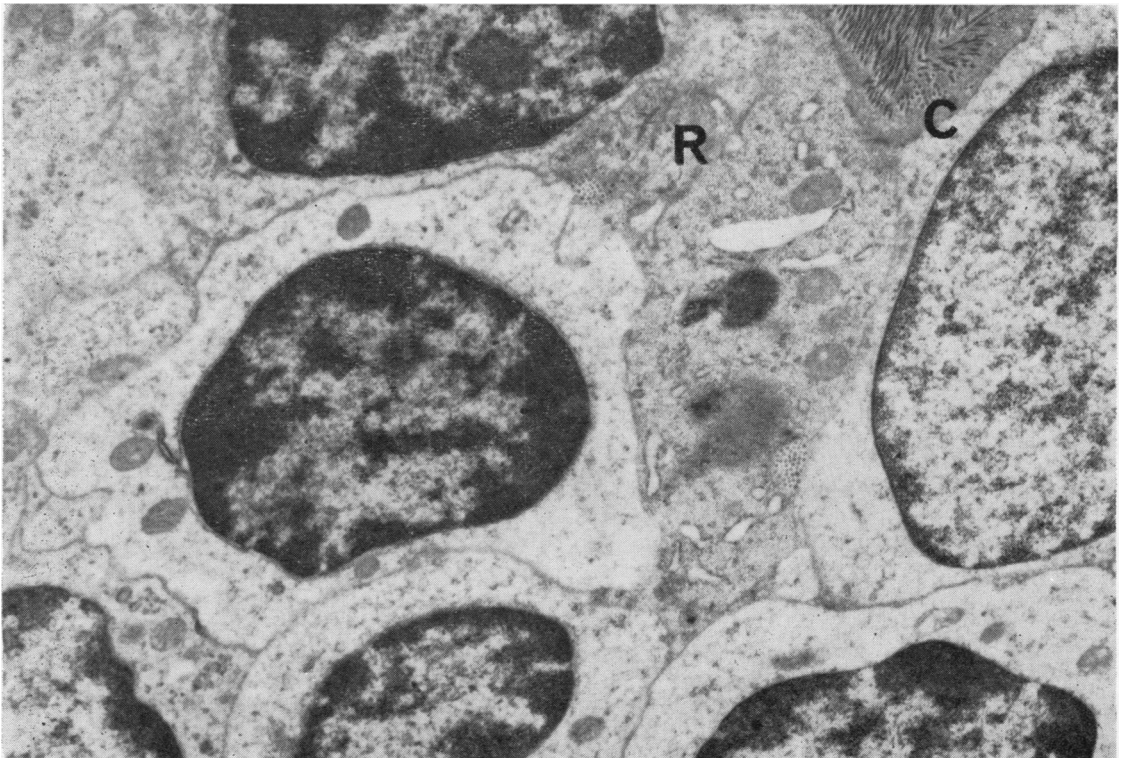


FIG. 5 Electron micrograph. Several lymphocytes are seen together with a reticulum cell (R) which contains dense lysosomal bodies. Interstitial tissue contains collagen (C). $\times 21,500$.

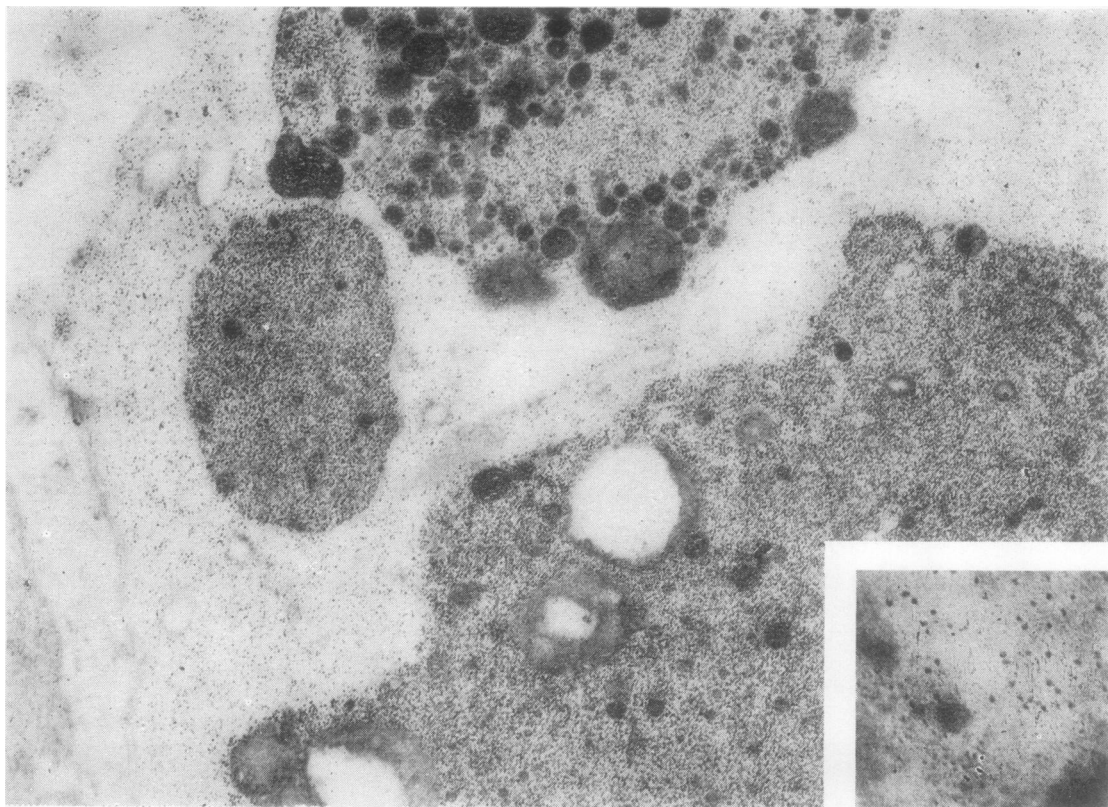


FIG. 6 *Electron micrograph. Phagocytic reticulum cell containing innumerable ferritin granules concentrated within large dense lysosomes. $\times 40,000$. Inset: the molecular structure of ferritin is resolved. $\times 254,000$ approx.*

rheumatoid subjects; deposits of iron in the controls were comparatively rare and when present were never extensive, whereas only two of the rheumatoid patients showed no iron.

A χ^2 analysis, using Fisher's exact test, gives a P value of <0.01 in a comparison between control and rheumatoid nodes with and without iron deposits.

The axillary node in the patient with chronic gout showed extensive deposits of iron within proliferated sinus cells; there was no follicular hyperplasia.

CHEMICAL ESTIMATION OF IRON CONCENTRATION IN AXILLARY NODES

The concentration of iron is shown with the clinical details of the rheumatoid patients in Table II (opposite). There was good correlation in most between the histological assessment and the chemical procedure. A wide range of values was noted and the mean was $102.0 \mu\text{g./g.}$ (S.D. 67.6). The mean concentration of the seven *post mortem* rheumatoid nodes ($77.28 \mu\text{g./g.}$) was lower than that of the four biopsied nodes ($145.25 \mu\text{g./g.}$) but the values were not significantly different ($t' = 1.96$; $P > 0.10$). There was no correlation between the duration of disease or the rheumatoid factor titre and the iron concentration.

In the thirty control cases the mean value was $35.37 \mu\text{g./g.}$ (S.D. 27.37) and the range 17 to $131 \mu\text{g./g.}$ There was no significant age or sex difference. The mean for the females was 28.80 and for the males $41.93 \mu\text{g./g.}$ ($t' = 1.33$; $P > 0.10$). The correlation coefficient between age and iron concentration was 0.03 (not significant).

The difference in values between the control and the rheumatoid nodes was highly significant ($t' = 3.76$; $P < 0.001$). Of possibly greater importance was a comparison between controls and rheumatoid patients not treated with iron or blood transfusions. The mean iron concentration in the latter group of five patients was $70.50 \mu\text{g./g.}$ ($t' = 2.47$; $P < 0.05$).

Seven patients had anaemia recorded at some stage in the course of the disease, and the mean iron concentration for the group was $126.0 \mu\text{g./g.}$ The mean for the remaining four patients was $60.0 \mu\text{g./g.}$ ($t' = 1.70$; $P < 0.10$).

Five of the patients had received iron therapy and for them the mean was $139.8 \mu\text{g./g.}$ compared with $70.5 \mu\text{g./g.}$ for the other six cases ($t' = 1.90$; $P < 0.10$). The smallness of the sample size perhaps explains why neither difference is statistically significant.

Table II Clinical particulars and iron concentration in eleven patients with rheumatoid arthritis

Case No.	Sex	Age (yrs)	Duration of disease (yrs)	Source of node	SCAT titre	Haemoglobin range (g. per cent.)	Therapy for anaemia	Iron in node		Cause of death
								Histological (grade)	Chemical ($\mu\text{g.}/\text{g.}$)	
1	M	51	12	PM	1,024	9.4-15.1	Yes	+++	137	Myocardial infarct
2	F	72	13	PM	2,048	7.9-12.8	Yes	++	152	Myocardial infarct
3	F	43	18	B	0	9.8-11.6	Yes	++++	250	—
4	F	42	6	PM	1,024	8.1-14.0	Yes	+++	95	Atlanto-axial dislocation
5	M	63	14	PM	2,048	11.5-13.0	No	+	22	Cerebral thrombosis
6	M	59	14	B	2,048	14.0	No	+	118	—
7	F	53	3	B	0	7.7-11.0	No	++	145	—
8	M	60	17	PM	256	10.2-13.8	Yes	+	65	Myocardial infarct
9	F	21	14	PM	0	8.3-11.2	No	0	38	Gold toxicity septicaemia
10	F	69	30	PM	NA	11.6-12.8	No	0	32	Myocardial infarct
11	M	69	3	B	128	12.4-13.6	No	++	68	—

PM = *post mortem*. B = biopsy. NA = not available.

The patient with the highest iron content (Case 3) had received many courses of intramuscular iron over a 7-year period and had also been given 3 units of blood for persistent anaemia. There was no evidence of folic acid or vitamin B₁₂ deficiency and blood loss had been excluded. The serum iron varied between 14 and 42 $\mu\text{g.}$ per cent. She had persistently active joint disease and synovial membrane removed at synovectomy from a knee showed extensive and dense iron deposits in synovial macrophages.

The concentration of iron in the node in the patient with chronic gouty arthritis was 162.0 $\mu\text{g.}/\text{g.}$ Unfortunately a history of previous iron intake or blood transfusions was not available for this case nor for most of the controls.

Discussion

Three pathological features not generally recognized were noted in eleven axillary lymph nodes from subjects with rheumatoid arthritis. Deposits of iron, often of an extensive nature, erythrophagocytosis, and a neutrophil infiltrate occurred with varying frequency in the sinus regions. The latter was seen in two of the four biopsied nodes and in neither patient was there evidence of infection. The first two features are probably related. The engulfment of erythrocytes by reticulum cells of the bone marrow is followed by the formation of ferritin (Bessis, 1961) and ferritin was demonstrated in the two nodes subjected to electron microscopy. Ferritin molecules were concentrated into large lysosomal bodies which were identical with those seen in phagocytic cells in rheumatoid synovia (Muirden, 1966), where it was concluded that the iron present was mainly derived from erythrocytes or their lysed remnants. Phagocytic reticulum cells of normal rat lymph nodes feature considerably

smaller lysosomes and these occasionally contain a few ferritin molecules (Han, 1961). A similar derivation from erythrocytes is possible as studies suggest that the reticuloendothelial system (RES) cannot remove iron directly from plasma (Elmlinger, Huff, Tobias, and Lawrence, 1953). Varying numbers of erythrocytes were found in the sinus regions of the control lymph nodes, but erythrophagocytosis was identified in only three of the thirty nodes. This is a smaller proportion than the 27 per cent. shown by Smith (1958) in a study of 167 autopsy axillary nodes where haemosiderin was absent in the majority.

Two other sources of iron have to be considered. Tissue breakdown products from the inflammatory granulation tissue in the joints are likely to be carried to the regional lymph nodes. Sinus cell hyperplasia fits well with the stimulus provided by excessive amounts of cell debris and possibly immune complexes. Some of the iron from the large deposits in the joints (Muirden and Senator, 1968; Mowat and Hothersall, 1968) is likely to be slowly released *via* lymphatics and to be retained by the filter of phagocytic sinus cells. The iron-containing reticulum cells then seem to spread through the whole cortex as they appear in the lymphocyte follicles and even in the germinal centres. In this way iron is an interesting marker for an immune mechanism linking the joint to antibody production in the lymph nodes. The iron deposits in the patient with chronic gouty arthritis may also have arisen from the inflamed joints.

The highest values of iron concentration in the nodes were found in those patients treated with intramuscular iron and blood transfusions, a fact also noted by Gardner and Roy (1961). Iron preparations are invariably given into the gluteal region and iron is absorbed *via* lymphatics to the regional nodes (Cappell, Hutchison, Hendry, and Conway, 1954). Because of the extensive subcutaneous lymphatic

network it is likely that some will pass directly to axillary nodes. The injected iron rapidly reaches the circulation and there is a rise in serum iron within 24 hours. After a single injection of 50 mg. iron sorbitol, Strandberg (1966) demonstrated levels of 400 $\mu\text{g.}$ per cent. or more in rheumatoid patients where the mean pre-treatment level was 48 $\mu\text{g.}$ per cent. In another series, which included some rheumatoid patients, given 250 mg. iron dextran on four consecutive days, the serum level rose to 1,200 $\mu\text{g.}$ per cent. (Karlefors and Norden, 1958). From the circulation iron dextran, which has a molecular weight of 180,000 to 230,000, is extracted by the RES before being utilized for red cell production (Martin, Bates, Beresford, Donaldson, McDonald, Dunlop, Sheard, London, and Twigg, 1955), and even iron sorbitol, with a low molecular weight of less than 5,000, is metabolized in part at least through the RES (Wetherley-Mein, Buchanan, Glass, and Pearce, 1962). Ferritin is found when iron dextran is taken up by subcutaneous macrophages (Muir and Golberg, 1961) and by synovial cells (Ball, Chapman, and Muir, 1964), and there seems to be no reason why phagocytic reticulum cells of lymph nodes should not be capable of this conversion. It is relevant that particulate matter introduced into the circulation is more rapidly removed in patients with rheumatoid arthritis than in controls, and substances used in these experiments include gold, lipid emulsion, and iron oxide (Salky, Mills, and DiLuzio, 1965).

Iron deposited in lymph nodes after intramuscular iron is unlikely to be confined to axillary and inguinal nodes. We have had one mediastinal node specimen from a rheumatoid patient with a long history of anaemia treated with multiple courses of intramuscular iron. The node was large and cellular but proliferation of lymphocyte follicles and sinus cells was not marked. Extensive deposits of carbon and haemosiderin were noted and the iron concentration was 259 $\mu\text{g./g.}$ which is higher than values recorded in any of the axillary nodes.

The higher iron levels in anaemic patients seem largely due to the iron therapy they have received. Haemosiderin deposits and a high iron concentration did, however, occur in the absence of treatment with haematinics, and a significant difference was shown between iron values in controls and those in rheumatoid patients not treated with iron. The difference might have been greater had it been possible to exclude control cases who had received blood transfusions or iron in the past.

The presence of iron deposits in lymph nodes is relevant to the abnormality in iron metabolism responsible for the anaemia of rheumatoid arthritis. The hypoferraemia coupled with evidence of increased iron storage (Lawson, Owen, and Mowat,

1967) suggests that the RES may be reluctant to release storage iron (Weinstein, 1959; Owen and Lawson, 1966). Efforts to demonstrate increased concentrations of iron in liver, spleen, and lymph nodes in patients not treated with iron have up until now been unsuccessful (Gardner and Roy, 1961). Recent studies suggest the synovial membrane as an important source of iron sequestration (Muir and Senator, 1968; Mowat and Hothersall, 1968), and we have provided evidence that the clearance of erythrocyte-bound iron from inflamed joints is very slow (Muir, 1969). The lymph nodes appear to be an additional area of iron storage and it is disappointing that much of the parenteral iron used in the therapy of the anaemia is deposited in lymph nodes rather than in the developing normoblasts. Iron infusions may even result in painful lymphadenopathy with systemic symptoms as shown by Theodoropoulos, Makkous, and Constantoulakis (1968).

The rapid restoration of serum iron to normal levels and the haemoglobin rise occurring in response to corticosteroid and corticotrophin therapy (Whittingham, Balazs, and Mackay, 1967; Mowat, Hothersall, and Aitchison, 1969) has yet to be explained in the terms of the suggested iron abnormality. Steroids, however, do have a depressing effect on RES phagocytosis (Salky and others, 1965), and Wardle and Attan (1967) suggested that the abnormal reaction of reticuloendothelial cells to iron may be related to their participation in immune reactions. The proliferation of phagocytic sinus cells in lymph nodes and the increased size and number of the macrophage type A cell in rheumatoid synovia shown by electron microscopy (personal observations) do not occur solely in response to a stimulus to remove iron. Steroid suppression of disease activity involving reduction in the phagocytic stimulus of tissue breakdown products and immune complexes may allow a release of iron from reticulum cells and synovial macrophages.

Summary

Histological examination of axillary nodes from subjects with rheumatoid arthritis indicates that haemosiderin-containing macrophages are a frequent finding. Nine of eleven nodes showed iron pigment, and electron microscopy confirmed the presence of ferritin in reticulum cells in the two biopsies studied. The mean concentration of iron estimated chemically after ashing segments of the nodes was 102.0 $\mu\text{g./g.}$ dry weight of tissue. This was significantly higher than the values for thirty control nodes in which the mean was 35.4 $\mu\text{g.}$ The mean of six rheumatoid patients who had not been treated with parenteral iron or blood transfusions was 70.5 $\mu\text{g.}$, which was still significantly higher than that of

the controls. One patient with chronic gouty arthritis also had extensive deposits of iron in the axillary nodes.

The presence of increased iron in lymph nodes, together with the synovial membrane deposits, is seen as part of the abnormality of iron metabolism which is responsible for the anaemia of rheumatoid arthritis.

I should like to thank Dr. R. Strang and Dr. I. Mackay for permission to report details of individual cases and Dr. A. E. Seymour for providing the material in Case 6. Prof. H. Attwood kindly provided the lymph nodes used for controls and the surgical biopsies were performed by Mr. K. Mills and Mr. D. Ritchie. I should also like to thank Prof. R. R. H. Lovell for advice and encouragement, and Miss K. Gardner, Mr. I. Kohlman, and Mr. K. Rogers for valuable technical assistance.

References

- BALL, J., CHAPMAN, J. A., AND MURDEN, K. D. (1964) *J. Cell Biol.*, **22**, 351 (The uptake of iron in rabbit synovial tissue following intra-articular injection of iron dextran).
- BESSIS, M. (1961) In 'The Cell', vol. 5, ed. J. Brachet and A. E. Mirsky, p. 163. Academic Press, New York and London.
- CAPPELL, D. F., HUTCHISON, H. E., HENDRY, E. B., AND CONWAY, H. (1954) *Brit. med. J.*, **2**, 1255 (A new carbohydrate-iron haematinic for intramuscular use).
- CRUICKSHANK, B. (1958) *Scot. med. J.*, **3**, 110 (Lesions of lymph nodes in rheumatoid disease and in disseminated lupus erythematosus).
- ELMLINGER, P. J., HUFF, R. L., TOBIAS, C. A., AND LAWRENCE, J. H. (1953) *Acta haemat. (Basel)*, **9**, 73 (Iron turnover abnormalities in patients having anemia: serial blood and *in vivo* tissue studies with Fe⁵⁹).
- GARDNER, D. L. (1965) 'Pathology of the Connective Tissue Diseases'. Arnold, London.
- AND ROY, L. M. H. (1961) *Ann. rheum. Dis.*, **20**, 258 (Tissue iron and the reticulo-endothelial system in rheumatoid arthritis).
- HAN, S. S. (1961) *Amer. J. Anat.*, **109**, 183 (The ultrastructure of the mesenteric lymph node of the rat).
- KARLEFORS, T., AND NORDÉN, A. (1958) *Acta med. scand.*, Suppl. 342, 'Studies on Iron-Dextran Complex'.
- LAWSON, A. A. H., OWEN, E. T., AND MOWAT, A. G. (1967) *Ann. rheum. Dis.*, **26**, 552 (Nature of anaemia in rheumatoid arthritis. VII. Storage of iron in rheumatoid disease).
- MARTIN, L. E., BATES, C. M., BERESFORD, C. R., DONALDSON, J. D., McDONALD, F. F., DUNLOP, D., SHEARD, P., LONDON, E., AND TWIGG, G. D. (1955) *Brit. J. Pharmacol.*, **10**, 375 (The pharmacology of iron-dextran intramuscular haematinic).
- MOTULSKY, A. G., WEINBERG, S., SAPHIR, O., AND ROSENBERG, E. (1952) *Arch. intern. Med.*, **90**, 660 (Lymph nodes in rheumatoid arthritis).
- MOWAT, A. G., AND HOTHERSALL, T. E. (1968) *Ann. rheum. Dis.*, **27**, 345 (Nature of anaemia in rheumatoid arthritis. VIII. Iron content of synovial tissue in patients with rheumatoid arthritis and in normal individuals.
- , —, AND AITCHISON, W. R. C. (1969) *Ibid.*, **28**, 303 (Nature of anaemia in rheumatoid arthritis. XI. Changes in iron metabolism induced by the administration of corticotrophin).
- MUIR, A. R., AND GOLBERG, L. (1961) *Quart. J. exp. Physiol.*, **46**, 289 (Observations on subcutaneous macrophages. Phagocytosis of iron-dextran and ferritin synthesis).
- MURDEN, K. D. (1966) *Ann. rheum. Dis.*, **25**, 387 (Ferritin in synovial cells in patients with rheumatoid arthritis).
- (1969) *Ibid.*, **28**, 548 (Clearance of Fe⁵⁹ labelled erythrocytes from normal and inflamed rabbit knee joints. I. Relationship to the anaemia of rheumatoid arthritis).
- AND SENATOR, G. B. (1968) *Ibid.*, **27**, 38 (Iron in the synovial membrane in rheumatoid arthritis and other joint diseases).
- OWEN, E. T., AND LAWSON, A. A. H. (1966) *Ibid.*, **25**, 547 (Nature of anaemia in rheumatoid arthritis. VI. Metabolism of endogenous iron).
- ROBERTSON, M. D. J., HART, F. DUDLEY, WHITE, W. F., NUKI, G., AND BOARDMAN, P. L. (1968) *Ibid.*, **27**, 253 (Rheumatoid lymphadenopathy).
- ROPEL, M. W., BENNETT, G. A., COBB, S., JACOX, R., AND JESSAR, R. A. (1959) *Ibid.*, **18**, 49 (Diagnostic criteria for rheumatoid arthritis. 1958 Revision).
- SALKY, N. K., MILLS, D., AND DI LUZIO, N. R. (1965) *J. Lab. clin. Med.*, **66**, 952 (Activity of reticuloendothelial system in diseases of altered immunity).
- SMITH, F. (1958) *J. Path. Bact.*, **76**, 383 (Erythrophagocytosis in human lymph-glands).
- STRANDBERG, O. (1966) *Acta med. scand.*, Suppl. 454, 'Anemia in Rheumatoid Arthritis', Chap. 3, p. 52 (Distribution and utilization of Fe⁵⁹ labelled iron-sorbitol-citric acid (Jectofer) in patients with rheumatoid arthritis and healthy controls).
- THEODOROPOULOS, G., MAKKOUS, A., AND CONSTANTOULAKIS, M. (1968) *J. clin. Path.*, **21**, 492 (Lymph node enlargement after a single massive infusion of iron dextran).
- WARDLE, E. N., AND ATTAN, J. (1967) *Brit. J. Haemat.*, **13**, 194 (An electron microscope study of bone marrow in rheumatoid disease).

- WEINSTEIN, I. M. (1959) *Blood*, **14**, 950 (Correlative study of the erythrokinetics and disturbances in iron metabolism associated with the anaemia of rheumatoid arthritis).
- WETHERLEY-MEIN, G., BUCHANAN, J. G., GLASS, U. H., AND PEARCE, L. C. (1962) *Brit. med. J.*, **1**, 1796 (Metabolism of ^{59}Fe -sorbitol complex in man).
- WHITTINGHAM, S., BALAZS, N. D. H., AND MACKAY, I. R. (1967) *Med. J. Aust.*, **2**, 639 (The effect of corticosteroid drugs on serum iron levels in systemic lupus erythematosus and rheumatoid arthritis).
- WOOTTON, I. D. P. (1964) *In 'Micro-analysis in Medical Biochemistry'*, 4th ed., p. 124. Churchill, London.

RÉSUMÉ

Le fer dans le ganglion lymphatique chez les malades atteints de polyarthrite rhumatoïde
L'histologie, l'ultrastructure, et la concentration chimique

L'examen histologique des ganglions axillaires des sujets atteints de polyarthrite rhumatoïde indique que les macrophages contenant l'hémossiderine sont une occurrence fréquente. Neuf des onze ganglions montraient le pigment de fer et la microscopie électronique confirmait la présence de ferritine dans les cellules réticulaires dans les deux biopsies étudiées. La moyenne de la concentration du fer estimée chimiquement après que les segments des ganglions avaient été convertis en cendres était 102,0 $\mu\text{g./g.}$ de poids sec de tissu. Cela a été beaucoup plus élevé que les valeurs dans trente ganglions témoins où la moyenne était 35,4 $\mu\text{g.}$ la moyenne de six malades rhumatoïdes qui n'avaient pas été traités avec du fer injectable ou par des transfusions de sang était 70,5 $\mu\text{g.}$, qui était encore plus élevée que la moyenne des témoins. Un malade atteint d'arthrite goutteuse chronique avait aussi des dépôts considérables de fer dans les ganglions axillaires.

Une augmentation de fer dans les ganglions ainsi que ses dépôts dans la membrane synoviale sont considérés comme une anomalie du métabolisme du fer qui est responsable de l'anémie dans la polyarthrite rhumatoïde.

SUMARIO

El hierro en ganglios linfáticos en la poliartritis reumatoide
Histología, ultraestructura y concentración química

Un examen histológico de los ganglios axilares en sujetos con poliartritis reumatoide indica que se encuentran con frecuencia macrófagos que contienen hemossiderina. Nueve de once ganglios revelaron pigmento de hierro, y la microscopía electrónica confirmó la presencia de ferritina en el retículo celular en las dos biopsias estudiadas. La concentración media de hierro, calculada químicamente después de reducir a cenizas segmentos de los ganglios, era de 102.0 $\mu\text{g./g.}$ de peso seco de tejido. Esto era significativamente mayor que los valores correspondientes a treinta ganglios testigo, en los cuales el promedio era de 35.4 $\mu\text{g.}$ El promedio de seis pacientes reumatoides que no habian sido tratados con hierro parentérico o transfusión de sangre era de 70.5 $\mu\text{g.}$, que seguía siendo significativamente más alto que le de los testigos. Un paciente con artritis gotosa crónica presentaba también grandes depósitos de hierro en los ganglios axilares.

El exceso de hierro en los ganglios linfáticos, junto con los depósitos en la membrana sinovial, se considera como parte de la anomalía del metabolismo del hierro que produce la anemia en la poliartritis reumatoide.