

# Capillaroscopic observations in rheumatic diseases\*

W. REDISCH,† E. J. MESSINA, G. HUGHES, AND C. McEWEN

Department of Medicine and the Rheumatic Diseases Study Group, New York University Medical Center, New York, N.Y.

The role of the vasculature in rheumatic diseases has been a subject of speculation and investigation for some time. Wider recognition of the fact that disturbances in microcirculation play a major, if not perhaps a primary, role in a number of clinical entities has led to attempts to study the microvessels in this group of diseases. This paper is a report on rheological and morphological cutaneous capillary changes observed in rheumatoid arthritis (RA), progressive systemic sclerosis (PSS), localized scleroderma (LS), systemic lupus erythematosus (SLE), psoriatic arthritis, and dermatomyositis.

Since a review of the literature has shown the need for a more uniform terminology, an attempt is also made to suggest a preliminary glossary.

## Methods and materials

The capillary microscope used in this study consists of a Leitz binocular microscope modified for photography as well as observation with vertical illumination. The light source for observation is a 60 watt tungsten lamp, for photography a xenon gas flash tube, its power derived from the Leitz Microblitz 300. Flash duration is 1/1000th of a second; the camera used is a Leica M-1. To examine nailfold capillaries, the patient is placed in a sitting position with the hand at heart level. A drop of cedar-wood oil is applied to the skin at the base of the finger nail, and by focusing the beam of light vertically on the skin through

the microscope, the capillary loops become visible. Examination of the capillaries in the area of the medial malleoli and volar surfaces of the forearm is performed with the patient in a supine position. All observations are performed with the subjects in a comfortable environmental temperature (22° to 25° C.).

A range of physiological patterns was established on the basis of the examination and observation of 200 healthy subjects. Areas studied included the nailfolds of the 3rd and 4th fingers of both hands, and the skin over the medial malleoli and the volar surface of the forearms. In the patients, areas with skin of normal appearance were observed and photographed as well as overt lesions. Table I groups the patients, who were all under study by the Rheumatic Diseases Study Group, according to established clinical diagnosis. Those with rheumatoid arthritis met the criteria for 'definite' or 'classical' disease; 41 were sero-positive and one sero-negative. The diagnoses of systemic lupus, scleroderma, dermatomyositis, and psoriatic arthritis were based on typical clinical, laboratory, and histological criteria. The three patients diagnosed as having 'possible systemic lupus' presented the following features: all had disseminated rashes and arthralgias but negative LE and antinuclear antibody tests. In one the illness appeared after taking hydralazine for more than a year; another had Sjögren's syndrome and cryoglobulinaemia.

In order to avoid subjective bias, the following procedure was followed: Observer A examined and took photomicrographs; Observer B read the photomicrographs without previous knowledge of the patient's name or diagnosis or the date of examination. 'Normal subjects'

**Table I** Clinical particulars of 111 patients and 200 controls

Clinical diagnosis	No. of patients	Age (yrs)		Sex	
		Average	Range	Female	Male
Rheumatoid arthritis	31	50.7	23-67	21	10
Progressive systemic sclerosis	25	43.4	24-63	22	3
Localized scleroderma	6	46.8	27-64	5	1
Systemic lupus erythematosus	34	37.7	16-70	33	1
Possible systemic lupus	3	48.6	38-56	3	0
Psoriatic arthritis	9	49.7	33-52	2	7
Dermatomyositis	3	39.0	29-51	2	1
'Normal' controls	200	43.9	17-86	102	98

\* This work was supported by the National Institutes of Health, U.S.P.H.S. Grant Nos. AM 8659, AM 1431 and AM 5064.

† Now at New York Medical College.

were interspersed with patients. The findings were recorded according to slide numbers which later were used to determine the individual's name and diagnosis.

### Terminology and definitions

In the following paragraphs the terms used in this paper for description of the rheological and morphological characteristics are defined.

#### A. Rheological aspects

Direct observation in healthy subjects reveals capillary blood flow in the afferent limb to be continuous and recognition of individual cells difficult. As the blood approaches the efferent limb of the capillary, it is slowed, and recognition of individual cells is facilitated. The flow may be interrupted for periods lasting between a few seconds to as long as 90 seconds. During this time the capillary loop is not visible. Under physiological conditions this intermittency of flow may occur in two to four of the thirty loops observed in 1 sq. mm. The activity may shift in part or whole to different groups of capillaries.

SLUGGISH FLOW is that rate of flow which permits distinction of individual cells over prolonged periods of observation (hours-days) especially on the afferent side of the capillary channel. It may be observed in morphologically unaltered as well as altered loops.

AGGREGATE FLOW is characterized by the adherence of red cells to each other. Under physiological conditions in healthy individuals, it may occasionally be observed in the efferent limbs of the capillaries and subpapillary venous plexuses. The normal slowing of flow through this part of the microcirculation tends to favour aggregate formation. Aggregates, however, are rarely observed in the afferent limbs of the capillaries in healthy subjects; normally, they are dispersed and flow continues as a single or double row of cells. Failure of these aggregates to break up and their widespread appearance in morphologically altered or unaltered loops is designated *increased cellular aggregation with delayed or non-dispersion of aggregates*. This finding has also been called sludged blood (Knisely, Block, Eliot, and Warner, 1947), intravascular agglutination (Lutz, 1951), and disseminated intravascular coagulation (Hardaway, 1965).

PLASMA SKIMMING. The intravascular separation of cellular elements from plasma results in blood flow through the capillaries showing predominantly plasma and few erythrocytes. The phenomena contributing to this observation are increased vasomotor activity causing central entrapment and separation of cells from plasma and/or an increased tendency toward aggregate formation without dispersion, which causes partial, temporary, or permanent blockage at the origin of the capillary acting as a filter allowing primarily plasma flow. In normal subjects without aggregate flow plasma skimming occurs in a small percentage of loops if it occurs at all. When observed at all test sites and in more than 5 per cent. of the loops it is referred to as *increased intravascular separation of cellular elements from plasma* or *increased plasma skimming*.

STASIS OF ERYTHROCYTES and EXTRAVASATION OF RED BLOOD CELLS were observed in varying degrees in most of the entities studied; they represent the most severe rheologic change observed and tend to occur in the most severe and advanced cases. It is presumed to result from actual breaks in the capillary walls.

#### B. Morphological aspects

The general configuration of cutaneous capillaries at the nailfolds, ventral forearms, and malleoli is hairpin or U-shaped.

CRISSCROSSING, or crossing of afferent and efferent limbs, is a physiological variation and is sometimes dependent on the angle and plane at which the capillary is viewed. The terms *figure of eight* (Walls and Buchanan, 1956) and *crisscrossing* (Hauptmann, 1946) have been used interchangeably with the term TORTUOSITY. This, however, is the term we have used to describe undulation of the capillary limbs; the transitional and efferent limbs are generally involved, rarely the afferent. In healthy individuals, tortuosity occurs in not more than 5 per cent. of the loops and *increased tortuosity* is taken to mean the occurrence of such undulations in more than 10 per cent. of the loops. In considering tortuosity (which included *figure of eight*) as a morphological abnormality, Walls and Buchanan (1956) found marked variations from nailfold to nailfold and from one hand to the other. We have considered increased tortuosity to be present only where there was no significant change in frequency of occurrence from nailfold to nailfold in the same individual.

MEANDERING describes the combined effect of undulation and coiling of all three capillary limbs, causing the capillary to appear wound around and upon itself. *Meandering with tight terminal convolutions* denotes undulations close together at the transition from afferent to efferent limb only. This formation of capillary loops has been previously described as a coiled capillary ball (Ross, 1964). *Meandering with loose convolutions* describes the appearance when undulations are further apart all along the loop, including the afferent, transitional, and efferent limbs. Other terms which have been used to describe this type of capillary are *thick clumpy crops* and *corkscrew loops* (Gilje, O'Leary, and Baldes, 1953; Ross, 1966).

WIDTH. The average width of the efferent limb is 20  $\mu$  (range 12 to 30  $\mu$ ). A width of 35  $\mu$  or greater is described as *widening\* of the efferent limb*. The average width of the afferent limb is found to be 10  $\mu$  (range 5 to 20  $\mu$ ). A width of 25  $\mu$  or greater is described as *widening the afferent limb*. Generally, there exists a ratio between the widths of the efferent and afferent limbs with the former generally 1.5 to twice as wide and occasionally three to four times as wide as the latter. When this ratio is exceeded it is described as *disproportionate widening of the efferent limb*.

The apical or transitional portion of the capillary loop is intermediate in width (17  $\mu$ , range 10 to 25  $\mu$ ). When the width of the transitional segment is greater than that

\*The terms 'widening and narrowing' rather than 'dilation' and 'constriction' are used, because measurements of the width of the channel are based primarily on the width of the blood column; the actual state of the capillary wall in relation to the width of the blood column has not yet been sufficiently investigated.

of the efferent limb the appearance is described as *apical widening*.

The subpapillary venular plexus is that anastomosing network of vessels into which capillary flow continues; these vessels may or may not be visible. Flow is slower here than in the capillary loops. When excessively widened, the subpapillary venular plexus is always visible; flow is then extremely sluggish, giving the impression of 'congestion'. This is described as *subpapillary venular plexus widening and engorgement*. When the efferent capillary limb or venular plexus or both take on the appearance of 'linked sausages', it is described as *focal narrowing and widening* of efferent capillary limb and/or venular plexus.

**LENGTH.** The average visible length of a nailfold capillary, including afferent, transitional, and efferent limbs, is 475  $\mu$ ; *elongation of loops* refers to capillaries exceeding 700  $\mu$  in length.

**NUMBER.** Under controlled conditions of comfort temperature (22° to 25° C.), the number of capillaries visible in 1 sq. mm. ranges between ten and thirty. When the number of visible capillaries is below five, this is described as *marked paucity of loops*; when it is above thirty, as *increased number of loops*. In some instances a diminished number of visible loops is associated with *enlargement of visible individual loops* and is described as such.

**PATTERN.** Nailfold capillaries are observed to lie in parallel rows with the transitional limb pointing towards the distal end of the finger. When this parallel pattern of nailfold loops is lost, it is called *disarrangement of capillary polarity*.

## Results

Tables II and III list the incidence of observed rheological and morphological changes in the various entities studied. The reader is directed to these Tables

for a more extensive analysis of the findings, only the most important features being presented below.

In order to be considered significant the rheological and morphological deviations were tabulated only if observed in the third and fourth nailfolds of both hands and at least one of the other test sites.

Measurements of linear flow velocity have so far served no useful purpose, since fluctuations exist within different segments of a single capillary and between capillaries of the same and different nailfolds. The nature and character of flow has been found more informative, especially when the changes are observed at several test sites, indicating a systemic rather than a local phenomenon.

## General

The rheological changes reported here, when observed, were found to be present at all test sites in 'normal' appearing skin as well as in lesions or involved areas. With the majority of the rheological changes, no correlation with treatment could be clearly demonstrated. One parameter, namely increased cell aggregation with delayed dispersion of aggregates, correlated well with the state of disease, in that clinical exacerbations were associated with recorded increase and clinical remissions, whether spontaneous or drug-induced, with recorded decrease in this flow change.

In all the diseases presented in this paper, sluggish flow and dusky colour of the blood column were generally found together. This tends to indicate, as one would suspect, that the longer transit time through the capillary causes the blood to give up more of its oxygen and, therefore, to take on a deeper bluish colour as opposed to its normal pink or red. Increased cellular aggregation with delayed

**Table II** *Incidence of rheological changes observed in various rheumatic diseases (per cent.)*

Rheological change	Diagnosis						
	Rheumatoid arthritis	Progressive systemic sclerosis	Localized scleroderma	Systemic lupus erythematosus	Possible SLE	Psoriatic arthritis	Dermatomyositis
Sluggish flow	58	100	83	97	100	100	100
Increased plasma skimming	71	None	None	9	67	None	None
Dusky colour of blood column	52	100	83	97	100	100	100
Increased cellular aggregation with delayed dispersion of cell aggregates	39	100	67	97	100	67	67
Extravasation	13	56	17	29	67	67	100
Stasis of erythrocytes	13	56	None	15	67	67	100

dispersion of aggregates was observed in 67 to 100 per cent. of the patients in every disease group except rheumatoid arthritis, in which it was observed in only 39 per cent. But rheumatoid arthritis is the only group in which increased plasma skimming was observed in a significant number of patients (71 per cent.). As explained earlier, plasma skimming can be the result of two phenomena acting singly or together, namely increased vasomotor activity and increased cellular aggregation with delayed dispersion of cell aggregates. However, almost three-quarters of the rheumatoid arthritis patients with plasma skimming were not those with increased cellular aggregation. Increased vasomotor activity is not always readily apparent here, since small diameter changes can produce this effect and yet not be seen because of the nature of the technique and opacity of the skin, but it is interesting that 71 per cent. of the rheumatoid patients were observed to have a paucity of visible capillaries which might

be explained as a result of increased vasomotor activity with vasoconstriction of precapillary arterioles and closure of capillary loops. Further, these patients were, in general, those in which increased plasma skimming was observed.

The photomicrographs (Figs 1 to 6) are examples of deviations of the basic microcirculatory pattern as seen in each disease. These are taken from representative areas and not from those which appeared clinically to be the most severely affected. It is possible (though not probable) that these places were previously involved and subsequently healed (example, psoriatic plaque).

Increased tortuosity and widening of all three capillary limbs were the most common findings in all the patients. They were observed to occur together as a rule when the normal loops in the same field were also widened. When the normal loops were not wide, the tortuous loops could be seen to be of normal calibre or wider.

**Table III** Incidence of morphological changes observed in various rheumatic diseases (per cent.)

Morphological change	Diagnosis						
	Rheumatoid arthritis	Progressive systemic sclerosis	Localized scleroderma	Systemic lupus erythematosus	Possible SLE	Psoriatic arthritis	Dermatomyositis
Increased tortuosity (transitional and efferent limb)	48	24	33	68	100	67	100
Meandering with tight terminal convolutions	None	None	None	None	None	100	None
Meandering with loose convolutions	None	None	None	91	100	None	None
Disproportionate widening of efferent limb	6	None	33	38	100	None	None
Widening of all three limbs	42	100	50	88	100	44	100
Apical widening	16	None	16	35	100	None	None
Venular plexus widening and engorgement	42	32	16	38	33	11	None
Focal narrowing and widening of efferent limb and venules	10	8	16	18	None	None	33
Elongation of loops (linear)	42	None	None	21	67	None	None
Diminished number of loops associated with enlargement of loops	None	100	33	6	None	None	33
Paucity of visible capillaries	71	100	16	12	100	None	33
Disarrangement of capillary polarity	13	36	16	15	None	None	None

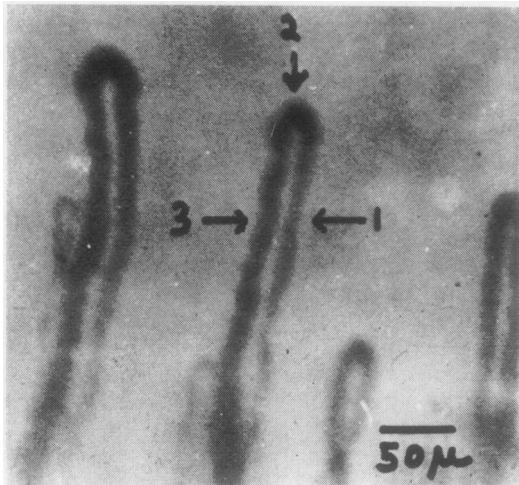


FIG. 1 Example of long moderately widened, normal hairpin-shaped nailfold capillaries. (1) Afferent limb, (2) transitional or apical limb, (3) efferent limb.

#### *Rheumatoid arthritis*

In contrast to the other diseases, rheumatoid arthritis did not present with any single rheological or morphological deviation with an incidence greater than 71 per cent. The two most frequently observed changes were increased plasma skimming and paucity of visible capillaries (each in 71 per cent. of the patients). Linear elongation of loops was observed in 42 per cent. of the rheumatoid arthritis patients (Fig. 2). The possible significance of this finding is dealt with in detail in the discussion.

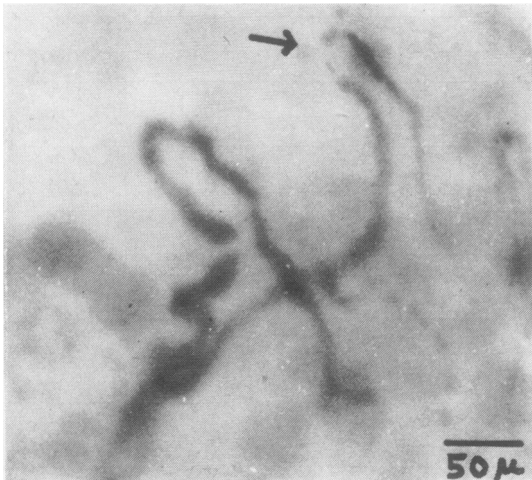


FIG. 2 Pattern of nailfold capillaries as observed in rheumatoid arthritis, showing reduction in number of loops, plasma space (indicating plasma skimming, arrow), and moderate widening of efferent limb extending into subpapillary venular plexus.

#### *Systemic sclerosis*

Progressive systemic sclerosis (PSS) and localized

scleroderma (LS) were observed to have what seems to be a characteristic pattern, namely a particular type of enlargement of capillaries: individual capillaries are seen to be enlarged four to ten times the size of an average normal loop, and the enlargement is present throughout all three limbs. Associated with this enlargement is a reduction in the number of loops within its immediate vicinity. As mentioned in the sections on definitions, ten to thirty loops may be seen in 1 sq. mm. in a normal subject. Whenever this enlarged loop is observed, it may be the only one in 1 sq. mm. or there may be up to five. Also, the more advanced the state of disease the greater the frequency of occurrence of this loop type and the more marked the paucity of loops. Four of the patients with localized scleroderma had this type of change but are not listed as such in Table III because, although the loops were enlarged, the degree of paucity as established by our criteria was not significant. It must be pointed out that they were also judged clinically to be less advanced. Two additional cases not included in the tabulation have shown these loop changes but without the typical skin changes that are part of the clinical picture. One of these (ML 44) has since developed overt sclerodermatous lesions on the fingers and hands approximately 1½ years after the first observation. The other (LF 52) is now 2½ years after the first examination) beginning to show tightness and thickness of the skin over both hands. So far this type of capillary pattern has been observed only in progressive systemic sclerosis and localized scleroderma (Fig. 3).

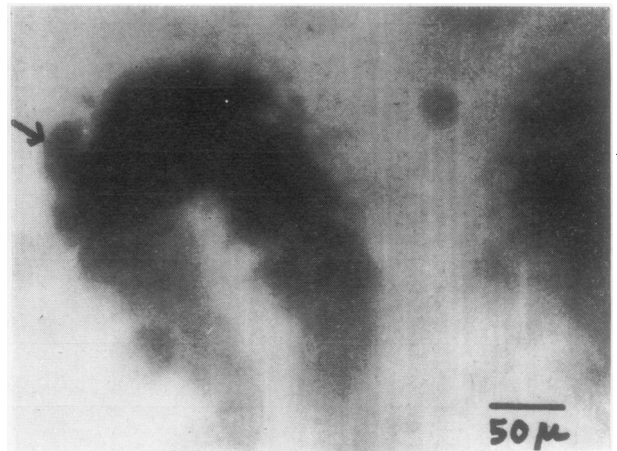


FIG. 3 Example of enlarged nailfold loop as observed in progressive systemic sclerosis (scleroderma), characterized by marked widening of all three limbs; blood flow is extremely sluggish with large cellular aggregations visible (arrow). The total number of capillaries is reduced as compared to Fig. 1.

*Systemic lupus erythematosus*

Patients with systemic lupus erythematosus and the three cases diagnosed as possible SLE were observed to have similar changes in microcirculatory pattern. A bizarre form of loop, which we have described as meandering with loose convolutions, was observed only in these patients. This type of loop seems to be an extension of severe tortuosity (Fig. 4) and may resemble a glomerular tuft in what appears to be its severest form (Fig. 5). In Table III only 91 per cent. of the SLE patients are listed as showing this abnormal loop. The three patients who were not listed had this type of loop but did not meet our other criteria as explained above.

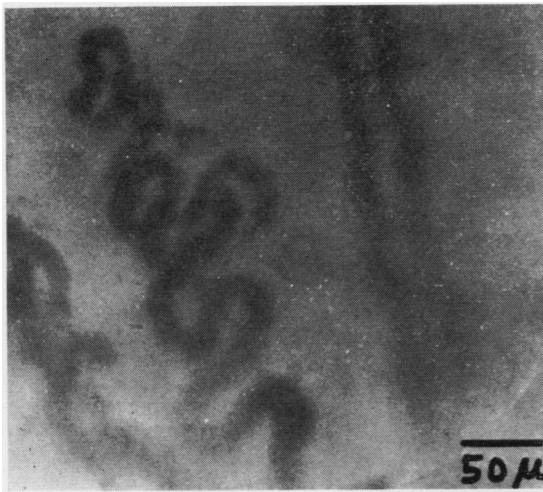

FIG. 4 Nailfold capillary pattern described as 'meandering with loose convolutions' as observed in systemic lupus erythematosus. The loops in this field display elongation of capillaries by two processes, namely meandering (a and b) and straight or linear (c).

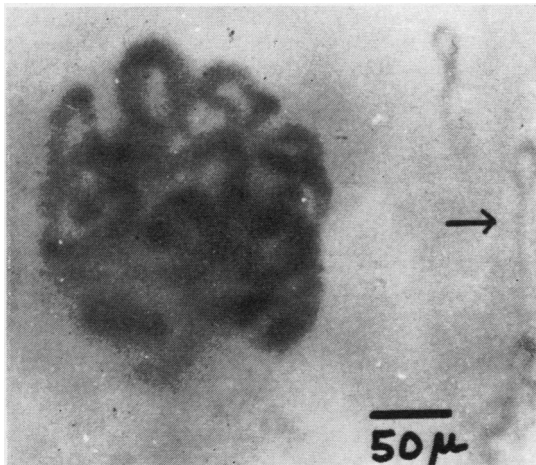


FIG. 5 A more extensive form of meandering with loose convolutions in nailfold capillaries in systemic lupus erythematosus. Normal loops are also visible (arrow).

*Psoriatic arthritis* (Fig. 6)

Patients with psoriatic arthritis were observed to have capillaries which meandered, but in a distinctly different way from those in SLE patients. This form of meandering with tight terminal convolutions is characterized by the short radii of the convolutions. Thus, this type of loop which may have as many arcs as those in SLE will occupy a smaller area than the meandering loops in SLE in which the convolutions have larger radii. This form of capillary has been observed only in psoriatic arthritis and psoriasis. This type of capillary was observed both in lesions and in normal appearing skin, but those in the lesions were wider and the flow was slower.

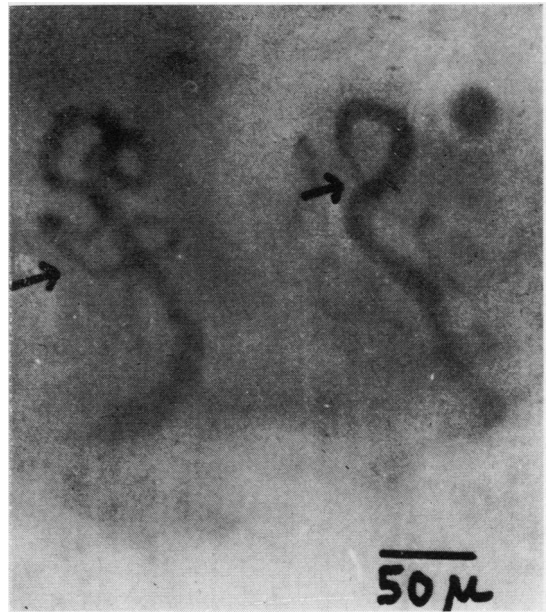


FIG. 6 Meandering as observed in psoriasis and psoriatic arthritis. This form of meandering usually does not involve the whole loop. Also evident is the severe narrowing of the afferent limb (arrows).

*Dermatomyositis*

Only three patients with dermatomyositis were studied. As shown in Table III, increased tortuosity of transitional and efferent limbs and widening of all three limbs were present in all. These features were similar to those in SLE but other features of the latter were absent.

The morphological changes observed in RA, psoriatic arthritis, PSS, and SLE once present appear to be permanent and do not change. During spontaneous or medically-induced remissions, the basic loop aberration is not observed to revert to a normal hairpin-shaped capillary although reduction in calibre of one or more of the capillary limbs may be observed. In this respect the morphological

changes do not reflect the state of the disease. However, the ratio of abnormal to normal capillaries was seen to increase with time in those patients whose disease was judged clinically to be progressing. In contrast, the rheological change of increased aggregate flow with delayed dispersion of aggregates was observed to wax and wane with exacerbations and remissions. In remissions, congestions and cell aggregations were reduced and flow was less sluggish.

In some of the controls, especially in the older age group, none of whom presented with any demonstrable manifestations of disease, undulations and crossings were seen; never, however, did these deviations from the classical 'hairpin' reach the proportions of 'tortuosity' as defined above. None of the other abnormalities described in the four conditions studied was observed in controls. Similar observations have not been made on a systematic basis in any large number of patients with other chronic diseases, but a few such patients have been examined. None of the changes described here were seen in sixteen patients with osteoarthritis involving the hands or in three with ankylosing spondylitis. Well-known changes were seen in patients with diabetes but these were of different type as described elsewhere (Terry, Messina, Schwartz, Redisch, and Steele, 1967). Similarly, these changes have not been seen in patients with various types of cancer or arteriosclerosis. In patients with congestive heart failure and in a smaller number with polycythaemia vera rheological changes were seen but not of the type described in this paper.

## Discussion

Some of the observations reported here have been made earlier by other workers. It is not the purpose of this paper to review all the literature; reference is made only to those papers which help to demonstrate certain points. The reader is directed to the following references for a broader coverage of clinical capillary microscopy, including a history of the method (Gilje and others, 1953; Roth, 1946; Davis and Landau, 1966).

Brown and O'Leary (1928) described 'giant loops' and 'deficiency in number of loops' in diffuse primary scleroderma. Kurban, Farah, and Chaglassian (1964), using biopsy material from the palmar hypothenar, stained for alkaline phosphatase activity and found many of the papillae devoid of loops. We have observed in all patients with PSS a marked paucity of loops associated with enlargement of individual loops. We have described these changes as related because it is our impression that the striking enlargement, which was not seen in any other group studied, may well represent a compensatory mechanism. The more advanced the sclerodermatous

process, the more marked is the paucity of loops and the incidence and degree of individual enlargement. In addition, these capillary changes have been observed in two of our patients long before the development of the clinically observable skin changes. In both PSS and localized scleroderma, normal loops may also be seen, but their number is comparatively small. This morphological change may serve as a basis for distinguishing PSS and LS from the other entities.

Extrapolation of these observations to other organ systems is of course speculative. However, evidence is gradually accumulating which suggests that PSS is a multiorgan disease the clinical features of which are associated with vascular lesions (Wildenthal, Schenker, Smiley, and Ford, 1968). Recently, Norton, Hard, Lewis, and Ziff (1968), using electron microscopy, studied biopsy material of skeletal muscle from patients with PSS, and found a capillary abnormality consisting in a laminated appearance of the basement membrane, increase in the diameter of the capillaries, and decrease in the number of vessels. The appearance of this vascular abnormality, as seen *in vivo* with the capillary microscope in the 'non-involved' skin and likewise with the electron microscope in 'non-involved' skeletal muscle, tends to support our impression and a previous suggestion (Brown, O'Leary, and Adson, 1931) that the vascular changes are forerunners of some of the other pathological features and may play a significant role in pathogenesis. This may also be true for SLE (Lawler and Lumpkin, 1961), since the abnormal microvascular formation described above occurred not only in areas of rash but also in apparently normal skin without histological evidence of inflammation (Smukler, Redisch, Messina, Hughes, and Kulka, 1967). This suggests that microangiopathy may be a basic manifestation of the disease.

As noted, total capillary surface per unit area was increased in rheumatoid arthritis, psoriasis, and often in SLE. There are five possible mechanisms by which this increase might be brought about:

- (1) Perfusion of previously non-perfused channels;
- (2) Formation of new capillaries;
- (3) Widening;
- (4) True enlargement;
- (5) Elongation.

The opposite mechanism can have the opposite effect. The fifth mechanism may consist either in straight elongation and extension into the tissue or increased tortuosity or meandering without linear extension into the tissue. More than one of these mechanisms can be operative. For example, in our group of rheumatoid arthritis patients, 70 per cent. showed a decrease in the number of visible capillaries, 41 per cent. linear elongation, and 48 per cent in-

crease in tortuosity. Both types were seen separately as well as in combination.

Gilje and others (1953) described 'corkscrew loops' in the nailfold and palmar plaques of patients with SLE. Lawler and Lumpkin (1961) observed no significant alteration in size and shape of vessels in normal skin from forearms of patients with SLE, but they did find a decrease in the total number of loops. Kurban and others (1964), using the alkaline phosphatase method, demonstrated changes in involved and non-involved skin of lupus patients; shortening of the loops and frequent branching, coiling, and double looping. In our group of SLE patients, only 11 per cent. showed a decrease in number of capillaries, 67 per cent. showed increased tortuosity, 88 per cent. showed widening of all limbs, and 91 per cent. showed the type of loop described by us as meandering with loose convolutions. The meandering loop appears to be similar to the 'corkscrew' loop (Gilje and others, 1953). This type has been observed in SLE and in three patients with possible SLE, and may well serve as a distinguishing feature from the other entities studied. Three patients with drug-induced SLE and four who were referred with the diagnosis of RA were found to have meandering with loose convolutions on capillaroscopy. In the last four cases, positive LE-cell preparations and antinuclear antibody tests with diffuse pattern were subsequently obtained, and the final clinical diagnosis was systemic lupus erythematosus.

The morphological changes reported here in psoriatic arthritis have also been observed in psoriasis (Ross, 1964), and this we have been able to confirm. The tight terminal convolutions observed in all our patients with psoriatic arthritis were also seen in the twenty patients with psoriasis unaccompanied by arthritis whom we screened. The fact that these features in psoriatic patients were seen in uninvolved areas of skin as well as in lesions suggests that these are very early, if not primary, changes and that inflammation may be a secondary superimposed feature.

The consistent involvement of the efferent (venular) limb in the various morphological changes observed here tends to support a schema proposed by Kulka (1964) for the mechanism of tissue damage through microcirculatory impairment in these disease entities. Various factors, neural, humoral, and haemic, are considered to mediate the three basic circulatory defects of vasoconstriction, venular dilation, and endothelial leakage; they may lead to an increase in degree of inflammatory injury, manifested by exudation, proliferation, and necrosis. Exaggerating these defects and superimposed upon them are, of course, the rheological changes which contribute to reduced flow, congestion, increased dilation of

terminal vessels, and leakage of plasma as well as blood cells, eventually causing stasis and necrosis. These observations and the schema offer at least a partial explanation of the clinical observation of ischaemic ulceration and gangrene which are sometimes observed in rheumatoid arthritis, systemic lupus, and other of these diseases, even in the absence of demonstrable necrotizing arteritis or other occlusive arterial or major venous disease.

While there is no direct evidence linking these vascular manifestations to the many immunological features accompanying these diseases (Kunkel and Tan, 1964), it seems more than likely that they may be implicated in the pathogenesis of the observed vascular changes. Antigen-antibody complexes are known to occur in systemic lupus erythematosus (Tan, Schur, and Kunkel, 1965) and rheumatoid arthritis (Edelman, Kunkel, and Franklin, 1958), and may well be present in some of the other connective tissue disorders, all of which have a high incidence of antibodies to various nuclear constituents, rheumatoid factors, and hyperglobulinaemia. Some of the mechanisms by which these complexes can, in certain well defined conditions, localize in blood vessels and initiate a series of changes ultimately leading to tissue damage has now been extensively documented by Cochrane (1963), Kniker and Cochrane (1968), and Cochrane and Hawkins (1968). It seems possible that the changes observed with the capillary microscope are the counterpart *in vivo* of the pathological lesions encountered on histological examination of the tissues. Studies in conjunction with Dr. P. Kulka correlating the results of capillary microscopy with pathological studies support this concept (Kulka, 1964).

### Summary and conclusions

Surface microcirculatory studies carried out in patients with RA, SLE, PSS, and psoriatic arthritis have revealed some rheological and morphological deviations from the norm. The rheological changes consist in slowing of flow and increase in intraluminal cell aggregation. Morphological changes concern mainly the number and the width and length of microchannels. Widening and elongation occur in different forms; these forms appear to be consistent and predictable in at least three of the entities studied, namely SLE, psoriatic arthritis, and PSS. The most striking changes seen in significantly high percentages were:

In RA: Tortuosity, elongation of loops, increased plasma skimming.

In SLE: Meandering with loose convolutions, widening, increased aggregation of cells and delayed dispersion of aggregates, dusky colour of blood column.



In PSS: Marked reduction in number of loops, marked individual enlargement of loops, slowing and stagnation of blood flow, dark colour of blood column.

In psoriatic arthritis: Tight terminal convolutions. The rheological changes may explain the occurrence of ischaemic manifestations in the absence of occlusive arterial and major venous disease.

## References

- BROWN, G. E., O'LEARY, P. A., AND ADSON, A. W. (1931) *Ann. intern. Med.*, **4**, 531 (Diagnostic and physiologic studies in certain forms of scleroderma).
- BROWN, G. E., AND O'LEARY, P. A. (1928). *Arch. intern. Med.*, **36**, 73 (Skin capillaries in scleroderma).
- COCHRANE, C. G. (1963) *J. exp. Med.*, **118**, 489 (Studies on the localization of circulating antigen-antibody complexes and other macromolecules in vessels. I. Structural studies).
- AND HAWKINS, D. (1968) *Ibid.*, **127**, 137 (Studies on circulating immune complexes. III. Factors governing the ability of circulating complexes to localize in blood vessels).
- DAVIS, E., AND LANDAU, J. (1966) 'Clinical Capillary Microscopy'. Thomas, Springfield, Ill.
- EDELMAN, G. M., KUNKEL, H. G., AND FRANKLIN, E. C. (1958) *J. exp. Med.*, **108**, 105 (Interaction of the rheumatoid factor with antigen-antibody complexes and aggregated gammaglobulin).
- GILJE, O., O'LEARY, P. A., AND BALDES, E. J. (1953) *Arch. Derm.*, **68**, 136 (Capillary microscopic examination in skin diseases).
- HARDAWAY, R. M. (1965) *Milit. Med.*, **130**, 451 (Disseminated intravascular coagulation with special reference to shock and its treatment).
- HAUPTMANN, A. (1964) *Arch. Neurol. Psychiat.*, **56**, 631 (Capillaries in the finger nailfold in patients with neurosis, epilepsy and migraine).
- KNIKER, W. T., AND COCHRANE, C. G. (1968) *J. exp. Med.*, **127**, 119 (The localization of circulating immune complexes in experimental serum sickness. The role of vasoactive amines and hydrodynamic forces).
- KNISELY, M. H., BLOCK, E. H., ELIOT, T. S., AND WARNER, L. (1947) *Science*, **106**, 431 (Sludged blood).
- KULKA, J. P. (1964) *Ann. N.Y. Acad. Sci.*, **116**, 1018 (Microcirculatory impairment as a factor in inflammatory tissue damage).
- KUNKEL, H. G., AND TAN, E. M. (1964) *Advanc. Immunol.*, **4**, 351 (Autoantibodies and disease).
- KURBAN, A. K., FARAH, F. S., AND CHAGLIASSIAN, H. T. (1964) *Dermatologica (Basel)*, **129**, 257 (Capillary changes in some connective tissue diseases).
- LAWLER, J. C., AND LUMPKIN, L. R. (1961) *Arch. Derm.*, **83**, 636 (Cutaneous capillary changes in lupus erythematosus).
- LUTZ, B. R. (1951) *Physiol. Rev.*, **31**, 107 (Intravascular agglutination of formed elements of blood).
- NORTON, W. L., HURD, E. R., LEWIS, D. C., AND ZIFF, M. (1968) *J. Lab. clin. Med.*, **71**, 919 (Evidence of microvascular injury in scleroderma and systemic lupus erythematosus: quantitative study of the microvascular bed).
- ROSS, J. B. (1964) *Brit. J. Derm.*, **76**, 511 (The psoriatic capillary. Its nature and value in the identification of the unaffected psoriatic).
- (1966). *J. invest. Derm.*, **47**, 282 (Nailfold capillaroscopy—A useful aid in the diagnosis of collagen vascular diseases).
- ROTH, G. M. (1946) 'Nailfold capillaries in man', in 'Peripheral Vascular Diseases', ed. E. V. Allen, N. W. Barker, and E. A. Hines, Jr., pp. 148-164. Saunders, Philadelphia.
- SMUKLER, N. M., REDISCH, W., MESSINA, E. J., HUGHES, G., AND KULKA, J. P. (1967) 'Capillaroscopy and biopsy study of cutaneous microangiopathy in systemic lupus erythematosus'. Presented at American Rheumatism Association, New York, June 15, 1967.
- TAN, E. M., SCHUR, P. H., AND KUNKEL, G. H. (1965) *J. clin. Invest.*, **44**, 1104 (DNA in the serum of patients with systemic lupus erythematosus (SLE): Abstract).
- TERRY, E. N., MESSINA, E. J., SCHWARTZ, M. S., REDISCH, W., AND STEELE, J. M. (1967) *Diabetes*, **16**, 595 (Manifestation of diabetic microangiopathy in nail-fold capillaries).
- WALLS, E. W., AND BUCHANAN, T. J. (1965). *J. Anat.*, **90**, 329 (Observations on the capillary blood vessels of the human nailfold).
- WILDENTHAL, K., SCHENKER, S., SMILEY, J. D., AND FORD, K. L., JR. (1968) *Arch. intern. med.*, **121**, 365 (Obstructive jaundice and gastrointestinal haemorrhage in progressive systemic sclerosis).

RÉSUMÉ

**Les observations capillairescopes dans les maladies rhumatismales**

Les études microcirculatoires de surface entreprises chez les malades atteints d'arthrite rhumatoïde, de lupus érythémateux disséminé, de sclérose systémique progressive et d'arthrite psoriasique ont révélé quelques déviations rhéologiques et morphologiques. Les changements rhéologiques consistent en un ralentissement du flot et en une augmentation de l'agrégation des cellules à l'intérieur des capillaires. Les changements morphologiques concernent surtout le nombre, la largeur et la longueur des microconduits. L'allongement et l'élargissement ont lieu sous différentes formes; ces formes sont compatibles et peuvent être prédites dans au moins trois des entités étudiées, le lupus érythémateux, l'arthrite psoriasique et la sclérose systémique progressive.

Les changements les plus marqués rencontrés à un pourcentage élevé:

Dans l'arthrite rhumatoïde: la tortuosité, l'allongement des sinuosités, l'augmentation dans la séparation du plasma.

Dans le lupus érythémateux disséminé: les circonvolutions tortueuses, l'élargissement et l'augmentation dans l'agrégation des cellules et la dispersion différée des agrégats, la couleur d'un brun foncé de la colonne sanguine.

Dans la sclérose systémique progressive: la réduction marquée dans le nombre des sinuosités, un élargissement individuel marqué des sinuosités, le ralentissement et la stagnation du flot sanguin et la couleur foncée de la colonne sanguine.

Dans l'arthrite psoriasique: les circonvolutions serrées et tordues.

Les changements rhéologiques peuvent expliquer la présence des manifestations ischémiques en l'absence des maladies artérielles occlusives ou des maladies veineuses graves.

SUMARIO

**Observaciones capilaroscópicas en enfermedades reumáticas**

Estudios microcirculatorios superficiales, llevados a cabo en pacientes con PCE, LE, esclerosis diseminada (EPS) y artritis psoriática, han revelado ciertas desviaciones de la norma, reológicas y morfológicas. Los cambios reológicos consisten en la retardación del flujo y el aumento en la agregación celular intraluminal. Los cambios morfológicos se refieren, principalmente, al número y el ancho y longitud de los microcanales. El ensanchamiento y la elongación ocurren de distintas formas; y estas formas parecen ser consistentes y adivinables en, por lo menos, tres de las entidades estudiadas, a saber: LE, artritis psoriática y EPS. Los cambios más notables observados en proporciones altamente significativas eran:

En PCE: sinuosidad, elongación de los anillos, aumento de la espuma plasmática.

En LE: Septenteante con circunvoluciones sueltas, ensanchamiento, mayor agregación de células, dispersión retardada de agregados, color oscuro de la columna de sangre.

En EPS: Notable reducción en el número de anillos, notable crecimiento individual de anillos, disminución y estancamiento del flujo sanguíneo, color oscuro de la columna de sangre.

En artritis psoriática: circunvoluciones de torsión apretadas.

Los cambios reológicos podrían explicar la presencia de manifestaciones isquémicas en ausencia de enfermedad oclusiva arterial y afección venosa importante.