


# Case of apparent mpox reinfection

John Golden <sup>1,2</sup>, Lindsey Harryman,<sup>2</sup> Megan Crofts,<sup>2</sup> Peter Muir,<sup>3</sup> Matthew Donati,<sup>3</sup> Sophie Gillett,<sup>3</sup> Charles Irish<sup>3</sup>

<sup>1</sup>56 Dean Street, Department of GUM/HIV, Chelsea and Westminster Hospital NHS Foundation Trust, London, UK

<sup>2</sup>Unity Sexual Health, University Hospitals Bristol and Weston NHS Foundation Trust, Bristol, UK

<sup>3</sup>Southwest Regional Laboratory, UK Health Security Agency, North Bristol NHS Trust, Bristol, UK

## Correspondence to

Dr John Golden, 56 Dean Street, Department of GUM/HIV, Chelsea and Westminster Hospital NHS Foundation Trust, London SW10 9NH, UK; j.golden@nhs.net

Received 27 December 2022

Accepted 7 January 2023

Published Online First

27 January 2023

## ABSTRACT

We present an apparent second episode of mpox (monkeypox) genital ulcerative disease in a non-immunosuppressed MSM (man who has sex with men) patient who had completely recovered from a primary mpox infection 4 months previously. The patient had also received a complete two-dose course of smallpox vaccination between the two presentations. This case highlights the importance of continuing to include mpox in the differential diagnoses for individuals presenting with genital or mucosal ulceration, regardless of assumed immunity derived from prior infection or vaccination.

## BACKGROUND

In 2022, the first multicountry outbreak of mpox (monkeypox) was recognised outside of Africa,<sup>1</sup> with the majority of cases being managed in sexual health services. Most people have presented with genital, perianal or non-genital skin lesions and lymphadenopathy,<sup>2</sup> but there have also been atypical presentations<sup>3</sup> such as proctitis.<sup>4,5</sup> It is unclear

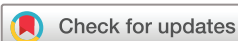whether primary mpox infection leads to lasting immunity from reinfection.<sup>3</sup> We present a case of laboratory-confirmed second mpox infection diagnosed 12 weeks after recovery from the initial infection.

## PRESENTATION AND INVESTIGATIONS

A white man in his early 30s presented in July 2022 to a sexual health clinic in South West England with a recent history of inguinal lymphadenopathy, rectal discharge and rectal pain. Examination revealed obvious rectal discharge only and no external or mucosal skin lesions. He was treated empirically for proctitis with 2 weeks of doxycycline and 1 week of aciclovir. A rectal swab taken on this occasion tested positive for mpox, and he was given routine isolation advice, making an uncomplicated recovery within 2 weeks. He received two doses of Jynneos smallpox vaccination as part of the nationwide programme—the first dose given subcutaneously 1 week after this presentation and the second dose given subcutaneously 10 weeks after that. In November 2022, he re-presented with a 3-day

**Table 1** Results of investigations in relation to clinical presentation, attendance and vaccination

	Timeline				
	T0	T1*	T11†	T16‡	T20§
	First attendance	Vaccine dose 1	Vaccine dose 2	Second attendance	Third attendance
Symptoms and signs	Rectal pain, rectal discharge and inguinal lymphadenopathy			Headache, back pain, neck pain, anal sore and aphthous mouth ulcer	Rectal pain, rectal discharge
Investigations (sites)					
CT/GC NAAT (Aptima Combo, Hologic) (rectal and pharyngeal swabs, urine)	Negative			Negative	GC positive (rectal)
HSV PCR (in-house lab based test at UKHSA, Bristol) (rectal, etc)	HSV-2 positive (rectal)			Negative (anal sore) Negative (mouth ulcer)	Not tested
T.pallidum PCR (in-house lab based test at UKHSA, Colindale) (rectal etc)	Negative (rectal)			Negative (anal sore) Negative (ulcer in mouth)	Negative (rectal)
Orthopoxvirus DNA PCR and mpox virus PCR (UKHSA lab developed test) (rectal, etc)	Positive (rectal)			Positive (anal sore) Negative (ulcer in mouth)	Negative (rectal)
HIV (Architect HIV Ag/Ab combo assay (Abbott)) (serum)	Negative			Negative	Negative
Hepatitis C (Architect anti-HCV assay (Abbott)) (serum)	Negative			Negative	Negative
RPR (rapid plasma reagin) (serum)	1:2			Positive neat	Positive neat
*1 week after first attendance. †11 weeks after first attendance. ‡16 weeks after first attendance. §4 weeks after second attendance. CT, <i>Chlamydia trachomatis</i> ; GC, <i>Neisseria gonorrhoeae</i> ; HSV, herpes simplex virus; mpox, monkeypox.					



© Author(s) (or their employer(s)) 2023. No commercial re-use. See rights and permissions. Published by BMJ.

**To cite:** Golden J, Harryman L, Crofts M, et al. *Sex Transm Infect* 2023;**99**:283–284.

history of headache, backache and neck pain. He had no focal neurological signs on examination. There was a 2 mm aphthous ulcer on his right lower gum and a 1 mm ulcer 2 cm within the anal canal as well as tender left-sided raised cervical lymph nodes. He reported numerous casual male sexual partners over the preceding 2 weeks. The anal ulcer tested positive for mpox, and again he had an uncomplicated recovery within 2 weeks. Significant medical history included a diagnosis of neurosyphilis associated with syphilis seroconversion the previous year, for which he had completed a treatment course. The patient had, in the past, been treated for rectal *Chlamydia trachomatis* and *Neisseria gonorrhoeae* infections. He had no other comorbidity and took PrEP (HIV pre-exposure prophylaxis) only with no other prescribed or recreational drugs.

#### OTHER INVESTIGATIONS

Results are summarised in [table 1](#). Both mpox positive swab results were confirmed by the UKHSA Rare & Imported Pathogens Laboratory, Porton Down. Both episodes were accordingly diagnosed as mpox proctitis. A repeat rectal swab taken 2 weeks after recovery from the second episode tested negative for mpox. The patient tested positive for rectal gonorrhoea at this time.

#### DIFFERENTIAL DIAGNOSIS

During both presentations, chlamydia (including lymphogranuloma venereum), gonorrhoea, herpes simplex virus, syphilis and mpox were all considered in the differential.

#### TREATMENT

At his second attendance, the patient was extremely anxious about a recurrence of neurosyphilis and was offered empirical treatment with oral prednisolone, oral probenecid and intramuscular procaine penicillin while awaiting syphilis serology. Treatment was terminated once syphilis reinfection had been ruled out by a static RPR.

#### DISCUSSION

As far as we are aware, there have not been any other published cases of reinfection during the 2022 mpox outbreak. An alternative explanation to reinfection is that mpox infection persisted following first infection during the intervening period. This is unlikely to explain the new clinical signs and prodromal illness the patient experienced at the second presentation, which could not be attributed to any other investigated STI. Persistence is also unlikely, given that time from infection to viral clearance is typically less than 6 weeks<sup>6</sup> and the repeat rectal swab 2 weeks after the second presentation was negative for mpox. Nucleotide sequence comparison of mpox DNA detected in both clinical episodes and additional tests between episodes would be required to shed further light on this. Meanwhile, this case informs the advice health professionals give to patients about mpox and clearly indicates including mpox infection in the differential for patients presenting with mucocutaneous lesions, regardless of prior infection or vaccination status.

#### Learning points

- ⇒ Patients with a prior confirmed mpox infection presenting with signs and symptoms of mpox at a later date should be retested for mpox.
- ⇒ Patients who have previously received a full course of smallpox vaccination presenting with signs and symptoms of mpox should have mpox testing included in a full panel of investigations.
- ⇒ Further investigation is needed to investigate the degree of immunity offered by mpox infection and how this is affected by subsequent smallpox vaccination.
- ⇒ Further investigation is needed to investigate the degree of immunity offered by a course of smallpox vaccination and how this is affected by a previous mpox infection.

**Handling editor** Anna Maria Geretti

**Contributors** All authors were responsible for the care and investigation of the patient. JG wrote and submitted the report and is responsible for its overall content. All authors contributed to editing the report prior to its submission.

**Funding** The authors have not declared a specific grant for this research from any funding agency in the public, commercial or not-for-profit sectors.

**Competing interests** MC received speaker fees from BASHH. PM consulted for and received payment from University Hospital Plymouth & London Medical Laboratory. All other authors declared no competing interests.

**Patient consent for publication** Not applicable.

**Ethics approval** Not applicable.

**Provenance and peer review** Not commissioned; internally peer reviewed.

This article is made freely available to access and read on the journal website in accordance with BMJ's website terms and conditions for the duration of the monkeypox emergency or until otherwise determined by BMJ. You may download and print the article for personal or non-commercial use provided all copyright notices and trademarks are retained. If you wish to reuse any or all of this article please use the request permissions link.

#### ORCID iD

John Golden <http://orcid.org/0000-0002-0763-6170>

#### REFERENCES

- 1 World Health Organization. Disease Outbreak News; Multi-country monkeypox outbreak in non-endemic countries; 2022. <https://www.who.int/emergencies/disease-outbreak-news/item/2022-DON385> [Accessed 27 Dec 2022].
- 2 Girometti N, Byrne R, Bracchi M, *et al*. Demographic and clinical characteristics of confirmed human monkeypox virus cases in individuals attending a sexual health centre in London, UK: an observational analysis. *Lancet Infect Dis* 2022;22:1321–8.
- 3 World Health Organisation. Monkeypox; 2022. <https://www.who.int/news-room/fact-sheets/detail/monkeypox> [Accessed 27 Dec 2022].
- 4 Gedela K, Da Silva Fontoura D, Salam A, *et al*. Infectious proctitis due to human monkeypox. *Clin Infect Dis* 2022. doi:10.1093/cid/ciac713. [Epub ahead of print: 02 Sep 2022].
- 5 UK Health Security Agency. Monkeypox case definition updated to include new symptoms, 2022. Available: <https://www.gov.uk/government/news/monkeypox-case-definition-updated-to-include-new-symptoms> [Accessed 27 Dec 2022].
- 6 Suñer C, Ubals M, Tarín-Vicente EJ, *et al*. Viral dynamics in patients with monkeypox infection: a prospective cohort study in Spain. *Lancet Infect Dis* 2022. doi:10.1016/S1473-3099(22)00794-0. [Epub ahead of print: 12 Dec 2022].